

## Full-Endoscopic Resection of Osteoid Osteoma in the Thoracic Spine: A Case Report

João Paulo Machado Bergamaschi, Carlos Alberto Montovani Costa and Luiz Henrique Sandon

*Int J Spine Surg* 2021, 14 (s4) S78-S86

doi: <https://doi.org/10.14444/7169>

<https://www.ijssurgery.com/content/14/s4/S78>

This information is current as of May 17, 2025.

---

**Email Alerts** Receive free email-alerts when new articles cite this article. Sign up at:  
<http://ijssurgery.com/alerts>

# Full-Endoscopic Resection of Osteoid Osteoma in the Thoracic Spine: A Case Report

JOÃO PAULO MACHADO BERGAMASCHI, MD,<sup>1</sup> CARLOS ALBERTO MONTOVANI COSTA, MD,<sup>2</sup> LUIZ HENRIQUE SANDON, MD<sup>3</sup>

<sup>1</sup>*Clinica Atuali Spine Care, São Paulo, Brazil,* <sup>2</sup>*Clinica Orthos, Piracicaba, Brazil,* <sup>3</sup>*Clinica Atuali Spine Care, São Paulo, Brazil*

## ABSTRACT

Common symptoms such as axial pain or nocturnal pain, associated with warning signs that are often worrisome in addition to nonspecific radiological findings, can characterize benign lesions in the spine, and osteoid osteoma is among them. We describe here a clinical case of a pediatric patient with an expansive bone lesion in the thoracic spine discovered after investigation for thoracic pain, mainly at night, which, despite a good response to simple analgesics, evolved in the short term with global spinal deformity. After a multidisciplinary evaluation, she underwent surgical resection using a pioneering endoscopic technique that allowed the definitive anatomopathological diagnosis of osteoid osteoma and guaranteeing very satisfactory treatment and evolution. Although there are already several therapeutic techniques described and with good results in specific cases of osteoid osteomas and other benign neoplastic lesions of the spine, full-endoscopic resection appears as an innovative and potentially promising option for diagnosis and treatment, especially since it is a safe, effective, and not too morbid intervention.

Minimally Invasive Surgery

Keywords: osteoid osteoma, minimally invasive, endoscopic surgery, bone tumor, spine

## INTRODUCTION

When a patient presents with unexplained axial pain that is difficult to control and alarming symptoms, such as worsening nocturnal pain, deformities or postural changes, and suspicious radiological imaging, benign bone tumor of the spine, although rare, should be considered.<sup>1,2</sup> Historically, management of benign bone tumors includes surgical lesion resection and possible mechanical stabilization. Since the early 1990s, percutaneous (ablation) techniques have been increasingly advocated for resolution of this type of disease.<sup>3</sup>

This case is among the pioneers in the literature in the use of this technique in the resection of tumors, previously more restricted to the treatment of degenerative pathologies of the spine. Since 2012, some case reports began to appear describing full-endoscopic techniques in the initial surgical treatment of spinal tumors.<sup>4</sup>

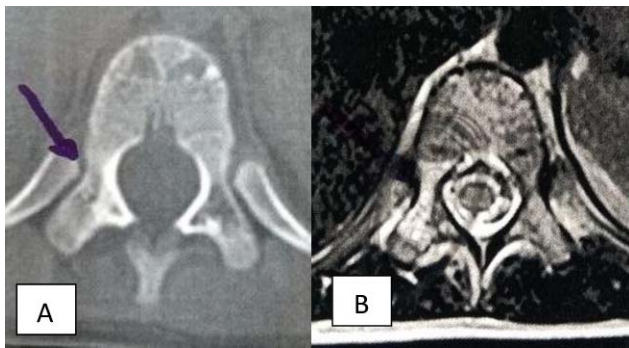
We combined the resoluteness and efficiency of traditional surgical resection with technology and the noninvasiveness of percutaneous techniques to treat a patient with osteoid osteoma of the thoracic spine using a full-endoscopic surgical technique.

The endoscopic procedure proved to be just as resolute as it was noninvasive and resulted in good control of the disease without structural changes to the patient's spine.

## CASE PRESENTATION

A 6-year-old female patient, previously healthy with no history of trauma, presented with nonspecific thoraco-lumbar pain (transition), which was predominantly local in tightness, without irradiation or signs of radiculopathy, and without associated neurological deficits. The pain was of a moderate intensity (visual analog scale: 6/10). There was no associated weight loss or febrile episodes, and while she could not describe the worsening pain, it kept her awake at night. She showed significant improvement with the use of acetylsalicylic acid (AAS).

Medical charts outlined responses to conservative and drug treatment, details of outpatient follow-ups, and complementary radiological investigations but did not specify determinative differential diagnoses. Computed tomography (CT) of the thoraco-lumbar spine showed absence of the right T11 pedicle, and its space was replaced by material with



**Figure 1.** (A) Axial computed tomography of the spine. The image shows absence of the right T11 pedicle, its space being replaced by cell attenuation coefficient material. (B) Axial T2-weighted magnetic resonance image. The image shows the right T11 pedicle with local hypersignal, indicating spondylolysis without signs of listesis.

a cell attenuation coefficient. It was observed high signal on T1- and T2-weighted magnetic resonance at the right pedicle of T11, suggestive of a fracture line (spondylolysis) without signs of listesis (Figure 1). Bone scintigraphy showed a slight and focal increase in osteoblastic activity on the right edge of the T11 vertebra, indicative of spondylolysis (Figure 2).

After 2 months, the patient's parents noticed asymmetry of the patient's shoulder heights and postural changes. Panoramic radiography of the spine showed dextroscoliosis, with a Cobb angle of 20° (Figure 3).

### Surgical Procedure

In view of the clinical picture and progress, we considered a biopsy to obtain material for a histopathological exam for a definitive etiological diagnosis, or resection of the lesion. As it was a single and apparently well-delimited lesion occupying mostly the vertebral pedicle and posterior structures, surgical resection of the lesion was performed by a spine surgeon with more than 5 years of experience in endoscopic spine surgery. Using extraforaminal access, an 8-mm incision was made ~50 mm laterally along the midline at the height of the right T10/T11. Local puncture was performed, guided by radioscopy, with the target being the upper and lateral portion of the T11 pedicle. After positioning the guide wire, dilators were allocated until introduction of the 8-mm-diameter working cannula. Positioning confirmed extraforaminal T10/T11 with radioscopy. An endoscope with an angle of 30° was introduced, with a 3.7-mm working channel (Figure 4). After hemostasis with bipolar cauterization and removal of soft

tissues, desired bone structures were identified. Drainage was performed caudally using a 3.5-mm-diameter foraminoplasty burr around the T11 right upper articular process. With removal of the cortical bone layer from the pedicle, reddish bone tissue was seen with hypervascularization interspersed with whitish tissue with hardened consistency. Bone material was collected for biopsy with endoscopic forceps and Kerrison (Figure 5). Complete removal of the lesion was performed under endoscopic vision. The end of resection was determined according to the macroscopic aspect of the bone structure of the surgical bed and by radioscopy guidance, keeping the lower bone cortex of the right T11 pedicle intact (Figure 6).

After bone resection, local hemostasis, and bipolar cauterization, the residual trabecular tissue in all beds was reviewed. The endoscope and working cannula were removed, and skin was closed with a 4.0 nylon single stitch (Figure 7).

### Outcomes

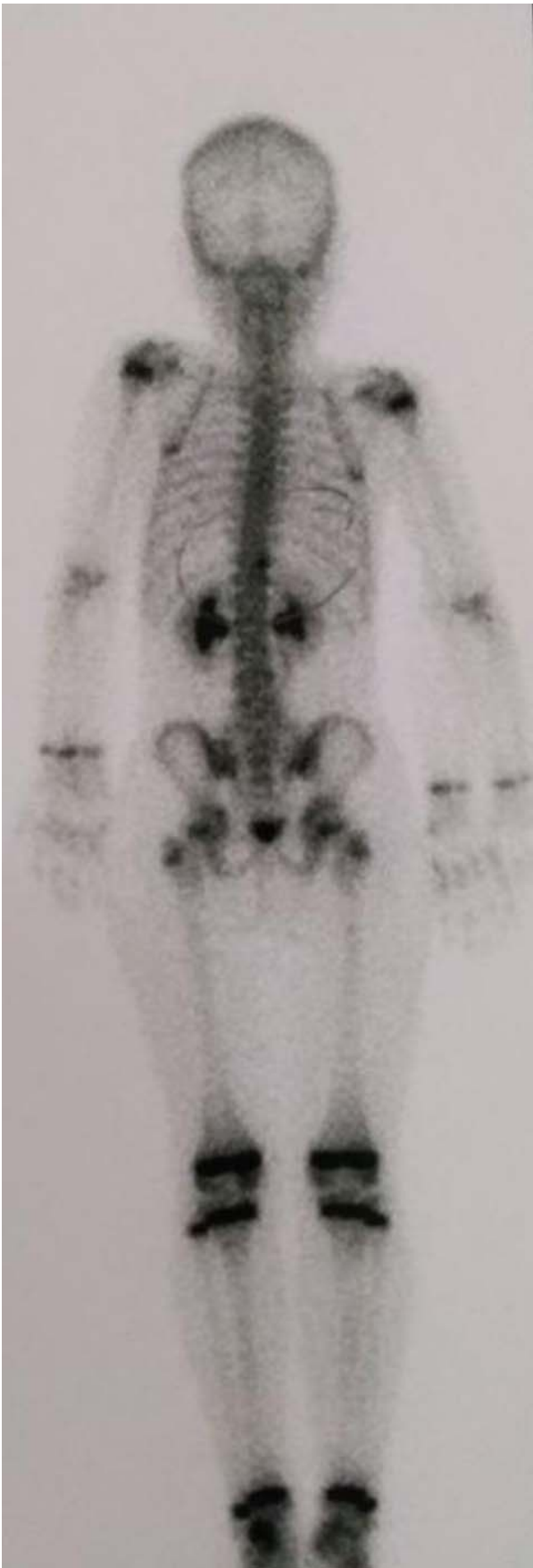The patient reported immediate pain improvement without neurological changes in the postoperative period. She was discharged less than 24 hours after surgery. There was progressive reduction of local pain, and daily routine activities and physical/school activities were resumed within 7 days. The anatomopathological examination identified "bone lesion suggestive of osteoid osteoma, with no signs of malignancy in the piece."

At the 1-year outpatient follow-up, the patient showed complete remission of clinical symptoms and no radiological signs of lesion recurrence (Figure 8).

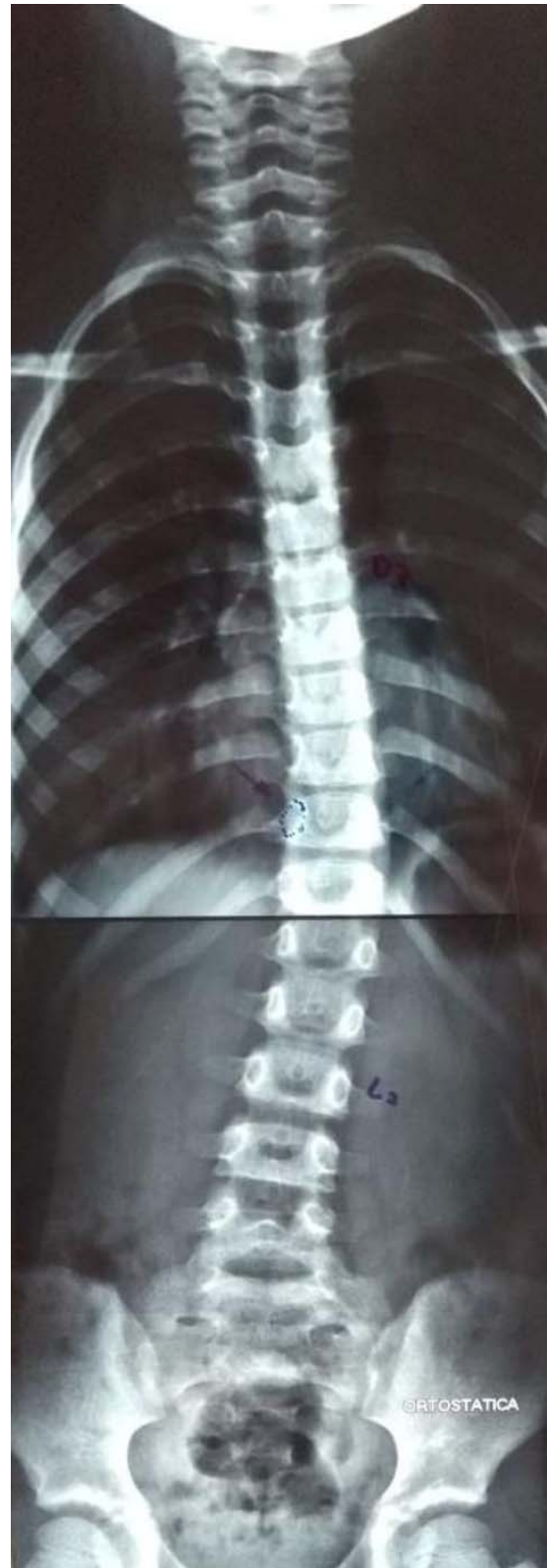## DISCUSSION

### Osteoid Osteoma

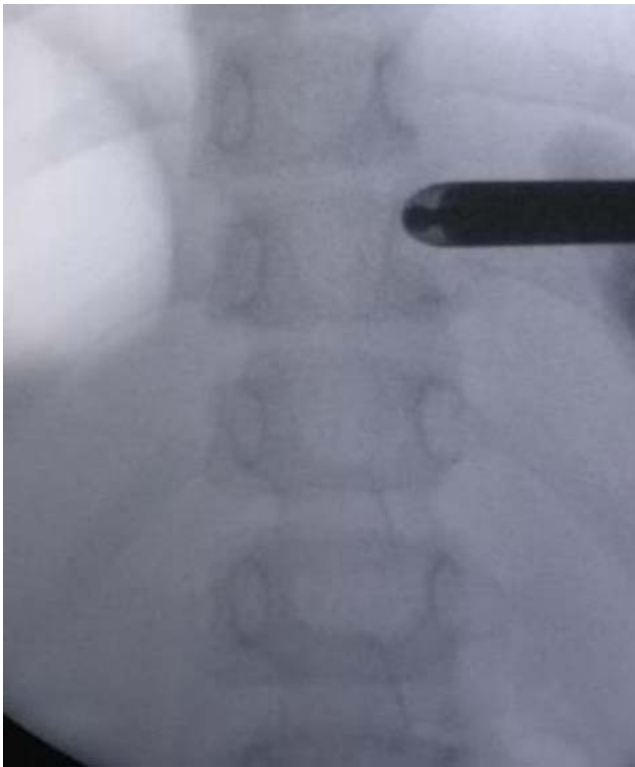
Benign tumors account for only 4%–13% of spinal injuries.<sup>5</sup> Osteoid osteoma, which accounts for only 0.3% of all primary bone tumors,<sup>6</sup> was first described by Jaffe in 1935.<sup>7</sup> Osteoid osteomas are lesions with proliferation of bone cells, frequently affecting long bones.<sup>8</sup> Only 20% of osteoid osteomas occur in the spine.<sup>9</sup> Structurally, osteoid osteomas contain osteoblasts that produce immature bone tissue. They are usually small, benign, and self-limited with local production of prostaglandin PGE2 in the nidus (to which its main symptom, local pain, is attributed).<sup>7</sup>



**Figure 2.** Bone scintigraphy. The image shows a slight increase in osteoblastic activity on the right edge of the T11 vertebra.



**Figure 3.** Panoramic radiography. The image shows dextrochondral scoliosis with a 20° Cobb angle.



**Figure 4.** Positioning the working cannula at the extraforaminal T10/T11 endoscopic approach.

The thoraco-lumbar spine is the most common site of osteoid osteomas, involving mainly posterior elements, such as spinous processes, transverse processes, facets, laminae, and pedicles.<sup>7,10</sup> There seems to be a higher incidence in males (2:1–4:1).<sup>9</sup> The most common age at presentation is from the age of 10 to early adulthood.<sup>7,10</sup>

Due to its nonspecificity, the average duration of symptoms before final diagnosis of osteoid osteoma is ~20 months. Most patients (80%–100%) have neck or back pain, usually localized but occasionally radicular, and the pain may correlate with activity. It usually appears or worsens at night and usually responds very well to treatment with AAS or nonsteroidal anti-inflammatory drugs (NSAIDs). AAS relieves pain in 14%–90% of patients.<sup>7,10</sup>

### Radiological Findings

Osteoid osteomas are solitary lesions and mostly osteosclerotic on radiography, with or without visible nidus.<sup>7</sup> Calcification of the nidus and an area of surrounding sclerosis with low signal intensity are common on T1- and T2-weighted images. With gadolinium administration, there may be intense uptake within the vascular nidus.<sup>10</sup>

Spinal angiography usually reveals a nonspecific pattern of hypervascularity in these lesions, but it is rarely indicated and should not be performed routinely.<sup>10</sup>

Differential diagnoses for osteoid osteoma include osteoblastoma, aneurysmal bone cyst, giant cell tumor, osteosarcoma, Ewing's sarcoma, cartilaginous tumors (enchondroma, osteochondroma, and chondrosarcoma), and osteomyelitis.<sup>10</sup> Metastases should be included in the differential diagnosis in elderly patients, and fibrous dysplasia should be considered if the pattern of involvement is polio-stotic. The location of the lesion within the spine and its imaging characteristics can differentiate it from most of these lesions; however, in some cases, definitive diagnosis can be made only with histopathological examination.<sup>10</sup>

### Histology

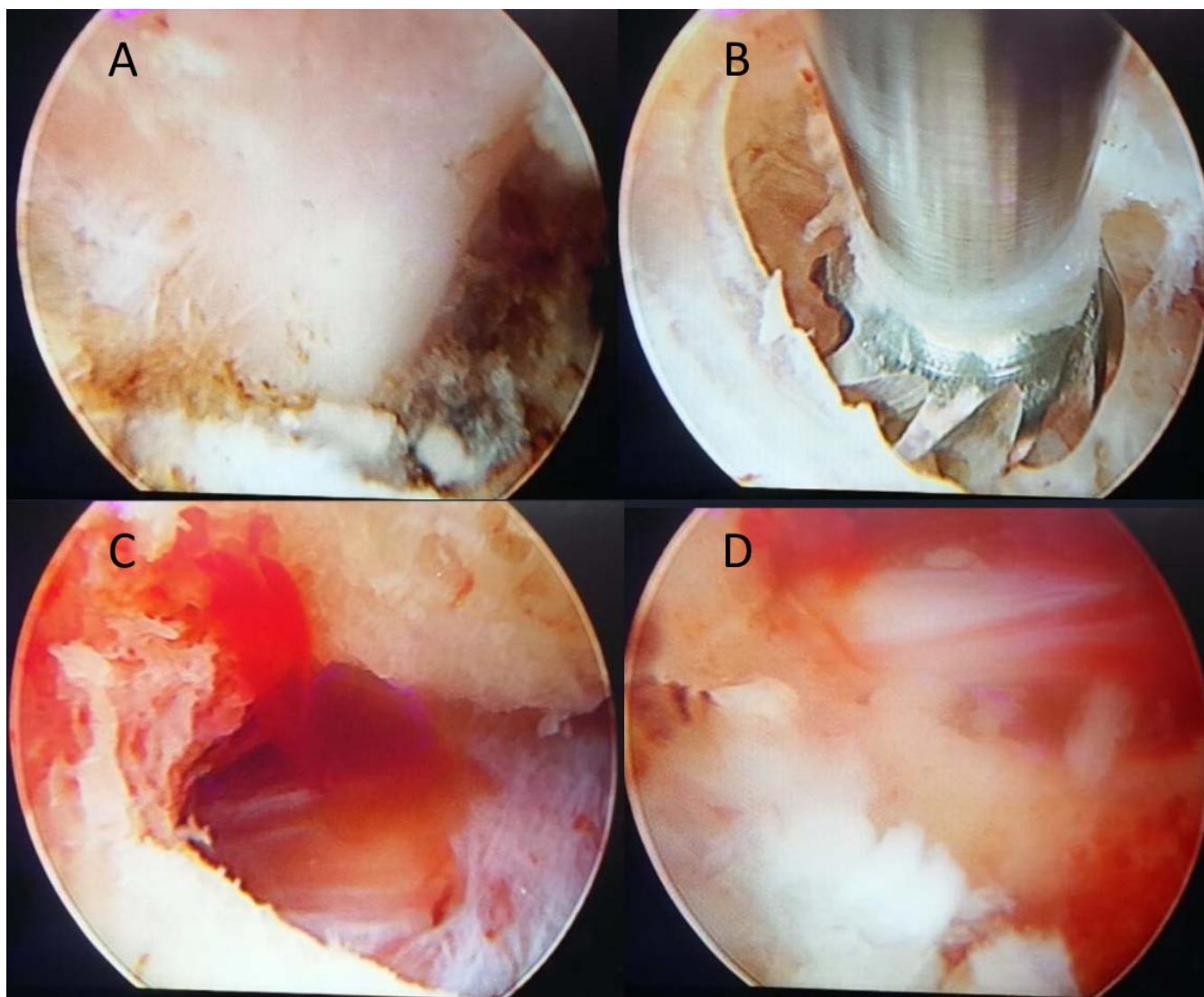
On histological examination, osteoid osteoma consists of a reddish yellow nodule with osteoblasts, producing osteoid bone (immature) and tissue trabeculae interconnected with a highly vascularized fibrous connective tissue ring. There are varying degrees of sclerosis around the lesion.<sup>10</sup>

In the past, osteoid osteoma and osteoblastoma were often differentiated based simply on size. McLeod et al<sup>11</sup> arbitrarily defined lesions 1.5 cm or less in diameter as osteoid osteomas and lesions over 1.5 cm in diameter as osteoblastomas. Recently, some researchers have abandoned this size-based classification and emphasized the use of biological behavior to classify these lesions. Raskas et al<sup>12</sup> suggested that all lesions with neural and soft tissue involvement should be called osteoblastomas regardless of its size.

### Treatment

Benign vertebral tumors often do not require surgical treatment.<sup>10</sup> Many are reduced to incidental findings on radiological exams, and when they are asymptomatic and not suspected of malignant or aggressive behavior, they can be followed up periodically to ensure that progression does not occur.<sup>7</sup>

Medical treatment of osteoid osteoma pain involves NSAIDs or AASs, especially for nocturnal pain. As the pain becomes more intense and less responsive to medication, surgery becomes the treatment of choice, and complete resection is usually curative.<sup>2,10</sup> Thus, its surgical indications



**Figure 5.** Intraoperative endoscopic images. (A) Initial image of the extraforaminal access, with view of the lateral border of the pedicle and the lower part of the foramen T10/T11 on the right. (B) Beginning of foraminoplasty and bone resection of the T11 upper right joint process using a foraminoplasty burr. (C) Macroscopic aspect of pathological bone tissue. (D) Lateral image of the central canal and the right T11 pedicle partially resected.

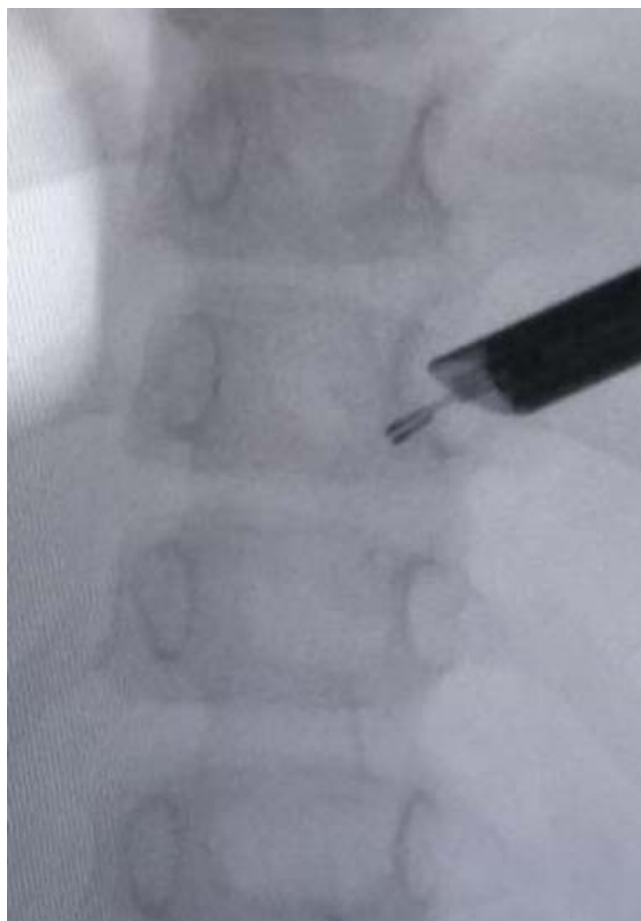are similar to those of other primary spinal tumors and include pain, deformity, tumor growth, diagnostic doubt, and complete oncologic treatment.<sup>2</sup>

Macrototal resection is the basis for surgical treatment of benign bone tumors. Surgical approaches and removal of these tumors from the spine, unlike the appendicular skeleton, are technically challenging.<sup>10</sup> Standard posterior approaches are usually used to resect spinous processes, laminae, pedicles, and facets. Posterior instrumentation is performed (usually simultaneously) when spinal instability occurs as a result of tumor destruction or extensive surgical resection of facets and pedicles. Most researchers suggest that 20%–50% of patients require simultaneous fusion, as

determined by the surgeon, based on intraoperative stability after resection.<sup>2,10</sup> However, conventional surgery without clear previous instability or neurological deficit is quite invasive and can cause morbidities, including the need for rehabilitation and prolonged absence from physical/work activities.<sup>13,14</sup>

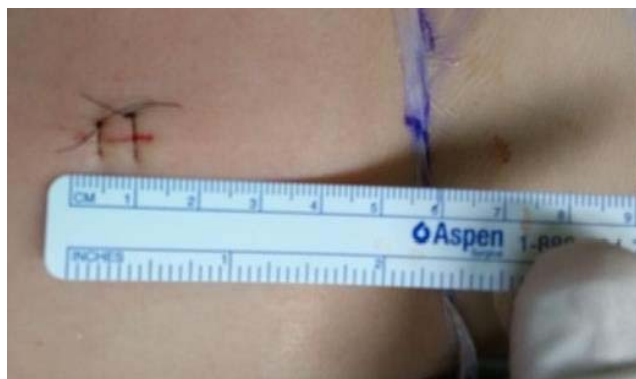Although widely described for treatment of malignant spinal injuries, radiotherapy for benign lesions can guarantee only delayed and transient relief and may represent a potential risk to adjacent neuronal structures; therefore, it is not recommended.<sup>14</sup>

Some percutaneous procedures are minimally invasive and guided by imaging, such as vertebro-



**Figure 6.** The conclusion of bone resection. Keeping the inferior cortical bone of the right T11 pedicle intact, local hemostasis, and bipolar cauterization of all beds and residual trabecular tissue are reviewed.

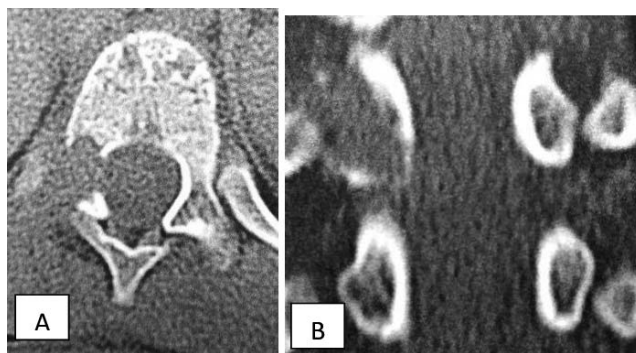
plasty or kyphoplasty, cryoablation, laser ablation, microwave ablation, and alcohol ablation. Vertebroplasty or kyphoplasty encompasses several techniques for internal stabilization of the vertebral body with bone cement. It is more specifically intended for injuries that cause collapse or compressive (axial) fracture of the vertebra.<sup>14,15</sup> Cryoablation uses a liquid gas, usually argon, to quickly cool the tip of the cryogenic probe. The formation of extracellular ice results in a relative imbalance of solutes between the intra- and extracellular environment, subsequent intracellular water extraction by osmosis, and cellular dehydration. Increases in intracellular concentration of solutes result in damage to both the cell's enzymatic machinery and the cell membrane.<sup>16,17</sup> Laser ablation uses optical fibers to transmit energy from infrared light to the tumor, producing rapid temperature rise, protein denaturation, and coagulative necrosis.<sup>18</sup> Microwave ablation uses probes to provide electro-



**Figure 7.** An 8-mm skin incision is made ~50 mm lateral to the midline at the height of the right T10/T11.

magnetic microwaves to the tissue, resulting in agitation of ionic molecules and frictional heat and, subsequently, coagulative tissue necrosis.<sup>14</sup> Alcohol ablation is a relatively inexpensive percutaneous tumor ablation technique that causes tumor necrosis directly through cell dehydration and indirectly through vascular thrombosis and tissue ischemia.<sup>14</sup> However, such percutaneous techniques have restrictions, such as patients with spinal instability with or without concomitant pathological fracture, focal neurological deficit, advanced coagulopathy, and systemic infection.

Previous reports on minimally invasive treatments have focused on image-guided percutaneous radio-frequency ablation.<sup>16,19</sup> However, this technique has several limitations. As it is usually performed using fluoroscopy guidance, a lack of direct visualization of the operative field can lead to incorrect displacement of the radio-frequency electrode and increase the risk of inadvertent damage to nearby neural or vascular structures. Furthermore, it is not possible to remove lesions located inside the



**Figure 8.** Imaging at the first year. (A) Axial spine computed tomography and (B) coronal spine computed tomography, without radiological signs of lesion recurrence.

vertebral canal or in the neural foramen using radio-frequency ablation.<sup>19</sup>

With technological developments, new surgical modalities have emerged that seek to solve the limitations of these procedures. Microendoscopic surgery of the spine requires knowledge of deep anatomical structures, meticulous preoperative planning, and a considerable learning curve. This procedure has the following advantages: small skin incision, shorter hospitalization, less rehabilitation, preserved facet and pedicle, no need for fusion, and clear macroscopic visualization of small tumors. Additionally, a single view through an oblique lens (30°) helps identify the orientation of the nerve root, pedicle, and tumor. There are previous descriptions of assisted video procedures (using a microsurgical approach, usually using tubular retractors and a video system similar to that used in arthroscopies), which facilitate less muscle and soft tissue damage and direct visualization of nervous structures and the tumor itself in some cases. However, with the use of conventional surgical materials, it has accessibility limitations for more central or anterior lesions in the vertebral body.<sup>20</sup>

Finally, endoscopy or full-endoscopic surgery of the spine, as reported in this article, represents the newest and perhaps the most promising treatment for resection of injuries of this type. The percutaneous endoscopic technique is already widely used for degenerative spinal diseases such as disk herniation, stenosis, and facet cysts.<sup>1</sup>

In the literature, the use of the full-endoscopic technique has been reported by Joo et al<sup>4</sup> since 2012, although in this report its use was aimed at the treatment of neuropathic pain by decompression of nervous structures compressed by an expansive metastatic lesion and not exactly the treatment of the underlying disease. After that, some other reported cases of biopsy and decompression of metastatic lesions of the spine were performed by transforaminal endoscopic access.<sup>4,21,22</sup> In 2015, Yoshioka et al<sup>20</sup> demonstrated for the first time the possibility of complete resection of a lesion in lumbar spine with a microendoscopic (endoscopic-assisted) approach. In the same year, Telfeian et al<sup>23</sup> published the first case of resection of an epidural tumor (Ewings sarcoma) resected by full-endoscopic thoracic access with foraminoplasty.

Since then, endoscopy has shown good results and total resection of benign spinal lesions (such as osteoid osteomas), allowing good control of symp-

toms from the immediate postoperative period, shorter hospital stays, faster recovery, and the guarantee of very satisfactory periods in disease-free patients, as in the case series described by Tianhang et al. They showed excellent immediate and 3-year follow-up results in 11 patients with benign lesions of the lumbar and sacrum spine resected using a purely endoscopic technique.<sup>1</sup> Xu et al reported that 81.3% (13/16 patients) of patients needed internal fixation after conventional open surgical resection to treat lesions such as osteoid osteoma.<sup>1</sup> Nasir et al reported the need for fusion in only 24% of cases (20/84 patients); however, the recurrence rate was 7% with fragmented intraleisional resection (as in microsurgical or microendoscopic techniques).<sup>1</sup> Georgia et al treated this type of lesion with photocoagulation and percutaneous laser ablation and found that only 29.8% (17/57) of patients underwent bone biopsy after ablation and that 29.4% (5/17) did not obtain a definitive pathological diagnosis due to insufficient samples.<sup>24</sup> The full-endoscopic technique allows good protection and preservation of adjacent structures such as muscle tissue and nerve roots, does not compromise spinal stability, allows good resection of the nidus, and, if associated with the use of radio-frequency probes, allows cauterization of neovascularization and tumor damage, preventing or limiting its recurrence. Thus, it is becoming the preferred method in terms of both therapeutic effectiveness and medical costs.

It is important to remember, however, that in general (whatever the technique of choice), the results of surgical treatment for osteoid osteoma are satisfactory. Complete pain relief was achieved in more than 90% of patients in most of the reported series.<sup>25</sup> Pain relief usually occurs early in the postoperative period (a few hours or days after surgery). The majority (70%–90%) of patients with preoperative scoliosis evolved satisfactorily.<sup>26</sup> Moreover, for good results with endoscopic techniques, experience and skill are required, which are achieved only with training and a considerable learning curve.<sup>27–29</sup>

## CONCLUSION

In conclusion, we report the first case of full-endoscopic resection of an osteoid osteoma in the thoracic vertebra. This is an effective, cost-effective, minimally invasive technique for complete resection of the lesion. It allows collection of samples for an



anatomopathological exam to facilitate a more accurate diagnosis and optimal adjuvant follow-up. It has also been shown to be effective in controlling the disease after 1 year.

Although it is very promising, further studies are needed with larger samples and longer postoperative follow-up to compare this endoscopic technique with other therapeutic options for treatment of benign tumors of the spine, such as osteoid osteoma.

## REFERENCES

- Xie T, Xiu P, Song Y, Zeng J, Huang S. Percutaneous endoscopic excision and ablation of osteoid osteoma of the lumbar spine and sacrum: a technical note and outcomes. *World Neurosurg.* <https://doi.org/10.1016/j.wneu.2019.09.039>
- Ropper AE, Cahill KS, Hanna JW, McCarthy EF, Gokaslan ZL, Chi JH. Primary vertebral tumors: a review of epidemiologic, histologic, and imaging findings, part I: benign tumors. *Neurosurgery.* 2011;69(6):1171–1180.
- Azouz EM, Kozlowski K, Marton D, et al. Osteoid osteoma and osteoblastoma of the spine in children. Report of 22 cases with brief literature review. *Pediatr Radiol.* 1986;16(1):25–31.
- Joo YC, Ok WK, Baik SH, Kim HJ, Kwon OS, Kim KH. Removal of a vertebral metastatic tumor compressing the spinal nerve roots via a single-port, transforaminal, endoscopic approach under monitored anesthesia care. *Pain Physician.* 2012;15(4):297–302.
- Kelley SP, Ashford RU, Rao AS, et al. Primary bone tumors of the spine: a 42-year survey from the Leeds Regional Bone Tumour Registry. *Eur Spine J.* 2007;16(3):405–409.
- Barlow E, Davies AM, Cool WP, Barlow D, Mangham DC. Osteoid osteoma and osteoblastoma: novel histological and immunohistochemical observations as evidence for a single entity. *J Clin Pathol.* 2013;66(9):768–774.
- Pourfeizi HH, Tabrizi A, Bazavar MR, Sales JG. Clinical findings and results of surgical resection of toracolumbar osteoid osteoma. *Asian Spine J.* 2014;8(2):150–155.
- Lichtenstein L. Benign osteoblastoma: a category of osteoid-and bone-forming tumors other than classical osteoid-osteoma, which may be mistaken for giant-cell tumor or osteogenic sarcoma. *Cancer.* 1956;9(5):1044–1045.
- Jackson RP, Reckling FW, Mants FA. Osteoid osteoma and osteoblastoma. Similar histologic lesions with different natural histories. *Clin Orthop Relat Res.* 1977(128):303–313.
- Kan P, Schmidt MH. Osteoid osteoma and osteoblastoma of the spine. *Neurosurg Clin North Am.* 2008;19(1):65–70.
- McLeod RA, Dahlin DC, Beabout JW. The spectrum of osteoblastoma. *AJR Am J Roentgenol.* 1976;126(2):321–325.
- Raskas DS, Graziano GP, Herzenberg JE, et al. Osteoid osteoma and osteoblastoma of the spine. *J Spinal Disord.* 1992;5(2):204–11.
- Jiang L, Liu XG, Yuan HS, et al. Diagnosis and treatment of vertebral hemangiomas with neurologic deficit: a report of 29 cases and literature review. *Spine J.* 2014;14(6):944–954.
- Tomasian A, Wallace AN, Jennings JW. Benign spine lesions: advances in techniques for minimally invasive percutaneous treatment. *Am J Neuroradiol.* 2017;38(5):852–861.
- Wardlaw D, Cummings SR, Van Meirhaeghe J, et al. Efficacy and safety of balloon kyphoplasty compared with non-surgical care for vertebral compression fracture: a randomised controlled trial. *Lancet.* 2009;373(9668):1016–1024.
- Rybak L. Fire and ice: thermal ablation of musculoskeletal tumors. *Radiol Clin North Am.* 2009;47(3):455–469.
- Gage AA, Baust JG. Cryosurgery for tumors. *J Am Coll Surg.* 2007;205(2):342–356.
- Koch G, Cazzato RL, Gilkison A, Caudrelier J, Garnon J, Gangi A. Percutaneous treatments of benign bone tumors. *Semin Intervent Radiol.* 2018;35(4). <https://doi.org/10.1055/s-0038-1673640>
- Regev GJ, Salame K, Keynan O, Lidar Z. Resection of benign vertebral tumors by minimally invasive techniques. *Spine J.* 2015;15(11):2396–2403. <http://dx.doi.org/10.1016/j.spinee.2015.07.002>
- Yoshioka K, Matsuda E, Murakami H, Tsuchiya H. Microendoscopic excision of osteoid osteoma in the pedicle of the third lumbar vertebra. *Asian Spine J.* 2015;9(6):958–961.
- Henderson F Jr, Hubbard ZS, Jones S, Barley J, Frankel B. Endoscopic decompression of epidural spinal metastasis causing lumbar radiculopathy through a transforaminal approach: report of two cases. *AME Case Rep.* 2020;4:2. <http://dx.doi.org/10.21037/acr.2019.12.02>
- Konakondla S, Sofoluke N, Xia J, et al. Transforaminal endoscopic approach for large-sample tumor biopsy using beveled working channel for core technique: a technical note. *World Neurosurg.* 2020. <https://doi.org/10.1016/j.wneu.2020.05.096>
- Telfeian AE, Choi DB, Aghion DM. Transforaminal endoscopic surgery under local analgesia for ventral epidural thoracic spinal tumor: case report. *Clin Neurol Neurosurg.* 2015;134:1–3.
- Tsoumakidou G, Thenint MA, Garnon J, Buy X, Steib JP, Gangi A. Percutaneous image-guided laser photocoagulation of spinal osteoid osteoma: a single-institution series. *Radiology.* 2016;278(3):936–943.
- Kirwan EO, Hutton PA, Pozo JL, Ransford AO. Osteoid osteoma and benign osteoblastoma of the spine. Clinical presentation and treatment. *J Bone Jt Surg Br.* 1984;66(1):21–26.
- Pettine KA, Klassen RA. Osteoid-osteoma and osteoblastoma of the spine. *J Bone Jt Surg Am.* 1986;68(3):354–61.
- Ransom NA, Gollogly S, Lewandrowski KU, Yeung A. Navigating the learning curve of spinal endoscopy as an established traditionally trained spine surgeon. *J Spine Surg.* 2020;6(suppl 1):S197–S207. doi:10.21037/jss.2019.10.03. PMID: 32195428
- Asano LYJ, Bergamaschi JPM, Dowling Á, Rodrigues LMR. Transforaminal endoscopic lumbar discectomy: clinical outcomes and complications. *Rev Bras Ortop.* 2020;55(01):048–053.
- Asano LYJ, Bisson G, Gianuzzi D, Dowling Á, Rodrigues LMR. Lumbar endoscopic discectomy in obese patients. *Coluna|Columna.* 2019;18(3):222–225.

**Ethical Statement:** The authors are accountable for all aspects of the work in ensuring that questions related to the accuracy or integrity of any part of the work are appropriately investigated and resolved. Written informed consent was obtained

from the parents of the patient for publication of this case report and any accompanying images. A copy of the written consent is available for review by the Editor-in-Chief of this journal.

**Disclosures and COI:** The authors declare no conflicts of interest.

**Corresponding Author:** João Paulo M. Bergamaschi, Alameda Santos, 745–CJ 71 Cerqueira

Cesar, São Paulo 014019-001, Brazil. Phone: +55 11 3567-4299; Email: [jberga@clinicaatualli.com.br](mailto:jberga@clinicaatualli.com.br).

Published 11 February 2021

This manuscript is generously published free of charge by ISASS, the International Society for the Advancement of Spine Surgery. Copyright © 2020 ISASS. To see more or order reprints or permissions, see <http://ijssurgery.com>.