

## Traumatic Bilateral L3-4 Facet Dislocation With Open Decompression and Short Segment Fusion

Andrew Y. Liu and Emmanuel N. Menga

*Int J Spine Surg* 2021, 14 (s4) S21-S25

doi: <https://doi.org/10.14444/7160>

<https://www.ijssurgery.com/content/14/s4/S21>

This information is current as of June 11, 2025.

---

**Email Alerts** Receive free email-alerts when new articles cite this article. Sign up at:  
<http://ijssurgery.com/alerts>

# Traumatic Bilateral L3-4 Facet Dislocation With Open Decompression and Short Segment Fusion

ANDREW Y. LIU, MD, EMMANUEL N. MENGA, MD

*Department of Orthopaedics & Rehabilitation, University of Rochester Medical Center, Rochester, New York*

## ABSTRACT

Traumatic lumbar facet dislocations are exceedingly rare, with reported cases primarily involving the lumbosacral junction. This injury arises from very high flexion distraction forces imparted on the lumbar spine. Herein we describe a bilateral L3-4 facet dislocation, a particularly rare injury pattern, using a short-segment posterior decompression and fusion followed by an interbody fusion through a lateral approach. Our case involves a 24-year-old man who presented to the emergency department after a high-speed, head-on motor vehicle collision. He was a restrained passenger with no prior significant medical history. He was found to have multisystem injuries, the most notable a L3-4 bilateral lumbar facet dislocation. The patient was neurologically intact upon his presentation but developed radiculopathy several hours into his hospital admission. He was treated operatively through a posterior decompression and instrumented short-segment fusion as well as a subsequent interbody fusion through a lateral approach at the same level. Pure lumbar spine facet dislocations outside the lumbosacral junction, especially bilateral dislocations, are exceedingly rare and often result in neurological deficits. A literature review reveals only a few cases outside of Asia, all of which were treated with decompression and either short- or long-segment fusion. No accepted treatment algorithm for this injury has been established. Open treatment is almost always indicated. Decompression and short-segment fusion is a valid treatment option, but patient and injury characteristics must be considered on an individualized basis.

Level of Evidence: 5.

## Lumbar Spine

Keywords: lumbosacral traumatic dislocation, traumatic lumbosacral spondylolisthesis, posterolateral fusion, posterolateral osteosynthesis

## INTRODUCTION

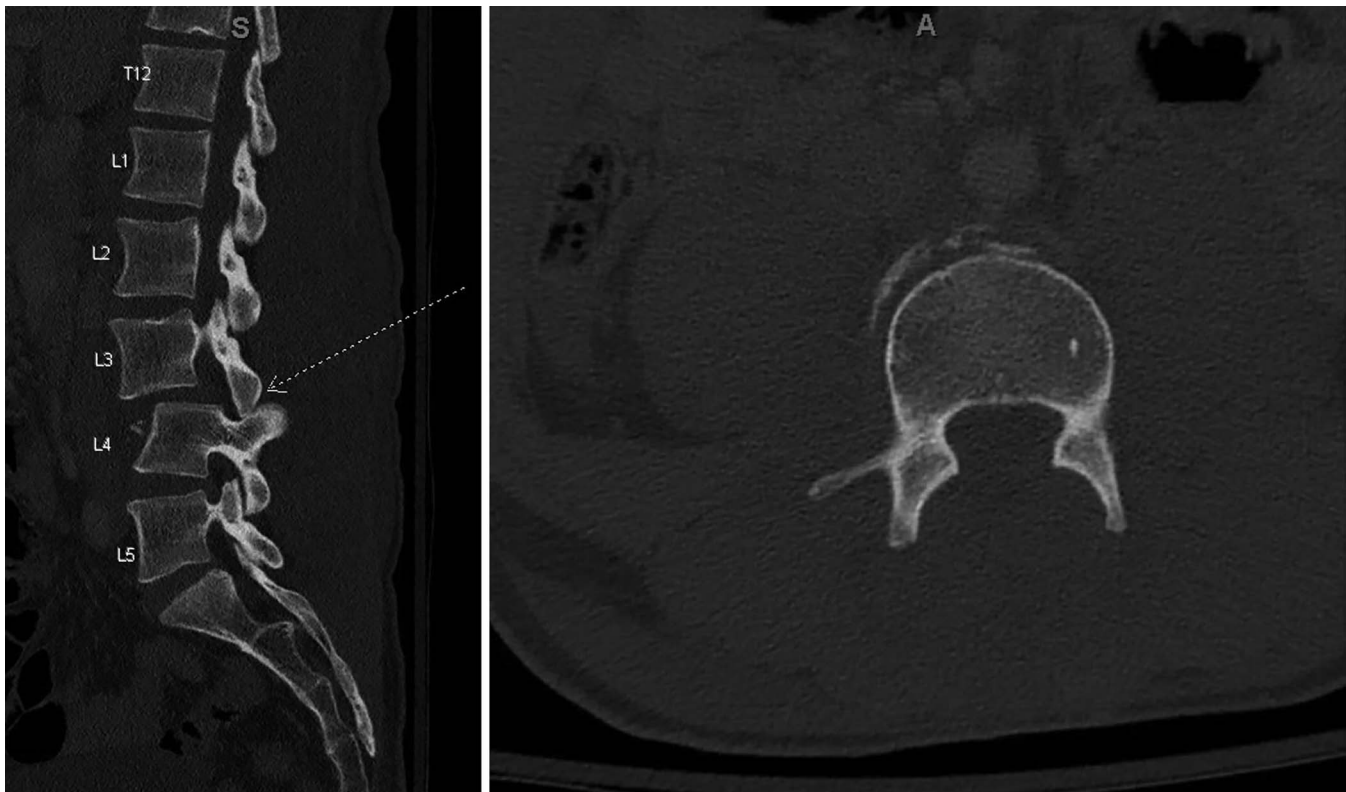Traumatic lumbar facet dislocation, especially bilateral facet dislocation, is exceedingly rare, with few cases described in the literature. Spinal dislocations generally occur in the cervical spine, given the more sagittal orientation of the facet joints.<sup>1</sup> Few reported cases have been described, and those that were typically involved the lumbosacral junction.<sup>2,3</sup> These injuries typically occur in younger patients as a result of flexion distraction forces on the spine and are associated with multisystem injuries.<sup>4</sup> We describe the presentation and management of a patient with bilateral lumbar facet dislocation with severe radiculopathy treated by using a posterior surgical decompression with short segmental reduction with instrumented fusion followed by an anterior interbody fusion through a lateral approach. We also review the literature on isolated traumatic lumbar facet dislocations.

## CASE REPORT

### Clinical Presentation

A 24-year-old man was admitted to our level 1 trauma center following a head-on motor vehicle collision that occurred at approximately 40 mph. The patient was wearing a seat belt at the time of the accident, and his airbags did deploy. The patient was able to extricate himself from his vehicle. On initial evaluation, Advanced Trauma Life Support principles were followed, and he remained hemodynamically stable with unremarkable primary survey. His Glasgow Coma Scale score was 15 on arrival.

On secondary survey, the patient reported low back pain with accompanying lumbar spine tenderness, but remained neurologically intact with American Spinal Injury Association Grade E. He also reported left hip pain, left shoulder pain, right great toe pain, right hand pain, and abdominal pain without rebound tenderness.



**Figure 1.** (Left) Bilateral jumped facets at L3-4 seen on injury computer tomography (CT) of lumbar spine. (Right) Axial cut at L3-4 showing empty facet sign.

Computed tomography (CT) scan of the cervical, thoracic, and lumbar spine obtained for trauma evaluation demonstrated fracture dislocation at L3-4 with bilateral jumped facets of L3 on L4 in addition to L4 compression fracture and left L2-3 transverse process fractures (Figure 1). An MRI of the lumbar spine demonstrated severe canal stenosis at the L3-4 level with L3-4 epidural hematoma (Figure 2). Imaging and examination also demonstrated a right great toe fracture dislocation, bilateral pneumothoraces, and evidence of abdominal contusion.

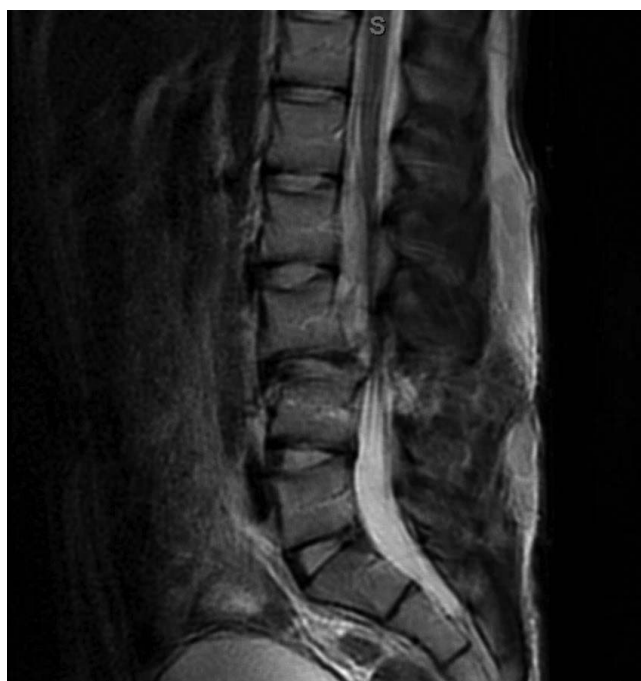Although initially neurologically intact, approximately 2 hours into his admission, the patient began experiencing severe low back pain, severe bilateral lower extremity radiating pain, and paresthesias with intact/preserved motor function. He also complained of increased abdominal pain during this time, and further work-up revealed a right colonic mesenteric injury. Given the unstable nature of his spinal injury in addition to rapidly progressing radiculopathy, urgent spinal surgical intervention was recommended including an L3-4 fracture reduction, L3-4 decompression, and posterior instrumented fusion. Due to his mesenteric injury and imaging concern for intra-abdominal bleeding, a

decision was made in conjunction with the acute trauma service to proceed with emergency exploratory laparoscopy prior to proceeding with spinal surgical decompression and stabilization.

### Operative Procedure

Standard posterior midline approach to the lumbar spine was performed. Notable during exposure was complete traumatic disruption of the fascial layer, the muscle layers, and the interspinous ligament between the L3 and L4 levels with an accompanying step-off at the L3-4 level. Rotational deformity of the L3 and L4 spinous processes was present, with right-sided rotation and right-sided translation of the L4 vertebral body. Meticulous exposure was performed with resection of damaged fascia and muscle, avoiding neural injury. After completion of exposure, traumatic disruption of the left L3-4 interspinous ligament was also identified with direct visualization of the exiting left L3 nerve root, which was intact.

Next, bilateral pedicle screws were placed at L3 and L4. Laminectomies at both levels were performed, given the severe central canal stenosis at the L3-4 level from the right-sided rotation and translation of the L4 vertebral body, causing



**Figure 2.** T2-weighted sagittal reconstruction of lumbar spine MRI demonstrating epidural hematoma.

traction and compression of the left L3 nerve root. Due to persistent traction and compression despite laminectomies, further decompression was performed with bilateral facetectomies and neuroforaminotomies for complete decompression of the bilateral L3 nerve roots.

In efforts to correct the rotational and translational deformity of the injured segment, rods were bent to a lordotic sagittal alignment to help with correction of the spinal deformity. A rod was placed on the left side between the L3 and L4 screw while at the same time holding the spinous process at the L2 level to translate and rotate the vertebral body to gain realignment of the vertebral bodies. After placement of the rod over the left side, the right-sided rod was placed, followed by assurance of satisfactory alignment using fluoroscopy.

Due to extensive muscle and fascia and intertransverse process ligament disruption at the left L3-4 posterolateral gutter, the left L3 nerve root was exposed with no room for placement of a bone graft over the left L3-4 posterolateral gutter for posterior fusion. Local lamina, spinous process, and facet joint autograft was, however, placed over the right L3-4 posterolateral gutter for posterior spinal fusion after decortication of the right L3 and L4 transverse processes. A decision was made to complete the fusion through an anterior approach with a left L3-4 direct lateral interbody fusion technique at a later

date, given the extent of soft tissue disruption posteriorly at the injured level, focus on damage control orthopedics, and concern regarding the patient's abdominal and pulmonary injuries.

Five days after initial fracture decompression and instrumented stabilization, the patient was taken to the operating room so surgeons could perform anterior L3-4 fusion through a left L3-4 direct lateral interbody fusion technique to reduce the risk for pseudoarthrosis, given resection of bilateral facet joints at L3-4 and limited posterior fusion bed for posterolateral fusion at the L3-4 level. Following excision of the L3-4 disc, an appropriately sized cage was inserted. The cage was then packed with allograft and bone morphogenic protein and packed into place (Figure 3).

### Postoperative Course and Follow-Up

The patient's immediate postoperative course was unremarkable. He reported some residual left anterior thigh numbness likely related to his trauma. He was discharged home on postoperative day 5.

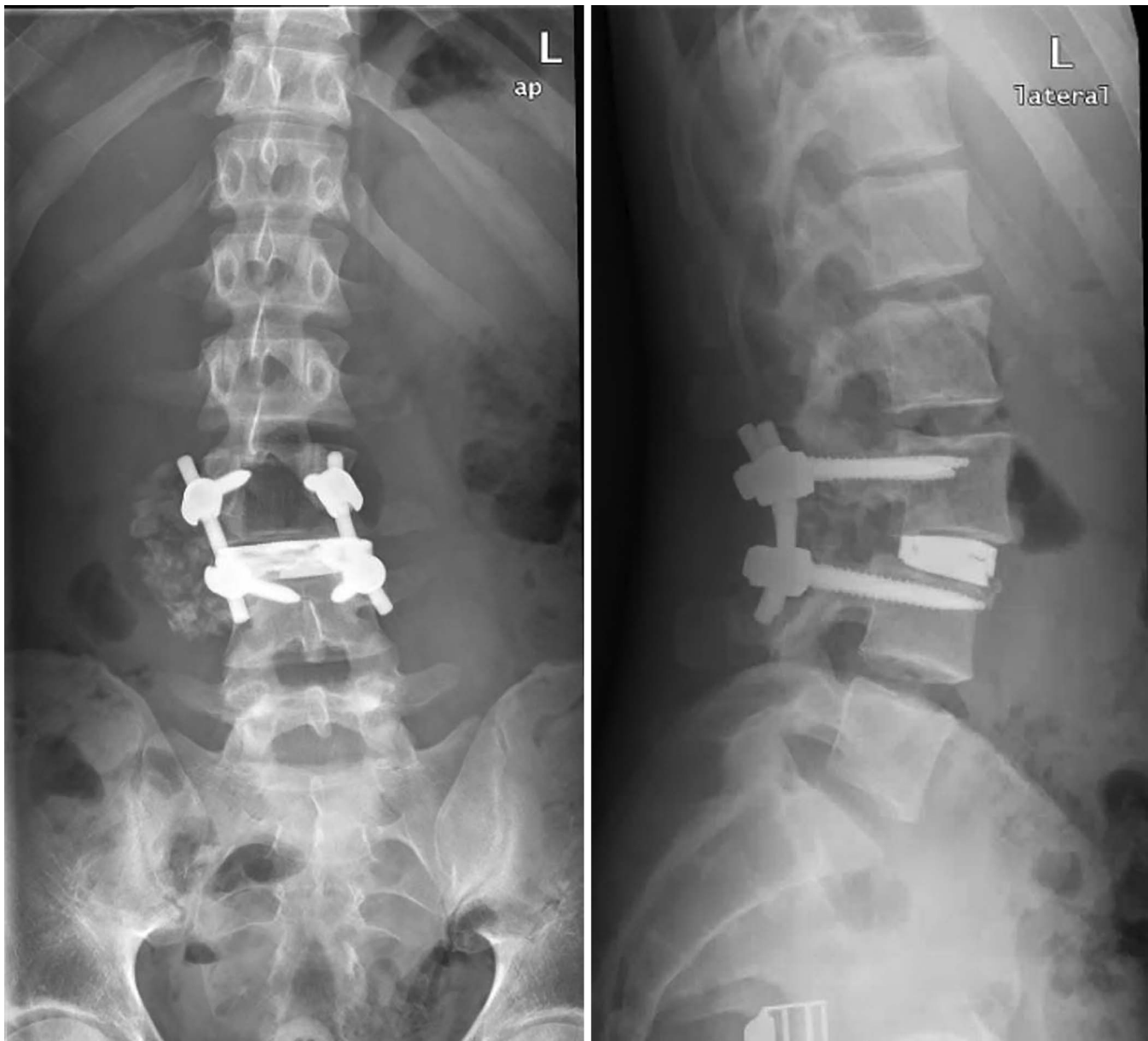
During his 2-month postoperative clinic visit, the patient reported complete resolution of his bilateral radicular leg pain and demonstrated full sensory and motor function on his physical exam. He continued to do well at his 3.5-month visit, with only occasional right-sided lower back pain. His last clinic radiographs revealed reasonable coronal and sagittal alignment with a stable L3-4 fusion construct with no signs of loosening or cage migration.

## DISCUSSION

Lumbar facet dislocations are rarely seen relative to cervical facet dislocations. A combination of the more sagittal alignment of the lumbar facet joints, larger vertebral bodies, and surrounding paraspinal musculature means that a very large flexion distraction force is required to separate the lumbar facet joints.<sup>5</sup> In our case, a high-speed, off-center frontal collision generated the distractive and rotational forces necessary to explain the injury of a seat-belted passenger.

Many cases of facet dislocations at the lumbosacral junction have been described, but generally with associated fractures.<sup>6-9</sup> The lumbosacral junction is likely more frequently involved because of the more coronal alignment of the facet joints and because of increased sagittal motion at the caudal end of the lumbar spine. Facet dislocations at other levels





**Figure 3.** Final construct showing 3-column fusion construct at L3-4.

within the lumbar spine are much less commonly seen, with several total reported cases found in the literature.<sup>6,10,11,15</sup> Bilateral lumbar facet dislocations are rare, with a few total cases described.<sup>12–15</sup> There is only one other reported case of a pure bilateral dislocation outside the lumbosacral junction in an adult.<sup>4</sup> Common to these injuries are the mechanism of a high-speed motor vehicle accident, associated multisystem injuries, including abdominal solid organ and hollow viscus injuries, and prevalence of neurological deficits (more common in bilateral facet dislocations<sup>3</sup>).

Given the rarity of lumbar facet dislocations, no established treatment guidelines have been formulated. The majority of case reports have used open facet reduction and short segment instrumented fixation as the treatment of choice. However, both short- (two-level) and long-segment fusion constructs have been described for this injury, with no clear difference in outcomes. In our case, a short-segment posterior instrumented fusion, including interbody fusion, was performed. Despite a good clinical outcome, the coronal alignment at L3-4 could perhaps have been improved with a longer fusion construct. The benefits of using a longer

construct must be weighed against the risks of prolonged surgical time and more extensive soft tissue dissection, especially in the context of associated injuries and significant soft tissue injury. Treatment strategy should be determined according to both patient and injury characteristics.

## REFERENCES

1. Anissipour AK, Agel J, Baron M, Magnusson E, Bellabarba C, Bransford RJ. Traumatic cervical unilateral and bilateral facet dislocations treated with anterior cervical discectomy and fusion has a low failure rate. *Global Spine J*. 2017;7(2):110–115.
2. Cho N, Alkins R, Khan OH, Ginsberg H, Cusimano MD. Unilateral lumbar facet dislocation: case report and review of the literature. *World Neurosurg*. 2019;123:310–316.
3. Grivas TB, Papadakis SA, Katsiva V, Koufopoulos G, Mouzakis V. Unilateral lumbosacral dislocation: case report and a comprehensive review. *Open Orthop J*. 2012;6:473–477.
4. Im SH, Lee KY, Bong HJ, Park YS, Kim JT. Bilateral locked facets at lower lumbar spine without facet fracture: a case report. *Korean J Spine*. 2012;9(3):278–280.
5. Moon AS, Atesok K, Niemeier TE, Manoharan SR, Pittman JL, Theiss SM. Traumatic lumbosacral dislocation: current concepts in diagnosis and management. *Adv Orthop*. 2018;2018:6578097. doi:10.1155/2018/6578097
6. Mori K, Hukuda S, Katsuura A, Saruhashi Y, Asajima S. Traumatic bilateral locked facet at L4-5: report of a case associated with incorrect use of a three-point seatbelt. *Eur Spine J*. 2002;11(6):602–605.
7. Park HY, Ha KY, Kim YH, et al. Delayed bilateral facet dislocation at L4-5: a case report. *Medicine (Baltimore)*. 2018;97(38):e12483. doi:10.1097/MD.00000000000012483
8. Ra IH, Min WK. Traumatic bilateral facet dislocation of lumbar spine: “double facet sign.” *Spine J*. 2013;13(11):1705–1707.
9. Rhea E, Rahmathulla G. Traumatic unilateral L3-4 jumped facet treated with open reduction and short segment fusion. *World Neurosurg*. 2018;119:103–107.
10. Schiedo RM, Lavelle W, Ordway NR, Rustagi T, Sun MH. Purely ligamentous flexion-distraction injury in a five-year-old child treated with surgical management. *Cureus*. 2017;9(4):e1130. doi:10.7759/cureus.1130
11. Song KJ, Lee KB. Bilateral facet dislocation on L4-L5 without neurologic deficit. *J Spinal Disord Tech*. 2005;18(5):462–464.
12. Vialle R, Wolff S, Pauthier F, et al. Traumatic lumbosacral dislocation: four cases and review of literature. *Clin Orthop Relat Res*. 2004;(419):91–97.
13. Xu R, Solakoglu C, Kretzer RM, McGirt MJ, Witham TF, Bydon A. Bilateral traumatic dislocation without fracture of the lumbosacral junction: case report and review of the literature. *Spine (Phila Pa 1976)*. 2011;36(10):E662–E668.
14. Zarrouk A, Kamoun K, Karray M, Rajhi H, Zlitni M. Traumatic lumbosacral fracture dislocation: a case report and review of the literature. *Rev Chir Orthop Reparatrice Appar Mot*. 2007;93(7):730–735.
15. Zenonos GA, Agarwal N, Monaco EA 3rd, Okonkwo DO, Kanter AS. Traumatic L4-5 bilateral locked facet joints. *Eur Spine J*. 2016;25(suppl 1):129–133.

**Disclosures and COI:** The authors received no funding for this study and report no conflicts of interest.

**Corresponding Author:** Andrew Y. Liu, MD, University of Rochester Medical Center, Department of Orthopaedics & Rehabilitation, Building D, 4901 Lac De Ville Blvd, Rochester, NY 14618. Phone: (215) 595-3130; Email: Andrew\_Liu@URMC.Rochester.edu.

Published 11 February 2021

This manuscript is generously published free of charge by ISASS, the International Society for the Advancement of Spine Surgery. Copyright © 2020 ISASS. To see more or order reprints or permissions, see <http://ijssurgery.com>.