

Percutaneous Lumbar Interbody Fusion With an Expandable Titanium Cage Through Kambin's Triangle: A Case Series With Initial Clinical and Radiographic Results

Timothy Y. Wang, Vikram A. Mehta, Mostafa Gabr, Eric W. Sankey, Alexia Bwensa, C. Rory Goodwin, Isaac O. Karikari, John H. Chi and Muhammad M. Abd-El-Barr

Int J Spine Surg 2021, 15 (6) 1133-1141

doi: <https://doi.org/10.14444/8144>

<https://www.ijssurgery.com/content/15/6/1133>

This information is current as of May 17, 2025.

Email Alerts Receive free email-alerts when new articles cite this article. Sign up at:
<http://ijssurgery.com/alerts>

Percutaneous Lumbar Interbody Fusion With an Expandable Titanium Cage Through Kambin's Triangle: A Case Series With Initial Clinical and Radiographic Results

TIMOTHY Y. WANG, MD¹; VIKRAM A. MEHTA, MD, MPH¹; MOSTAFA GABR, MD¹; ERIC W. SANKEY, MD¹; ALEXIA BWENSA, BA¹; C. RORY GOODWIN, MD, PHD¹; ISAAC O. KARIKARI, MD¹; JOHN H. CHI, MD, MPH²; AND MUHAMMAD M. ABD-EL-BARR, MD, PHD¹

¹Department of Neurosurgery, Division of Spine, Duke University Medical Center, Durham, North Carolina, 27701, USA; ²Department of Neurosurgery, Brigham and Women's Hospital, Harvard Medical School, Boston, Massachusetts, 02115, USA

ABSTRACT

Background: There has been an increased interest in lumbar interbody fusions through Kambin's triangle. In this study, we describe percutaneous access to the lumbar disc and insertion of an expandable titanium cage through Kambin's triangle without facetectomy. The objective of this study is to determine the feasibility as well as clinical and radiographical outcomes of completely percutaneous lumbar interbody fusion (perCLIF) using an expandable titanium cage through Kambin's triangle.

Methods: A retrospective review of patients undergoing single-level perCLIF for grade 1 lumbar spondylolisthesis via Kambin's triangle using an expandable titanium cage was performed. Demographic information, Oswestry Disability Index (ODI), preoperative and postoperative radiographic factors, perioperative data, and complications were recorded. Fusion was assessed with 1-year postoperative computed tomography scan or lumbar spine x-ray and defined as bridging disc or posterolateral fusion without evidence of hardware fracture or perihardware lucency.

Results: A total of 16 patients (3 males) were included in this study. Spondylolisthesis, anterior disc height, and posterior disc height were significantly improved at 6 weeks, 6 months, and 12 months, postoperatively ($P < 0.05$). ODI was significantly improved by 24.4% at 12 months postoperatively ($P = 0.0036$). One patient was readmitted within 30 days for pain control but otherwise there were no complications including permanent neurological injury, infection, deep vein thrombosis, pulmonary embolism, or cardiac events. Fifteen (93.8%) patients had radiographic fusion at their 1-year postoperative imaging.

Conclusion: Our initial experiences have shown that perCLIF can be performed using an expandable titanium cage through Kambin's triangle with excellent radiographic and clinical results. In this series, perCLIF is a safe and clinically efficacious procedure for reducing grade 1 lumbar spondylolisthesis and improving radiculopathy. This procedure is completed percutaneously without the use of an endoscope.

Clinical Relevance: This study highlights improvements in outcomes of minimally invasive surgery.

Level of Evidence: IV.

Minimally Invasive Surgery

Keywords: expandable cage, Kambin's triangle, lumbar interbody fusion, minimally invasive surgery, percutaneous spinal fusion

INTRODUCTION

Low back pain is one of the costliest disabilities¹ and is commonly caused by degenerative disc disease and spondylolisthesis.^{2,3} The aging population has seen a concurrent rise in patients with low back pain. While conservative treatment is the initial approach to symptom management, there is a subset of patients who remain refractory to these measures and thus require surgical intervention. Fortunately, recent advancements in spine surgery have greatly expanded surgeons' ability to treat this disease.⁴

Lumbar interbody fusions are one such treatment option for degenerative disc disease and spondylolisthesis.⁵ Early techniques often required significant

tissue dissection and muscle disruption in order to expose traditional gross anatomical landmarks for the purpose of interbody placement and pedicle screw insertion. The rapid popularization of minimally invasive spine (MIS) surgery has obviated this need, and as a result, modern methods now rely more so on navigation and fluoroscopy and can accomplish anatomically similar surgeries through smaller incisions. Minimally invasive surgeries thus require less direct visualization of anatomical landmarks which reduces the need for muscle retraction and dissection—a common reason for postoperative pain, morbidity, blood loss, and increased length of stay.^{6–9} It is the minimization of this muscle retraction and dissection that defines the field of MIS surgery.

Percutaneous lumbar interbody fusion (perCLIF) is a new minimally invasive surgery that allows for interbody fusion. Unlike traditional transforaminal lumbar interbody fusion or posterior lumbar interbody fusion, perCLIF is performed through Kambin's triangle, defined as the exiting nerve root (hypotenuse), superior end plate of the caudal vertebral body (base), and thecal sac. This natural corridor allows for access to the disc space without the need for a facetectomy.¹⁰⁻¹³

Through Kambin's triangle, the surgeon can perform a thorough discectomy including disc removal, end plate preparation, and cage placement. There is minimal dissection of soft tissue and disruption of the posterior tension band, which may reduce patient pain and morbidity and iatrogenic instability. While there are several studies demonstrating feasibility of perCLIF, there are no high quality data on postoperatively patient-reported as well as radiographical outcomes.¹⁴ Work published in 2019 by Morgenstern and Morgenstern described the perCLIF. However, their technique utilized an endoscope to visualize the entry to the disc space.¹⁴ Additional existing literature has demonstrated the feasibility of static, non-expandable cages, and porous allograft-containing mesh.¹⁴⁻¹⁷ This is the first reported series demonstrating the feasibility and outcomes of patients with low-grade spondylolisthesis undergoing lumbar fusion through the perCLIF approach utilizing an expandable titanium cage.

METHODS

Study Design

The authors performed a single-center, single-surgeon retrospective review of prospectively collected data of patients with the following inclusion criteria: (1) adult patients age greater than or equal to 18 years, (2) undergoing single-level perCLIF via Kambin's triangle, (3) utilizing an expandable titanium cage interbody device for, (4) treatment of grade 1 spondylolisthesis from 1 July 2018 to 31 July 2019. In general, patients with severe central and foraminal stenosis were not included as it was felt that more direct decompression would be needed in these cases. Demographic information, comorbidities, preoperative and postoperative radiographic factors, perioperative data, and complications were recorded. Oswestry Disability Index (ODI), was obtained from the patient preoperatively, which served as the baseline, and postoperatively at 6 weeks, 6 months, and 12 months.

Standing lumbar x-rays were obtained at 6 weeks, 6 months, and 12 months postoperatively and taken with a radiodense ruler to serve as a reference for radiographic measurements. If available, postoperative computed tomography (CT) scans at the 1-year postoperative follow-up were also reviewed. From these, the anterior disc height, posterior disc height, and severity of spondylolisthesis were measured. Radiographic fusion was determined if there was bridging bone in either the disc space or presence of posterolateral fusion. Any presence of hardware fracture, screw migration, or perihardware lucency was deemed suggestive of pseudarthrosis and thus was considered "nonfused." Complications such as 30-day postoperative readmission, deep vein thrombosis, pulmonary embolism, new temporary or permanent weakness or neurological deficit, and infections were also recorded. Parametric data were expressed as means with standard deviation and compared with the Fisher's exact test. Categorical data were compared with the χ^2 test with $\alpha < 0.05$.

Surgical Technique

Each case was completed by a single, fellowship-trained, neurosurgical surgeon. The patient was brought into the operating room and intubated under general anesthesia. Inhaled anesthetics were not used as to not interfere with continuously free-running electromyography (EMG) readings. After intubation, a urethral catheter is placed and EMG monitoring needles are introduced into the lower extremities. The patient is then flipped prone on a Jackson table with the arms aimed 90° toward the head in the "Superman" position. The disc space was then identified with fluoroscopic guidance. A paramedian stab incision is made 10 to 11 cm from the midline. Continuous EMG signals were monitored to ensure no damage to neighboring nervous tissue. A blunt EMG probe is used to pierce the fascia and aimed at Kambin's triangle (Figure 1A). Continuous EMG was used, and if there was not firing at 5 mA when the disc was entered, this was considered a safe entry to the disc.

Dilators were subsequently introduced over the blunt EMG probe, and a working channel was docked just inside the annulus to protect surrounding structures (Figure 1B). Disc material was removed with the sequential use of pituitary rongeur, fan-blade shaver, articulating curette, and rotating metal-bristle brushes. Discectomy was confirmed by placing a balloon into the disc space and filling the balloon with radiopaque dye. The balloon and dye fill the contours

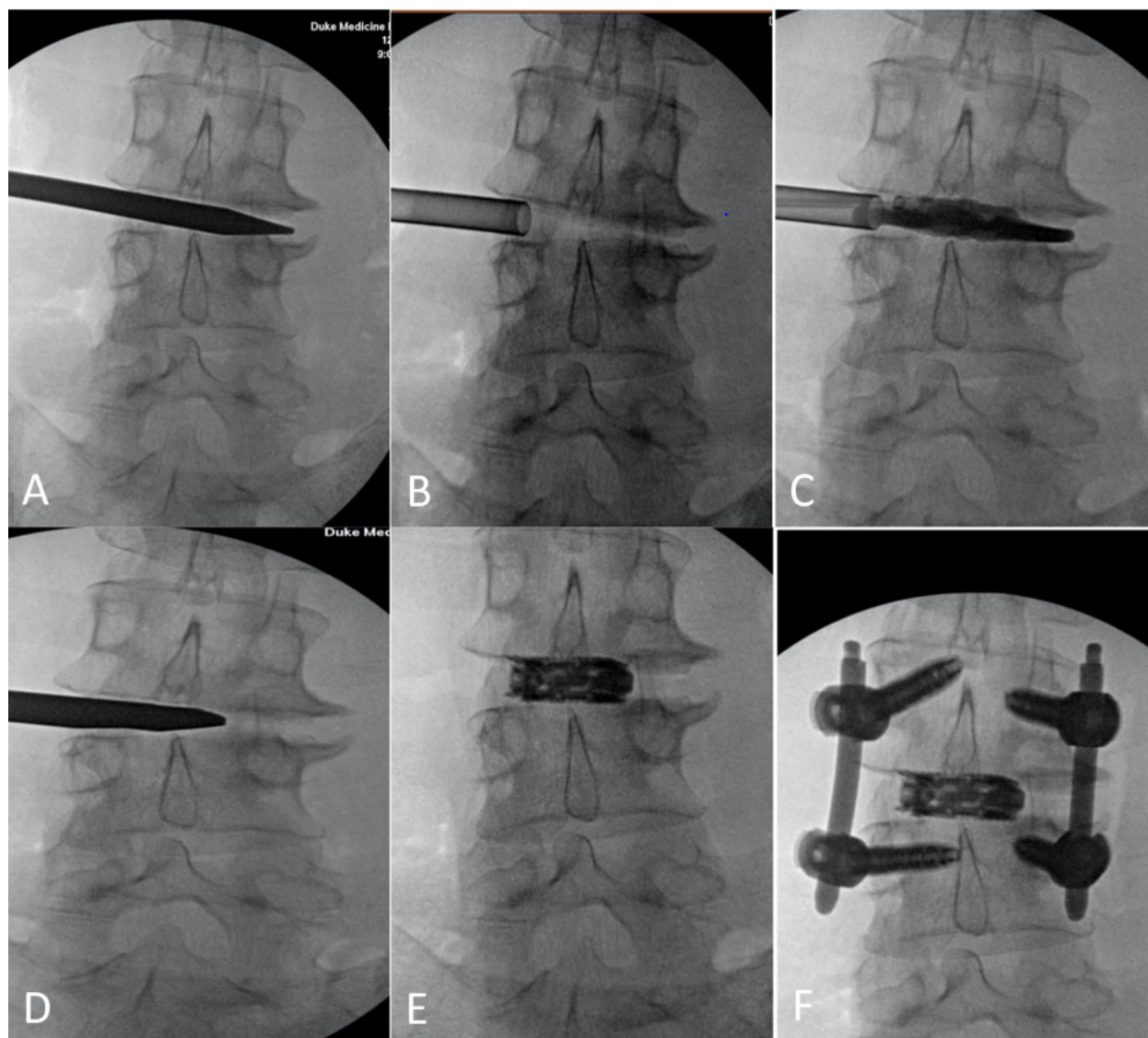


Figure 1. Sequential fluoroscopic imaging of the percutaneous lumbar interbody fusion. (A) A blunt electromyography guided probe traverses the fascia, Kambin's triangle, and is introduced into the disc space. (B) After sequential dilation, a working cannula is docked inside the disc space to protect surrounding structures. (C) After appropriate discectomy, a balloon is placed inside the disc space and inflated with radio-opaque material to confirm satisfactory discectomy. (D) After satisfactory end plate preparation, an introducer is placed at the center of the disc space and loaded with an expandable cage. (E) The cage is expanded as it is shown. (F) Percutaneous screws are placed to complete the procedure.

of the disc space and can identify any remaining disc fragments or confirm the complete discectomy (Figure 1C). Then, a special inserter (Envoy, Spineology, Minneapolis, MN) was used to help place the ELITE Expandable Cage (Spineology, Minneapolis, MN) (Figure 1D). The cage was inserted at a starting height of 7 mm and expanded to a final height of a maximum of 15 mm and filled with allograft cortical fibers. All cages are 10 mm wide and can come in 0, 6, and 12 degrees of lordosis.

Under fluoroscopic guidance, the cage was placed in the middle of the disc space and expanded until the cage is in good contact with the inferior and superior end plate to provide indirect decompression (Figure 1E). This

incision is closed at the skin, only, with either monocrystal suture or staples. Attention is then paid to percutaneous pedicle screw instrumentation, which can be performed via stab incisions or Wiltse incisions per surgeon preference with final fluoroscopy used to confirm appropriate placement of all hardware (Figure 1F).

Statistical Analysis

Data were compiled in Microsoft Excel (Microsoft Inc, Redmond, WA). Parametric data were expressed as means with standard deviation and compared with the Fisher's exact test. Categorical data were compared with the χ^2 test with $\alpha < 0.05$.

Table 1. Demographic data.

Variable	Value Count (%) or Mean (SD)
<i>N</i>	16 (100%)
Age (years)	56.9 (11.4)
Female	13 (81.3%)
BMI (kg/m ²)	30.8 (5.3)
Grade 1 spondylolisthesis	16 (100%)
Hypertension	7 (43.8%)
Dyslipidemia	2 (12.5%)
Diabetes mellitus type 2	4 (25.0%)
Coronary artery disease	2 (25.0%)
Rheumatoid arthritis	0 (0.0%)
Operative level	
L1-L2	0 (0%)
L2-L3	1 (6.3%)
L3-L4	3 (18.8%)
L4-L5	9 (56.3%)
L5-S1	3 (18.8%)

RESULTS

Demographic Data

Sixteen patients were identified as having a grade 1 lumbar spondylolisthesis that underwent perLIF, and all patients were followed postoperatively through at least 1 year. Table 1 depicts the patient demographics, comorbidities, and level of disease. Thirteen of the 16 patients were female (81.3%), and 3 were male (18.7%). The average age was 56.9 ± 11.4 years. The average Body Mass Index was 30.8 ± 5.3 kg/m² with a range of 22.1 to 39.5 kg/m². The most common operative level was L4-5 with 9 patients (56.3%), followed by L3-4, and L5-S1 with 3 patients each (18.8%) and L2-3 with 1 patient (6.3%). PercLIF did not have to be abandoned for the more traditional open or minimally invasive approaches for any patient.

Hospitalization Data

Operative data is summarized in Table 2. The mean operative time was 157 ± 45.9 min, with an average estimated blood loss of 39.3 ± 39.4 mL. Average hospital stay was 1.5 days, where 8 of the 16 patients discharged on postoperative day 1. Of those remaining 8 patients who were not discharged on postoperative day 1, 4 had not yet cleared physical and occupational therapy, 3 patients still required intravenous analgesic agents, and

Table 2. Operative and hospitalization data.

Variable	Value Count (%) or Mean (SD)
Operative time (minutes)	149 (33.8)
Estimated blood loss (milliliters)	29.6 (12.4)
Length of stay (nights)	1.50 (.650) ^a

^aTwo patients were considered outliers and omitted as they were outside the mean plus 2 standard deviations.

1 patient was not yet medically safe for discharge due to respiratory distress. Two patients' length of stay were 2 standard deviations outside of the group's mean. As such, they were considered outliers and not included in the length of stay data analysis.

Complications

No intraoperative complications were noted. In this patient series, there were no instances of new postoperative neurological deficits or radiculopathies. One patient who underwent an L4-5 perLIF was readmitted within 30 days of surgery. His index case was uncomplicated, but he remained in the hospital until postoperative day 8 for pain control, at which point the patient was discharged to home. He was presented to the emergency department with postoperative pain on postoperative day 21. CT lumbar spine and CT myelogram were conducted, which confirmed well-positioned hardware and no compression of the nerve roots or thecal sac. The patient was readmitted for pain management and was discharged home after 5 days of additional analgesia and work with physical and occupational therapy.

Radiographical Data

Radiographical data are summarized in Table 3. Baseline spondylolisthesis was 8.6 ± 5.4 mm and improved to 5.0 ± 2.0 mm at 6 weeks postoperatively, 4.3 ± 2.7 mm at 6 months postoperatively, and 3.7 ± 2.11 mm at 12 months postoperatively (*P* = 0.005, *P* = 0.036, and *P* = 0.044, respectively). Changes in preoperative and postoperative spondylolisthesis are summarized in Figure 2. This corresponded to a 34.6 ± 21.8% improvement in spondylolisthesis at 6 weeks, 42.6 ± 30.1% improvement at 6 months, and 58.2 ± 27.6% improvement at 12 months. Baseline anterior disc height was 5.8 ± 2.7 mm and improved to 8.9 ± 2.8 mm at 6 weeks postoperatively, 11.9 ± 4.0 mm at 6 months postoperatively, and 10.5 ± 3.0 mm at 12 months postoperatively (*P* < 0.0002, *P* = 0.003, and *P* = 0.040, respectively). Baseline posterior disc height was 5.9 ± 2.7 mm and improved to 8.9 ± 2.8 mm at 6 weeks postoperatively, 8.0 ± 1.3 mm at 6 months postoperatively, and 9.0 ± 4.1 mm at 12 months postoperatively (*P* = 0.0005, *P* = 0.018, and *P* = 0.048, respectively). Figure 3 shows the change in anterior and posterior disc height preoperatively and postoperatively. Lumbar lordosis varied widely among patients and averaged 17.3 ± 20.2 degrees preoperatively and 19.4 ± 17.4%, immediately postoperatively. All patients had 12-month postoperative imaging for review, which demonstrated a 93.8% fusion rate per previous criteria.

Table 3. Patient spondylolisthesis, anterior disc height, and posterior disc height.

Variable	Baseline, Mean (SD) (n = 16)	6 Weeks, Mean (SD) (n = 16)	6 Months, Mean (SD) (n = 10)	12 Months, Mean (SD) (n = 6)	P Value
Spondylolisthesis (mm)	8.6 (5.4)	5.0 (2.0)	4.3 (2.7)	3.7 (2.11)	6 weeks: $P = 0.005$ 6 months: $P = 0.036$ 12 months: $P = 0.044$
Anterior disc height (mm)	6.9 (3.6)	11.9 (3.5)	11.9 (4.0)	10.5 (3.0)	6 weeks: $P < 0.0002$ 6 months: $P = 0.003$ 12 months: $P = 0.040$
Posterior disc height (mm)	5.9 (2.7)	8.9 (2.8)	8.0 (1.3)	9.0 (4.1)	6 weeks: $P = 0.0005$ 6 months: $P = 0.018$ 12 months: $P = 0.048$

Oswestry Disability Index

Average baseline ODI was $41.5 \pm 8.45\%$ indicating “severe disability” and improved to $34.4 \pm 14.9\%$ and “moderate disability” at 6 weeks, $35.8 \pm 8.6\%$ and “moderate disability” at 6 months, and $17.0 \pm 14.1\%$ and “minimal disability” at 12 months. One-year ODI was significantly improved when compared to baseline ($P = 0.0036$). The improvement in ODI is illustrated in Figure 4.

Case Example

A 54-year-old male with an unremarkable past medical history presented with back and leg pain refractory to conservative measures and subsequently underwent magnetic resonance imaging and flexion-extension x-ray imaging (Figure 5) demonstrating degenerative disc disease at L3-4 with loss of height, diffuse disc bulge, including right neuroforamen compromise with

resulting severe narrowing. Flexion-extension x-ray images showed static grade 1 spondylolisthesis with retrolisthesis of L3 on L4. The patient underwent an uncomplicated perCLIF at L3-4, with excellent hardware placement and durable indirect decompression at 6 months postoperatively. The patient’s ODI improved from a baseline of 40% to 11% at 6 weeks and 6% at 12 months postoperatively, indicating a rapid reduction in disability that was maintained long term.

DISCUSSION

MIS surgery techniques have undergone tremendous changes within the past 2 decades. This has included the advent of new corridors to the spine, such as lateral and oblique approaches, which aim to avoid the important paraspinous musculature, as well as tubular and endoscopic spine surgery. Endoscopic spine surgeons have long appreciated the importance

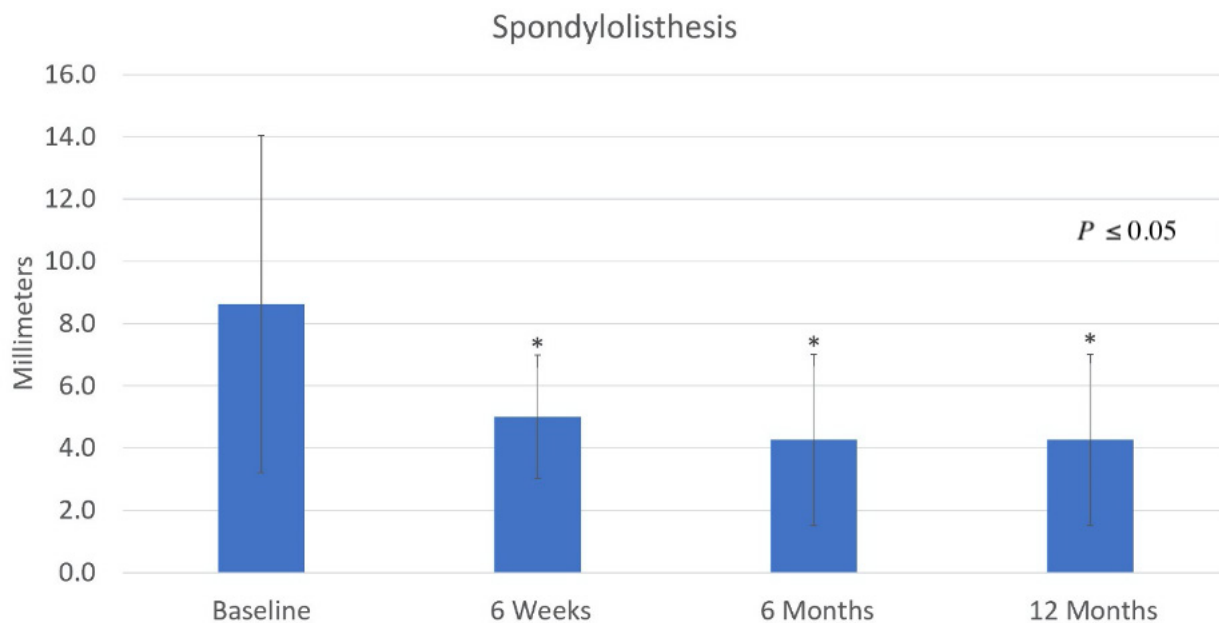


Figure 2. Bar graph illustrates the correction of the grade 1 spondylolisthesis preoperatively compared to 6 weeks, 6 months, and 12 months postoperatively. The improvement in spondylolisthesis was significantly improved at 6 weeks, 6 months, and 12 months postoperatively ($P < 0.05$).

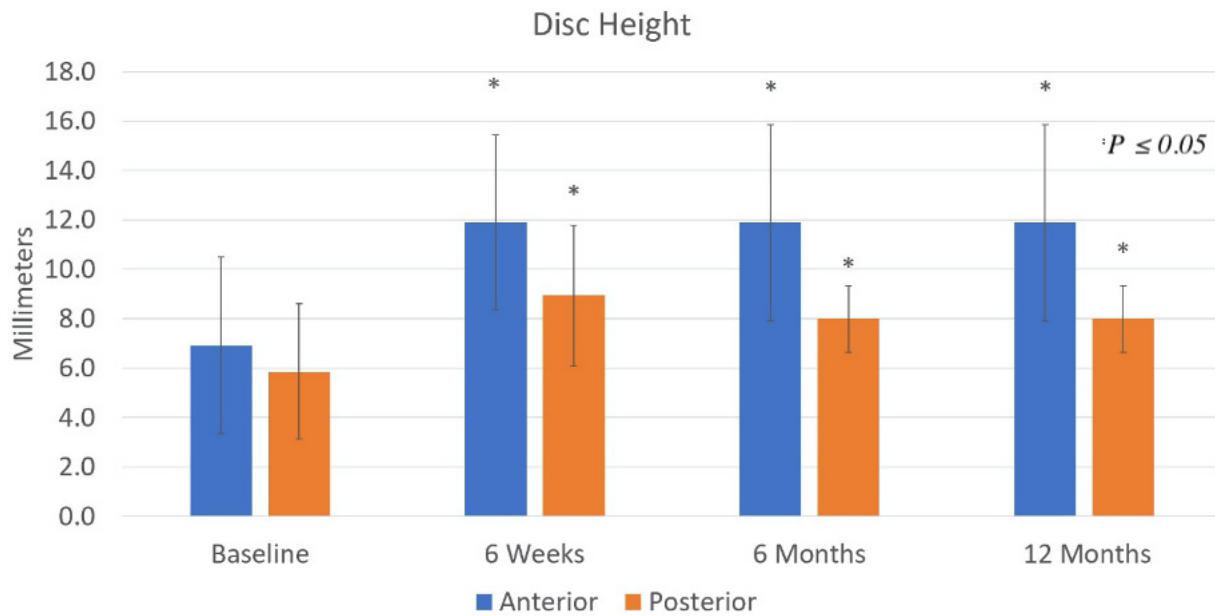


Figure 3. Bar graph shows baseline disc height and its increase at 6 weeks, 6 months and 12 months postoperatively. The anterior and posterior disc height was significantly increased at 6 weeks, 6 months, and 12 months postoperatively ($P \leq 0.05$).

of Kambin's triangle as a method to perform discectomies without the need for laminectomies or facetectomies, which ensures minimal disruption of the normal tissue by utilizing natural anatomical planes and windows. As the facet joint contains a rich vascular and nerve supply, avoiding disruption can prevent unnecessary patient pain and morbidity.¹⁸ Until recently, it was only possible to perform discectomy through Kambin's triangle, as previous technology

prevented the operator from placing interbody devices through endoscopic or percutaneous portals. Recent advances in instrumentation have granted this ability to surgeons, thus allowing for a complete perCLIF. This case series demonstrates promising clinical and radiographic improvements following complete perCLIF; while this series contains only 16 patients, none of the patients experienced any new neurological deficit or major surgical complication.

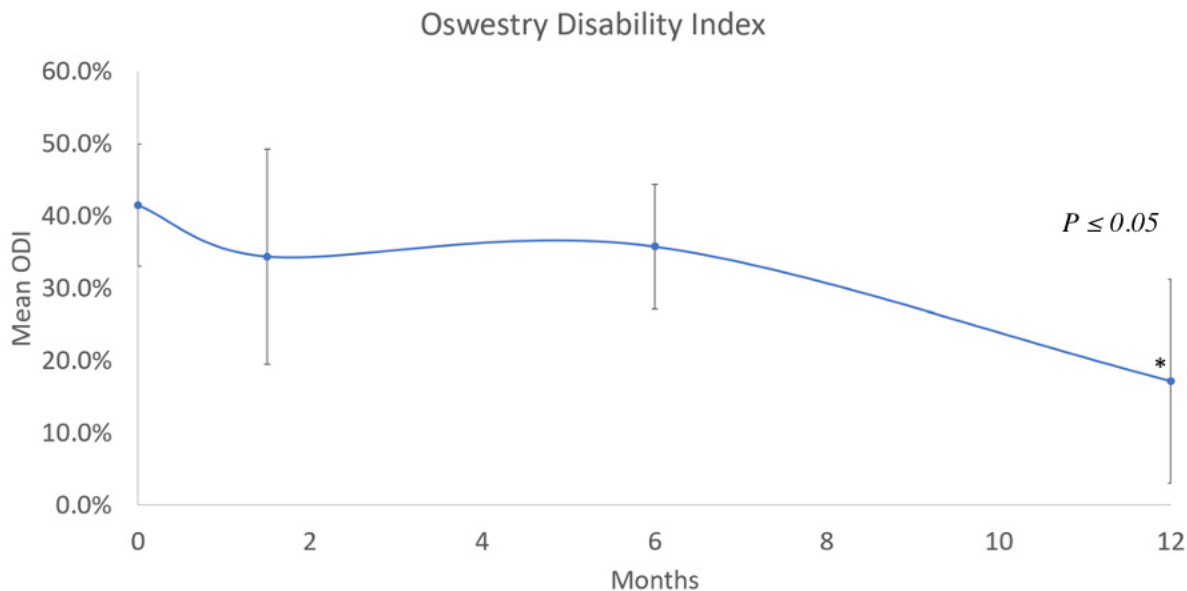


Figure 4. Scatter plot demonstrating mean Oswestry Disability Index (ODI) scores of patients receiving percutaneous lumbar interbody fusion procedure over 1-year period. ODI scores were significantly improved at 1 year when compared to baseline ($P \leq 0.05$).

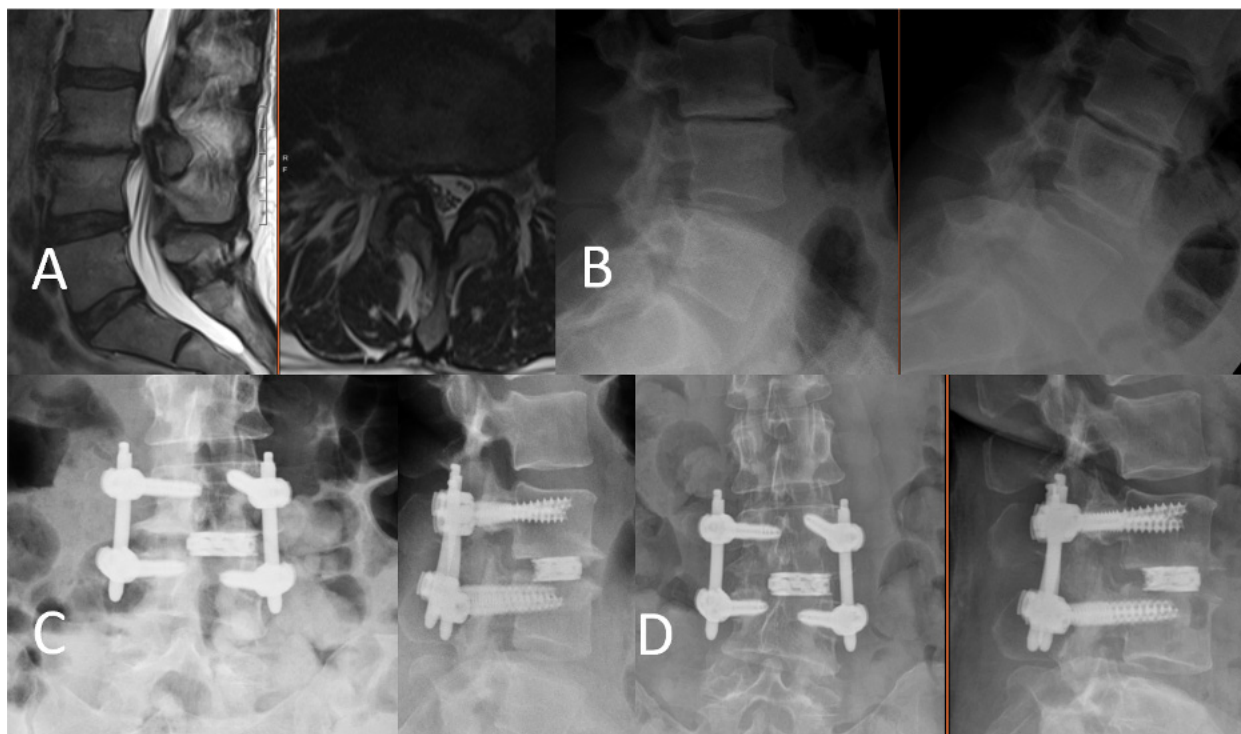


Figure 5. Radiographical evaluation of the patient. (A) Preoperative lumbar sagittal and axial magnetic resonance imaging without contrast showing degenerative disc disease, height loss, and disc bulge at L3-4 with left neuroforaminal stenosis. (B) Preoperative flexion-extension lumbar x-rays showing a grade 1 spondylolisthesis at L3-4. (C) Anterior-posterior and lateral lumbar x-rays immediately after L3-4 percutaneous lumbar interbody fusion (perCLIF) showing satisfactory placement of the interbody expandable cage and rigid pedicle screw and rod fixation. (D) Anterior-posterior and lateral lumbar x-rays 6 months after L3-4 perCLIF showing appropriate hardware placement.

The completely percutaneous technique described in this manuscript offers the spine surgeon a unique ability to perform lumbar interbody fusion with minimal unnecessary tissue trauma. Minimally invasive transforaminal lumbar interbody fusion (MIS TLIF) is another such well-established minimally invasive technique, although the need for medial or complete facetectomy results in slightly higher blood loss when compared to completely percutaneous methods. Estimated blood loss for a single-level MIS TLIF varies in the literature from 143 to 352 mL, which is comparatively still less than open techniques.^{19–22} Additionally, length of stay for a single-level MIS TLIF has been found to be 2.3 to 3.35 days^{23–25}. The perCLIF technique described here compares favorably with an average estimated blood loss of 39.3 mL and a length of stay of 1.5 days.

The reduced blood loss and shorter hospital stays were validated by patient-reported improvements in short- and long-term clinical and radiographic outcomes. In this cohort, both short- and long-term ODI score improvements surpassed the minimal clinically important difference of 12.8% to 14.3% as accepted in the previously published literature on lumbar spondylolisthesis.^{26,27} This has been similarly reported by existing literature on endoscopic percutaneous techniques,

including a 2019 report by Morgenstern and Morgenstern, which demonstrated significantly improved postoperative visual analog scale and ODI scores at 1 year.¹⁴ They followed this with a study on full percutaneous, transforaminal lumbar interbody fusion using a facet-sparing, trans-Kambin approach, similar to the technique reported in this manuscript. In this study, they found that visual analog scale axial lumbar pain, leg pain, and ODI were significantly improved postoperatively with a mean follow-up of 27.9 months²⁸. However, they noted a 32% postoperative complication rate consisting of ipsilateral dysesthesias and transitory muscle weakness. Their technique did not comment on the use of free-running EMG as was used for the patients in this series, which the present authors believe is necessary to ensure no damage is done to the exiting nerve root during the discectomy or impaction of the interbody device. Our patient sample consequently demonstrated no new cases of dysesthesias, despite undergoing a surgical technique that was otherwise similar to that proposed by Morgenstern and Morgenstern.

One previous criticism of percutaneous fusion techniques was increased rates of pseudarthrosis. This criticism stemmed from a multitude of factors, incomplete discectomy secondary to lack of direct visualization,

and small cage footprint due to percutaneous delivery portals. As the technique has evolved, clinical outcomes have improved while complications have decreased, and as this manuscript has demonstrated, fusion rates have improved to rival those of more traditional approaches.^{19,28,29}

Percutaneous techniques certainly have limitations. Similar to other spine procedures relying on ligamentotaxis and indirect decompression, patients with high-grade spondylolisthesis, or advanced bony lateral recess stenosis or central canal stenosis are considered poor candidates for percutaneous lumbar fusion.³⁰ However, patients with low-grade spondylolisthesis (either mobile or static) and degenerative disc disease causing back pain and radiculopathies seem to experience encouraging outcomes. Indeed, this is the first study to show interval significant improvements in ODI and disc height following perLIF for the indication of grade 1 lumbar spondylolisthesis with the implantation of an expandable titanium interbody cage through Kambin's triangle.

Limitations

Consistent with most small case series, surgeons should be cautious to make broad scale generalizations regarding the outcomes of this study. While the patients in this series did not have major surgical complications, it is important to recognize the ever present risk of nerve root injury and cerebrospinal fluid leak, which have been documented in previous literature.³¹

Lastly, as this was a single-surgeon, single-institutional study, there may be differences in technique or patient selection within the inclusion and exclusion criteria that may have impacted clinical outcomes. As more surgeons adopt percutaneous lumbar fusion techniques, the authors anticipate future studies will combine the techniques and outcomes from a multitude of providers.

CONCLUSION

In our retrospective series, the perLIF is an effective technique for the insertion of an expandable titanium cage for the treatment of grade 1 lumbar spondylolisthesis and does not require the use of an endoscope. These patients had significant improvement in their spondylolisthesis, disc height, and ODI scores after perLIF. Further long-term studies are needed to validate imaging and quality of life improvements seen here.

REFERENCES

1. Andersson GB. Epidemiological features of chronic low-back pain. *Lancet*. 1999;354(9178):581–585. doi:10.1016/S0140-6736(99)01312-4
2. Albert HB, Kjaer P, Jensen TS, Sorensen JS, Bendix T, Manniche C. Modic changes, possible causes and relation to low back pain. *Med Hypotheses*. 2008;70(2):361–368. doi:10.1016/j.mehy.2007.05.014
3. Takemitsu Y, Harada Y, Iwahara T, Miyamoto M, Miyatake Y. Lumbar degenerative kyphosis. *Spine*. 1988;13(11):1317–1326. doi:10.1097/00007632-198811000-00019
4. Martin BI, Mirza SK, Spina N, Spiker WR, Lawrence B, Brodke DS. Trends in lumbar fusion procedure rates and associated hospital costs for degenerative spinal diseases in the United States, 2004 to 2015. *Spine*. 2019;44(5):369–376. doi:10.1097/BRS.0000000000002822
5. Miyakoshi N, Abe E, Shimada Y, Okuyama K, Suzuki T, Sato K. Outcome of one-level posterior lumbar interbody fusion for spondylolisthesis and postoperative intervertebral disc degeneration adjacent to the fusion. *Spine*. 2000;25(14):1837–1842. doi:10.1097/00007632-200007150-00016
6. Goldstein CL, Macwan K, Sundararajan K, Rampersaud YR. Perioperative outcomes and adverse events of minimally invasive versus open posterior lumbar fusion: meta-analysis and systematic review. *J Neurosurg Spine*. 2016;24(3):416–427. doi:10.3171/2015.2.SPINE14973
7. Kim S, Mortaz Hedjri S, Coyte PC, Rampersaud YR. Cost-utility of lumbar decompression with or without fusion for patients with symptomatic degenerative lumbar spondylolisthesis. *Spine J*. 2012;12(1):44–54. doi:10.1016/j.spinee.2011.10.004
8. Morgenstern R, Morgenstern C, Yeung AT. The learning curve in foraminal endoscopic discectomy: experience needed to achieve a 90% success rate. *SAS J*. 2007;1(3):100–107. doi:10.1016/SASJ-2007-0005-RR
9. Rabei R, Patel K, Ginsburg M, et al. Percutaneous vertebral augmentation for vertebral compression fractures: national trends in the medicare population (2005-2015). *Spine*. 2019;44(2):123–133. doi:10.1097/BRS.0000000000002893
10. Butler AJ, Alam M, Wiley K, Ghasem A, Rush Iii AJ, Wang JC. Endoscopic lumbar surgery: the state of the art in 2019. *Neurosurgery*. 2019;16(1):15–23. doi:10.14245/ns.1938040.020
11. Telfeian AE, Veeravagu A, Oyelese AA, Gokaslan ZL. A brief history of endoscopic spine surgery. *FOC*. 2016;40(2):E2. doi:10.3171/2015.11.FOCUS15429
12. Tumialán LM, Madhavan K, Godzik J, Wang MY. The history of and controversy over kambin's triangle: a historical analysis of the lumbar transforaminal corridor for endoscopic and surgical approaches. *World Neurosurg*. 2019;123:402–408. doi:10.1016/j.wneu.2018.10.221
13. Kambin P, Gellman H. Percutaneous lateral discectomy of the lumbar spine. *Clin Orthop Relat Res*. 1983;174:127. doi:10.1097/00003086-198304000-00017
14. Morgenstern R, Morgenstern C. Percutaneous transforaminal lumbar interbody fusion (pTLIF) with a posterolateral approach for the treatment of degenerative disk disease: feasibility and preliminary results. *Int J Spine Surg*. 2015;9:41. doi:10.14444/2041
15. Heo DH, Son SK, Eum JH, Park CK. Fully endoscopic lumbar interbody fusion using a percutaneous unilateral biportal endoscopic technique: technical note and preliminary clinical results. *Neurosurg Focus*. 2017;43(2):E8. doi:10.3171/2017.5.FOCUS17146

16. Kolcun JPG, Brusko GD, Basil GW, Epstein R, Wang MY. Endoscopic transforaminal lumbar interbody fusion without general anesthesia: operative and clinical outcomes in 100 consecutive patients with a minimum 1-year follow-up. *Neurosurg Focus*. 2019;46(4):E14. doi:10.3171/2018.12.FOCUS18701
17. Wu J, Liu H, Ao S, et al. Percutaneous endoscopic lumbar interbody fusion: technical note and preliminary clinical experience with 2-year follow-up. *Biomed Res Int*. 2018;2018:5806037. doi:10.1155/2018/5806037
18. Manchikanti L, Boswell MV, Singh V, Pampati V, Damron KS, Beyer CD. Prevalence of facet joint pain in chronic spinal pain of cervical, thoracic, and lumbar regions. *BMC Musculoskeletal Disord*. 2004;5:15. doi:10.1186/1471-2474-5-15
19. Hockley A, Ge D, Vasquez-Montes D, et al. Minimally invasive versus open transforaminal lumbar interbody fusion surgery: an analysis of opioids, nonopioid analgesics, and perioperative characteristics. *Global Spine J*. 2019;9(6):624–629. doi:10.1177/2192568218822320
20. Ge DH, Stekas ND, Varlotta CG, et al. Comparative analysis of two transforaminal lumbar interbody fusion techniques. *Spine*. 2019;44(9):E555–E560. doi:10.1097/BRS.0000000000002903
21. Mummaneni PV, Bisson EF, Kerezoudis P, et al. Minimally invasive versus open fusion for Grade I degenerative lumbar spondylolisthesis: analysis of the Quality Outcomes Database. *Neurosurg Focus*. 2017;43(2):E11. doi:10.3171/2017.5.FOCUS17188
22. Skovrlj B, Belton P, Zarzour H, Qureshi SA. Perioperative outcomes in minimally invasive lumbar spine surgery: a systematic review. *World J Orthop*. 2015;6(11):996–1005. doi:10.5312/wjo.v6.i11.996
23. Wang MY, Lerner J, Lesko J, McGirt MJ. Acute hospital costs after minimally invasive versus open lumbar interbody fusion: data from a US national database with 6106 patients. *J Spinal Disord Tech*. 2012;25(6):324–328. doi:10.1097/BSD.0b013e318220be32
24. Singh K, Nandyala SV, Marquez-Lara A, et al. A perioperative cost analysis comparing single-level minimally invasive and open transforaminal lumbar interbody fusion. *Spine J*. 2014;14(8):1694–1701. doi:10.1016/j.spinee.2013.10.053
25. Parker SL, Mendenhall SK, Shau DN, et al. Minimally invasive versus open transforaminal lumbar interbody fusion for degenerative spondylolisthesis: comparative effectiveness and cost-utility analysis. *World Neurosurg*. 2014;82(1–2):230–238. doi:10.1016/j.wneu.2013.01.041
26. Copay AG, Glassman SD, Subach BR, Berven S, Schuler TC, Carreon LY. Minimum clinically important difference in lumbar spine surgery patients: a choice of methods using the Oswestry Disability Index, Medical Outcomes Study questionnaire Short Form 36, and pain scales. *Spine J*. 2008;8(6):968–974. doi:10.1016/j.spinee.2007.11.006
27. Asher AL, Kerezoudis P, Mummaneni PV, et al. Defining the minimum clinically important difference for grade I degenerative lumbar spondylolisthesis: insights from the Quality Outcomes Database. *Neurosurg Focus*. 2018;44(1):E2. doi:10.3171/2017.10.FOCUS17554
28. Morgenstern C, Yue JJ, Morgenstern R. Full percutaneous transforaminal lumbar interbody fusion using the facet-sparing, trans-kambin approach. *Clin Spine Surg*. 2020;33(1):40–45. doi:10.1097/BSD.0000000000000827
29. Khalifeh JM, Dibble CF, Stecher P, Dorward I, Hawasli AH, Ray WZ. Transfacet minimally invasive transforaminal lumbar interbody fusion with an expandable interbody device—part II: consecutive case series. *Operative Neurosurgery*. 2020;19(5):518–529. doi:10.1093/ons/opaa144
30. Yuan C, Wang J, Zhou Y, Pan Y. Endoscopic lumbar discectomy and minimally invasive lumbar interbody fusion: a contrastive review. *Wideochir Inne Tech Maloinwazyjne*. 2018;13(4):429–434. doi:10.5114/wiitm.2018.77744
31. Ahn Y, Lee HY, Lee SH, Lee JH. Dural tears in percutaneous endoscopic lumbar discectomy. *Eur Spine J*. 2011;20(1):58–64. doi:10.1007/s00586-010-1493-8

Funding: The authors received no financial support for the research, authorship, and/or publication of this article.

Declaration of Conflicting Interests:

Vikram A. Mehta, MD, MPH: none, Timothy Y. Wang, MD: none, Eric W. Sankey, MD: none, Alexia Bwensa BA: none, Mostafa Gabr, MD: none, C. Rory Goodwin, MD, PhD: Received grants from the Burroughs Wellcome Fund, North Carolina Spine Society, and the NIH/NINDS K12 NRC DP Physician Scientist Award, Robert Wood Johnson Harold Amos Medical Faculty Development Program. Isaac O. Karikari, MD: Consultant for Nuvasive; Receives Fellowship funding from Nuvasive. Member of Advisory Board for Johnson&Johnson Adult Deformity Group. John H. Chi, MD, MPH: Consulting for K2M, Muhammad M. Abd-El-Barr, MD, PhD: Consultant for Spineology

Corresponding Author: Muhammad M. Abd-El-Barr, Duke University Medical Center, Durham, NC 27710, USA; m.abdelbarr@duke.edu

Published 20 January 2022

This manuscript is generously published free of charge by ISASS, the International Society for the Advancement of Spine Surgery. Copyright © 2021 ISASS. To see more or order reprints or permissions, see <http://ijssurgery.com>.