

## Disseminated Intravascular Coagulation in Pediatric Scoliosis Surgery: A Systematic Review

Sarah E. Walker, Lee Bloom, Patrick J. Mixa, Karen Paltoo, Frank S. Cautela, Hiram Luigi-Martinez, Joseph P. Scollan, Zhida Jin, Bhaveen H. Kapadia, Andrew Yang, Allison B. Spitzer, Peter G. Passias, Virginie Lafage, Khalid Hesham, Carl B. Paulino and Bassel G. Diebo

*Int J Spine Surg* 2022, 16 (1) 4-10

doi: <https://doi.org/10.14444/8201>

<https://www.ijssurgery.com/content/16/1/4>

This information is current as of May 2, 2025.

---

**Email Alerts** Receive free email-alerts when new articles cite this article. Sign up at:  
<http://ijssurgery.com/alerts>

# Disseminated Intravascular Coagulation in Pediatric Scoliosis Surgery: A Systematic Review

SARAH E. WALKER, MD<sup>1</sup>; LEE BLOOM, MD<sup>1</sup>; PATRICK J. MIXA, MD<sup>1</sup>; KAREN PALTOO, MD<sup>1</sup>;  
FRANK S. CAUTELA, MD<sup>1</sup>; HIRAM LUIGI-MARTINEZ, MD<sup>1</sup>; JOSEPH P. SCOLLAN, MD<sup>1</sup>; ZHIDA JIN, MD<sup>1</sup>;  
BHAVEEN H. KAPADIA, MD<sup>1</sup>; ANDREW YANG, MD<sup>1</sup>; ALLISON B. SPITZER, MD<sup>1</sup>; PETER G. PASSIAS, MD<sup>2</sup>;  
VIRGINIE LAFAGE, PHD<sup>3</sup>; KHALID HESHAM, MD<sup>1</sup>; CARL B. PAULINO, MD<sup>1</sup>; AND BASSEL G. DIEBO, MD<sup>1,4</sup>

<sup>1</sup>Orthopaedic Surgery, State University of New York, Downstate Medical Center, Brooklyn, NY, USA; <sup>2</sup>NY Spine Institute/Division of Spine Surgery, NYU Langone Medical Center, New York, NY, USA; <sup>3</sup>Orthopaedic Surgery, Lenox Hill/Northwell Health, New York, NY, USA; <sup>4</sup>Orthopaedic Surgery, Warren Alpert Medical School of Brown University, Providence, RI, USA

## ABSTRACT

**Background:** Disseminated intravascular coagulation (DIC) is a rare but serious complication of pediatric scoliosis surgery; sparse current evidence warrants more information on causality and prevention. This systematic review sought to identify incidence of DIC in pediatric patients during or shortly after corrective scoliosis surgery and identify any predictive factors for DIC.

**Methods:** Medline/PubMed, EMBASE, and Ovid databases were systematically reviewed through July 2017 to identify pediatric patients with DIC in the setting of scoliosis surgery. Patient demographics, medical history, surgery performed, clinical course, suspected causes of DIC, and outcomes were collected.

**Results:** Eleven studies met inclusion criteria. Thirteen cases from 1974 to 2012 (mean age:  $15.3 \pm 4.3$  years, 72% women) were identified, with neuromuscular ( $n = 7$ ; 54%) scoliosis as the most common indication. There were no prior bleeding disorder histories; all preoperative labs were within normal limits. Procedures included 8 posterior segmental fusions (54%), 3 Harrington rods (31%), 1 Cotrel-Dubousset, and 1 unit rod. Eight patients experienced DIC intraoperatively and 5 patients experienced DIC postoperatively. Probable DIC causes included coagulopathy following intraoperatively retrieved blood reinfusion, infection from transfusion, rhabdomyolysis, hemostatic matrix application, heparin use, and hypovolemic shock. Most common complications included increased intraoperative blood loss ( $n = 8$ ) and hypotension ( $n = 7$ ). The mortality rate was 7.69%; one fatality occurred in the acute postoperative period.

**Conclusions:** Prior bleeding disorder status notwithstanding, this review identified preliminary associations between variables during corrective scoliosis surgery and DIC incidence among pediatric patients, suggesting multiple etiologies for DIC in the setting of scoliosis surgery. Further investigation is warranted to quantify associated risk.

**Clinical Relevance:** This study brings awareness to a previously rarely discussed complication of pediatric scoliosis surgery. Further cognizance of DIC by scoliosis surgeons may help identify and prevent causes thereof.

**Level of Evidence:** 4.

Complications

Keywords: disseminated intravascular coagulation, scoliosis, pediatric surgery, postoperative complications

## INTRODUCTION

Disseminated intravascular coagulation (DIC) is a pathological process culminating in the activation of the coagulation cascade. This results in the production of fibrin and the formation of microthrombi in small to mid-sized vessels.<sup>1</sup> Ultimately, these occlusions can result in the infarction of end organs and death.<sup>2,3</sup> Furthermore, the increased activation of the coagulation cascade leads to a depletion of platelets and coagulation factors; this causes excessive bleeding.<sup>1</sup> As DIC is a syndrome rather than a disease, it is secondary to an underlying cause.<sup>2</sup> Etiologies of DIC can be divided into 2 pathways of coagulation cascade activation: a

cytokine-driven inflammatory response and via the release of procoagulatory factors into the blood.<sup>2,3</sup>

DIC is most commonly attributed to trauma and infection.<sup>2,4</sup> It has been previously reported that up to 32% of pediatric patients may develop DIC following head trauma.<sup>5</sup> These DIC patients have mortality rates 4 times higher than those of patients with normal hemostasis;<sup>5</sup> these results underscore the severity of the syndrome in pediatric populations and the need for physicians to understand its risks fully.

DIC as a complication of pediatric scoliosis surgery is rare and sparsely reported, with only several documented cases in current literature. In Raphael et al,<sup>6</sup> 2 incidences of DIC with unknown causes in 1982 were

reported. In Benavides et al,<sup>7</sup> one case of DIC following septic shock triggered by blood transfusion in 2003 was studied.

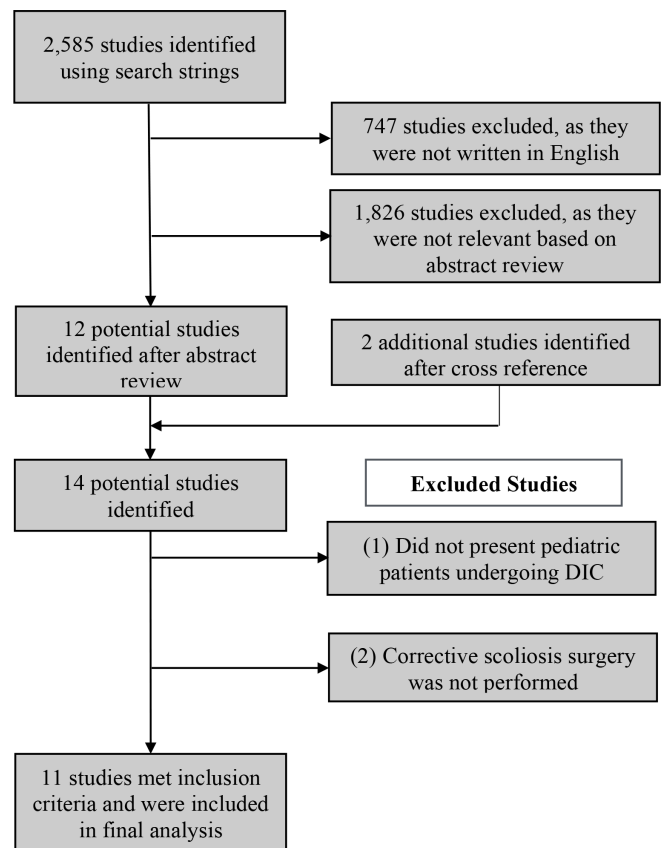
To our knowledge there are no systematic reviews that have been completed on this subject. This study aims to review the literature, evaluate occurrences of DIC in pediatric scoliosis surgery, and enhance the understanding of underlying factors and associated complications. Such an extensive review should permit the analysis of possible causes and detection of potential preventive measures.

## MATERIALS AND METHODS

Computer-based searches of the Medline (PubMed), EMBASE, and Ovid electronic databases were utilized to systematically review the literature through July 2017. The literature search was performed independently by 3 of the authors (Mixa, Scollan, and Diebo). The search terms “DIC” or “disseminated intravascular coagulation” were used along with “scoliosis,” or “spine,” or “pediatric” and “surgery” or “operation.” A total of 2585 abstracts were identified. Non-English articles were excluded ( $n = 747$ ), narrowing the search to 1826 abstracts. Of those, 12 articles discussed information relevant to our search criteria. A cross-reference was performed and 2 additional reports were added for a total of 14 studies. Inclusion criteria consisted of patients who had any type of scoliosis and developed DIC intraoperatively or postoperatively as a result of their surgical treatment. For this study, DIC was defined by the authors’ use of the terminology and not by common clinical presentations or established laboratory parameters. A total of 11 studies, including 8 case reports and 3 retrospective studies, met inclusion criteria. Data from these studies were extracted for the systematic review (Figure). This article does not contain any studies with human participants or animals performed by any of the authors.

### Statistical Analysis

Two reviewers (Mixa, Scollan) independently extracted the data from each article. The parameters included were patient demographics, type of surgery performed, clinical course, and patient outcome. Patients were categorized by the cause of scoliosis, past medical history, number of levels corrected, and instrumentation used. The timing of DIC was divided into intraoperative or postoperative periods. Intraoperative data, including surgical time, estimated



**Figure.** Flow diagram outlining the systematic review performed for this study.

blood loss, and intraoperative complications, were recorded. For each case, the symptoms associated with DIC, length of intubation, and time until stabilization were documented. Furthermore, patients were assigned a cause for DIC based on each study’s conclusion. Information regarding patients who did not experience DIC was excluded from this analysis.

Information from each study was extracted and organized into electronic spreadsheets (Microsoft Excel, Microsoft Office 2011, Redmond, Washington). Descriptive analysis was performed using Microsoft Excel.

## RESULTS

### Patient Population

A total of 11 studies reported on 13 patients who experienced DIC during or shortly after corrective scoliosis surgery (Table 1). These cases were reported between 1974 and 2012. The average age of the patients at the time of the event was  $15.2 \pm 3.9$  years, and 72% of these patients were women (Table 2). The etiologies of their scoliosis were neuromuscular ( $n =$

**Table 1.** Intraoperative and postoperative information for patients with disseminated intravascular coagulopathy following scoliosis surgery.

Study Name	Past Medical History	Time of Destabilization	IO Complication	PO Symptoms	PO Diagnosis/Intervention
Benavides S et al, 2003	Viral illness prior to PO blood donation	IO	Fever, hypotension	Septic shock, ARDS, LE ischemia, seizures, hypotension, renal failure, anemia	<i>Yersinia enterocolitica</i> from transfusion, BL below knee amputation, multiple intracranial hemorrhagic infarcts with subsequent seizure disorder
Canbay O et al, 2004	NR	PO	Dislocation of a pedicular pin at T3, loss of LE motor function, hypotension, myoclonic spasms	Hypotension, tachycardia and fever, myoclonic spasms, malignant hyperthermia	Myelography with nonionic, water-soluble contrast, rhabdomyolysis
Chechik O et al, 2010	Cerebral palsy	PO	NR	NR	NR
Ferschl M et al, 2009	None	IO	Ventricular tachycardia, ventricular fibrillation, cardiac arrest, surgical site bleeding, hypotension, cardiac resuscitation	Hypotension, ventricular fibrillation	IO application of a (20 mL) topical hemostatic matrix for increased bleeding at L2 pedicle was sent into intravascular space
Gabos PG et al, 2012.	Rett syndrome	PO	NR	NR	Heparin-induced thrombocytopenia following right leg deep vein thrombosis treatment
Hassmann GC et al, 1974	Distal weakness	IO	Pulseless ventricular tachycardia (at 90th min), cardiac massage performed, increased bleeding	Hypotension, restrictive lung disease, petechiae, hematuria	Coagulopathy after homologous blood
Master DL et al, 2011	None	PO	Coagulopathy, excessive blood loss, cardiac failure, death	NR	Death
McKie JS et al, 1997	None	IO	Increased bleeding, hypotension	Hypotension, ST- segment depression, ARDS, acute pancreatitis	Coagulopathy after reinfusion of IO retrieved blood
Murray DJ et al, 1992	Cerebral palsy with spastic quadriplegia	IO	Increased bleeding	NR	Coagulopathy after reinfusion of IO retrieved blood
Murray DJ et al, 1992	Myelomeningocele, T10 sensory level	IO	Increased bleeding, hematuria	NR	Coagulopathy after reinfusion of IO retrieved blood
Ogura Y et al, 2011	Cavernous hemangioma	PO	Massive hemorrhage from hemangioma, hypotension	Agitation, hypovolemic shock, BL frontal and temporal ischemia, aphasia	PO hemorrhage from hemangioma. Aphasia resolved and infarcts decreased in size
Raphael BG et al, 1982	Paraplegia, T6 injury at birth	IO	Increased bleeding, hypotension	24 h PO bleeding	Unknown
Raphael BG et al, 1982	Familial osteochondromatosis	IO	Increased bleeding	24 h PO bleeding	Unknown

Abbreviations: ARDS, acute respiratory distress syndrome; BL, bilateral; IO, intraoperative; LE, lower extremity; NR, not recorded; PO, postoperative.

**Table 2.** A summary of patient demographics, scoliosis type, procedure performed, and labs taken during time of disseminated intravascular coagulopathy.

Study Name	Age	Sex	Scoliosis Type	Procedure	Platelets (10 <sup>9</sup> /L)	Prothrombin Time (s)	Fibrin Degradation Products (s)	Fibrinogen (mg/dL)
Benavides S et al, 2003	12	F	Congenital	Posterior spinal fusion	NR	NR	NR	NR
Canbay O et al, 2004	14	F	Congenital	Posterior spinal fusion	NR	NR	>150	75
Chechik O et al, 2010	NR	NR	Neuromuscular	Posterior spinal fusion	NR	NR	NR	NR
Ferschl M et al, 2009	18	F	Idiopathic	Posterior spinal fusion	11	NR	>100	51
Gabos PG et al, 2012	14	F	Neuromuscular	Unit rod	NR	17.4	50	NR
Hassmann GC et al, 1974	13	F	Neuromuscular	Harrington rod	75	18.8	50	130
Master DL et al, 2011	NR	NR	Neuromuscular	Posterior spinal fusion	NR	NR	NR	NR
McKie JS et al, 1997	17	M	Idiopathic	Harrington rod	NR	17.4	>150	NR
Murray DJ et al, 1992	18	M	Neuromuscular	Posterior spinal fusion	95	NR	NR	NR
Murray DJ et al, 1992	17	F	Neuromuscular	Posterior spinal fusion	46	18	75	50
Ogura Y et al, 2011	12	M	Tumor induced	Posterior spinal fusion	19	20	150	19
Raphael BG et al, 1982	26	F	Neuromuscular	Distraction rods	73.5	16.4	56	125
Raphael BG et al, 1982	13	F	Tumor induced	Harrington distraction rod	75	17	51.2	70

Abbreviation: NR, not reported.

7; 54%), congenital ( $n = 2$ ; 15%), tumor induced ( $n = 2$ ; 15%), and idiopathic ( $n = 2$ ; 15%).

### Past Medical History and Preoperative Labs

Patients who had neuromuscular scoliosis presented with a history of cerebral palsy,<sup>8,9</sup> mild distal weakness,<sup>4</sup> Rett syndrome,<sup>10</sup> and a myelomeningocele with a T10 sensory level.<sup>9</sup> Tumors causing the scoliotic curve were from a patient with familial osteochondromatosis<sup>6</sup> and a cavernous hemangioma.<sup>11</sup> One patient was also diagnosed with a viral illness prior to preoperative blood donation. No patients presented with a history of prior bleeding disorder, and all complete blood counts and coagulation panels were within normal limits prior to surgery.

### Operative Course

The surgeries performed to correct the scoliosis include: posterior spinal fusions ( $n = 8$ ; 62%), Harrington rods ( $n = 3$ ; 23%), a Cotrel-Dubousset rod ( $n = 1$ ; 8%), and a unit rod ( $n = 1$ ; 8%). The mean surgical time was  $351 \pm 137$  minutes with a mean fusion length of 13 levels. The average preoperative Cobb angle was  $65^\circ$ . An average of  $4.7 \pm 2.4$  units of blood were transfused intraoperatively, including various combinations of homologous, preoperative, and intraoperative cell-saver blood per case.

### DIC Events

A total of 8 patients<sup>4,6,7,9,12,13</sup> sustained DIC during the intraoperative period. Potential causes included coagulopathy after reinfusion of intraoperatively retrieved blood,<sup>9,13</sup> *Yersinia enterocolitica* infection from transfusion,<sup>7</sup> pyelography with nonionic water-soluble contrast causing rhabdomyolysis,<sup>14</sup> and application of hemostatic matrix.<sup>12</sup> There were 2 unknown causes in the intraoperative period.<sup>6</sup> Five patients were diagnosed with DIC in the postoperative period.<sup>10,14,15</sup> At the end of one operation, myoclonic spasms were present and loss of motor function was observed in the lower extremities.<sup>16</sup> The patient was returned to the operating room for decompression due to dislocation of a pedicle pin at the T3 level. At this time, the patient experienced DIC. One study attributed the use of heparin for treatment of a deep vein thrombosis as the initiating factor for DIC,<sup>10</sup> while another suggested hypovolemic shock after diazepam administration.<sup>11</sup> In 2 patients, the authors were unable to attribute an etiology to the event during the postoperative period.<sup>6,8,16</sup>

During DIC, mean platelet count was 56,000 per microliter (range: 11–95,000), fibrinogen was 78 mg/dL (range: 19–130), fibrin degradation product was 23.8 mg/L (range: 11.2–40), average prothrombin time was 18 seconds (range: 16–20), partial thromboplastin time was greater than 100 seconds, hemoglobin was 5.7 g/dL (range: 5.5–5.9), hematocrit was 27.6 g/dL (range: 21–34), and the international normalized ratio was 3.3 (range: 2.3–4.5).

### Post-DIC Course

The most common complication reported was increased intraoperative blood loss (8/13 cases, 62%) and hypotension (7/13 cases, 54%). Two patients went into cardiac arrest during the procedure.<sup>4,12</sup> One patient had a massive hemorrhage after attempted removal of a cavernous hemangioma.<sup>11</sup> There were individual symptoms of renal failure and acute pancreatitis, along with 2 accounts of acute respiratory distress syndrome.<sup>7,13</sup> A subset of papers included the postoperative period, during which the patient remained intubated that ranged between 1 and 6 days. Labs began to normalize at an average of  $3.5 \pm 2.5$  days after DIC. One patient was noted as having ischemia in his lower extremities after septic shock that required bilateral below knee amputations.<sup>7</sup> The same patient also experienced intracranial hemorrhagic infarcts leading to a seizure disorder. The clinical outcome in a second patient involved bilateral frontal and temporal lobe ischemia leading to sensory and conduction aphasia.<sup>11</sup> Only 5 studies reported length of hospital stay, which ranged between 6 and 20 days. The mortality rate was 7.69%. There was one reported fatality in the acute postoperative period.<sup>16</sup> This patient experienced excessive blood loss, coagulopathy, and eventually cardiac failure.

## DISCUSSION

The overall results from the systematic review suggest that while DIC is a major complication of pediatric scoliosis surgery, it is a very rare outcome. Of the 803 studies investigated, only 13 cases of DIC were identified. Although the incidence of reported cases is low, DIC can lead to serious morbidity and mortality given the often large amount of blood loss sustained during these surgeries. With a mortality rate of 7.69%, coagulopathies such as DIC are severe complications that can potentially be avoided if better understood.

Our review suggests multiple etiologies for post-surgical DIC including coagulopathy after reinfusion of intraoperatively retrieved blood,<sup>9,13</sup> infection



from transfusion,<sup>7</sup> rhabdomyolysis,<sup>14</sup> application of hemostatic matrix,<sup>12</sup> heparin use,<sup>6</sup> and hypovolemic shock.<sup>11</sup> However, the causes of DIC were unknown in 4 cases.<sup>6,8,16</sup> Given that DIC is likely an underreported complication, it is possible that actual incidence of DIC may be even greater.

Spinal surgery is essentially a traumatic event for the patient. As in cranial trauma, endothelial damage and tissue injury likely trigger intravascular coagulation by pathological activation of the hemostatic system.<sup>15</sup> One of the early signs noticed in 8 of the patients was increased surgical site bleeding during the procedure. Activation of the cascade can occur in many ways. In Canbay et al,<sup>14</sup> the patient experienced lower extremity muscle spasms causing rhabdomyolysis after myelography was performed. The activation of the coagulation cascade most likely occurred due to the release of necrotic components of muscle tissue.<sup>17</sup> Similar pathology can also be implied in the cases where hypotension and shock occurred. In Benavidas et al,<sup>7</sup> the patient went into shock after an infected preoperative blood donation. The sample was taken 3 days prior to symptoms of a low grade gastrointestinal infection and was subsequently contaminated with *Y enterocolitica* causing transient bacteremia. In this case, the endotoxin production caused the rapid turn of events and could have been prevented by closely monitoring the patient after transfusion.

In the 3 patients who underwent DIC after receiving preoperatively donated red blood cell infusion, cell damage triggering coagulation occurred due to inadequate wash cycle and vigorous suction from the surgical field.<sup>9,13</sup> This may lead to an increase in procoagulation elements and put the patient at risk.<sup>18</sup> When hemostatic matrix agents are used in surgery, as in Ferschl et al,<sup>12</sup> precaution should be taken to prevent introduction into intravascular spaces to prevent pathway activation.<sup>19</sup> In addition, patients with neuromuscular scoliosis are up to 7 times more likely to experience excess intraoperative blood loss during the procedure vs those with idiopathic scoliosis.<sup>16</sup>

Patients with a neoplasm, as in Ogura et al,<sup>11</sup> are also at an increased risk due to the procoagulatory properties of tumors. As in Gabos et al,<sup>10</sup> it is also important to be aware of possible heparin-induced thrombocytopenia-associated DIC when heparin is used to treat a deep vein thrombosis.<sup>20</sup> The remaining cases in this study represent the challenge of finding a true cause for DIC. As for the one fatal case of DIC, any insinuating factor also remains unknown.<sup>16</sup>

This is a distinctive study because it analyzes the various aspects of this serious complication in the pediatric population. For example, our findings were consistent with those of a study of 36,335 pediatric patients from the National Inpatient Sample.<sup>21</sup> According to De la Garza Ramos et al,<sup>21</sup> DIC is a rare complication of surgery for adolescent idiopathic scoliosis with an incidence of 0.18%. However, unlike our study, this study did not report on the causes of DIC among their patients. It also did not report on the perioperative conditions and postoperative outcomes. These factors, if included, would have offered greater insight into the complexity of DIC.

DIC is a rare, but possible life-threatening complication of pediatric spinal surgery for scoliosis. Being able to prevent the causes and identify the signs and symptoms of DIC can protect these patients from death, end-organ damage, and other long-term complications. This study is the largest known systematic review of the literature on this topic. It also sheds light on the limited amount of high level evidence available in the literature suggesting more attention should be paid to this issue.

This study has a few limitations that are inherent to systematic reviews. The main limitation of this systematic review is the quality of the included studies because multiple case reports were used to obtain the information we reported. In addition, many of the studies included in the review are becoming outdated and include procedures that are no longer regularly performed. Moreover, the sample size of this review was small; only 13 patients from 11 studies were included. Therefore, national studies are needed for a larger sample size and better understanding of the outcomes of DIC in pediatric patients undergoing scoliosis surgery. Another reason for our low sample size may be due to the underreporting of DIC as a complication of pediatric scoliosis surgery. DIC is often unrecognized and can be difficult to diagnose.<sup>22</sup> Although this paper reported perioperative conditions, it did not report long-term postoperative outcomes. Long-term prospective studies can also be carried out to note the incidence of DIC in these patients as well. Furthermore, these 2 kinds of studies could possibly make clearer the causes of this complication and give new insight into the precautions needed to prevent DIC in new patients. Further studies are required to estimate the true incidence, as this study potentially only included publication of severe cases and case series with major events during hospital courses. This may underestimate negative or minor occurrences, which may not have been formally written up or published.

## CONCLUSION

Overall, this systematic review illustrates that DIC is a rare and dangerous complication of pediatric scoliosis surgery. Although only 13 patients were identified in the literature up until July 2017, the mortality rate is astoundingly high at 7.69%. Furthermore, 3 of these patients had unknown causes for their DIC. Therefore, even though the incidence of reported cases is low in the pediatric population, there is still room to improve outcomes by preventing this complication from occurring. This can be done by elucidating the causes of DIC in future cases and identifying risk factors that may predispose patients to this condition.

## ACKNOWLEDGMENTS

The authors received no input from pharmaceutical companies, industry, or individuals.

## REFERENCES

1. Levi M, Ten Cate H. Disseminated intravascular coagulation. *N Engl J Med*. 1999;341(8):586–592. doi:10.1056/NEJM199908193410807
2. Ho PK, Thong LWW C. Disseminated intravascular coagulation. *Curr Opin Hematol*. 1995;2(5):402–406. doi:10.1182/asheducation-2009.1.240
3. Levi M, de Jonge E, van der Poll T. Plasma and plasma components in the management of disseminated intravascular coagulation. *Best Pract Res Clin Haematol*. 2006;19(1):127–142. doi:10.1016/j.beha.2005.01.027
4. Hassmann GC, Keim HA. Disseminated intravascular coagulation (DIC) in orthopedic surgery. Case report and review of literature. *Clin Orthop Relat Res*. 1974;(103):118–132. doi:10.1097/00003086-197409000-00070
5. Miner ME, Kaufman HH, Graham SH, Haar FH, Gildenberg PL, Miner ME. Disseminated intravascular coagulation fibrinolytic syndrome following head injury in children: frequency and prognostic implications. *J Pediatr*. 1982;100(5):687–691. doi:10.1016/s0022-3476(82)80565-9
6. Raphael BG, Lackner H, Engler GL. Disseminated intravascular coagulation during surgery for scoliosis. *Clin Orthop Relat Res*. 1982;(162):41–46.
7. Benavides S, Nicol K, Koranyi K, Nahata MC. Yersinia septic shock following an autologous transfusion in a pediatric patient. *Transfus Apher Sci*. 2003;28(1):19–23. doi:10.1016/S1473-0502(02)00096-4
8. Chechik O, Fishkin M, Wientroub S, Ovadia D. A new pelvic rod system for the surgical correction and fixation of pelvic obliquity in pediatric neuromuscular scoliosis. *J Child Orthop*. 2011;5(1):41–48. doi:10.1007/s11832-010-0318-y
9. Murray DJ, Gress K, Weinstein SL. Coagulopathy after reinfusion of autologous scavenged red blood cells. *Anesth Analg*. 1992;75(1):125–129. doi:10.1213/0000539-199207000-00024
10. Gabos PG, Inan M, Thacker M, Borkhu B. Spinal fusion for scoliosis in rett syndrome with an emphasis on early postoperative complications. *Spine (Phila Pa 1976)*. 2012;37(2):E90–4. doi:10.1097/BRS.0b013e3182404698
11. Ogura Y, Watanabe K, Hosogane N, et al. Severe progressive scoliosis due to huge subcutaneous cavernous hemangioma: a case report. *Scoliosis*. 2011;6:3. doi:10.1186/1748-7161-6-3
12. Ferschl MB, Rollins MD. Thromboemboli, acute right heart failure and disseminated intravascular coagulation after intraoperative application of a topical hemostatic matrix. *Anesth Analg*. 2009;108(2):434–436. doi:10.1213/ane.0b013e31818d3f48
13. McKie JS, Herzenberg JE. Coagulopathy complicating intraoperative blood salvage in a patient who had idiopathic scoliosis. A case report. *J Bone Joint Surg Am*. 1997;79(9):1391–1394. doi:10.2106/00004623-199709000-00014
14. Canbay O, Bal N, Akinci S, Kanbak M, Aypar U, et al. Rhabdomyolysis after intraoperative myelography. *Paediatr Anaesth*. 2004;14(6):509–513. doi:10.1111/j.1460-9592.2004.01215.x
15. Clark JA, Finelli RE, Netsky MG. Disseminated intravascular coagulation following cranial trauma. Case report. *J Neurosurg*. 1980;52(2):266–269. doi:10.3171/jns.1980.52.2.0266
16. Master DL, Son-Hing JP, Poe-Kochert C, Armstrong DG, Thompson GH. Risk factors for major complications after surgery for neuromuscular scoliosis. *Spine (Phila Pa 1976)*. 2011;36(7):564–571. doi:10.1097/BRS.0b013e3181e193e9
17. Zutt R, van der Kooij AJ, Linthorst GE, Wanders RJA, de Visser M. Rhabdomyolysis: review of the literature. *Neuromuscul Disord*. 2014;24(8):651–659. doi:10.1016/j.nmd.2014.05.005
18. König G, Yazer MH, Waters JH. The effect of salvaged blood on coagulation function as measured by thromboelastography. *Transfusion*. 2013;53(6):1235–1239. doi:10.1111/j.1537-2995.2012.03884.x
19. Fiss I, Danne M, Stendel R. Use of gelatin-thrombin matrix hemostatic sealant in cranial neurosurgery. *Neurol Med Chir (Tokyo)*. 2007;47(10):462–467. doi:10.2176/nmc.47.462
20. Selleng K, Warkentin TE, Greinacher A. Heparin-induced thrombocytopenia in intensive care patients. *Crit Care Med*. 2007;35(4):1165–1176. doi:10.1097/01.CCM.0000259538.02375.A5
21. De la Garza Ramos R, Goodwin CR, Abu-Bonsrah N, et al. Patient and operative factors associated with complications following adolescent idiopathic scoliosis surgery: an analysis of 36,335 patients from the nationwide inpatient sample. *J Neurosurg Pediatr*. 2016;25(6):730–736. doi:10.3171/2016.6.PEDS16200
22. Wada H, Matsumoto T, Yamashita Y. Diagnosis and treatment of disseminated intravascular coagulation (DIC) according to four DIC guidelines. *J Intensive Care*. 2014;2(1):15. doi:10.1186/2052-0492-2-15

**Funding:** The author(s) received no financial support for the research, authorship, and/or publication of this article.

## Declaration of Conflicting Interests:

There are no conflicts of interest directly related to this paper. Author 9 is a consultant for, or has received institutional or research support from, Sage Products LLC. Author 12 is a consultant for, or has received institutional or research support from, Cervical Scoliosis Research Society, Medicea, and Zimmer. Author 13 is a consultant for, or has received institutional or

research support from, DePuy, Johnson & Johnson, and Medtronic. Author 15 is a consultant for, or has received institutional or research support from, DePuy Synthes. The remaining authors have no conflicts of interest.

**Corresponding Author:** Bassel G. Diebo, Orthopaedic Surgery Resident, SUNY Downstate Medical Center, 450 Clarkson Ave., Box #30,

Brooklyn, NY 11203, USA; dr.basseldiebo@gmail.com

This manuscript is generously published free of charge by ISASS, the International Society for the Advancement of Spine Surgery. Copyright © 2022 ISASS. To see more or order reprints or permissions, see <http://ijssurgery.com>.