

Prevalence and Modes of Posterior Hardware Failure With a Staged Protocol for Circumferential Minimally Invasive Surgical Correction of Adult Spinal Deformity: A 13-Year Experience

Neel Anand, Andrew Chung, Christopher Kong, Alisa Alayan, Babak Khandehroo, Sheila Kahwaty and David Gendelberg

Int J Spine Surg 2022, 16 (3) 481-489

doi: <https://doi.org/10.14444/8256>

<https://www.ijssurgery.com/content/16/3/481>

This information is current as of May 17, 2025.

Email Alerts Receive free email-alerts when new articles cite this article. Sign up at:
<http://ijssurgery.com/alerts>

Prevalence and Modes of Posterior Hardware Failure With a Staged Protocol for Circumferential Minimally Invasive Surgical Correction of Adult Spinal Deformity: A 13-Year Experience

NEEL ANAND, MD¹; ANDREW CHUNG, DO²; CHRISTOPHER KONG, MD¹; ALISA ALAYAN, MD¹;
BABAK KHANDEHROO, MD¹; SHEILA KAHWATY, PA-C¹; AND DAVID GENDELBERG, MD¹

¹Department of Orthopedics, Cedars-Sinai Spine Center, Los Angeles, CA, USA; ²Sonoran Spine Institute, Tempe, AZ, USA

ABSTRACT

Background: One of the common complications of adult spinal deformity (ASD) correction is the failure to relieve pain. This may result from the failure of implanted hardware to provide adequate stabilization. While numerous studies exist, characterizing complications that can occur with minimally invasive correction of ASD and data regarding hardware failure in this setting are limited.

Objective: This article characterizes the rate and mode of posterior hardware failure in the setting of circumferential minimally invasive surgery (CMIS) for ASD correction.

Methods: Patients undergoing staged CMIS correction of ASD from January 2007 to September 2018 were identified. Patients with a minimum 2-year follow-up were included in the study.

Result: A total of 263 patients (168 women and 95 men) were included in the study. The mean age of patients was 64 years (21–85, SD 13.7), and the mean length of follow-up was 90 months (24–164, SD 40.2). An average of 6 levels (3–16, SD 3.15) was fused per patient.

Eight patients had a mechanical hardware failure and required revision surgery (3.04%). No catastrophic failures were noted in our series. Hardware failures were characterized as follows: 2 patients with broken screws, 5 patients with loose screws, and 1 patient who had symptomatic T12-L1 and L5-S1 nonunion with bilateral distal rod fractures, iliac set screw loosening, and proximal T12 screw loosening. Following revision surgery, all of these patients had confirmed solid fusion on computed tomography (CT) scan at their latest follow-up visit.

Interestingly, 3 other patients had loosening of the set screw on their iliac bolts. Five patients had rod fractures between L5 and S1 or below S1. All 8 of these patients were asymptomatic with confirmed fusion at L5-S1 on CT scans.

Conclusion: The prevalence of clinically significant hardware failure needing revision in our series was low at 3.04%. Symptomatic hardware prominence requiring revision was 2.3%. Specifically, rod fractures were not common (2.2%). Our study suggests that in the appropriately selected patient, CMIS to correct ASD without osteotomies may result in acceptable rates of hardware failure. Future studies should compare the results of CMIS deformity correction to a matched population of patients undergoing open deformity correction.

Clinical Relevance: This study suggests that in the appropriately selected patient, CMIS to correct ASD without osteotomies may result in acceptable rates of hardware failure.

Level of Evidence: 4.

Minimally Invasive Surgery

Keywords: spinal deformity, adult, minimally invasive, hardware, failure

INTRODUCTION

Recent estimates place the prevalence of adult spinal deformity (ASD) at upward of 60%. While only a small proportion of these individuals ultimately become symptomatic, associated pain may be quite severe,^{1,2} resulting in significant dysfunction and debility.³ Subsequently, ASD has been associated with very poor health-related quality of life measures.^{1,4} With an aging population and with spinal fusions becoming

more commonplace, the burden of ASD on our society appears to be only increasing.

Fortunately, ASD correction has been proven to substantially improve outcomes in well-selected patients.^{2,5} However, traditional open deformity corrective surgery comes with a high cost of potential morbidity with rates of all-cause complications as high as 86%^{6–8} and a rate of major complications of up to 18.5%.⁶ Notably, the rate of postoperative hardware failure can also be quite

high and is now a leading cause of revision surgery in this patient population.⁹ Rod fractures alone have an incidence of 18.4% in this surgical setting¹⁰ with even higher rates noted in patients undergoing 3-column osteotomies.¹¹

Consequently, in the past decade, minimally invasive techniques have been incorporated into the surgical management of spinal deformity as a potential mitigation strategy for these obstacles. While supportive data are somewhat limited, the results published to date have nonetheless been quite favorable. Minimally invasive surgery (MIS) for deformity correction has been associated with decreased blood loss,¹²⁻¹⁸ potentially quicker operative times,^{13,14} and shorter hospital lengths of stay.^{14,18} Furthermore, all-cause complications may additionally be less frequent with circumferential minimally invasive surgery (CMIS) for deformity correction.^{15,17,19,20}

Failure of implanted hardware to provide adequate stabilization is a potential source of significant postoperative debility,¹⁰ and despite emerging data supporting the clinical efficacy of CMIS, the rate of hardware failure in this patient population has not been well defined.²¹ Thus, the purpose of this study was to characterize the rate and mode of posterior hardware failure in patients undergoing CMIS for ASD correction.

MATERIAL AND METHODS

Patient Data

This was a retrospective review of a prospectively collected data registry of 358 patients who underwent CMIS correction of ASD from January 2007 to September 2018. ASD was defined utilizing the following parameters: a Cobb angle >20 or sagittal vertical axis (SVA) >50 mm or a pelvic incidence/lumbar lordosis (LL) mismatch >10°. Of the patients identified, 281 patients had undergone CMIS correction of ASD at 3 or more levels for severe back pain with or without radicular pain that had been recalcitrant to extensive conservative management for at least 6 months. Only patients with a minimum clinical and radiographic follow-up of 2 years were included in the analysis ($N = 263$). Informed consent was obtained from all patients. Institutional Review Board approval from Cedars Sinai was obtained for this study (IRB no. Pro00015483).

All patient demographic information was collected. Patient comorbidities were additionally noted. Radiographic parameters including thoracic kyphosis, LL, pelvic tilt, PI, SVA, and coronal balance were measured preoperatively, 3 months postoperatively, and at

latest follow-up utilizing full-length 36" standing films. PI-LL was additionally calculated off preoperative and postoperative images. Postoperatively, any hardware-related complications including loosening, fracture of instrumentation, or symptomatic hardware were noted based on detailed review of each postoperative radiograph and/or computed tomography (CT) image, which was routinely performed from 2011 at 18 months to 2 years to assess fusion. All patients with radiographic evidence of hardware failure had a CT image to assess for underlying fusion.

Patient-reported outcome measures including the visual analog score, treatment intensity score,²² Oswestry Disability Index, Short Form-36 survey, and the Scoliosis Research Society-22 item survey were collected preoperatively, at 1 year, and at latest follow-up.

CMIS Protocol

The CMIS protocol and its evolution over time have previously been described²³ and are outlined here. Under the CMIS protocol, patients with identified ASD underwent 2-staged deformity correction with an intervening 3-day interval. The old protocol was executed as follows: **Stage 1**, multilevel lateral lumbar interbody fusions and **Stage 2**, axial lumbar interbody fusion (AxialIF) at L5-S1 as needed with subsequent MIS posterior pedicle screw fixation with rod contouring and derotation/translation. The new protocol was instituted in May 2011 and was executed accordingly: **Stage 1**, multilevel oblique lateral lumbar interbody fusion and MIS L5-S1 oblique lumbar interbody fusion (OLIF) or anterior lumbar interbody fusion (ALIF) and **Stage 2**, MIS pedicle screws with rod contouring and derotation/translation. For both protocols, 5.5-mm titanium alloy rods were utilized. Posterior segmental "pars-facet-pars" fusions were done at those segments that did not have an interbody fusion. These were usually proximal to the L1-L2 segment. No patient had any facet resection or any grade of posterior column osteotomy or an anterior column realignment procedure other than at L5-S1 where an ALIF would require release of the anterior longitudinal ligament.

On postoperative day 2 following Stage 1, a standing radiograph was obtained, and patients were subsequently mobilized. Any persistence of radicular pain or neurogenic claudication was noted during this time, and sagittal alignment was reassessed using plain radiography. These data were then utilized to plan for the second stage accordingly including the need for additional posterior decompression, if needed. After Stage 1, only 4

Table 1. Clinical and functional outcomes.

Outcome Measure	Mean (SD) (Range)				P Value
	Preoperative	6 wk	1 y	Latest Follow-Up	
Visual analog scale	6.3 (2.2) (2–10)	4.1 (2.3) (0–9)	3.2 (2.7) (0–8)	2.5 (2.8) (0–6.5)	<0.05
Treatment intensity score	49.8 (22.5) (0–100)	36.9 (23.9) (0–96)	30.4 (27.3) (0–90)	31.4 (21.5) (0–75)	<0.05
Oswestry Disability Index	43.3 (17) (0–82)	38.2 (22.2) (0–88)	26.9 (20.2) (0–73)	32 (21.9) (0–84)	<0.05
Short Form-36 survey	55.8 (30.4) (2–141)	63.5 (33.3) (8–150)	79.3 (37) (7–157)	85.8 (43.8) (8–168)	<0.05
Scoliosis Research Society 22-item survey	2.86 (0.6) (1.2–4.5)	3.3 (0.8) (1.4–4.5)	3.8 (0.8) (1.8–4.9)	3.7 (0.8) (2.1–5)	<0.05

Note: P values reflect difference between preoperative and last follow-up values.

patients needed a posterior microdecompression due to persistent radiculopathy.

Also, as part of the protocol, all patients had magnetic resonance imaging besides full-length standing radiographs preoperatively. The feasibility of CMIS techniques was assessed by studying anatomical corridors and vascular anatomy. CT was performed if any doubt exists of a segmental fusion or facet fusion. Dual-energy x-ray absorptiometry was also performed to document bone density. If the dual-energy x-ray absorptiometry T score was less than 3.0, minimally invasive surgical correction was deferred. If T score was between 2.0 and 3.0, daily injection of teriparatide (Forteo) was recommended and continued for 1 year after surgery.

Statistical Analysis

Descriptive statistics were calculated with SDs and ranges. Patient characteristics for both groups were analyzed using χ^2 and student *t* tests. A χ^2 test was used for categorical variables, and an independent student *t* test was used to assess continuous variables. A P value of <0.05 was set as our measure of statistical significance.

RESULTS

Patient Data

A total of 281 patients met the criteria to be included in this study. A total of 263 patients (168 women and 95 men) were available for review with minimum 2-year follow-up. The mean age of patients undergoing CMIS for spinal deformity correction was 64 years (SD 13.7).

The mean length of follow-up was 90 months (SD 38.2). A total of 1686 levels were fused with an average of 6 levels fused (SD 3.1) per patient. Mean body mass index was 27 kg/m² (SD 5.9). Patient clinical and radiographic outcomes are noted in Tables 1 and 2, respectively.

Hardware Failure

A total of 8 patients had mechanical hardware failure requiring revision surgery (3.04%). No catastrophic failures were noted in our series. Of the 8 patients with hardware failure, 4 were women and 4 were men. Hardware failures were characterized as follows: 2 patients with broken screws, 5 patients with loose screws, and 1 other patient who had symptomatic T12- L1 and L5-S1 nonunion with bilateral distal rod fractures, iliac set screw loosening, and proximal T12 screw loosening. Following revision surgery, all of these patients had confirmed solid fusion on CT scan by their latest follow-up visit.

Interestingly, 3 other patients had set screw loosening of their iliac bolts (Figures 1 and 2). Five patients had rod fractures between L5 and S1 or below S1 (Figures 3 and 4). All 8 of these patients were asymptomatic with confirmed fusion at L5-S1 on CT scans. No catastrophic failures were noted (Table 3).

From a temporal standpoint, rod fractures were detected at varying times with 5 of the 6 patients totally asymptomatic and showing solid fusion on CT scan (Table 4). Six other patients had symptomatic hardware prominence that

Table 2. Radiographic outcomes.

Outcome Measure	Mean (SD) (Range)				P Value
	Preoperative	1-y Postoperative	Last Follow-Up	(Last Follow-Up) – (Preoperative)	
Cobb angle	31.1 (14.5) (15.2–74.7)	13.9 (8.9) (0–48.3)	12.1 (9.1) (0–49.7)	18.9 (9.8) (0.94–62.1)	<0.05
Lumbar lordosis	41 (16.3) (2.4–84.3)	46.7 (11.4) (10.8–88.2)	48.1 (11.2) (18.3–75.8)	10.2 (9.1) (0.12–43.8)	<0.05
Pelvic incidence/lumbar lordosis mismatch	18.6 (12.3) (0.3–60.9)	11.5 (8.1) (0.1–37.2)	11.7 (7.5) (0–29.6)	10.5 (9.3) (0.05–44)	<0.05
Sagittal vertical axis	64.1 (54.5) (9.5–267)	39.5 (31.4) (0–163)	39.1 (30.2) (0–125.5)	36.8 (35.7) (0.51–192.2)	<0.05

Note: P values reflect difference between preoperative and last follow-up values.

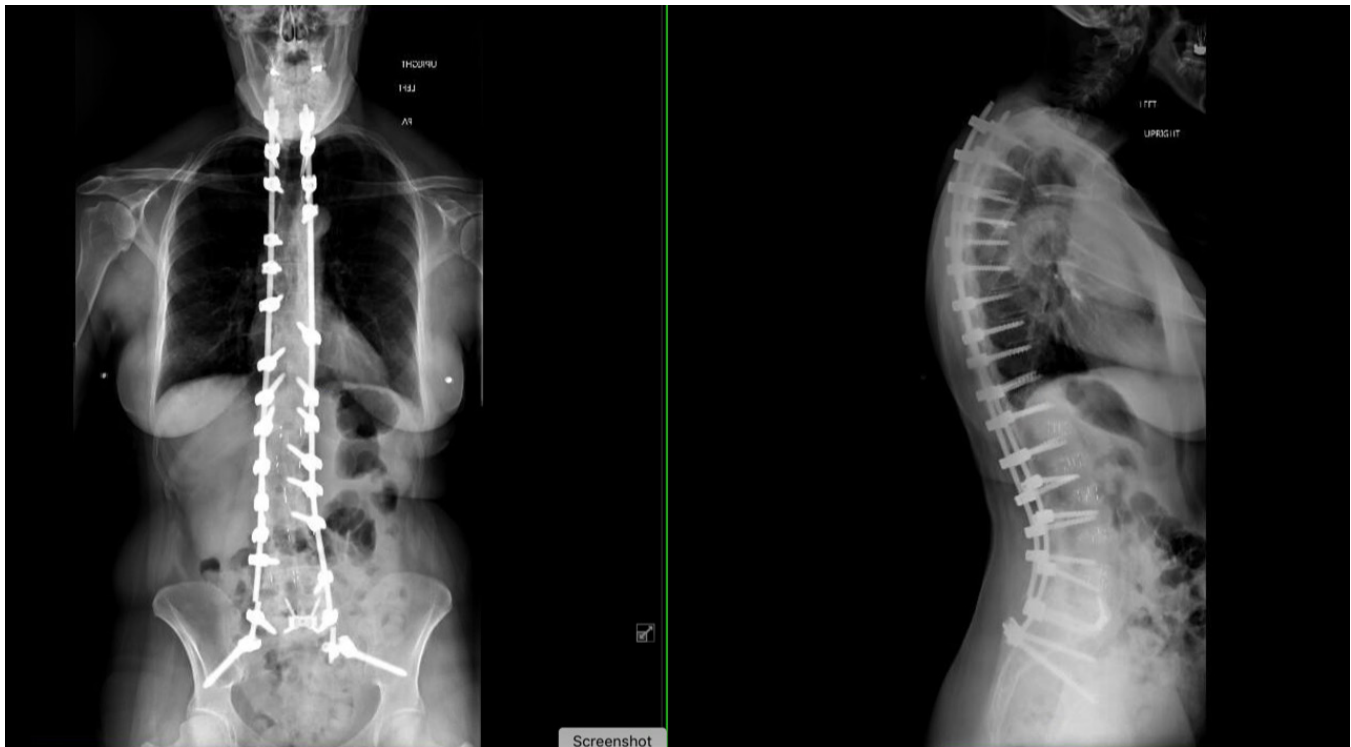

Figure 1. Anterior-posterior and lateral scoliosis films demonstrate rod fracture between L5 and S1, and below S1.

did need revision surgery. A further 5 patients had malpositioned screws that needed revision.

Of the 263 patients in the study, 8 had an lowest instrumented vertebra between T10 and T12, 4 between L1 and L3, 11 at L4, 63 at L5, and 177 at S1. Of 177 patients who had fusions spanning L5-S1, 70 had iliac screw fixation and 107 did not (Table 5). Of patients fused to the ilium,

the mean number of levels fused was 9 levels (4–16). For those not fused to the ilium, the mean number of levels fused was 6 levels (3–15). Of patients not fused to L5-S1, there were only 3 hardware failures.

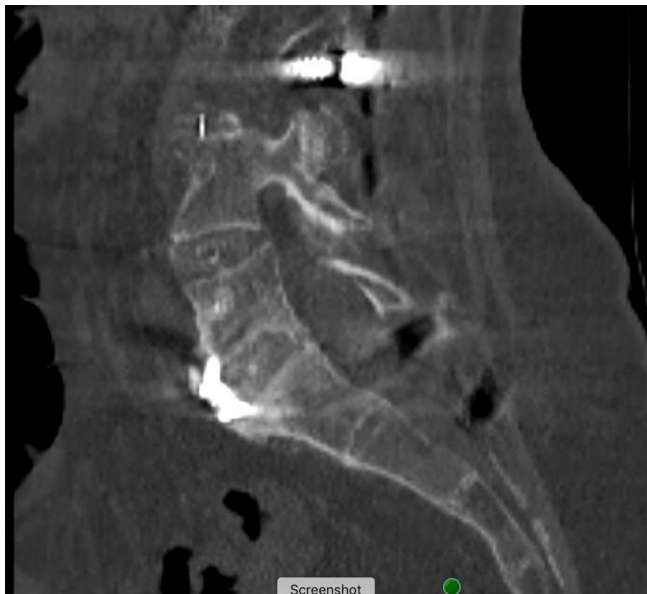


Figure 2. Corresponding sagittal computed tomography image demonstrates fusion at L5-S1.

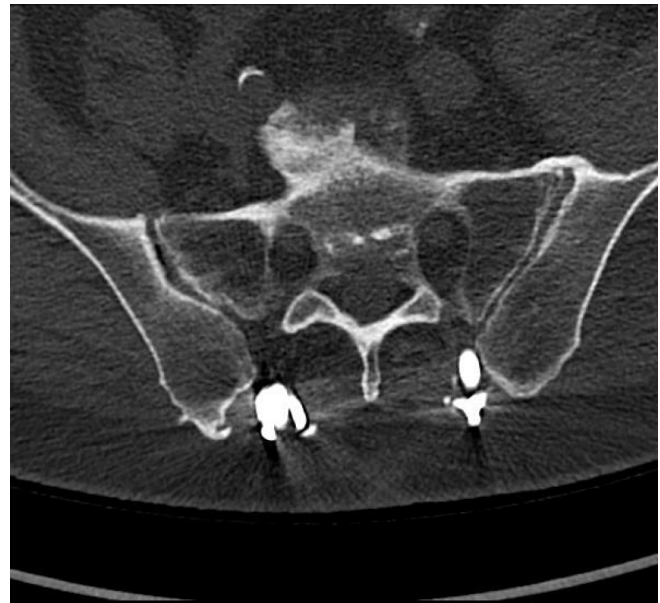

Figure 3. Axial computed tomography image demonstrating absence of set screw in right iliac screw.

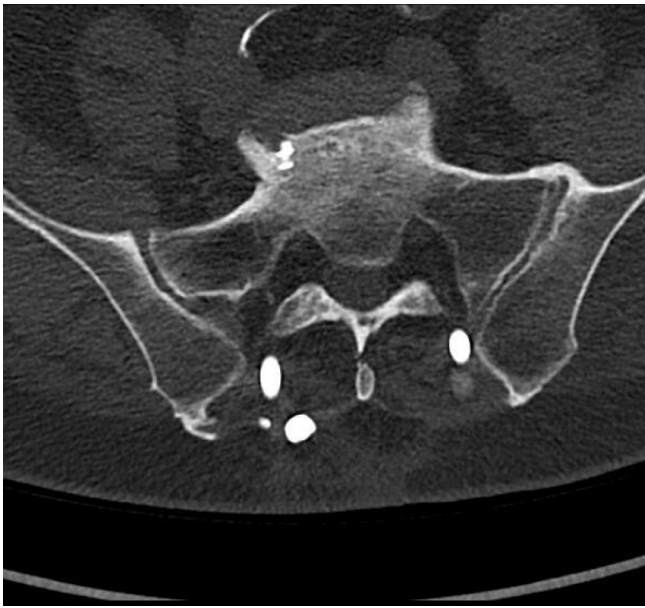

Figure 4. Axial computed tomography image demonstrating corresponding loosened set screw of empty iliac screw seen in Figure 3.

Lumbosacral Fusion

There were 56 patients who had an AxiaLIF at L5-S1. There were 47 patients with ALIF at L5-S1 and 74 patients with OLIF at L5-S1. Out of all 23 hardware failures, 3 of the hardware failures occurred in 3 patients undergoing AxiaLIF (2 with sacral screw loosening and 1 proximal hardware prominence). The failure rate of the AxiaLIF fixation screw has been previously reported, and we have strongly recommended in prior publications not to use AxiaLIF as a means of stabilizing L5-S1 in the setting of a spinal deformity. We have not used AxiaLIF in our protocol since 2011.²⁴⁻²⁶

DISCUSSION

A common complication following ASD correction is the failure of implanted hardware to provide adequate stabilization, which in turn is a source of significant postoperative morbidity and a common reason

for revision surgery.¹⁰ While hardware failure in open surgical correction for ASD has been relatively well characterized,^{10,11,27} similar data in the setting of CMIS for ASD correction remain significantly limited. In our series, we found that with use of CMIS for ASD, the rate of all comers of hardware failure including hardware prominence was 8.7%. However, only 5.3% of patients required surgery. Excluding prominent symptomatic hardware, symptomatic mechanical hardware failure rate was 3.0%. This is in stark contrast to the high rates of hardware failure that have been cited in the setting of open deformity correction.^{10,11,27}

Rod fracture has been cited as one of the most common reasons for revision spinal deformity surgery.¹⁰ Utilizing traditional open deformity corrective techniques, rates of rod fracture may approach 18.4%.^{10,11,27} With use of 3-column osteotomies, rates of rod fracture may be much higher (31.7%).¹¹ In our series, the prevalence of actual rod fracture was quite low with only 6 patients of 263 experiencing the complication (2.2%). There may be several explanations for this. First, with the CMIS protocol, the use of multi-level interbody cages enables load sharing, and the use of ligamentotaxis enables creation of a physiological and harmonious restoration of LL. This minimizes the need for hyperacute bends in the rod, which have been linked to higher rates of rod failure.²⁸ The lack of anterior column support around oft-used osteotomies in the setting of open deformity may also contribute to fatigue failure of rods in this setting.²⁹ In comparison with our staged protocol for CMIS deformity correction, robust anterior column support and the absence of posterior-based osteotomies mitigate this latter risk. Additionally, staged correction with interval re-evaluation of sagittal alignment may allow for more optimal fine-tuning of sagittal parameters potentially further mitigating risk of overcorrection and early hardware failure.²³ An important aspect of our technique is that rod contouring is smooth and graduated and only done in the sagittal plane. No coronal bends or in situ contouring, other than distally to seat the rod in the iliac screw, are created. Furthermore, bone density is an integral part of our preoperative workup before embarking on CMIS correction of ASD, and this may also explain the low hardware failure rate.³⁰

Most importantly, all of the above collectively may explain the paradox of only a 2.2% rod fracture rate despite universal use of 5.5-mm titanium alloy rods. The latter has been associated with higher rates of fatigue failure in open spinal deformity correction.^{29,31,32} Rod fractures in our series only occurred distally, either

Table 3. Hardware failure (21 patients)—2-y follow-up.

Mode of Failure	n	Women	Men
Broken screw	2	1	1
Screw loosening	5	3	2
Symptomatic hardware prominence	6	4	2
Set Screw loosening	4 ^a	2	2
Rod fractures ^c	6 ^b	4	2
Total	23	14	9

^aThree of the set screw loosening were asymptomatic. No revision required.

^bFive rod fractures were asymptomatic with solid fusion on computed tomography scan. No revision.

^cOne male patient had symptomatic T12-L1 and L5-S1 nonunion with bilateral distal rod fractures, iliac set screw loosening, and proximal T12 screw loosening.

Table 4. Rod fractures.

Laterality and Details	Fused? ^a	Revision?	Occurrence (mo)
Left sided below S1, right sided between L5 and S1	Yes	No	55
Left sided below S1, right sided between L5 and S1	Yes	No	58
Left sided between L5 and S1	Yes	No	13
Left sided between L5 and S1	Yes	No	3
Left sided below S1, L5 facet fractures	Yes	No	31
Left below L5, right below S1 ^b	No	Yes	36

^aConfirmed fusion at L5-S1 on computed tomography image.

^bOne male patient with symptomatic L5-S1 nonunion with bilateral rod fractures.

between L5 and S1 or below S1. In order to seat the rod into the iliac screw in some patients, the use of in situ bending distal to the S1 screw was utilized. The focal hyperacute bend in the rod likely served as a localized stress riser leading to fatigue failure of the rod.²⁸ Also noted in 4 patients was iliac bolt set screw loosening. We theorize that this may have been due to the direct inline attachment of the rod to the iliac screw. In this construct, increased repetitive stress at the set screw-rod interface may have caused the screw to slowly back out over time. This is in contrast to the more traditional iliac screw construct, which diffuses the aforementioned mechanical stresses through use of a side connector. Ultimately, while there was initial concern for underlying pseudarthrosis in these latter patients with rod fractures and iliac set screw loosening, 8 of these 9 patients were fortunately asymptomatic and needed no intervention. Furthermore, CT scans confirmed fusion at L5-S1 in all of these patients. Hence, we would caution against routine revision in these patients with set screw loosening or distal rod fractures. Prior publications have suggested that rod failure is associated with poorer health-related quality of life measures.¹⁰ Thus, CMIS may be an effective technique for ASD correction under the appropriate indications.

There were 6 patients with prominent, symptomatic hardware that needed revision (2.2%). Early on in our experience, we inadvertently left pedicle screws slightly prominent to facilitate subfascial passage of the rod. In 2 patients during rod reduction, the proximal screws did

back out. In this setting, several of our very thin patients who were already predisposed to developing symptoms from hardware did develop symptoms.

It is important to note the rationale for transitioning from AxiaLIF to ALIF or OLIF at L5-S1 in our practice. While beyond the scope of this study, we found an unacceptably high number of pseudarthroses in patients undergoing AxiaLIF (6 patients in our series). Furthermore, we found that AxiaLIF was suboptimal at sagittal correction when compared to an ALIF.²⁴ Consequently, we abandoned the use of AxiaLIF, since 2011, in favor of ALIF and OLIF at L5-S1.

The number of available MIS surgical techniques has rapidly expanded over the past 2 decades. As surgeons have become more proficient with these techniques and technology has evolved, there is increasing evidence to support the benefits of MIS procedures when compared to equivalent open procedures. Maximal preservation of native anatomy, decreased blood loss¹²⁻¹⁸ and post-operative pain, shorter hospital lengths of stay,^{14,18} and a quicker return to function have all been attributed to MIS techniques.^{12,33-38} While comparative data of post-operative complications in MIS vs open deformity techniques are still limited, preliminary data suggest that MIS deformity correction may mitigate the high complication rates seen with open surgery.^{15,19} Importantly, these latter benefits may explain why recent studies have even suggested that MIS approaches to deformity correction result in significantly lower costs/hospitalization charges when compared to open approaches.^{12,14}

Table 5. Failures with iliac screw vs no iliac screws.

Mode of Failure	<i>n</i>	Iliac Screw (<i>n</i> = 70)	No Iliac Screw (<i>n</i> = 107)	<i>P</i> Value
Broken screw	2	2	0	0.0701
Screw loosening	5	2	3	0.6114
Symptomatic hardware prominence	6	2	4	0.6584
Set screw loosening	4 ^a	4	0	0.0047
Rod fractures	6 ^b	6	0	0.003
Total	23	16	7	

Note: Boldface indicates statistically significant findings at $P < 0.05$.

^aThree of the set screw loosening were asymptomatic. No revision required.

^bFive rod fractures were asymptomatic with solid fusion on computed tomography image. No revision was needed.

Ultimately, in an increasingly patient centric and cost-conscious environment, as MIS deformity corrective techniques continue to evolve, they may very well represent the future of spinal deformity management.

Limitations

There are some notable limitations with our study. First, although data were pulled from a prospectively collected database, this was nonetheless, a retrospective study and is subject to all the respective inherent limitations. Furthermore, with a low incidence of hardware failure, with inherent categorical heterogeneity further limiting the numbers of each mode of failure, more sophisticated multivariable risk analyses were not feasible. Finally, surgeon selection bias in this particular patient population could have contributed to more optimal results. A criticism often heard is that CMIS correction is only for mild deformities. In our series, 146 (55.5%) patients had severe ASD as categorized by having one of the following (Cobb angle $>50^\circ$ or SVA >95 mm or PI/LL mismatch >20 or pelvic tilt >30).^{39,40} Furthermore, all patients in the cohort, except for those with persistent thoracic kyphosis after first stage or those with upper instrumented vertebra greater than T10 (12 patients), had a physiological harmonious correction of their spinal deformity without any osteotomies. Our alignment goals were also in agreement with published literature on age-adjusted sagittal parameters that above all, aim to optimize patient clinical outcomes.^{41–43} Furthermore, it would have been ideal to compare our results to the results of a propensity-matched cohort of patients with adult deformity treated with open correction techniques. Nonetheless, in spite of these potential limitations, our study is the first of its size to characterize long-term hardware failures in a well-selected cohort of ASD patients undergoing CMIS spinal deformity correction.

CONCLUSION

The prevalence of clinically significant hardware failure needing revision in our series was low at 3.04%. Symptomatic hardware prominence requiring revision was 2.2%. Specifically, rod fractures were not common (2.2%). Our study would suggest that in the appropriately selected patients, CMIS to correct ASD without osteotomies may result in acceptable rates of hardware failure. Future studies should compare the results of CMIS deformity correction to a matched population of patients undergoing open deformity correction.

REFERENCES

1. Ailon T, Scheer JK, Lafage V, et al. Adult spinal deformity surgeons are unable to accurately predict postoperative spinal alignment using clinical judgment alone. *Spine Deform.* 2016;4(4):323–329. doi:10.1016/j.jspd.2016.02.003
2. Liu S, Diebo BG, Henry JK, et al. The benefit of nonoperative treatment for adult spinal deformity: identifying predictors for reaching a minimal clinically important difference. *Spine J.* 2016;16(2):210–218. doi:10.1016/j.spinee.2015.10.043
3. Bess S, Line B, Fu K-M, et al. The health impact of symptomatic adult spinal deformity: comparison of deformity types to United States population norms and chronic diseases. *Spine (Phila Pa 1976).* 2016;41(3):224–233. doi:10.1097/BRS.0000000000001202
4. Riley MS, Bridwell KH, Lenke LG, Dalton J, Kelly MP, et al. Health-related quality of life outcomes in complex adult spinal deformity surgery. *J Neurosurg Spine.* 2018;28(2):194–200. doi:10.3171/2017.6.SPINE17357
5. Transfeldt EE, Topp R, Mehdob AA, Winter RB. Surgical outcomes of decompression, decompression with limited fusion, and decompression with full curve fusion for degenerative scoliosis with radiculopathy. *Spine (Phila Pa 1976).* 2010;35(20):1872–1875. doi:10.1097/BRS.0b013e3181ce63a2
6. Sciubba DM, Yurter A, Smith JS, et al. A comprehensive review of complication rates after surgery for adult deformity: a reference for informed consent. *Spine Deform.* 2015;3(6):575–594. doi:10.1016/j.jspd.2015.04.005
7. Yeramaneeni S, Robinson C, Hostin R. Impact of spine surgery complications on costs associated with management of adult spinal deformity. *Curr Rev Musculoskelet Med.* 2016;9(3):327–332. doi:10.1007/s12178-016-9352-9
8. Smith JS, Shaffrey CI, Klineberg E, et al. Complication rates associated with 3-column osteotomy in 82 adult spinal deformity patients: retrospective review of a prospectively collected multicenter consecutive series with 2-year follow-up. *J Neurosurg Spine.* 2017;27(4):444–457. doi:10.3171/2016.10.SPINE16849
9. Passias PG, Soroceanu A, Yang S, et al. Predictors of revision surgical procedure excluding wound complications in adult spinal deformity and impact on patient-reported outcomes and satisfaction. *J Bone Joint Surg Am.* 2016;98(7):536–543. doi:10.2106/JBJS.14.01126
10. Lertudomphonwanit T, Kelly MP, Bridwell KH, et al. Rod fracture in adult spinal deformity surgery fused to the sacrum: prevalence, risk factors, and impact on health-related quality of life in 526 patients. *Spine J.* 2018;18(9):1612–1624. doi:10.1016/j.spinee.2018.02.008
11. Smith JS, Shaffrey E, Klineberg E, et al. Prospective multicenter assessment of risk factors for rod fracture following surgery for adult spinal deformity. *J Neurosurg Spine.* 2014;21(6):994–1003. doi:10.3171/2014.9.SPINE131176
12. Swamy G, Lopatina E, Thomas KC, Marshall DA, Johal HS, et al. The cost effectiveness of minimally invasive spine surgery in the treatment of adult degenerative scoliosis: a comparison of transpoas and open techniques. *Spine J.* 2019;19(2):339–348. doi:10.1016/j.spinee.2018.05.040
13. Than KD, Mummaneni PV, Bridges KJ, et al. Complication rates associated with open versus percutaneous pedicle screw instrumentation among patients undergoing minimally invasive interbody fusion for adult spinal deformity. *Neurosurg Focus.* 2017;43(6):E7. doi:10.3171/2017.8.FOCUS17479

14. Uddin OM, Haque R, Sugrue PA, et al. Cost minimization in treatment of adult degenerative scoliosis. *J Neurosurg Spine*. 2015;23(6):798–806. doi:10.3171/2015.3.SPINE14560
15. Than KD, Park P, Tran S, et al. Analysis of complications with staged surgery for less invasive treatment of adult spinal deformity. *World Neurosurg*. 2019;126:e1337–e1342. doi:10.1016/j.wneu.2019.03.090
16. Chou D, Mummaneni P, Anand N, et al. Treatment of the fractional curve of adult scoliosis with circumferential minimally invasive surgery versus traditional, open surgery: an analysis of surgical outcomes. *Global Spine J*. 2018;8(8):827–833. doi:10.1177/2192568218775069
17. Chou D, Mundis G, Wang M, et al. Minimally invasive surgery for mild-to-moderate adult spinal deformities: impact on intensive care unit and hospital stay. *World Neurosurg*. 2019;127:e649–e655. doi:10.1016/j.wneu.2019.03.237
18. Uribe JS, Beckman J, Mummaneni PV, et al. Does MIS surgery allow for shorter constructs in the surgical treatment of adult spinal deformity? *Neurosurgery*. 2017;80(3):489–497. doi:10.1093/neuros/nyw072
19. Anand N, Sardar ZM, Simmonds A, Khandehroo B, Kahwaty S, Baron EM, et al. Thirty-day reoperation and readmission rates after correction of adult spinal deformity via circumferential minimally invasive surgery-analysis of a 7-year experience. *Spine Deform*. 2016;4(1):78–83. doi:10.1016/j.jspd.2015.08.002
20. Anand N, Cohen JE, Cohen RB, Khandehroo B, Kahwaty S, Baron E, et al. Comparison of a newer versus older protocol for circumferential minimally invasive surgical (CMIS) correction of adult spinal deformity (ASD)-evolution over a 10-year experience. *Spine Deform*. 2017;5(3):213–223. doi:10.1016/j.jspd.2016.12.005
21. Godzik J, Haglin JM, Alan N, et al. Retrospective multi-center assessment of rod fracture after anterior column realignment in minimally invasive adult spinal deformity correction. *World Neurosurg*. 2019;130:e400–e405. doi:10.1016/j.wneu.2019.06.096
22. Anand N, Hamilton JF, Perri B, Miraliakbar H, Goldstein T, et al. Cantilever TLIF with structural allograft and RhBMP2 for correction and maintenance of segmental sagittal lordosis: long-term clinical, radiographic, and functional outcome. *Spine (Phila Pa 1976)*. 2006;31(20):E748–53. doi:10.1097/01.brs.0000240211.23617.ae
23. Anand N, Kong C, Fessler RG. A staged protocol for circumferential minimally invasive surgical correction of adult spinal deformity. *Neurosurgery*. 2017;81(5):733–739. doi:10.1093/neuros/nyx353
24. Anand N, Alayan A, Cohen J, Cohen R, Khandehroo B, et al. Clinical and radiologic fate of the lumbosacral junction after anterior lumbar interbody fusion versus axial lumbar interbody fusion at the bottom of a long construct in CMIS treatment of adult spinal deformity. *J Am Acad Orthop Surg Glob Res Rev*. 2018;2(10):e067. doi:10.5435/JAAOSGlobal-D-18-00067
25. Anand N, Alayan A, Agrawal A, Kahwaty S, Nomoto E, Khandehroo B, et al. Analysis of spino-pelvic parameters and segmental lordosis with L5-S1 oblique lateral interbody fusion at the bottom of a long construct in circumferential minimally invasive surgical correction of adult spinal deformity. *World Neurosurg*. 2019;130:e1077–e1083. doi:10.1016/j.wneu.2019.07.091
26. Schmidt FA, Wong T, Chidambaram S, Kirnaz S, Anand N, Roger H. FAANS The Rise and Fall of a Surgical Technique: AxialLIF. date unknown.
27. Smith JS, Shaffrey CI, Ames CP, et al. Assessment of symptomatic rod fracture after posterior instrumented fusion for adult spinal deformity. *Neurosurgery*. 2012;71(4):862–867. doi:10.1227/NEU.0b013e3182672aab
28. Tang JA, Leasure JM, Smith JS, Buckley JM, Kondrashov D, Ames CP, et al. Effect of severity of rod contour on posterior rod failure in the setting of lumbar pedicle subtraction osteotomy (PSO): a biomechanical study. *Neurosurgery*. 2013;72(2):276–282. doi:10.1227/NEU.0b013e31827ba066
29. Januszewski J, Beckman JM, Harris JE, Turner AW, Yen CP, Uribe JS, et al. Biomechanical study of rod stress after pedicle subtraction osteotomy versus anterior column reconstruction: a finite element study. *Surg Neurol Int*. 2017;8:207. doi:10.4103/sni.sni_44_17
30. Gupta A, Cha T, Schwab J, et al. Osteoporosis increases the likelihood of revision surgery following a long spinal fusion for adult spinal deformity. *Spine J*. 2021;21(1):134–140. doi:10.1016/j.spinee.2020.08.002
31. Han S, Hyun S-J, Kim K-J, Jahng T-A, Lee S, Rhim S-C, et al. Rod stiffness as a risk factor of proximal junctional kyphosis after adult spinal deformity surgery: comparative study between cobalt chrome multiple-rod constructs and titanium alloy two-rod constructs. *Spine J*. 2017;17(7):962–968. doi:10.1016/j.spinee.2017.02.005
32. Shinohara K, Takigawa T, Tanaka M, et al. Implant failure of titanium versus cobalt-chromium growing rods in early-onset scoliosis. *Spine (Phila Pa 1976)*. 2016;41(6):502–507. doi:10.1097/BRS.0000000000001267
33. Allen RT, Garfin SR. The economics of minimally invasive spine surgery: the value perspective. *Spine (Phila Pa 1976)*. 2010;35(26 Suppl):S375–82. doi:10.1097/BRS.0b013e31820238d9
34. Avila MJ, Walter CM, Baaj AA. Outcomes and complications of minimally invasive surgery of the lumbar spine in the elderly. *Cureus*. 2016;8(3):e519. doi:10.7759/cureus.519
35. Alimi M, Hofstetter CP, Pyo SY, Paulo D, Härtl R, et al. Minimally invasive laminectomy for lumbar spinal stenosis in patients with and without preoperative spondylolisthesis: clinical outcome and reoperation rates. *J Neurosurg Spine*. 2015;22(4):339–352. doi:10.3171/2014.11.SPINE13597
36. Al-Khouja LT, Baron EM, Johnson JP, Kim TT, Drazin D, et al. Cost-effectiveness analysis in minimally invasive spine surgery. *Neurosurg Focus*. 2014;36(6):E4. doi:10.3171/2014.4.FOCUS1449
37. Parker SL, Adogwa O, Witham TF, Aaronson OS, Cheng J, McGirt MJ, et al. Post-operative infection after minimally invasive versus open transforaminal lumbar interbody fusion (TLIF): literature review and cost analysis. *Minim Invasive Neurosurg*. 2011;54(1):33–37. doi:10.1055/s-0030-1269904
38. Phan K, Hogan JA, Mobbs RJ. Cost-utility of minimally invasive versus open transforaminal lumbar interbody fusion: systematic review and economic evaluation. *Eur Spine J*. 2015;24(11):2503–2513. doi:10.1007/s00586-015-4126-4
39. Slattery C, Verma K. Classification in brief: SRS-schwab classification of adult spinal deformity. *Clin Orthop Relat Res*. 2018;476(9):1890–1894. doi:10.1007/s11999.0000000000000264
40. Terran J, Schwab F, Shaffrey CI, et al. The SRS-Schwab adult spinal deformity classification: assessment and clinical correlations based on a prospective operative and nonoperative cohort. *Neurosurgery*. 2013;73(4):559–568. doi:10.1227/NEU.0000000000000012
41. Protosaltis TS, Soroceanu A, Tishelman JC, et al. Should sagittal spinal alignment targets for adult spinal

deformity correction depend on pelvic incidence and age? *Spine (Phila Pa 1976)*. 2020;45(4):250–257. doi:10.1097/BRS.0000000000003237

42. Park P, Okonkwo DO, Nguyen S, et al. Can a minimal clinically important difference be achieved in elderly patients with adult spinal deformity who undergo minimally invasive spinal surgery? *World Neurosurg*. 2016;86:168–172. doi:10.1016/j.wneu.2015.09.072

43. Park P, Fu K-M, Eastlack RK, et al. Is achieving optimal spinopelvic parameters necessary to obtain substantial clinical benefit? An analysis of patients who underwent circumferential minimally invasive surgery or hybrid surgery with open posterior instrumentation. *J Neurosurg*. 2019;30(6):833–838. doi:10.3171/2018.11.SPINE181261

Funding: The authors received no financial support for the research, authorship, and/or publication of this article.

Disclosures: Neel Anand reports consulting fees from Medtronic and Depuy-Synthes; royalties from

Medtronic, Globus Medical, and Elsevier; and stocks/stock options in Paradigm Spine, Theracell, Spinal Balance, Spinal Simplicity, Viseon, Bonovo, Globus Medical, all outside of the submitted work. The remaining authors have no disclosures.

IRB Approval: Hospital IRB approval was received for this study.

Corresponding Author: Andrew Chung, Sonoran Spine Institute, 1255 W Rio Salado Pkwy #107, Tempe, AZ 85281, USA; asc@sonoranspine.com

Published 14 June 2022

This manuscript is generously published free of charge by ISASS, the International Society for the Advancement of Spine Surgery. Copyright © 2022 ISASS. To see more or order reprints or permissions, see <http://ijssurgery.com>.