

Seizure-Induced Spinal Fractures: A Systematic Review

Luis A. Robles and Amancio Guerrero-Maldonado

Int J Spine Surg 2022, 16 (3) 521-529

doi: <https://doi.org/10.14444/8244>

<https://www.ijssurgery.com/content/16/3/521>

This information is current as of May 17, 2025.

Email Alerts Receive free email-alerts when new articles cite this article. Sign up at:
<http://ijssurgery.com/alerts>

Seizure-Induced Spinal Fractures: A Systematic Review

LUIS A. ROBLES, MD¹ AND AMANCIO GUERRERO-MALDONADO, MD²

¹Section of Neurosurgery, Hospital Joya, Puerto Vallarta, Jalisco, Mexico; ²Department of Neurosurgery, Centro de Especialidades Médicas, Celaya, Guanajuato, México

ABSTRACT

Background: Patients with epilepsy have a higher risk of skeletal injuries, and some of these fractures occur in the spine during a seizure. Seizure-induced spinal fractures (SISF) are unusual injuries that typically occur in the thoracolumbar spine. Because these skeletal injuries are not well described in the literature, this article aims to analyze the characteristics of this uncommon clinical entity.

Methods: A PubMed and Scopus search adhering to preferred reporting items for systematic reviews and meta-analyses guidelines was performed to include studies reporting patients with SISF. The data gathered from this review were analyzed to characterize this condition.

Results: The search yielded 34 articles with a total of 38 patients with SISF. All studies were case reports (level 5 evidence). Most fractures occurred in the thoracic and lumbar spine, and the most common injuries were type A1 and A4 fractures according to the AO spine classification system. Different characteristics of SISF are described including demographics, clinical findings, imaging, and treatment.

Conclusions: SISF should be ruled out in patients who have a recent history of seizures and who report persistent dorsolumbar pain or neurological deficit. SISF usually occurs in the thoracolumbar spine and less frequently in the cervical spine. This review shows that different patterns of neurological deficits, some of them severe, may occur in approximately a quarter of patients with SISF.

Clinical Relevance: This study provides awareness of an uncommon spine condition. Physicians should suspect SISF in patients with persistent dorsolumbar pain after a seizure.

Lumbar Spine

Keywords: seizure-induced spinal fractures, spinal fractures related to convulsions, vertebral compression fractures, fractures related to seizures, fractures related to epilepsy

INTRODUCTION

Patients with epilepsy are prone to multiple types of bone fractures.^{1,2} These injuries can occur either directly as a result of the violent force of a seizure or may occur secondary to falling at the time of the episode. A wide variety of fractures and dislocations have been described associated with convulsive events. Seizures mainly induce fractures of the humerus, scapula, hip, and spine. Previous studies showed that the incidence of fractures after seizures was 0.3%,³ and the incidence of spinal fractures induced by seizures was 0.04%.¹

Seizure-induced spinal fractures (SISF) are not well described in the literature; thus, our goal was to describe the characteristics of this uncommon condition.

METHODS

Study Selection

A comprehensive literature search of PubMed and Scopus was performed in accordance with preferred reporting items for systematic reviews and meta-analyses guidelines. Also, a search was performed on Google scholar to identify articles not reported in

PubMed or Scopus. The search for publications was undertaken using the following keywords: “seizure-induced spine fractures,” “seizure-induced vertebral fractures,” “convulsion spine fracture,” and “spine fracture related to seizure.” The search extended to all available English language articles from 1970 to February 2021. Articles were reviewed by 2 of the study authors (L.A.R. and A.G.M.), who performed title and abstract reviews separately. Titles and abstracts were initially reviewed to identify articles with positive exclusion criteria. For those abstracts that met the inclusion criteria, the full text was retrieved and reviewed by the authors. Furthermore, the references for all search-selected manuscripts were also reviewed for potential cases.

Inclusion and Exclusion Criteria

Cases were included in the final review only if patients had SISF corroborated by radiographic studies and the article showed adequate clinical and radiological information. The following articles were excluded: literature reviews, animal studies, correspondence or letters, articles not available in full text, articles reporting different pathologies to SISF, vertebral fractures not

related to seizures, and articles with incomplete clinical information.

Data Extraction

The following data were extracted from eligible cases: (1) age and gender, (2) symptoms, (3) cause of seizures, (4) previous use of antiepileptic drugs, (5) number of seizures previous to fracture, (6) location of spinal fracture, (7) time from fracture to diagnosis, (8) presence of osteoporosis, (9) associated conditions or injuries, (10) treatment, and (11) outcome.

Radiological studies were analyzed to confirm the presence of SISF. Imaging methods included x-ray, computed tomography, and magnetic resonance images. Descriptions of thoracolumbar fractures were made according to the AO spine injury classification system.⁴

The presence of bone density anomalies was sought in patients who underwent a bone density test, especially dual-energy x-ray absorptiometry (DEXA). Osteopenia was considered when the *T* score was between -1.0 and -2.5 , and osteoporosis was diagnosed when the *T* score was -2.5 or below.

RESULTS

The initial literature search yielded 134 articles. Nine articles reporting cases included for analysis were obtained from Google scholar. After the removal of duplicates, the title and abstract of 119 articles were screened and, based on exclusion criteria, 74 articles were eliminated. After this initial filter, 45 articles were assessed for eligibility, of which 11 were excluded for different reasons. Thus, 34 studies with a total of 38 patients were eligible for analysis (Figure 1). The Table shows the characteristics of these 38 patients with SISFs who were identified from previous publications.^{1,5-37} All included articles were case reports, and according to the Oxford Center for Evidence-Based Medicine table, they were labeled as level V studies. Not all articles provided information about each item; therefore, a comparative analysis was limited by the nature of the source data. Statistical analysis was not conducted for this review because comparative analyses could not be performed.

Patient Demographics

The youngest patient was 11 years old, and the oldest was 75 years old. The average age was 40 years. Fifty-five percent of cases occurred among individuals in the fourth and fifth decades of life. Seventy-three percent of patients were men.

Clinical Manifestations

The most common symptom observed was local pain depending on the fracture's location. Local pain was observed in every patient with cervical and thoracolumbar fractures. Twenty-six percent of patients experienced a motor deficit in the lower limbs, and some of them presented with cauda equina syndrome.

Causes of Seizures

The most common cause of seizures in these patients was idiopathic epilepsy; less common causes of seizures were brain tumors, medication overdoses, and others.

Location and Type of Fractures

The most common type of fractures was A1 and A4. SISF may be observed on any level of the thoracolumbar spine, being L1 and L2 the most common sites of injury. In 4 patients, the fracture was located in the cervical spine.

Bone Density Status

DEXA was performed in only 10 patients (26%) in this study. The presence of osteoporosis, osteopenia, and normal results was equally distributed in these cases.

Treatment and Outcome

All patients who manifested with only local pain achieved a good outcome, regardless if they were treated with surgery or conservatively. Treatment was tailored according to the severity of the fracture, wedge-compression fractures were treated conservatively, and burst fractures were usually treated with surgery. All patients with cervical fractures were treated with surgery. Patients with motor deficits showed partial improvement at follow-up.

DISCUSSION

Epileptic seizures are relatively common, affecting approximately 0.2%–0.5% of the general population.²¹ Bone fractures in epileptic patients may be related to trauma either induced directly by a convulsion or resulting from a fall or other accident resulting from the seizure. In the absence of external trauma, it is reported that the mechanism of vertebral fracture is by the powerful contraction of the paraspinal muscles during a seizure.

This study presents a comprehensive systematic review of patients with SISF. In the following

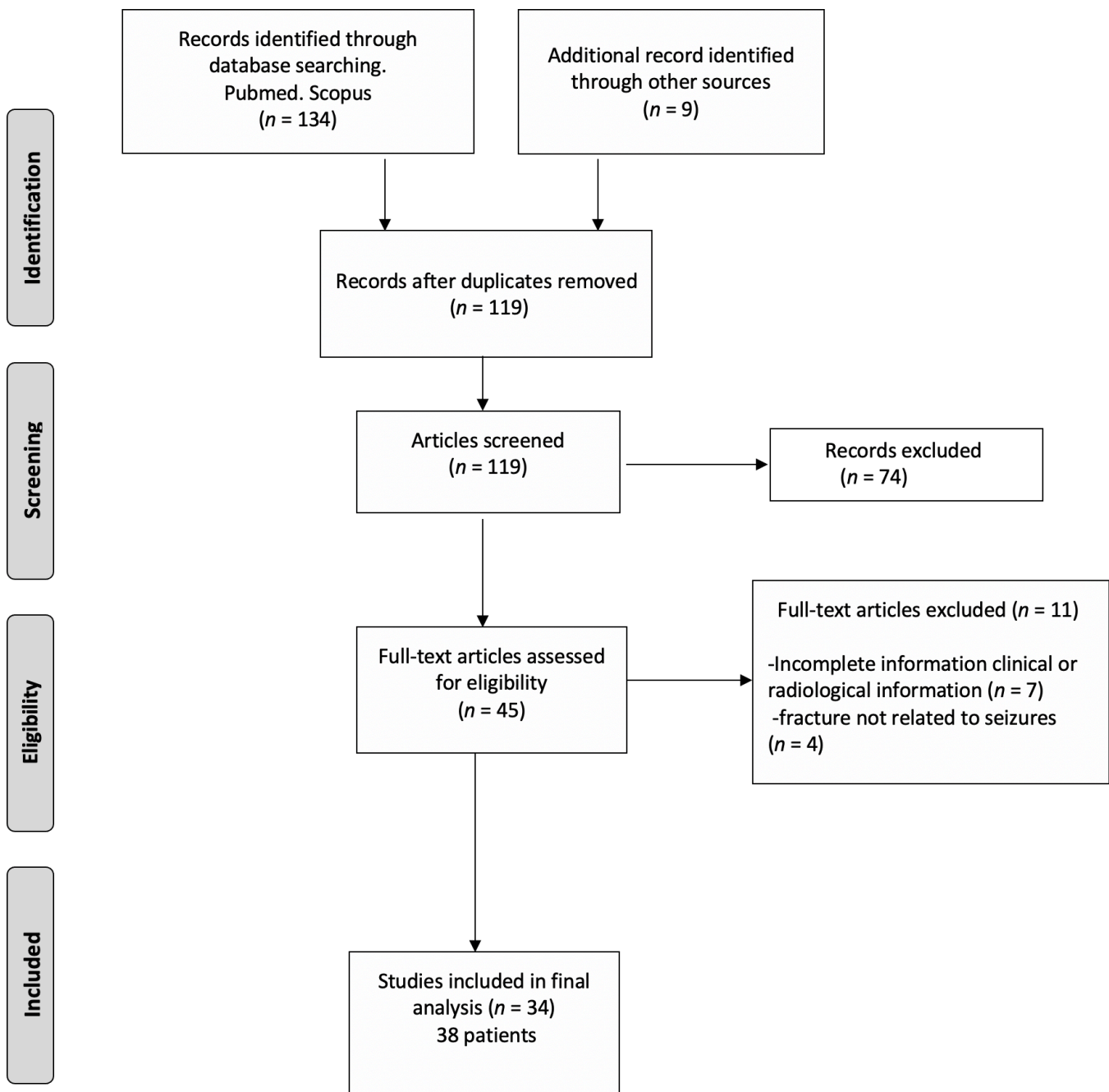


Figure 1. Flow chart of the literature search strategy and article selection for screening and analysis.

paragraphs, data obtained from this review and other sources are summarized to describe the characteristics observed in patients with SISF.

Demographics

Previous studies showed an incidence of 0.3% of skeletal fractures in cases of tonic-clonic seizures and an incidence of 0.04% of spinal fractures.¹ Literature suggests that SISF may be underreported, especially those patients with mild or minimal symptoms.

A previous study reported that a rate of 15% of vertebral compression fractures in epileptic patients with no history of trauma or back pain.² In this review, it was observed that SISF may occur at any age and for unknown reasons, a 3:1 ratio favoring men was observed. There was a variety of causes of seizures in this study, with idiopathic epilepsy the most common cause, followed by medication overdose, brain tumors, hypoglycemia, and others.

Table. Summary of patients with seizure-induced spinal fractures.

Author, Year	Age, y (Sex)	Symptoms	Cause of Seizures	Epilepsy Treatment	Number Seizures	Level of Spine	AO Fracture Type	Evolution Time	Dual-Energy X-ray Absorptiometry	Associated Conditions	Treatment	Outcome
Lim & Shim, 2021 ²¹	50 (M)	LBP Paraparesis	Hepatic cirrhosis	No	Multiple	L2	A4	1 d	Osteoporosis	Encephalopathy	360° T2-L4 stabilization	Partial recovery
Bosco et al, 2020 ³⁶	52 (M)	LBP Paraparesis	Idiopathic	No	1	L1	Burst A4	4 mo	No	No	T11-L3 instrumentation	Complete recovery
Robichaud et al, 2020 ⁵	71 (M)	LBP Paraparesis	Intracranial meningioma	No	1	L1	Burst A4	1 wk	No	Intracranial meningioma	Laminectomies T11-L3	Partial recovery
Case 1	53 (M)	LBP Interscapular pain	Idiopathic	No	1	L1	Burst A4	NA	No	Scapular fractures	Decompression T11-L3 stabilization	Partial recovery
Case 2	49 (M)	Neck pain	Idiopathic	No	Multiple	T4	A1	1 d	No	Scapular fractures	Conservative	Complete recovery
Grzonka et al, 2019 ⁶	47 (F)	Neck pain	Elastic seizure	Carbamazepine + lamotrigine	NA	C2	Hangman type II	1 wk	No	NA	Occipitocervical fusion	Complete recovery
Hurley et al, 2017 ⁷	44 (F)	Dorsal pain	Venlafaxine overdose	No	1	T8	Burst A4	1 wk	No	Depression	T7-T11 stabilization	Complete recovery
Smith et al, 2017 ⁸	28 (M)	Dorsal pain	Idiopathic epilepsy	Lamotrigine 1 y	1	T6-T7	A1	10 d	Normal	No	Conservative analgesics	Complete recovery
Stilwell et al, 2016 ⁹	61 (F)	Dorsal pain	NA	No	Multiple	T6	T6 burst A4 L5 A1	2 d	No	Sternal fracture, bilateral humerus fractures, femur fracture	T4-T8 stabilization Lumbar conservative	Complete recovery
Moscote-Salazar et al, 2015 ¹¹	46 (M)	LBP Dorsal pain	NA	NA	NA	L2	A2	2 d	No	No	Posterior fusion	Complete recovery
Atalar et al, 2015 ¹²	49 (M)	Dorsal pain	Idiopathic, first seizure	No	1	T5-T8	A1	1 d	Osteoporosis	Type 1 diabetes	Conservative brace	Complete recovery
Ali et al, 2015 ¹³	52 (M)	LBP Dorsal pain	Brain tumor	No	NA	L3	A2	3 d	No	Shoulders dislocation	Conservative	NA
Uvaraj et al, 2014 ¹⁴	18 (M)	LBP Dorsal pain	Idiopathic	No	1	T5-T8	A1	11 mo	No	No	Brace, conservative	Complete recovery
Majkowska et al, 2014 ¹⁵	21 (F)	LBP	Hypoglycemia	No	1	T12	A4	11 mo	Osteopenia	Type 1 diabetes	Surgery stabilization	NA
Ghayem	42 (M)	LBP	NA	NA	1	L2-3-4	A1	NA	Normal	No	Brace, conservative	Complete recovery
Hasankhani et al, 2013 ¹⁶	20 (M)	LBP Hypoesthesia lower limbs	Tramadol overdose	No	1	T12	Burst A4	1 wk	No	No	T10-L2 stabilization	Complete recovery
Rahimiza-deh et al, 2012 ¹⁷	35 (F)	LBP	Idiopathic epilepsy	No	1	T12	Burst A4	2 d	No	No	Stabilization T11-L1	NA
Alian, 2011 ¹⁸	42 (F)	LBP	Hypoglycemia	No	1	L2	Burst A3	5 d	No	Diabetes	Brace, conservative	Complete recovery
Malik et al, 2011 ¹⁹	36 (M)	LBP Cauda equina syndrome	Idiopathic epilepsy	Phenytoin	1	L1 L2	Burst A4 A1	1 d	No	Humeral fracture	Surgery (no specified)	Partial recovery
Sharma et al, 2011 ²⁰	28 (M)	LBP Paraplegia	Idiopathic epilepsy	NA	Multiple	L1	Burst A4	1 d	No	No	Stabilization T12-L2 Laminectomy	Partial recovery
Napier and Nolan, 2011 ²¹	62 (F)	LBP	Idiopathic	No	1	L1	Burst A4	3 wk	No	Rheumatoid arthritis	L1 corpectomy Stabilization	Complete recovery
Is et al, 2009 ²²	11 (M)	Dorsal pain	Isoniazid intoxication	No	Multiple	T5	Burst A3	1 d	Normal	No	Conservative brace	Complete recovery
Kalaci et al, 2008 ²³	45 (M)	LBP	Idiopathic epilepsy	No	1	L2 L4	A2 A4	1 d	Osteopenia	No	L1-L5 stabilization	NA
Mehlhorn et al, 2007 ²⁴	29 (M)	LBP Paraparesis	Brain tumor	No	1	L2-L3	Burst A3	1 d	Osteoporosis	Shoulder dislocation	Anterior L2-4 stabilization	Complete recovery
Shin et al, 2007 ²⁵	34 (F)	LBP	Brain tumor	No	1	L2	Burst A3	1 d	Osteopenia	No	Conservative	Complete recovery
Case 1	35 (M)	Cauda equina syndrome	Unknown cause	No	1	L1	Burst A3	2 d	No	No	L1-3 stabilization	Complete recovery
Case 2	42 (M)	Dorsal pain	Unknown	No	1	T6-7-8	A1	NA	No	Dislocation shoulders	Conservative	NA
Roohi and Fox, 2006 ²⁶	26 (M)	Dorsal pain	First seizure	No	1	T5-6	A1	1 d	No	History of lupus Steroids use	Kyphoplasty	Complete recovery
Perry and Atkinson, 2006 ²⁷	34 (M)	Dorsal pain	Idiopathic epilepsy	Multiple drugs	1	T6-7	T6 A1 T7 A4	2 wk	Normal	No	Corpectomy stabilization T5-8	Complete recovery
Gnaanalin-gham et al, 2004 ²⁸	34 (M)	Dorsal pain	Idiopathic epilepsy	Multiple drugs	1	T6-7	T6 A1 T7 A4	2 wk	Normal	No	Corpectomy stabilization T5-8	Complete recovery
Takahashi et al, 2002 ²⁵	34 (M)	Dorsal pain	Idiopathic epilepsy	Multiple drugs	1	T6-7	T6 A1 T7 A4	2 wk	Normal	No	Corpectomy stabilization T5-8	Complete recovery

Table. Continued.

Author, Year	Age, y (Sex)	Symptoms	Cause of Seizures	Epilepsy Treatment	Number Seizures	Level of Spine	AO Fracture Type	Evolution Time	Dual-Energy X-ray Absorptiometry		Associated Conditions	Treatment	Outcome
									Absorptiometry	Evolution Time			
Torreggiani et al, 2001 ³⁰	75 (MF)	Neck pain	Idiopathic epilepsy	NA	1	C2 dens fracture	Type 2 odontoid fracture	1 d	No	No		Anterior C2 screw	Partial recovery
Kumar and Freeman, 1999 ³¹	44 (M) 34 (M)	Neck pain Quadriplegia	Idiopathic epilepsy	Phenytoin valproate	NA	C3-4 C3	C1 fracture C3-4 listhesis C3 Canal narrowing	1 d 1 d	No No	No		360 Stabilization Laminectomy	Partial recovery Partial recovery
Case 1		Neck pain	Idiopathic epilepsy	Phenytoin	Multiple								
Case 2		Quadripareisis											
Aboukasm and Smith, 1997 ³²	21 (M) 36 (M)	Dorsal pain Dorsal pain	Idiopathic epilepsy Idiopathic epilepsy	No No	1 1	T7-8-9 T5-6	A1 A1	1 wk 1 d	No No	No		Conservative Conservative	NA NA
Case 1													
Case 2													
Youssef et al, 1995 ³³	35 (M)	LBP	Clonazepam use	No	1	L1-L2	L1 A4 L2 A1 T7 A4	5 d	No	No	schizophrenia	Surgery Stabilization	Complete recovery
McCullen and Brown, 1994 ¹	41 (F)	Dorsal pain	Amoxapine intoxication	No	1	T6-T8	T7 A4	1 wk	No	No	Humeral fracture	Anterior corpectomy T7 stabilization T4-10 posterior	Complete recovery
Gräbe, 1988 ³⁴	39 (M)	LBP	NA	No	1	L5-S1	Lumbosacral dislocation	NA	No	No		Anterior lumbosacral fusion	Complete recovery
Nabarro, 1985 ³⁵	48 (M)	Dorsal pain	Hypoglycemia	No	1	T3-T4	A1	1 d	No	No		Conservative	NA

Abbreviations: LBP, low back pain; NA, not available.

Clinical Presentation

The most common clinical manifestation observed in this review was local pain in the area of the fractured vertebra, which is why radiological studies were indicated in these patients. Continuous local pain at the fractured spinal site was observed in each case in this review. The presence of neurological deficit has been reported in a few cases of SISF. In this review, almost 30% of patients experienced some type of neurological deficit, including sensory deficit, cauda equina syndrome, paraparesis, quadriparesis, paraplegia, and quadriplegia. As expected, patients with more severe fractures were those who presented with neurological manifestations.

Most patients were diagnosed with SISF on the same day of the epileptic event; however, in some patients, the diagnosis of the fracture occurred in a delayed fashion. In some cases, when the seizure was unwitnessed, especially during the night, the presence of continuous and unexplained local pain was the motive to order imaging tests and diagnose these injuries. In this study, SISF occurred after a single convulsive event in 85% of cases, and the fracture was related to multiple seizures in 15% of cases.

Location and Type of SISF

The most common location of SISF reported in the literature is the upper and midthoracic spine.²⁹ During a seizure, the muscles of the neck, abdomen, pelvis, and back contract violently. During contraction of the muscles, these forces are concentrated along the anterior and middle columns of the midthoracic kyphotic curve; thus, these injuries are more frequent in this area.¹

In this review, the most common site of SISF was observed in the upper lumbar spine (L1-L3), occurring in 50% of cases. Fractures located in the midthoracic region (T5-T8) were the second most common location and were present in 35% of patients. Fractures located in different areas of the spine were observed in a lower percentage. In 4 patients, the fracture was located in the cervical spine, including 2 injuries at C2 (odontoid type II and hangman fractures).

Ninety percent of the fractures observed were located in the thoracolumbar spine. All thoracolumbar SISFs reported in this review were compression fractures. Forty-four percent of cases were wedge-compression fractures (A1) and burst fractures (A4), which were observed in 47% of cases. Less common fractures were split fractures (A2) and incomplete burst fractures (A3). Figure 2 shows the frequency of thoracolumbar

fractures observed in this study. Some patients with multiple fractures presented with a different type of fractures at different levels.

The results observed in this review are somewhat different from what has been reported in the literature, where it is mentioned that fractures in the midthoracic spine are the most common site of SISF. This finding may be the result of the fact that compression fractures occurring in the thoracic spine are usually minor, thus leading to underreporting of these injuries.

Presence of Low Bone Density

People with epilepsy have a 2–6 times greater risk of fractures than the general population, with a particularly higher incidence of fractures of the vertebral bodies and femoral neck.³⁸ In recent years, there has been increasing evidence suggesting that epilepsy and its treatment can have adverse effects on bone mineralization and calcium metabolism.³⁹ Different studies have shown a significant reduction in bone mineral density and an increased fracture risk in patients treated with valproate and enzyme-inducing antiepileptics, such as phenobarbital, carbamazepine, and phenytoin.^{39–41} Another study reported that although a deficit in bone mineral density is observed in patients with epilepsy, this is too small to explain the increase in fracture risk observed in these patients, and it was concluded that the increased risk of fractures may be linked to seizures.⁴²

In this review, 82% of patients were not taking anticonvulsants when the vertebral fracture occurred. This finding suggests that the use of these medications likely did not have any influence on the occurrence of SISF. DEXA was performed in only 26% of patients in this review, showing a very similar incidence of findings of osteopenia, osteoporosis, and normal results. Of all patients who showed osteoporosis and osteopenia on DEXA, none of them were taking anticonvulsants. DEXA was performed on only 2 patients who were taking anticonvulsants, and this test was normal in both cases.

Although this is a very low number of patients, these results suggest that the decrease of bone mineral density was not secondary to the use of antiepileptics. However, the presence of low bone density observed in some patients in whom DEXA was performed may indicate that pre-existent low bone density caused by different factors may have had a role in the development of SISF.

Associated Injuries and Conditions

The most common musculoskeletal injuries seen after tonic-clonic seizures include thoracolumbar fractures, humeral head fractures and dislocations, manubriosternal joint disruption, and femoral neck, pelvic, acetabular, and

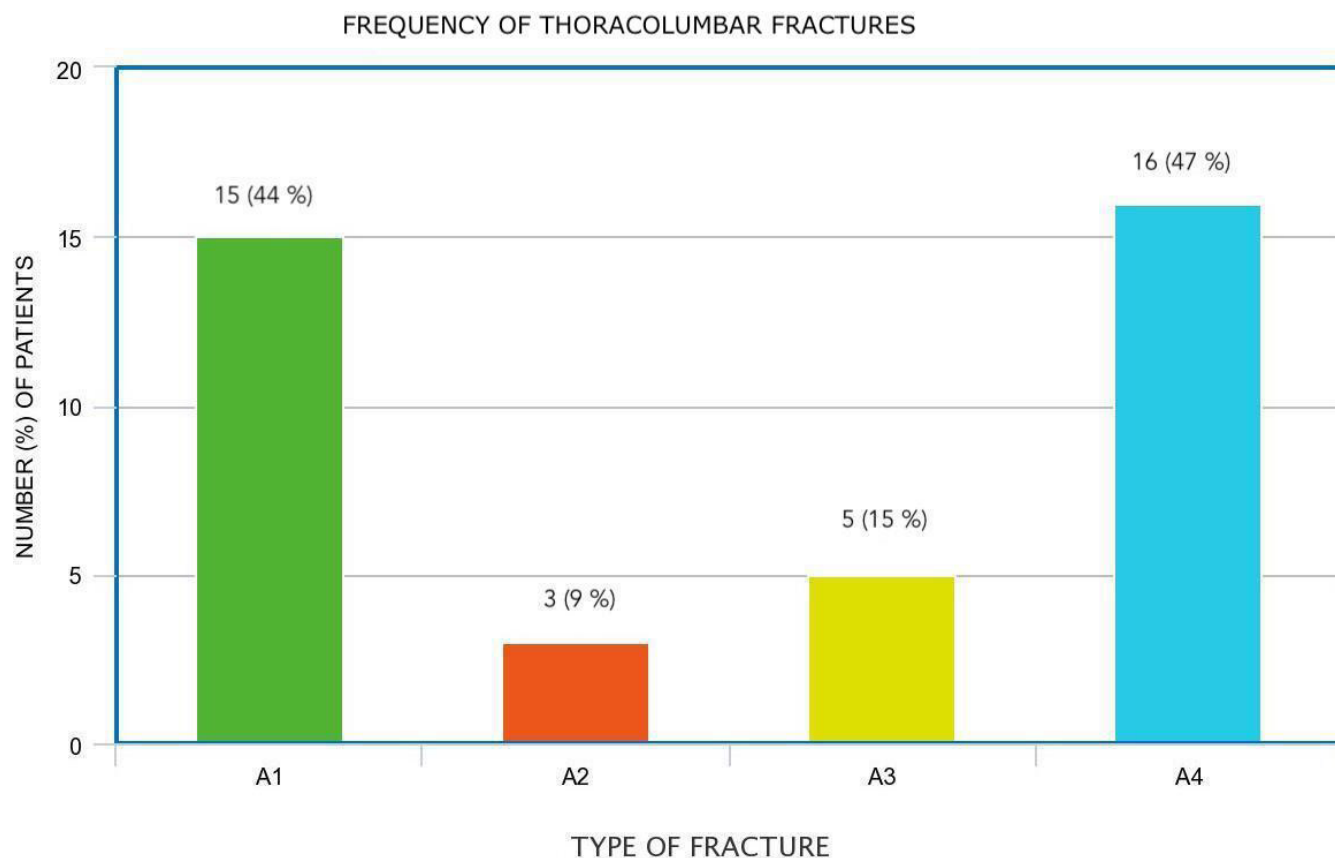


Figure 2. Bar chart showing the frequency of types of thoracolumbar fractures observed in this review. Different fracture patterns were observed in the same patient.

scapular fractures.²⁰ The presence of simultaneous skeletal injuries in different areas is seldom reported in the literature. In this review, almost 20% of patients showed fractures in other anatomic areas, including scapular fractures, humerus fractures, and shoulder dislocation. The patient with more associated fractures experienced a sternal fracture, bilateral humerus fractures, and femur fracture.¹⁰ Other nontraumatic conditions observed in these cases included brain tumors, depression, type 1 diabetes, rheumatoid arthritis, lupus, and schizophrenia.

Treatment and Outcome

The treatment of SISF was based on the characteristics of each fracture. The treatment of these skeletal injuries was basically the same as that used to treat spinal fractures from other causes. In this review, because most patients were collected from case reports, the treatment strategy was carried out according to the preferences of each surgeon and was generally based on the previously established management of spinal fractures.

Depending on the type of cervical injury, these patients were treated with different techniques,

including anterior C2 screw for an odontoid fracture, occipitocervical fusion for a hangman type fracture, and cervical fusion for subaxial injuries.

Most patients with thoracolumbar wedge-compression (A1) fractures were treated conservatively with a brace and medical treatment. Patients with split fractures (A2) were treated either with surgical stabilization or conservative treatment, and surgical treatment included posterior stabilization. Cases of incomplete burst fractures (A3) were treated either with conservative treatment or surgery; surgical stabilization was performed through an anterior approach in these patients. Finally, all patients with burst fractures (A4) underwent different types of surgical stabilization and decompression, being posterior instrumentation and laminectomies the most common surgical procedure.

In general, our findings were very similar to what is reported in the management of fractures from other causes, especially traumatic injuries. The outcome was reported with different periods of follow-up, some of them very short; therefore, it is not possible to report reliable outcomes.

Limitations

Although this study shows relevant information about SISF, it has some limitations. All of these patients were extracted from case reports; therefore, they are subject to reporting and description bias. In addition, only English language articles were included for review and therefore articles published in a different idiom could have been excluded. We also believe that SISF is underreported, especially in cases of fractures causing minor symptoms. Despite these limitations, this review summarizes all the accessible pertinent cases and gives insights into this special disease.

CONCLUSIONS

SISF is an uncommon event observed usually in the thoracolumbar spine. Persistent local pain at the fractured area is a constant symptom in these cases. Type A1 and A4 injuries localized in the thoracolumbar area were the most common fractures observed in this study. The results of this study show that the management of these fractures is similar to the treatment of vertebral fractures caused by other pathologies.

REFERENCES

1. McCullen GM, Brown CC. Seizure-induced thoracic burst fractures. A case report. *Spine (Phila Pa 1976)*. 1994;19(1):77–79. doi:10.1097/00007632-199401000-00017
2. Vasconcelos D. Compression fractures of the vertebrae during major epileptic seizures. *Epilepsia*. 1973;14(3):323–328. doi:10.1111/j.1528-1157.1973.tb03967.x
3. Finelli PF, Cardi JK. Seizure as a cause of fracture. *Neurology*. 1989;39(6):858–860. doi:10.1212/wnl.39.6.858
4. Reinhold M, Audigé L, Schnake KJ, Bellabarba C, Dai L-Y, Oner FC. AO spine injury classification system: a revision proposal for the thoracic and lumbar spine. *Eur Spine J*. 2013;22(10):2184–2201. doi:10.1007/s00586-013-2738-0
5. Robichaud AS, Barry TK, Barry SP. Seizure-induced thoracolumbar burst fractures - Not to be missed. *Epilepsy Behav Rep*. 2020;13:100352. doi:10.1016/j.ebr.2019.100352
6. Grzonka P, Rybitschka A, De Marchis GM, Marsch S, Sutter R. Bone fractures from generalized convulsive seizures and status epilepticus-a systematic review. *Epilepsia*. 2019;60(5):996–1004. doi:10.1111/epi.14738
7. Hurley CM, Baig MN, Callaghan S, Byrne F. Cervical spine hangman fracture secondary to a gelastic seizure. *BMJ Case Rep*. 2019;12(8):e230733. doi:10.1136/bcr-2019-230733
8. Smith RAJ, Poland N, Cope S. A seizure-induced T8 burst fracture re-presenting as an acute abdomen. *BMJ Case Rep*. 2017;2017:bcr-2017-220346. doi:10.1136/bcr-2017-220346
9. Stilwell P, Harman K, Hsu W, Seaman B. Multiple seizure-induced thoracic vertebral compression fractures: a case report. *J Can Chiropr Assoc*. 2016;60(3):252–257.
10. Gill JR, Murphy CG, Quansah B, Carrothers AD. Seizure induced polytrauma; not just posterior dislocation of the shoulder. *BMJ Case Rep*. 2015;2015:bcr2015211445. doi:10.1136/bcr-2015-211445
11. Moscote-Salazar LR, Rubiano AM, Alvis-Miranda HR, Alcalá-Cerra G. Non traumatic fractures of the lumbar spine and seizures: case report. *Romanian Neurosurgery*. 2015;29(4):477–480. doi:10.1515/romneu-2015-0063
12. Atalar E, Gunay C, Atalar H, Tunc T. A rarely seen multilevel thoracic vertebral fracture after a nocturnal hypoglycemic convulsion attack. *Case Rep Orthop*. 2015;2015:646352. doi:10.1155/2015/646352
13. Ali N, Bhat A, Bangroo F, Maqsood M, Dhanda M, Sharma S. Bilateral posterior fracture dislocation of shoulder with multiple vertebral fractures as a presentation of intracranial lesion: a report with review. *Prog Orthop Sci*. 2015;1(2):59. doi:10.5455/pos.20150928111339
14. Uvaraj NR, Gopinath NR, Bosco A. Non-traumatic vertebral fractures: an uncommon complication following the first episode of a convulsive seizure. *IJCRI*. 2014;5(2):135. doi:10.5348/ijcri-2014-02-458-CR-10
15. Majkowska L, Waliłko E, Mołęda P, Bohatyrewicz A. Thoracic spine fracture in the course of severe nocturnal hypoglycemia in young patients with type 1 diabetes mellitus--the role of low bone mineral density. *Am J Emerg Med*. 2014;32(7):816. doi:10.1016/j.ajem.2013.12.055
16. Ghayem Hasankhani E, Omid-Kashani F. Multiple lumbar vertebral fractures following a single idiopathic seizure in an otherwise healthy patient; a case report. *Med J Islam Repub Iran*. 2013;27(4):233–235.
17. Rahimizadeh A, Khajoo A, Rahimizadeh S. Seizure-induced thoracolumbar burst fracture secondary to tramadol use. *WSCJ*. 2012;3:50–55.
18. Alian A. Uncommon T12 burst fracture after an epileptic crisis. *Case Rep Orthop*. 2011;2011:726373. doi:10.1155/2011/726373
19. Malik SA, Mitra A, Bashir K, Mahapatra A, et al. Lumbar spine burst fracture as a result of hypoglycaemia induced seizure. *Injury Extra*. 2011;42(3):25–28. doi:10.1016/j.injury.2010.11.008
20. Sharma A, Avery L, Novelline R. Seizure-induced lumbar burst fracture associated with conus medullaris-cauda equina compression. *Diagn Interv Radiol*. 2011;17(3):199–204. doi:10.4261/1305-3825.DIR.3638-10.2
21. Napier RJ, Nolan PC. Diagnosis of vertebral fractures in post-ictal patients. *Emerg Med J*. 2011;28(2):169–170. doi:10.1136/emj.2009.088021
22. Iş M, Kiliçer C, Sencer A, Karasu A, Imer M. Seizure-induced unstable L1 burst fracture without trauma: a case report. *Erciyes Tip Dergisi*. 2009;31(1):S05–S09.
23. Kalaci A, Duru M, Karazincir S, Sevinç TT, Kuvandik G, Balci A. Thoracic spine compression fracture during isoniazid-induced seizures: case report. *Pediatr Emerg Care*. 2008;24(12):842–844. doi:10.1097/PEC.0b013e31818ea0a5
24. Mehlhorn AT, Strohm PC, Hausschildt O, Schmal H, Südkamp NP. Seizure-induced muscle force can caused lumbar spine fracture. *Acta Chir Orthop Traumatol Cech*. 2007;74(3):202–205.
25. Shin TS, Kim HW, Park KS, Kim JM, Jung CK. Burst fractures of the lumbar spine due to seizure. *Korean J Spine*. 2007;4(2):81–83.
26. Roohi F, Fox A. Burst fracture of the first lumbar vertebra and conus-cauda syndrome complicating a single convulsive seizure: a challenge of diagnosis in the Emergency Department. *J Emerg Med*. 2006;31(4):381–385. doi:10.1016/j.jemermed.2006.04.012

27. Perry D, Atkinson D. Orthopaedic surgeons diagnosing epilepsy from plain radiographs. *IJOS*. 2007;4(2):1–4. doi:10.5580/a7a
28. Gnanalingham K, Macanovic M, Joshi S, Afshar F, Yeh J. Non-traumatic compression fractures of the thoracic spine following a seizure -- treatment by percutaneous kyphoplasty. *Minim Invasive Neurosurg*. 2004;47(4):256–257. doi:10.1055/s-2004-818521
29. Takahashi T, Tominaga T, Shamoto H, Shimizu H, Yoshimoto T. Seizure-induced thoracic spine compression fracture: case report. *Surg Neurol*. 2002;58(3–4):214–216. doi:10.1016/s0090-3019(02)00837-6
30. Torreggiani WC, Lyburn ID, Harris AC, Nicolaou S. Odontoid fracture following an epileptic seizure. *Australas Radiol*. 2001;45(3):359–361. doi:10.1046/j.1440-1673.2001.00938.x
31. Kumar SK, Freeman BJ. Quadriplegia following grand mal seizures. *Injury*. 1999;30(9):626–629. doi:10.1016/s0020-1383(99)00156-4
32. Aboukasm AG, Smith BJ. Nocturnal vertebral compression fracture. A presenting feature of unrecognized epileptic seizures. *Arch Fam Med*. 1997;6(2):185–187. doi:10.1001/archfami.6.2.185
33. Youssef JA, McCullen GM, Brown CC. Seizure-induced lumbar burst fracture. *Spine (Phila Pa 1976)*. 1995;20(11):1301–1303. doi:10.1097/00007632-199506000-00020
34. Gräbe RP. Fracture-dislocation of the lumbosacral spine during a grand mal epileptic seizure. *A case report S Afr Med J*. 1988;74(3):129–131.
35. Nabarro JD. Compression fractures of the dorsal spine in hypoglycaemic fits in diabetes. *Br Med J (Clin Res Ed)*. 1985;291(6505):1320. doi:10.1136/bmj.291.6505.1320
36. Bosco A, Uvaraj NR, Ramakrishnan E. Delayed unrelated presentation of a lumbar burst fracture consequent to a remote episode of a single convulsive seizure: a diagnostic challenge. *J Clin Orthop Trauma*. 2020;11(5):952–955. doi:10.1016/j.jcot.2020.06.043
37. Lim D-J, Shim S-Y. Seizure-induced thoracolumbar burst fracture secondary to cirrhosis: a case report. *Interdiscip Neurosurg*. 2021;23(100935):100935. doi:10.1016/j.inat.2020.100935
38. Sheth RD, Gidal BE, Hermann BP. Pathological fractures in epilepsy. *Epilepsy Behav*. 2006;9(4):601–605. doi:10.1016/j.yebeh.2006.08.003
39. Meier C, Kraenzlin ME. Antiepileptics and bone health. *Ther Adv Musculoskelet Dis*. 2011;3(5):235–243. doi:10.1177/1759720X11410769
40. Nilsson OS, Lindholm TS, Elmstedt E, Lindbäck A, Lindholm TC. Fracture incidence and bone disease in epileptics receiving long-term anticonvulsant drug treatment. *Arch Orthop Trauma Surg*. 1986;105(3):146–149. doi:10.1007/BF00433931
41. Sheth RD, Wesolowski CA, Jacob JC, et al. Effect of carbamazepine and valproate on bone mineral density. *J Pediatr*. 1995;127(2):256–262. doi:10.1016/s0022-3476(95)70304-7
42. Vestergaard P. Epilepsy, osteoporosis and fracture risk - a meta-analysis. *Acta Neurol Scand*. 2005;112(5):277–286. doi:10.1111/j.1600-0404.2005.00474.x

Funding: The authors received no financial support for the research, authorship, and/or publication of this article.

Declaration of Conflicting Interests: The authors report no conflicts of interest in this work.

Corresponding Author: Luis A. Robles, Section of Neurosurgery, Hospital Joya, Av. Francisco Medina Ascencio 2760, Puerto Vallarta, Jalisco, México; larob@prodigy.net.mx

Published 07 April 2022

This manuscript is generously published free of charge by ISASS, the International Society for the Advancement of Spine Surgery. Copyright © 2022 ISASS. To see more or order reprints or permissions, see <http://ijssurgery.com>.