

Clinical and Radiological Outcome in a Series of Patients Treated by Anterior Cervical Discectomy and Fusion: Retrospective Controlled Study With 2 Different Stand-Alone Cages

Jose Poblete, Jaime Jesus Martinez-Anda, Angel Asdrubal Rebollar - Mendoza, Yajaira Castro - Moreno, Ramón Torne, Luis Reyes, Salvador Fuster, Eduard Tornero, Emilo Arch-Tirado, Roberto de Leo-Vargas, Andrés Combalia and Joaquim Enseñat

Int J Spine Surg 2022, 16 (5) 779-791

doi: <https://doi.org/10.14444/8351>

<https://www.ijssurgery.com/content/16/5/779>

This information is current as of May 17, 2025.

Email Alerts Receive free email-alerts when new articles cite this article. Sign up at:
<http://ijssurgery.com/alerts>

Clinical and Radiological Outcome in a Series of Patients Treated by Anterior Cervical Discectomy and Fusion: Retrospective Controlled Study With 2 Different Stand-Alone Cages

JOSE POBLETE, MD¹; JAIME JESUS MARTINEZ-ANDA, MD, MSc²; ANGEL ASDRUBAL REBOLLAR - MENDOZA, MD¹; YAJAIRA CASTRO - MORENO, MD²; RAMÓN TORNE, MD¹; LUIS REYES, MD, PhD¹; SALVADOR FUSTER, MD, PhD²; EDUARD TORNERO, MD, PhD²; EMILIO ARCH-TIRADO, PhD³; ROBERTO DE LEO-VARGAS, MD³; ANDRÉS COMBALIA, MD, PhD⁴; AND JOAQUIM ENSEÑAT, MD, PhD¹

¹Neurosurgery Department; Clinical Hospital, Faculty of Medicine, Barcelona University, Barcelona, Spain; ²Spine Surgery Department; Clinical Hospital, Faculty of Medicine, Barcelona University, Barcelona, Spain; ³Neurological Center, ABC Medical Center, Mexico City, Mexico; ⁴Department Orthopedic Surgery and Trauma, Clinical Hospital, Faculty of Medicine, Barcelona University and Institut d'Investigació Biomèdica, Barcelona, Spain

ABSTRACT

Background: Cervical spine balance and alignment targets after cervical spine surgery are poorly established in patients with cervical spine degenerative disease surgically treated by anterior cervical discectomy and fusion (ACDF). The objective of the study is to determine the correlation between radiological and clinical outcomes in patients surgically treated by ACDF with 2 different stand-alone cervical cages.

Methods: Clinical outcomes were evaluated using visual analog scale (VAS), Neck Disability Index (NDI), Nurick Scale, and Japanese Orthopedic Association score for myelopathy. Radiological evaluation included cervical and segmental Cobb angles, cervical sagittal vertical axis (cSVA), T1 slope (T1s), C0-C2 angle, fusion rates, adjacent segment degeneration, and cage subsidence.

Results: A total of 80 patients were included with an average age of 53 years. There was a statistically significant improvement in both clinical and radiological evaluations. There was a statistical significant correlation between cervical pain on cervical VAS and cSVA. There was a significant correlation between postoperative T1s and cSVA, related to the improvement in cervical angles. There was no significant difference in rates of fusion, adjacent segment changes, or reoperation between both cervical cages, and there was a higher rate of subsidence in the Aleutian group. There were significant differences between both groups on postoperative NDI and VAS, but this difference is not maintained during follow-up.

Conclusions: Cervical sagittal balance is directly related to clinical outcome in patients with cervical spine degenerative disease. Both cervical implants analyzed were comparable in clinical and radiological outcomes.

Clinical Relevance: There are important clinical and radiological parameters that should be taken into account for the analysis of the surgical outcome of patients treated by ACDF; this is one of the few studies that report the results with 2 different cervical cage designs.

Level of Evidence: 4.

Cervical Spine

Keywords: cervical spine, sagittal balance, degenerative spine disease

INTRODUCTION

Anterior cervical discectomy and fusion (ACDF) is the treatment of choice for several cervical spinal diseases; the aim of the procedure is to decompress neural structures, improve patient symptoms, and restore cervical spine sagittal balance and stability.

In recent times, several modifications have been described to the original procedure developed by Smith and Robinson for ACDF.¹ Those variations include the use of cervical cages made of several materials instead of autologous bone and the use of cages with or without

cervical plating. The stand-alone cervical cages (SAc) have the advantages of less surgical time, less bleeding, and less cervical tissue dissection, with a lesser ratio of postoperative dysphagia and quicker recovery.²

The maintenance of cervical alignment is an important factor, particularly in multilevel diseases, as misalignment after spinal instrumentation can lead to pseudarthrosis, cage subsidence, and neck pain, affecting clinical outcome and quality of life.³ Regardless, cervical spine alignment targets after cervical spine surgery are not well established.⁴

In this study, we assess the relationship between regional cervical alignment and balance, and clinical outcome in a series of patients with diagnosis of cervical spine degenerative disease, surgically treated by ACDF with 2 different SAc designs.

METHODS

We performed a retrospective analysis in a series of patients treated between January 2012 and July 2019 with diagnosis of cervical spine degenerative disease, who were surgically treated by ACDF with SAc at the Clinical Hospital of Barcelona, Spain. This study was performed in accordance with the ethical standards of the research committees at the Hospital Clinic of the University of Barcelona and with the 1964 Helsinki declaration and its later amendments or comparable ethical standards. Informed consent was obtained from all individual participants included in the study. The Institutional Review Board approval was obtained prior to the study commencement (registration number: HCB/2020/0802).

Patients

Inclusion criteria were as follows: (1) signs and symptoms of cervical pain, cervical radiculopathy, or spondylotic myelopathy; (2) cervical spondylosis confirmed by x-ray images and magnetic resonance imaging (MRI); (3) follow-up of ≥ 12 months; and (4) cervical x-ray images for follow-up analysis.

Exclusion criteria were as follows: (1) previous cervical spine surgery, (2) ossification of the posterior longitudinal ligament, (3) invasive malignancy, (4) evidence of systemic or local infection, and (5) patients lost at follow-up.

Clinical and Surgical Evaluation

Clinical and surgical data were retrospectively collected from hospital archives, analyzing preoperative and follow-up evaluations; some patients with incomplete charts were contacted via e-mail or telephone. We analyzed patients' age, gender, medical and smoking background, and bone densitometry, as prognosis factors. For clinical outcome evaluation, we used pre- and postoperative visual analog scale (VAS) for neck and radicular pain, Neck Disability Index (NDI),⁵ Nurick Scale, and Japanese Orthopedic Association (JOA) score for myelopathy.⁶ The NDI, VAS, JOA, and Nurick scores were evaluated at every follow-up consultation. Surgical outcomes were evaluated by analyzing

surgical complications, postoperative dysphagia, and reoperation rates.

Radiological Evaluation

Front, lateral, and flexion/extension cervical x-ray images were obtained before and after surgery, at first and sixth month, and yearly thereafter (Figure 1). MRI evaluation was made preoperatively in all patients; postoperative MRI was only made in patients with poor clinical outcomes.

The cervical angles evaluated were as follows (Figure 1): (1) C2-C7 Cobb's angle (cCobb), as the angle between a line parallel to the inferior endplate of C2 and a line drawn parallel to the inferior endplate of C7⁷; (2) the Harrison posterior target method to calculate C2-C7 angle (Harrison cervical angle [HCA]) as the angulation between a line parallel to the posterior wall of vertebral bodies of C2 and C7⁸; (3) cervical segmental Cobb angle (sCobb) of fused segment alignment was measured between the upper endplate of the most cranial vertebral body and the lower endplate of the most caudal vertebral body of surgically treated segment^{9,10}; (4) C2-C7 sagittal vertical axis (cSVA) as the horizontal distance between vertical line from the center of C2 and the posterior aspect of C7¹¹; (5) T1 slope (T1s) as the angle between horizontal plane and T1 upper endplate¹¹; and (6) C0-C2 angle, as the angle between McGregor line and the inferior surface of the axis. Postoperative x-ray images were analyzed for fusion, subsidence, and adjacent segment degeneration (Figure 2). Fusion was defined as (1) movement $< 3^\circ$ in flexion-extension postoperative x-ray images, (2) presence of trabeculae bridging bone formation at the anterior and/or posterior cortex of the involved vertebral bodies, and (3) absence of radiolucency through the fusion levels (Figure 2A).^{12,13} Adjacent segment degeneration was defined as (1) disc height decrease $> 25\%$, (2) disc wedging $> 5^\circ$, and (3) osteophytes formation with neural foramen and/or vertebral canal compression (Figure 2B).^{14,15} Subsidence was defined as a ≥ 3 mm decrease of the segmental height at postoperative images (Figure 2C).^{12,13}

Surgical Technique

A standard anterior cervical spine approach and microscopic discectomies were performed. Any body spur or uncovertebral joint, as well as the endplate cartilage, was removed using a curette or high-speed drill under a surgical microscope. While applying vertebral distraction, the cervical cage was inserted; the cages were filled with demineralized bone matrix (Trel-XC,

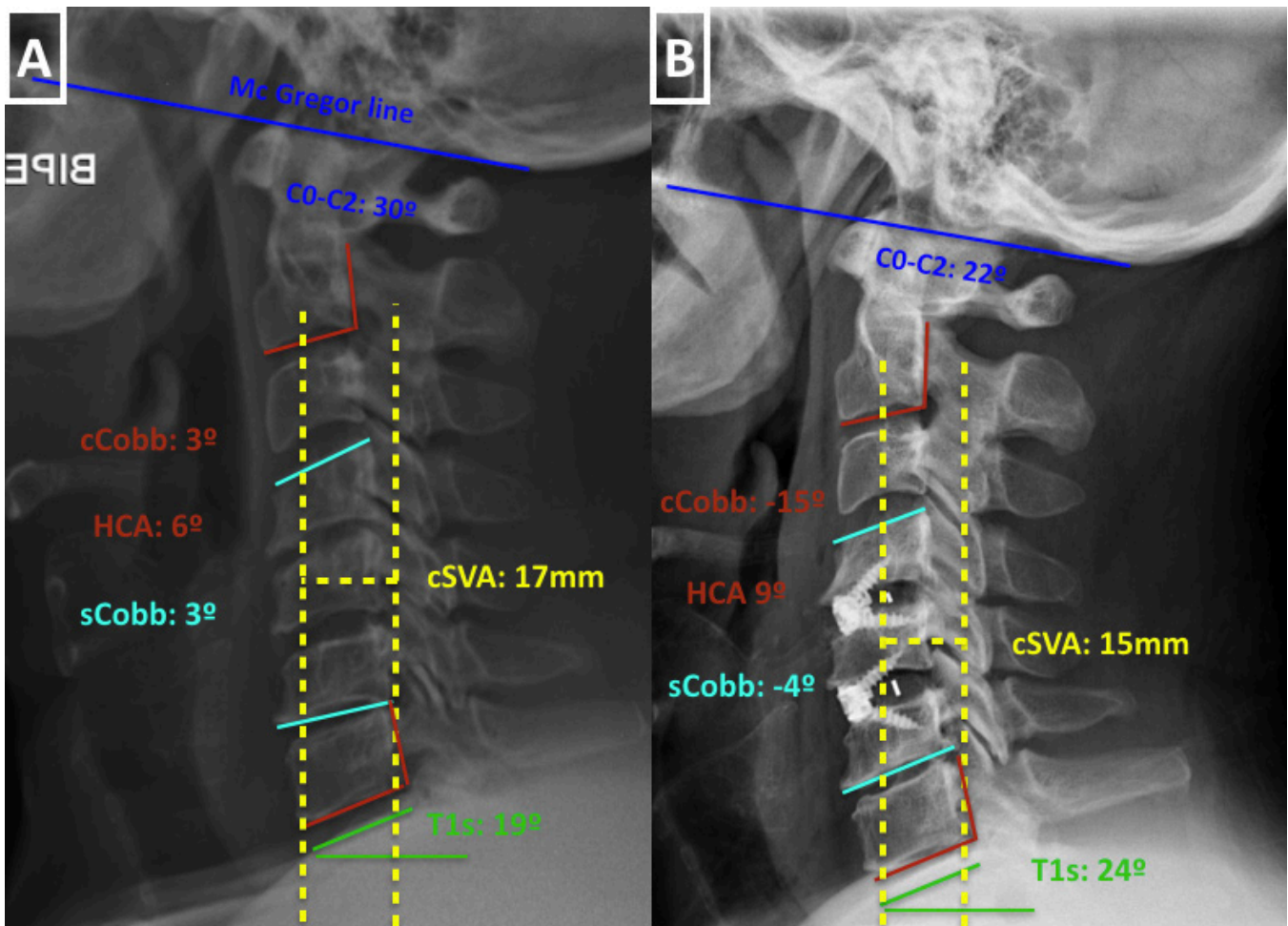


Figure 1. (A) Preoperative and (B) postoperative lateral x-ray images of a patient surgically treated with self-locking stand-alone anterior cervical discectomy and fusion technique for cervical spine degenerative disease. The cervical regional sagittal balance parameters measured for the present study are shown: cCobb, C2-C7 Cobb's angle; HCA, C2-C7 angle measured with the Harrison's method; sCobb, cervical segmental Cobb angle; cSVA, C2-C7 sagittal vertical axis; T1s, T1 slope; C0-C2, C0-C2 angle. HCA, Harrison cervical angle; cSVA, cervical sagittal vertical axis.

Integra, NJ, USA). Interbody instrumentation was performed using SAc with (Coalition, Globus Medical, PA, USA; Figure 3A) and without (Aleutian, Stryker, MI, USA; Figure 3B) self-locking systems. All procedures were performed by experienced spinal surgeons.

Statistical Methods

Continuous variables were expressed as mean and SD or median and interquartile range and were compared using the Student *t* test or the Mann-Whitney *U* test according to the Kolmogorov-Smirnov test of normality. Qualitative variables were described by absolute frequencies and percentages, and they were compared using the χ^2 test or Fisher's exact test, when necessary.

The Pearson's correlation model was applied to establish a relation between continuous numeric variables. Relative risk and Pearson's χ^2 test were performed to establish risk factors. The presence of interaction and the role of confounding factors were evaluated.

Statistical significance was defined as a 2-tailed *P* < 0.05. The analysis was performed using SPSS, version 20.0 (SPSS, Inc, Chicago, IL, USA).

RESULTS

A total of 80 patients who met the inclusion criteria were evaluated for this study, with an average age of 53 years, and cervical or radicular symptoms for a mean period of 11.6 months. Twenty-four patients (30%) were aged ≥ 60 years, 28 (35%) were smokers, and 15 of 24 (62.5%) patients evaluated for osteoporosis had a densitometry *T* value ≤ 2.5 . Mean preoperative cervical pain was 7.1 (VAS), radicular pain was 7.3 (VAS), and NDI was 40.2. Myelopathic symptoms were present in 18.7% of patients (Nurick ≥ 1), and the mean JOA was 15.6. Multiple-level disc degeneration was present in 46.2% of patients (Table 1). Mean value for preoperative regional cervical radiological measures was

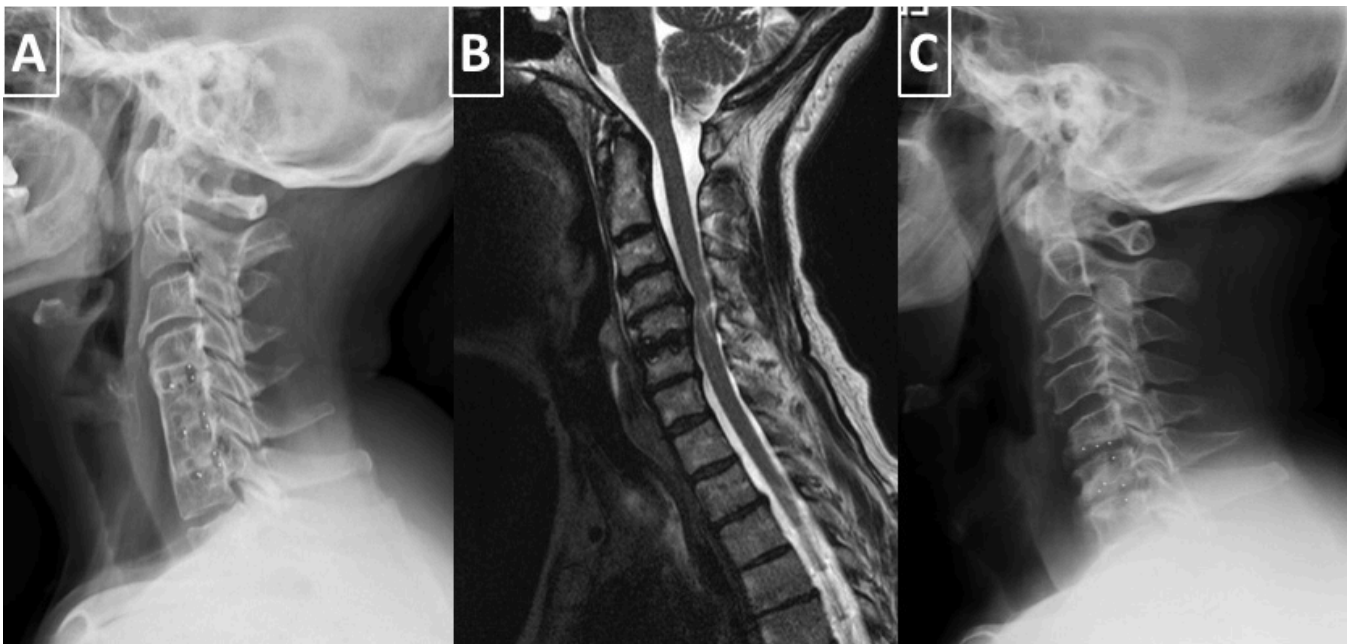


Figure 2. (A) Lateral x-ray image of a patient treated with 3-level stand-alone anterior cervical discectomy and fusion (ACDF) technique who developed bony fusion between intervened cervical levels. (B) Sagittal plane T2-weighted magnetic resonance image of a patient treated with single-level stand-alone ACDF technique who developed adjacent segment disease. (C) Lateral x-ray image of a patient treated with 2-level stand-alone ACDF technique who developed subsidence of intervened cervical levels.

(Figure 4) as follows: cCobb -10.6° , T1s 26.7° , HCA 17.8° , C0-C2 18° , cSVA 27.1 mm, and sCobb -1.7° .

Mean follow-up time was 22.5 months. Two patients (2.5%) developed postoperative complications, 1 patient with neurological deterioration (sensitive deterioration), and 1 patient with surgical site hematoma, but none of them required new surgery; 4 patients had long-term dysphagia (5%) (Table 2).

There was statistically significant postoperative improvement in cervical and radicular VAS, NDI, and JOA scores (Table 2). No statistical difference was found between single- vs multilevel disease in clinical outcome (cervical/radicular VAS, NDI, or JOA) (Table 3). Six patients (7.5%) required new surgery.

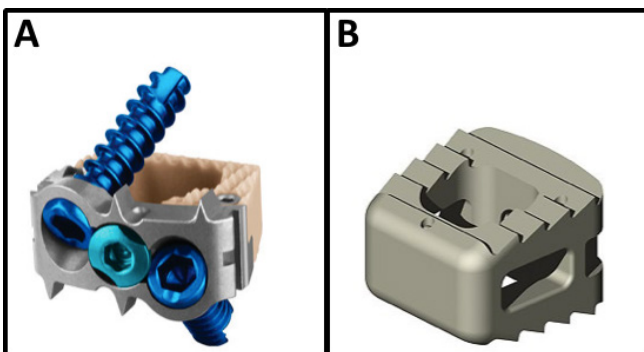


Figure 3. Cervical cages: (A) Coalition, Globus Medical, PA, USA and (B) Aleutian, Stryker, MI, USA.

Radiological Outcomes

There was statistically significant improvement in postoperative cCobb (Figure 4A), cSVA (Figure 4E), and sCobb (Figure 4F). No significant change was found

Table 1. Baseline characteristics of patients (N = 80).

Characteristics	Value
Age, y, mean (SD) (range)	53.15 (10.73) (30–78)
≥ 60 y, n (%)	24 (30%)
Gender: female, n (%)	43 (53.7%)
Smokers, n (%)	28 (35%)
Osteoporosis, n (%)	15 (18.8%)
Outcome measure	
VAS cervical pain, mean (SD)	7.15 (2.1)
VAS radicular pain, mean (SD)	7.35 (2)
Myelopathy symptoms (Nurick ≥ 1), n (%)	15 (18.75%)
NDI, mean (SD) (range)	40.21 (13.2) (14–80)
JOA, mean (SD)	15.67 (1.47)
Symptom duration, mo, median (IQR)	11.6 (0.4–22.8)
Type of spinal fusion, n (%)	
Single-level fusion	43 (53.8%)
Multiple-level fusion	37 (46.2%)
C3-C4	6 (7.5%)
C4-C5	11 (13.8%)
C5-C6	20 (25%)
C6-C7	8 (10%)
C3-C5	2 (2.5%)
C4-C6	3 (3.8%)
C5-C7	25 (31.3%)
C4-C7	5 (6.3%)
Myelopathic changes on MRI	21 (26.3%)

Abbreviations: IQR, interquartile range; JOA, Japanese Orthopedic Association Scale; MRI, magnetic resonance imaging; NDI, Neck Disability Index; VAS, visual analog scale.

Note: Statistically significant differences are shown in **boldface**.

^aEvaluation on first postoperative mo; in parentheses, P value of independent samples t test comparing preoperative vs postoperative evaluation.

^bLast follow-up evaluation; in parentheses, P value of independent samples t test comparing postoperative vs last follow-up evaluation.

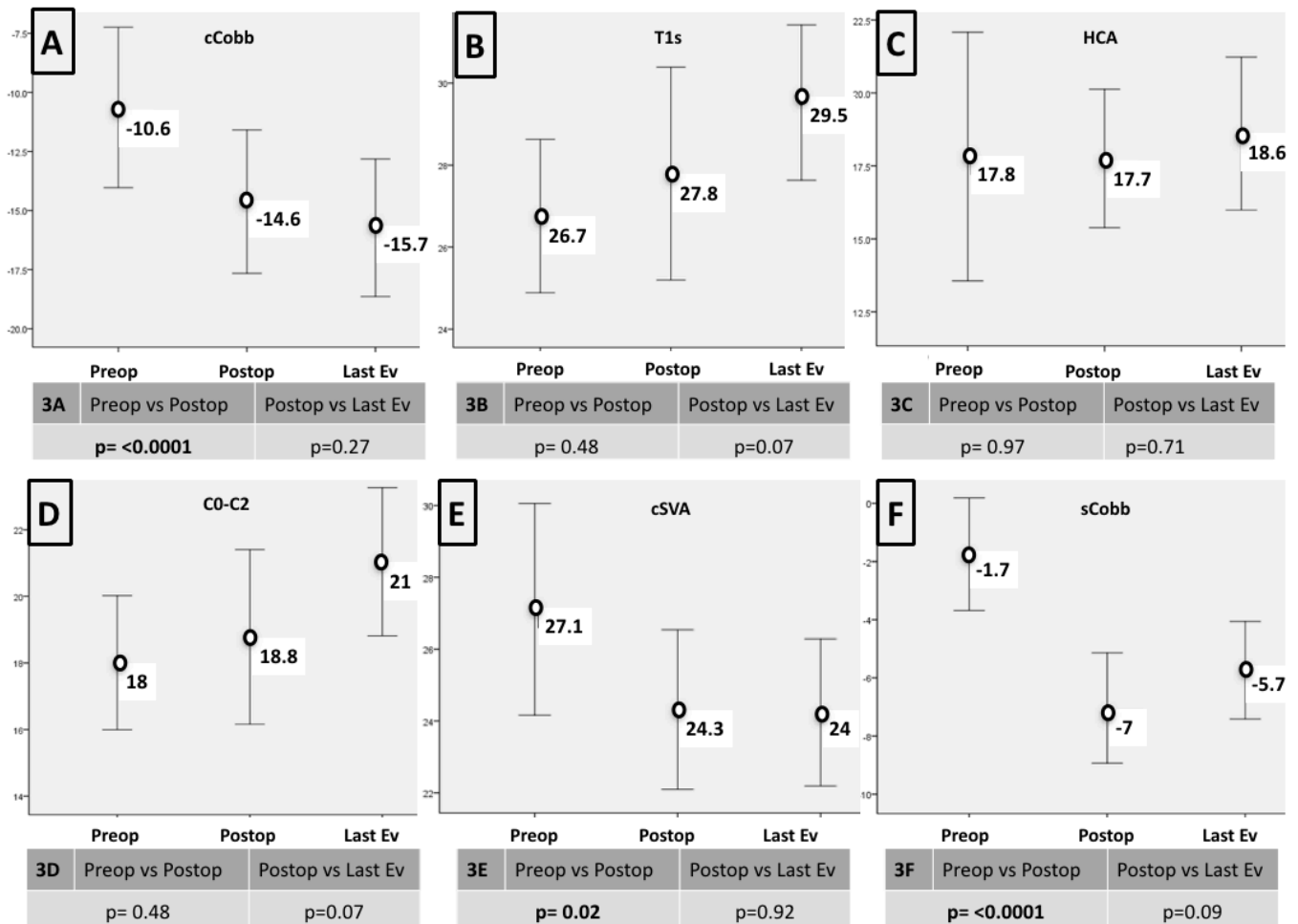


Figure 4. Error-bar charts showing the mean changes in regional cervical sagittal balance parameters during time, measured in preoperative (Preop), postoperative (Postop), and follow-up (last evaluation [Last Ev]) periods. (A) cCobb, C2-C7 Cobb's angle; (B) T1s, T1 slope; (C) HCA, C2-C7 angle measured with the Harrison's method; (D) C0-C2, C0-C2 angle; (E) cSVA, C2-C7 sagittal vertical axis; and (F) sCobb, cervical segmental Cobb angle. *P* values were obtained with Student's *t* test for independent values, and significant values are highlighted in **boldface**.

in postoperative T1s (Figure 4B), HCA (Figure 4C), or C0-C2 angle (Figure 4D). There were no significant changes in any of the cervical and radiological measures during follow-up (Figure 4). There was a higher change in segmental lordosis (sCobb) in patients with multi-level disease than those with single-level surgery, but it had no impact on cervical sagittal alignment (Table 3).

There was a statistical significant correlation between cervical pain on VAS (cervical VAS) and cSVA; as with less value of the cSVA, there was a better surgical result related to cervical pain at the postoperative period. Also there was a significant correlation between a decreased angle between C0 and C2 and less radicular pain on follow-up evaluation. More positive (kyphotic) angles between C2 and C7 (cCobb), and a higher C0-C2 angle were both related to a significant higher risk of requiring a new surgery during follow-up (Table 4).

In the preoperative radiological evaluation, there was a significant Pearson's correlation (CI = -0.56, *P*

≤ 0.0001) between T1s and cCobb, and this correlation was maintained throughout the postoperative and follow-up evaluations (Figure 5A, D and G). In the preoperative evaluation, there was no significant correlation between T1s and cSVA (Figure 5B), but this changed the postoperative (Figure 5E; CI = 0.37, *P* = 0.001) and follow-up (Figure 5H; CI = 0.32, *P* = 0.003) evaluations, related to the improvement in the cervical angles.

Radiological fusion was achieved in 85% of patients (Figure 2A, Table 2), adjacent segment degeneration was found in 5 patients (6.3%) (Figure 2B, Table 2), and cage subsidence was found in 26 patients (32.5%) (Figure 2C, Table 2). Patients with osteoporosis had a significant higher risk (relative risk = 3.9, *P* ≤ 0.001) of subsidence (Figure 6A). Age >60 years and multilevel surgery had a minor but significant increase in the risk of subsidence (Figure 6A). Osteoporosis and age >60 years were significant risk factors for adjacent segment degeneration (Figure 6B). The subsidence, adjacent

Table 2. Patient outcomes (N = 80).

Outcomes	N (%)	
Surgical technique		
Stand-alone cages	35 (43.8%)	
Self-locking stand-alone cages	45 (56.2%)	
Follow-up, mo, median (IQR)	22.5 (12–32.1)	
Surgical complications	2 (2.5%)	
Postoperative dysphagia		
Transient (<1 month)	16 (20%)	
Long term	4 (5%)	
Fusion achieved	68 (85%)	
Adjacent segment degeneration	5 (6.3%)	
Subsidence	26 (32.5%)	
Required new surgery	6 (7.5%)	
Pseudoarthrosis/subsidence	2 (2.5%)	
Adjacent segment degeneration	4 (5%)	
	Postoperative ^a	Last Evaluation ^b
Outcome measure		
VAS cervical Pain	4.26 (0.001)	4.6 (0.147)
VAS radicular pain	3.91 (0.001)	4.3 (0.1)
Myelopathy symptoms (Nurick 1)	15 (18.7%)	14 (17.5%)
NDI	27.4 (0.001)	29.33 (0.07)
JOA	16.97 (0.001)	16.95 (0.7)

Abbreviations: IQR, interquartile range; JOA, Japanese Orthopaedic Association Scale; NDI, Neck Disability Index; VAS, visual analog scale.

Note: Data presented as n (%) unless otherwise indicated. Statistically significant differences are shown in **boldface**.

^aEvaluation on first postoperative month; in parenthesis, P value of independent samples t test comparing preoperative evaluation vs postoperative evaluation.

^bLast follow-up evaluation; in parenthesis, P value of independent samples t test comparing postoperative evaluation vs last follow-up evaluation.

Table 3. Correlation between cervical spine levels surgically treated, cervical alignment, and clinical/radiological outcome.

	Single Level, Mean (SD)	Multilevel, Mean (SD)	P ^a
Postoperative Clinical Status			
NDI	25.4 (13.9)	29.7 (19.2)	0.25
Cervical VAS	4.1 (2.3)	4.4 (2.7)	0.5
Radicular VAS	3.9 (2.2)	3.9 (2.6)	0.9
JOA	16.9 (1.2)	17 (1.5)	0.8
Last Evaluation Clinical Status			
NDI	27.5 (15)	31.4 (19.8)	0.3
Cervical VAS	4.3 (2.4)	4.8 (2.9)	0.4
Radicular VAS	4.2 (2.7)	4.4 (2.8)	0.7
JOA	17 (1.2)	16.8 (1.5)	0.6
Postoperative Cervical Angles			
C2-C7 Cobb's angle	-13 (15.5)	-16 (10.8)	0.2
T1 slope	27.7 (13.3)	27.8 (9.5)	0.9
C0-C2 angle	18.8 (12.6)	18.7 (10.8)	0.9
Cervical segmental Cobb angle	-5.1 (7.1)	-9.2 (9.4)	0.02
Harrison cervical angle	17.6 (11.4)	17.8 (9.7)	0.9
Cervical sagittal vertical axis	25.4 (9.9)	23 (9.9)	0.2

Abbreviations: JOA, Japanese Orthopaedic Association; NDI, Neck Disability Index; VAS, visual analog scale.

^at test for independent samples.

segment degeneration, or fusion index has not affected the clinical outcome on follow-up (Figure 7), but those were the main indications for new surgery (Table 1).

Surgical and Radiological Outcomes Between the 2 Cervical Cages

Patients were treated with 2 cervical cages, Coalition (Figure 3A) and Aleutian (Figure 3B); both groups were comparable in age, gender, smoking habit, and osteoporosis background. Aleutian group had a significant longer follow-up compared with the Coalition group (23.8 vs 11.5 months, $P \leq 0.0001$). There was no significant difference in rates of fusion, adjacent segment changes, or reoperation between both groups, but there was a higher rate of subsidence in the Aleutian group (45.7% vs 22.2%, $P = 0.02$). There were significant differences between both groups on postoperative NDI (30.5 ± 18.7 vs 23.4 ± 13.4) and VAS (4.8 ± 2.5 vs 3.5 ± 2.2) with better postoperative outcomes in patients with Aleutian cages, but this difference is not maintained during follow-up (Table 5). On radiological evaluation, both groups were comparable in cervical angles preoperatively, and there was only a significant difference on postoperative cervical Cobb's angle, but this difference did not persist over time, as both groups had similar cervical Cobb's angles on last evaluation (Figure 8).

DISCUSSION

Cervical segment is the part of the spine with the most mobility in the sagittal plane; when cervical spine suffers degenerative changes, it has compensatory mechanisms to maintain the position of the head over the feet and to keep alignment and a horizontal gaze. Understanding the behavior of the cervical spine during degenerative processes is a challenge for the spine surgeon.¹⁶ Many factors interact with the alignment and balance of the cervical spine. In terms of the normality of the measured parameters, the values vary widely in the reported literature. It seems that factors, such as age, sex, race, and methods for measuring can cause some disparity.¹⁷ A preponderance of the literature analyzing the correlation between sagittal imbalance and patient outcomes is focused on the thoracolumbar or spinopelvic region, with little attention paid to studying the cervical sagittal balance.¹⁸

Patients with diagnosis of cervical spine degenerative disease have different degrees of loss of cervical sagittal alignment, which is a process that results from the decrease in cervical disc height and causes changes in the curvatures and progressive deformity of the

Table 4. Correlation between clinical status and cervical alignment.

	Postoperative Clinical Status					
	NDI		Cervical VAS		Radicular VAS	
	C ^a	P	C ^a	P	C ^a	P
cCobb	0.049	0.66	-0.15	0.16	-0.062	0.58
T1s	-0.098	0.38	-0.056	0.62	0.02	0.98
C0-C2	0.08	0.67	-0.005	0.9	-0.022	0.84
sCobb	0.06	0.56	-0.054	0.634	-0.036	0.75
HCA	-0.122	0.28	0.045	0.69	0.032	0.78
cSVA	-0.059	0.6	-0.29	0.009	-0.18	0.11

	Clinical Status on Last Follow-Up Evaluation					
	NDI		Cervical VAS		Radicular VAS	
	C ^a	P	C ^a	P	C ^a	P
cCobb	0.16	0.147	0.06	0.54	0.11	0.31
T1s	-0.16	0.156	-0.1	0.33	-0.06	0.55
C0-C2	0.011	0.92	-0.11	0.3	-0.25	0.02
sCobb	0.184	0.1	-0.04	0.69	0.096	0.4
HCA	-0.09	0.4	0.045	0.69	0.038	0.73
cSVA	0.035	0.75	-0.12	0.26	-0.068	0.54

	Reoperation		
	Yes ^b	No ^b	P ^c
cCobb	-4.7	-15.4	0.05
T1s	31.4	27.4	0.42
C0-C2	28.5	18	0.03
sCobb	-5.6	-7.1	0.6
HCA	15.6	17.9	0.6
cSVA	26.3	24.1	0.6

Abbreviations: C0-C2, C0-C2 angle; cCobb, C2-C7 Cobb's angle; cSVA, cervical sagittal vertical axis; HCA, Harrison cervical angle; NDI, Neck Disability Index; sCobb, cervical segmental Cobb angle; T1s, T1 slope; VAS, visual analog scale.

^aPearson's correlation coefficient.

^bMean value.

^cTest for independent samples.

cervical spine. The criteria for the physiologic reconstruction of cervical spine sagittal balance have not been defined.¹⁹ ACDF procedures improve segmental sagittal alignment, cervical overall shape, and angles, but these changes are inconsistently related to higher quality-of-life scores.²⁰

We present a case series of patients with diagnosis of cervical spine degenerative disease and surgically treated by ACDF with stand-alone cages, and the relation of their clinical and radiological outcomes to regional cervical spine angles. The cervical regional parameters were divided into 3 groups: (1) occipitocervical parameters, measuring the angle between C0 and C2; (2) cervical sagittal shape and alignment, measuring the cervical angle between C1-C2 and C7 with the Cobb's and Harrison's methods, and segmental angulation between surgically treated cervical segments with the Cobb's method; and (3) cervical sagittal balance parameters, with the T1s and cSVA. We have chosen those parameters, as they are the more consistent ones reported in the literature.¹⁶ We found significant postoperative changes in cCobb, sCobb, and cSVA (Figure 4), and we found a significant correlation between postoperative clinical status (cervical VAS score) and postoperative cSVA, suggesting that the cervical angulation

and alignment are as important factors as the cervical sagittal balance in obtaining a satisfactory clinical outcome⁴ (Table 4).

It has been emphasized the significance of T1s as a useful parameter to evaluate the whole-spine sagittal balance, and how its value can influence the lordosis of the cervical spine and affect clinical outcomes after cervical spine surgery. An increase in T1s can occur with global sagittal positive misalignment, and it causes the cervical spine to be tilted anteriorly, with an increase in the cSVA. With the increase of cSVA and T1s, lower cervical segments need to be flexed, and suboccipital segments are hyperextended, maintaining horizontal gaze. If the patient is not able to compensate high T1s with higher lordotic cervical curvature, the patient may tip over into positive cervical sagittal imbalance and experience pain and disability.^{21,22} We found a significant correlation between T1s and cSVA in the postoperative and follow-up evaluations that was not present in the preoperative evaluation, and this was related to the improvement of the cervical regional angles and was significantly related to clinical improvement (Table 4 and Figure 5). Although the association between cervical spine angles and whole-spine sagittal balance is controversial, cervical lordosis is thought to be a compensatory mechanism to maintain equilibrium

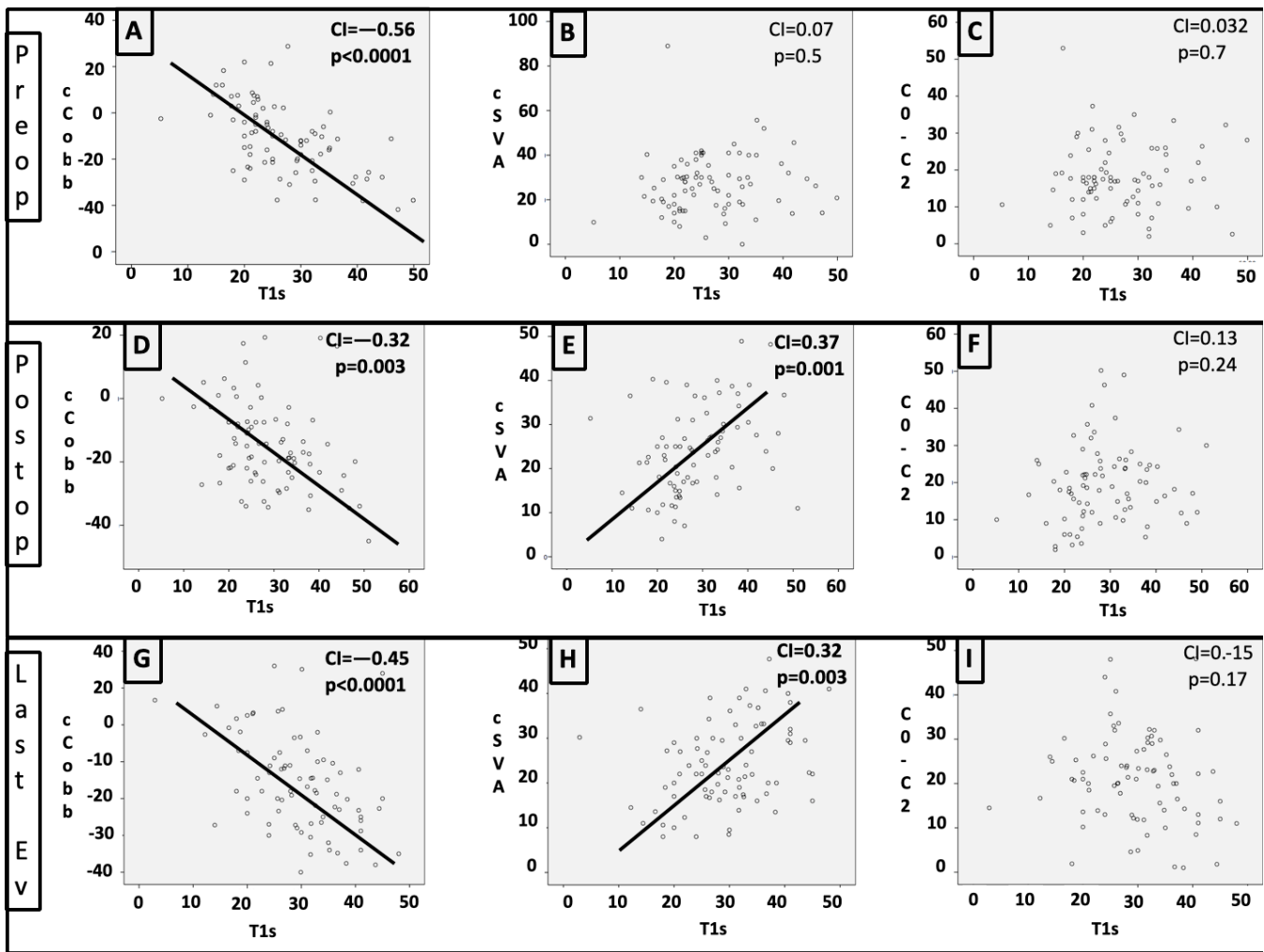


Figure 5. Scatterplots show the correlation between T1 slope (T1s) and C2-C7 Cobb's angle (cCobb), cervical sagittal vertical axis (cSVA) and C0-C2 angle (C0-C2) in preoperative (A), (B), and (C); postoperative (D), (E), and (F); and last follow-up evaluations (G), (H), and (I). CI, Pearson's correlations coefficient. Statistical significant values were highlighted in **bold**.

and forward gaze of the head,¹¹ and an analysis of the improvement of cervical lordosis should be revised in relation to the global spine sagittal balance.

Segmental alignment in cervical spine instrumented segments is an independent factor in the analysis of results after ACDF procedure and can be modified during follow-up by cage subsidence, nonunion, and adjacent segment degeneration. It has been reported that local kyphosis at the fused segment is observed in only 13% of patients with single-level fusion, but in 53% of patients with multiple-level fusion.²³ A loss of cervical global lordosis and lordosis at the instrumented cervical segment is documented during follow-up in patients treated by ACDF with stand-alone cages, compared with patients treated by ACDF with cages and plates, and this could be related to a higher index of subsidence,² which is the most common complication of ACDF using stand-alone cages. During the

process of bone remodeling, settlement of the cage of less than 2 mm into the vertebral bodies until fusion is to be expected.¹³ If cages subside ≥ 3 mm into the vertebral body, disc space and neural foramina heights both collapse.^{24,25} Subsidence is reported in 9.3% to 62.5% of cervical segments analyzed, it often occurs within 3 months after surgery and results in sagittal misalignment in most cases¹² with segmental loss of angulation as high as 8.7°. Clinical adjacent segment pathology may affect 9% to 25% of all patients within 10 years after an anterior cervical arthrodesis, and risk factors include pre-existing degeneration at the adjacent levels, previous cervical fusion, and sagittal cervical misalignment.²⁶⁻²⁸ High cervical cSVA, T1s, and postoperative cervical kyphosis are related to adjacent segment pathology requiring surgery.^{4,29} Cage-only technique seems to be associated with a 2- to 3-fold decrease in the rate of ASD.^{30,31} When single-level




Figure 6. Foster plot with relative risk (RR) of developing (A) subsidence, (B) adjacent segment degeneration, (C) fusion, and (D) the need of reoperation in the presence of multilevel surgery, age >60 years, smoking, and osteoporosis. P value was calculated with Pearson’s square X test, and significant results are highlighted in **bold**.

ACDF is performed, fusion rates are high and comparable with stand-alone techniques and anterior plating.²⁵ In multilevel cervical disease, a bony fusion rate varies from 78% to 100% and seems to be higher with cervical plating.^{2,30,32} We did not find a significant change in cervical or segmental cervical lordosis during follow-up in patients with single- or multilevel cervical surgery (Table 3 and Figure 4) or a significant relationship between subsidence, adjacent segment, fusion indices, and number of levels surgically treated, with clinical outcome (Figure 7),² but all patients who required new

surgery had diagnosis of pseudarthrosis, subsidence, or adjacent segment degeneration. Risk factors for adjacent segment degeneration and subsidence were multilevel surgery, osteoporosis, and age >60 years.

Our findings suggest that surgical goals of cervical spine surgery for degenerative spine disease should be focused not only on cervical spine alignment and angles, but also in terms of cervical sagittal balance in order to obtain satisfactory results. Patients with osteoporosis, age >60 years and multilevel involvement, and cervical alignment with kyphosis, could be better candidates for

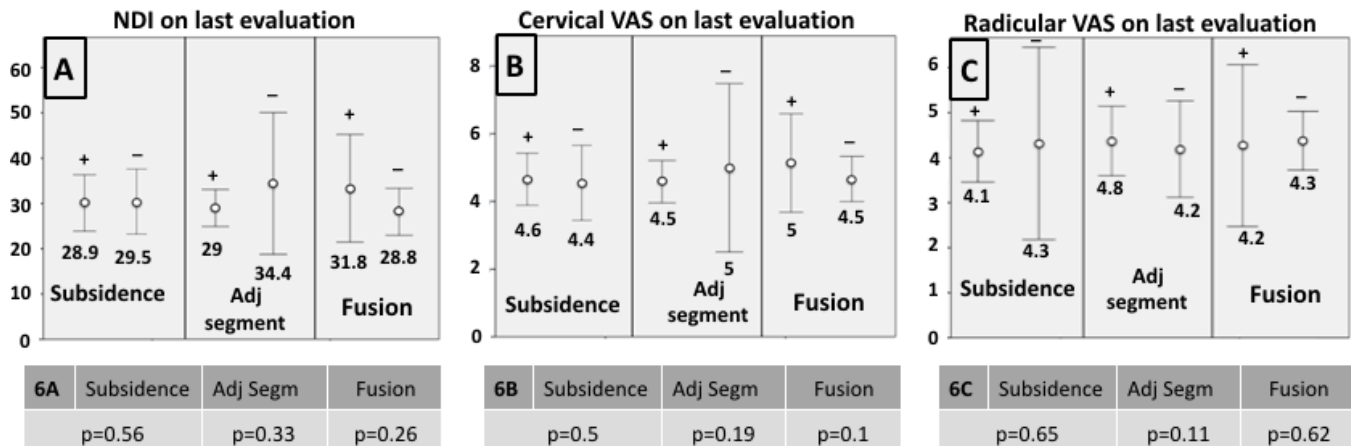


Figure 7. Error-bar charts showing the mean value of clinical parameters for evaluation of patients with cervical spine degenerative disease and their relationship with postoperative subsidence, adjacent segment degeneration (Adj segment), and bony fusion (Fusion) following cervical sagittal vertical axis anterior cervical discectomy and fusion technique. (A) NDI, Neck Disability Index; (B) cervical VAS, cervical pain visual analog scale; (C) radicular VAS, radicular pain visual analog scale. + indicates that the factor (fusion, adjacent segment degeneration or fusion) was present; - indicates that the factor (fusion, adjacent segment degeneration or fusion) was absent. P values were obtained with Student's t test for independent values, and significant values were highlighted in bold numbers.

ACDF with cages and plate, as this procedure increases lordosis in a higher value than stand-alone techniques and possibly diminishes rates of subsidence, which have an impact on reoperation rates.

Several cervical cages have been used for stand-alone ACDF, but there are few studies that compare clinical and radiological results. The first stand-alone cages available were placed without fixation systems to the adjacent vertebral bodies; these cages consist of polyether ether ketone-based cages with antimigration teeth

that resists implant migration, 2 vertical x-ray markers that facilitate proper implant position, and radiolucent material that provides visibility of implant to observe progression of bony union. More recently there are stand-alone cages available with self-locking systems that allow them to be fixated to the adjacent vertebral bodies with rods or clips systems. Most of these implants are also polyether ether ketone- and titanium-based cages, and self-locking systems are made in order to prevent migration of the implant. We compare the results with a

Table 5. Comparative analysis of clinical and radiological outcomes between patients surgically treated with Aleutian and Coalition cervical cages.

Characteristic	Aleutian	Coalition	P
Age, y, mean (SD)	52.7 (10.6)	53.4 (10.9)	0.56
Gender, women, %	65.7%	44.4%	0.06
Cervical levels, multilevel, n (%)	18 (51.4)	19 (42.2)	0.5
Smokers, %	37.1%	37.5%	0.9
Osteoporosis, %	22.5%	14.1%	0.06
Surgical complications, %	2.8%	2%	0.8
Follow time, mo, mean (SD)	23.8 (19)	11.5 (7.3)	< 0.0001
Neck Disability Index, mean (SD)			
Preoperative	39.2 (10.4)	40.9 (15)	0.5
Postoperative	23.4 (13.4)	30.5 (18.3)	0.05
Last evaluation	27.2 (15.5)	31 (18.7)	0.3
Cervical VAS, mean (SD)			
Preoperative	6.9 (2.2)	7.2 (2.1)	0.5
Postoperative	3.5 (2.2)	4.8 (2.5)	0.02
Last evaluation	4.1 (2.3)	4.9 (2.8)	0.2
Radicular EVA, mean (SD)			
Preoperative	7.4 (2.2)	7.2 (2)	0.7
Postoperative	3.4 (2.2)	4.2 (2.5)	0.1
Last evaluation	4 (2.4)	4.5 (3)	0.4
Japanese Orthopedic Association Scale, mean (SD)			
Preoperative	15.7 (0.9)	15.6 (1.7)	0.7
Postoperative	17.2 (1)	16.8 (1.6)	0.2
Last evaluation	17 (0.9)	16.8 (1.5)	0.5
Fusion rate, %	91.4%	80%	0.15
Subsidence rate, %	45.7%	22.2%	0.02
Adjacent segment rate, %	8.5%	4.4%	0.4
Required new surgery, n (%)	4 (11.4%)	2 (4.4%)	0.2

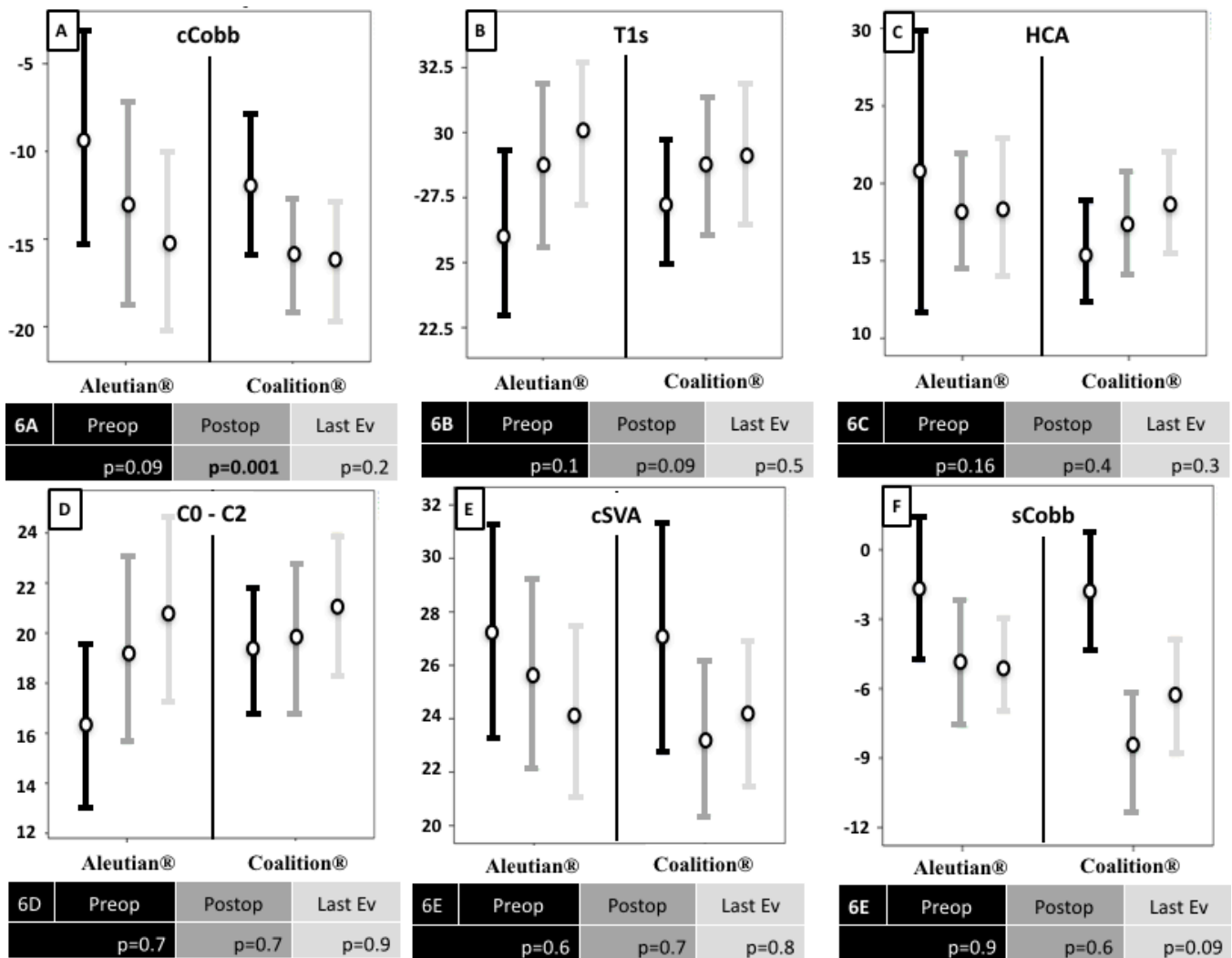


Figure 8. Error-bar charts showing the cervical radiological angles during preoperative (Preop), postoperative (Postop), and last evaluation (Last Ev), comparing both surgical implants, Aleutian and Coalition cages. On boxes below the charts, the P value is shown comparing the Aleutian vs Coalition groups. (A) cCobb, Cervical Cobb angle; (B) T1s, T1 slope; (C) HCA, Harrison's cervical angle; (D) C0 - C2, C0 - C2 Cobb's angle; (E) cSVA, cervical sagittal vertical axis; and (F) sCobb, segmental Cobb's angle of surgically treated level.

stand-alone cage (Aleutian, Figure 3B) and self-locking stand-alone cage (Coalition, Figure 3A), and we found several differences on clinical and radiological evaluation. Patients tend to have better clinical outcomes on immediate postoperative clinical scores with the Aleutian cages, but this clinical benefit was lost on follow-up (Table 5). On radiological outcome, the Coalition cages tend to give a better cervical profile with higher cervical lordosis achieved, but this benefit was also lost during follow-up. The Aleutian cages had higher rates of cage subsidence, but this had no clinical or radiological impact during follow-up. With these results, we can conclude that both cages are comparable as stand-alone techniques for ACDF surgery.

This study has some limitations. It is a retrospective case series of patients, and selection bias could have been introduced through the opinion of

including neurosurgery team in selecting the patients, as we decided to perform a robust comparison. Cervical cage use on each patient was decided based on the availability of the implants, and the Aleutian cage was first available for the hospital, so this group of patients had longer follow-up. Prospective studies with a comparative group of patients surgically treated with ACDF with cages and plates are suggested with a complete evaluation of sagittal spine balance, in order to establish if there is a relationship between global spine sagittal balance and clinical outcomes.

CONCLUSIONS

Cervical sagittal balance is an important parameter directly related to clinical outcome in patients with cervical spine degenerative disease surgically treated

with ACDF. No significant clinical or radiological differences were found between Aleutian and Coalition implants, and even a higher incidence of subsidence was found with Aleutian implant, there was no significant clinical difference during follow-up.

REFERENCES

- Smith GW, Robinson RA. The treatment of certain cervical-spine disorders by anterior removal of the intervertebral disc and interbody fusion. *The Journal of Bone & Joint Surgery*. 1958;40(3):607–624. doi:10.2106/00004623-195840030-00009
- Chen Y, Lü G, Wang B, Li L, Kuang L. A comparison of anterior cervical discectomy and fusion (ACDF) using self-locking stand-alone polyetheretherketone (PEEK) cage with ACDF using cage and plate in the treatment of three-level cervical degenerative spondylopathy: a retrospective study with 2-year follow-up. *Eur Spine J*. 2016;25(7):2255–2262. doi:10.1007/s00586-016-4391-x
- Moon HJ, Kim JH, Kim JH, Kwon TH, Chung HS, Park YK. The effects of anterior cervical discectomy and fusion with stand-alone cages at two contiguous levels on cervical alignment and outcomes. *Acta Neurochir (Wien)*. 2011;153(3):559–565. doi:10.1007/s00701-010-0879-z
- Teo AQA, Thomas AC, Hey HWD. Sagittal alignment of the cervical spine: do we know enough for successful surgery? *J Spine Surg*. 2020;6(1):124–135. doi:10.21037/jss.2019.11.18
- Vernon H, Mior S. The neck disability index: a study of reliability and validity. *J Manipulative Physiol Ther*. 1991;14(7):409–415.
- Association JO. Scoring system for cervical myelopathy. *J Jpn Orthop Assoc*. 1994;68:490–503.
- Scheer JK, Tang JA, Smith JS, et al. Cervical spine alignment, sagittal deformity, and clinical implications: a review. *J Neurosurg Spine*. 2013;19(2):141–159. doi:10.3171/2013.4.SPINE12838
- Donk RD, Fehlings MG, Verhagen WIM, et al. An assessment of the most reliable method to estimate the sagittal alignment of the cervical spine: analysis of a prospective cohort of 138 cases. *J Neurosurg Spine*. 2017;26(5):572–576. doi:10.3171/2016.10.SPINE16632
- Liu W, Rong Y, Chen J, et al. Cervical sagittal alignment as a predictor of adjacent-level ossification development. *J Pain Res*. 2018;11:1359–1366. doi:10.2147/JPR.S160472
- Oh JK, Kim TY, Lee HS, et al. Stand-alone cervical cages versus anterior cervical plate in 2-level cervical anterior interbody fusion patients: clinical outcomes and radiologic changes. *J Spinal Disord Tech*. 2013;26(8):415–420. doi:10.1097/BSD.0b013e31824c7d22
- Lin B-J, Hong K-T, Lin C, et al. Impact of global spine balance and cervical regional alignment on determination of postoperative cervical alignment after laminoplasty. *Medicine (Baltimore)*. 2018;97(45):45. doi:10.1097/MD.00000000000013111
- De Leo-Vargas RA, Muñoz-Romero I, Mondragón-Soto MG, Martínez-Anda JJ. Locking stand-alone cage constructs for the treatment of cervical spine degenerative disease. *Asian Spine J*. 2019;13(4):630–637. doi:10.31616/asj.2018.0234
- Kao T-H, Wu C-H, Chou Y-C, Chen H-T, Chen W-H, Tsou H-K. Risk factors for subsidence in anterior cervical fusion with stand-alone polyetheretherketone (PEEK) cages: a review of 82 cases and 182 levels. *Arch Orthop Trauma Surg*. 2014;134(10):1343–1351. doi:10.1007/s00402-014-2047-z
- Harada GK, Tao Y, Louie PK, et al. Cervical spine MRI phenotypes and prediction of pain, disability and adjacent segment degeneration/disease after ACDF. *J Orthop Res*. 2021;39(3):657–670. doi:10.1002/jor.24658
- Scheer JK, Tang JA, Smith JS, et al. Cervical spine alignment, sagittal deformity, and clinical implications: a review. *J Neurosurg Spine*. 2013;19(2):141–159. doi:10.3171/2013.4.SPINE12838
- Ling FP, Chevillotte T, Leglise A, Thompson W, Bouthors C, Le Huec JC. Which parameters are relevant in sagittal balance analysis of the cervical spine? A literature review. *European spine journal: official publication of the European spine society, the European spinal deformity society, and the European section of the cervical spine research society*. Feb. 2018;27(Suppl 1):8–15. doi:10.1007/s00586-018-5462-y
- Alijani B, Rasoulia J. The sagittal balance of the cervical spine: radiographic analysis of interdependence between the occipitocervical and spinopelvic alignment. *Asian Spine J*. 2020;14(3):287–297. doi:10.31616/asj.2019.0165
- Nguyen N-LM, Baluch DA, Patel AA. Cervical sagittal balance. *Contemporary Spine Surgery*. 2014;15(1):1–7. doi:10.1097/01.CSS.0000441214.29279.d0
- Lee SH, Son ES, Seo EM, Suk KS, Kim KT. Factors determining cervical spine sagittal balance in asymptomatic adults: correlation with spinopelvic balance and thoracic inlet alignment. *Spine J*. 2015;15(4):705–712. doi:10.1016/j.spinee.2013.06.059
- Zaidman N, De Witte O. Cervical sagittal balance: a predictor of neck pain after anterior cervical spine surgery? *Br J Neurosurg*. 2020;1–5. doi:10.1080/02688697.2020.1850643
- Knott PT, Mardjetko SM, Tychy F. The use of the T1 sagittal angle in predicting overall sagittal balance of the spine. *Spine J*. 2010;10(11):994–998. doi:10.1016/j.spinee.2010.08.031
- Martini ML, Neifert SN, Chapman EK, Mroz TE, Rasouli JJ. Cervical spine alignment in the sagittal axis: a review of the best validated measures in clinical practice. *Global Spine J*. 2021;11(8):1307–1312. doi:10.1177/2192568220972076
- Katsuura A, Hukuda S, Saruhashi Y, Mori K. Kyphotic malalignment after anterior cervical fusion is one of the factors promoting the degenerative process in adjacent intervertebral levels. *European spine journal: official publication of the European spine society, the European spinal deformity society, and the European section of the cervical spine research society*. Aug. 2001;10(4):320–324. doi:10.1007/s005860000243
- Gercek E, Arlet V, Delisle J, Marchesi D. Subsidence of stand-alone cervical cages in anterior interbody fusion: warning. *European spine journal: official publication of the European spine society, the European spinal deformity society, and the European section of the cervical spine research society*. Oct. 2003;12(5):513–516. doi:10.1007/s00586-003-0539-6
- Li Z, Wang H, Li L, Tang J, Ren D, Hou S. A new zero-profile, stand-alone fidji cervical cage for the treatment of the single and multilevel cervical degenerative disc disease. *J Clin Neurosci*. 2017;41:115–122. doi:10.1016/j.jocn.2017.02.043
- Hilibrand AS, Carlson GD, Palumbo MA, Jones PK, Bohlman HH. Radiculopathy and myelopathy at segments adjacent to the site of a previous anterior cervical arthrodesis. *J Bone Joint Surg Am*. 1999;81(4):519–528. doi:10.2106/00004623-199904000-00009
- Ji GY, Oh CH, Shin DA, et al. Stand-alone cervical cages versus anterior cervical plates in 2-level cervical anterior interbody fusion patients: analysis of adjacent segment degeneration.

J Spinal Disord Tech. 2015;28(7):E433–E438. doi:10.1097/BSD.0b013e3182a355ad

28. Yang X, Bartels RHMA, Donk R, Arts MP, Goedmakers CMW, Vleggeert-Lankamp CLA. The association of cervical sagittal alignment with adjacent segment degeneration. *Eur Spine J.* 2020;29(11):2655–2664. doi:10.1007/s00586-019-06157-0

29. Park MS, Kelly MP, Lee DH, Min WK, Rahman RK, Riew KD. Sagittal alignment as a predictor of clinical adjacent segment pathology requiring surgery after anterior cervical arthrodesis. *Spine J.* 2014;14(7):1228–1234. doi:10.1016/j.spinee.2013.09.043

30. Cheung ZB, Gidumal S, White S, et al. Comparison of anterior cervical discectomy and fusion with a stand-alone interbody cage versus a conventional cage-plate technique: a systematic review and meta-analysis. *Global Spine J.* 2019;9(4):446–455. doi:10.1177/2192568218774576

31. Zhao Y, Yang S, Huo Y, Li Z, Yang D, Ding W. Locking stand-alone cage versus anterior plate construct in anterior cervical discectomy and fusion: a systematic review and meta-analysis based on randomized controlled trials. *Eur Spine J.* 2020;29(11):2734–2744. doi:10.1007/s00586-020-06561-x

32. Choi MK, Kim SB, Park CK, Kim SM. Comparison of the clinical and radiologic outcomes obtained with single- versus two-level anterior cervical decompression and fusion using

stand-alone PEEK cages filled with allograft. *Acta Neurochir (Wien).* 2016;158(3):481–487. doi:10.1007/s00701-015-2692-1

Funding: The authors received no financial support for the research, authorship, and/or publication of this article.

Declaration of Conflicting Interests: The authors report no conflicts of interest in this work.

Corresponding Author: Jaime Jesus Martinez-Anda, Neurological Center, ABC Medical Center, Carlos Graef Fernández St. 154, P.C. 05300, Mexico City, Mexico; dr.martinezanda@gmail.com

Published 19 August 2022

This manuscript is generously published free of charge by ISASS, the International Society for the Advancement of Spine Surgery. Copyright © 2022 ISASS. To see more or order reprints or permissions, see <http://ijssurgery.com>.