

# Single-Position Fluoroscopy-Guided Lateral Lumbar Interbody Fusion With Intraoperative Computed Tomography–Navigated Posterior Pedicle Screw Fixation: Technical Report and Literature Review

Jacob L. Goldberg, Lynn B. McGrath, Jr, Sertac Kirnaz, Fabian Sommer, Joseph A. Carnevale, Branden Medary and Roger Härtl

*Int J Spine Surg* 2022, 16 (S1) S9-S16

doi: <https://doi.org/10.14444/8231>

<https://www.ijssurgery.com/content/16/S1/S9>

This information is current as of May 4, 2025.

---

**Email Alerts** Receive free email-alerts when new articles cite this article. Sign up at:  
<http://ijssurgery.com/alerts>

# Single-Position Fluoroscopy-Guided Lateral Lumbar Interbody Fusion With Intraoperative Computed Tomography–Navigated Posterior Pedicle Screw Fixation: Technical Report and Literature Review

JACOB L. GOLDBERG, MD<sup>1</sup>; LYNN B. MCGRATH, JR, MD<sup>1</sup>; SERTAC KIRNAZ, MD<sup>1</sup>; FABIAN SOMMER, MD<sup>1</sup>; JOSEPH A. CARNEVALE, MD<sup>1</sup>; BRANDEN MEDARY, BS<sup>1</sup>; AND ROGER HÄRTL, MD<sup>1</sup>

<sup>1</sup>Department of Neurosurgery, New York Presbyterian Hospital/Weill Cornell Medicine<sup>1</sup> New York, NY, USA

## ABSTRACT

Lateral lumbar interbody fusion (LLIF) is a powerful tool in minimally invasive spine surgery with high rates of fusion, excellent indirect decompression, and deformity correction. LLIF offers advantages compared with anterior lumbar interbody fusion including a more favorable complication profile. Traditionally, the interbody fusion is performed in the lateral position and fluoroscopy-assisted pedicle screw fixation performed with the patient repositioned prone. The evolution of both pedicle screw technology and intraoperative navigation has enhanced the feasibility of single (lateral)-position surgery. Early reports using fluoroscopy-assisted pedicle screws and computer or robotic navigation suggest this technique can be performed safely and accurately. The purpose of this brief report is to provide the technical steps, workflow, as well as pearls and pitfalls for single-position LLIF with true intraoperative computed tomography navigation-guided percutaneous pedicle screw fixation. A case example is included for illustration.

Lumbar Spine

Keywords: single-position lateral lumbar interbody fusion, LLIF, intraoperative navigation

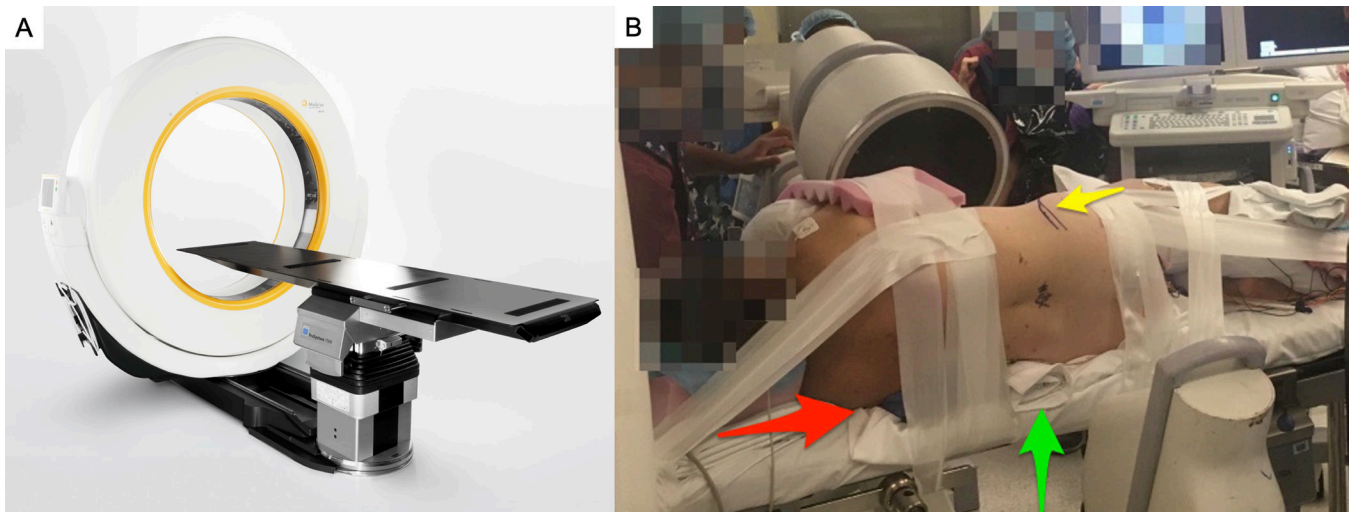
## INTRODUCTION

Lateral lumbar interbody fusion (LLIF) was first described as a lateral, anterior to the psoas approach to the lumbar spine<sup>1</sup> in 1997 by Mayer et al. In 2006, Ozgur et al reported a modified technique using a transpsoas approach to the disc space.<sup>2</sup> LLIF allows for the indirect decompression neural elements via restoration of the disc space height.<sup>3</sup> Wide access to the disc space allows LLIF to be used in achieving significant deformity corrections.<sup>4</sup> Additionally, lateral approaches can decrease the risks associated with anterior approaches to the lumbar spine including injury to the great vessels and abdominal organs.<sup>5,6</sup> The lateral approach is also attractive as access surgeons are not routinely used. As a result, the lateral approach to the lumbar interbody space is becoming a powerful tool in minimally invasive spine surgery (MISS).

Placement of interbody grafts through a lateral approach is often performed in conjunction with other instrumentation for fixation. Biomechanical evidence suggests that posterior instrumentation improves stability in conjunction with laterally placed cages.<sup>7</sup> Additionally, in those at risk for cage subsidence and

pseudarthrosis, posterior fusion at the time of index surgery has been suggested as a risk mitigation strategy.<sup>8</sup> To achieve combine cage placement with posterior fixation, many surgeons begin the operation with the patient positioned laterally for cage placement and reposition the patient prone for pedicle screw fixation. Inherent to this process is an increase in operative time associated with the position change, the subsequent need to resterilize and drape the operative field, and the increased cost associated with these requirements. This approach also carries risks associated with repositioning, such as unintentional extubation and potential cage migration. With the prone position, numerous risks have been reported. For example, the prone position has been associated with cardiopulmonary compromise, increased intra-abdominal pressure resulting in abdominal compartment syndrome, as well as increased risk of postoperative vision loss.<sup>9</sup>

Performance of both the cage placement as well as pedicle screw fixation in a single lateral position presents an appealing technical modification. A systematic literature review comparing single position to lateral then prone LLIF with posterior fusion found similar outcomes between the techniques with



**Figure 1.** (A) Intraoperative computed tomography (CT) with integrated flat operative bed (AIRO, Brainlab). Photograph used with permission from Brainlab). (B) Patient positioning. Patient is on a flat, integrated CT table and is secured with silk tape and padded. Both lateral and posterior operative sites are accessible. The iliac crest is marked (yellow arrow). The patient is as close to the edge of the operative table as safely possible (red arrow). A sheet is rolled to create lateral flexion and to minimize patient movement during the procedure (green arrow).

a trend toward shorter operating time and length of hospital stay with the single-position technique.<sup>10</sup> In this brief report, we provide the technical steps and workflow insights for single-position LLIF with navigation-guided percutaneous pedicle screws. Published reports of single-stage LLIF with a variety of techniques for pedicle screw placement are reviewed.

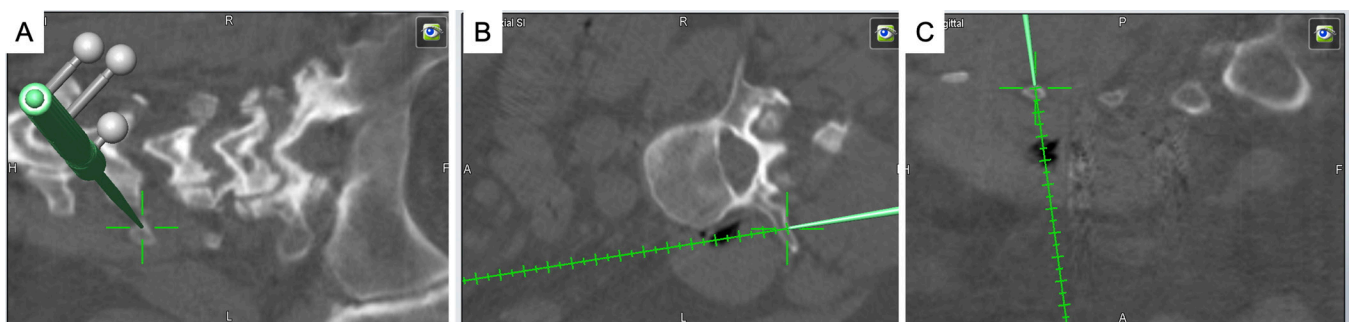
## OPERATIVE TECHNIQUE

### General Considerations

Lateral access surgeries are performed with general anesthesia and intraoperative neuromonitoring. The patient is intubated, and neuromonitoring electrodes are placed on a standard hospital bed. The patient is then transferred to a flat operating room table integrated with the intraoperative computed tomography (iCT) (Figure 1). Fluoroscopy is used to guide placement of the interbody cage, and iCT is used for the percutaneous pedicle screw placement.

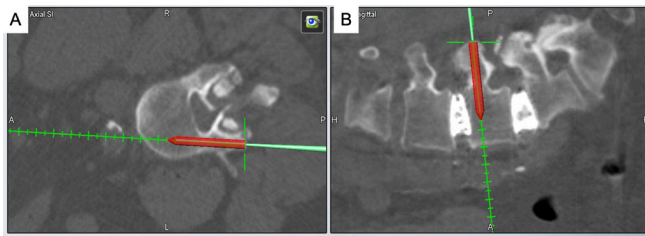
### Positioning

The patient is placed in the lateral position, carefully padded, and secured to the operative table with silk tape. Padding is placed in the axilla and under the hip to promote lateral flexion and allow access to disc spaces otherwise obstructed by either the ribs or the iliac crest (Figure 1). Hip padding further serves to immobilize the lumbar spine, theoretically increasing the registration accuracy when intraoperative navigation is used in the procedure. Care is taken when positioning the arms accounting for standard measures needed to avoid stretch or pressure injuries but also the need to use fluoroscopy to see the disc space and the subsequent need for the body to enter the computed tomography (CT) scanner when the intraoperative scan is acquired. Additionally, the patient's back side is placed as close to the edge of the operating room table as safely possible. This placement allows for the placement of the



**Figure 2.** Accuracy of intraoperative navigation is verified at the transverse process of the most cranial level (furthest from iliac crest reference array). (A) Coronal, (B) axial, and (C) sagittal.





**Figure 3.** Pedicle screws of various sizes and dimensions can be virtually sized (red). (A) Axial and (B) sagittal.

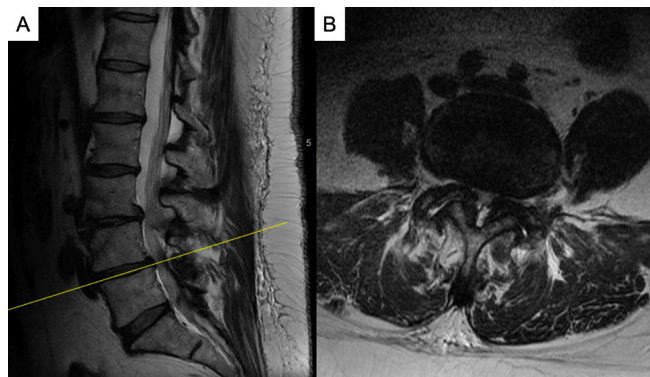
downside pedicle screws without obstruction from the operating room table.

### Interbody Cage Placement

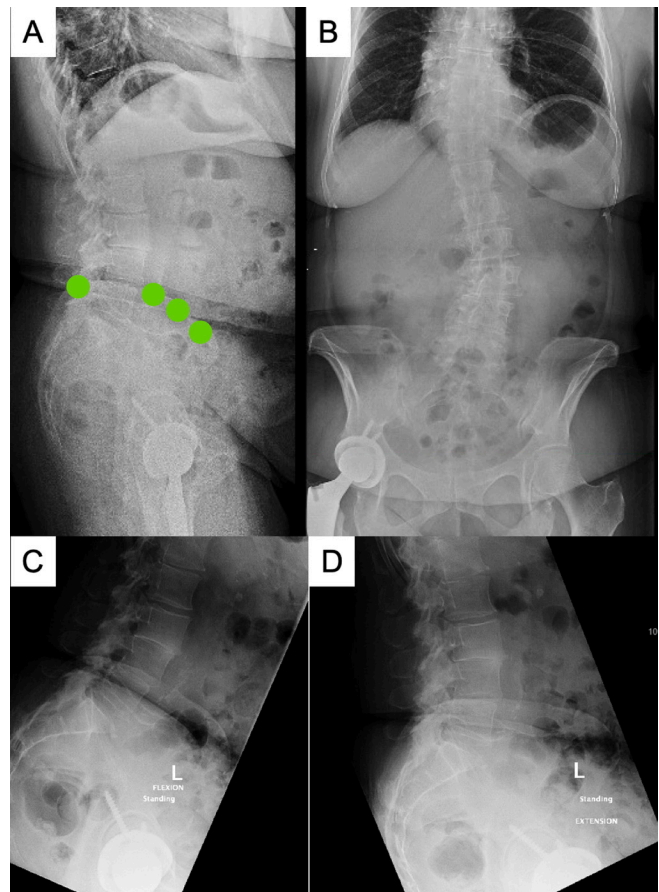
The lateral incision site and the posterior sites for pedicle screw insertion are widely prepped and draped. LLIF is performed in the usual fashion.<sup>11</sup> The minimally invasive approach is facilitated through the use of retractors with integrated neuromonitoring.<sup>11</sup> Discectomy, end plate preparation, and cage sizing and placement are performed with a combination of visual inspection and fluoroscopic guidance.

### Navigated Percutaneous Pedicle Screw Fixation

Steinmann pins are rigidly affixed to the iliac crest to support the navigation reference array. The operating table is tilted 15° away from the surgeon to facilitate placement of the “downside” pedicle screws. The table is tilted before the intraoperative scan is acquired to minimize potential sources for navigational inaccuracy. An iCT is then acquired. Accuracy of the navigation is confirmed. The scan is reviewed to assess the placement of the interbody cage. The following key steps are highlighted in the



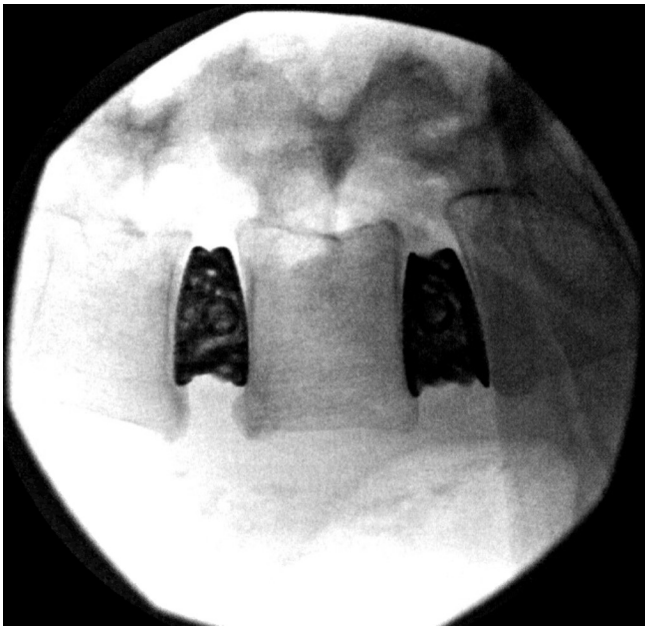
**Figure 4.** Magnetic resonance imaging (MRI) lumbar spine. (A) Sagittal T2 MRI lumbar spine most notable for loss of disc height at L3/4 and L4/5. Severe stenosis is evident at L3/4 and L4/5. (B) Axial T2 MRI at L4/5 demonstrating severe central stenosis.



**Figure 5.** Plain film x-ray images. (A) Standing lateral x-ray image. Significant disc height loss is evident in L3/4 and L4/5. Note level of iliac crest (green dots) allowing access to L4/5 disc space laterally. (B) Standing anteroposterior x-ray image without major coronal imbalance. Levoscoliosis with apex at L3 measures 24° and minor curve between T7 and T12 measures 18°. (C) Flexion x-ray images and (D) extension view demonstrate instability with pathologic movement most notable at L4/5.

performance of the navigated percutaneous pedicle screw placement:

1. The navigation pointer is used to determine the entry point and trajectory for each pedicle screw.
2. Skin incision, soft tissue dissection, and a single fascial incision are performed in usual fashion.
3. The screw entry point, at the junction of the facet and the transverse process, is palpated. The navigation pointer is placed onto this site to confirm navigational accuracy (Figure 2).
4. Screw diameter and length are “virtually” tested via the navigation system and the optimal size is determined (Figure 3).
5. Instrumentation is started at the “downside” and caudal-most pedicle where navigation is theoretically most accurate.
6. After all pedicle screws are placed, a titanium rod is contoured and tunneled beneath the fascia and



**Figure 6.** Intraoperative fluoroscopy (lateral view) demonstrating lordotic interbody cages placed at L3/4 and L4/5.

through each of the screw tulips. A cap is then placed and tightened.

7. Hemostasis is obtained at all incision sites, copiously irrigated with antibiotic solution, and closed in the usual fashion.

## ILLUSTRATIVE CASE

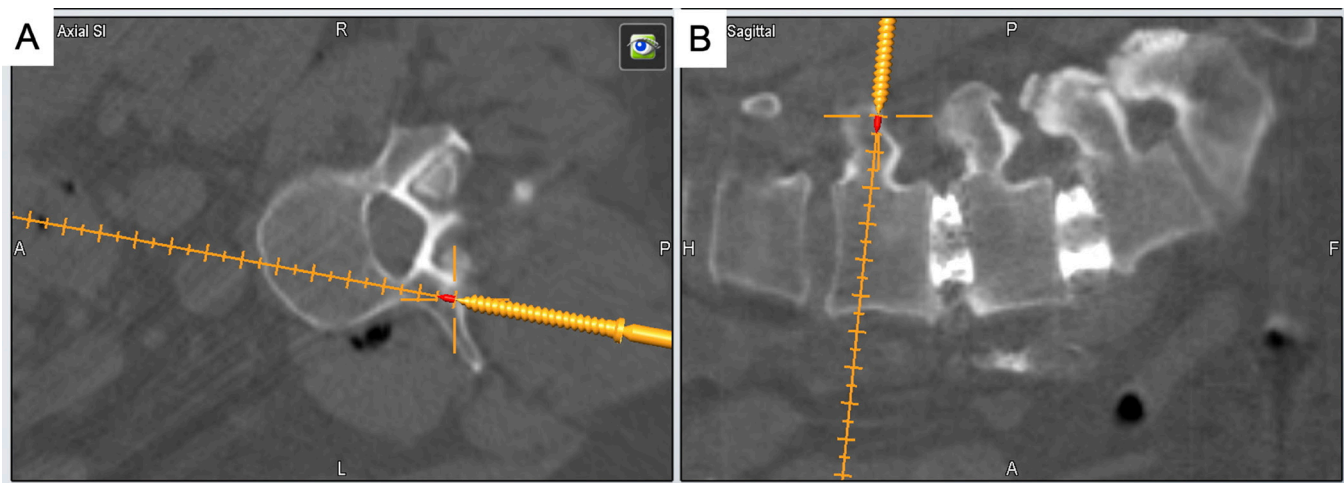A 62-year-old woman with no significant past medical history presented with 2 years of worsening mechanical low back pain and neurogenic claudication without significant improvement after conservative measures including physical therapy.

Magnetic resonance imaging (MRI) (Figure 4) revealed significant loss of disc height at L3/4 and L4/5 as well as significant central stenosis at those levels. Plain films (Figure 5) confirmed these findings and redemonstrated a mild degenerative scoliotic deformity, which had been stable for 10 years. Flexion and extension x-ray images revealed a mobile spondylolisthesis worst at L4/5. Given the patient’s symptomatic central stenosis and symptomatic mobile spondylolisthesis, she underwent a single-position L3-5 LLIF with navigated pedicle screw instrumentation. Lateral cage placement was performed in the standard fashion. Final cage position was confirmed via lateral fluoroscopy (Figure 6). After cage placement, an iCT was acquired to navigate the pedicle screws (Figures 7 and 8). The procedure was uncomplicated. Standing x-ray images on postoperative day 1 revealed intact hardware and restoration of disc height at the index levels (Figure 9). At 1-year follow-up, the patient reported near complete resolution of her preoperative symptoms.

## DISCUSSION

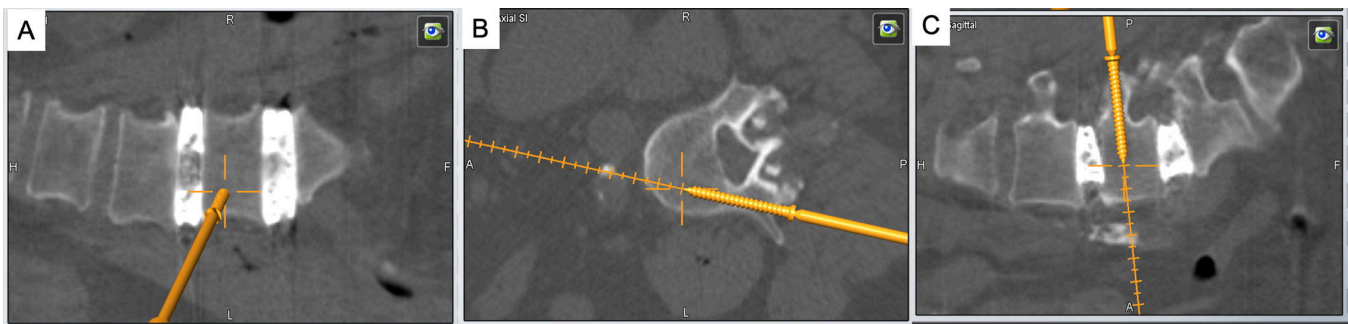
### Use of Fluoroscopy and iCT

The patterns of use of fluoroscopy and iCT during LLIF with posterior fixation differ by surgeon and remain an area of investigation.<sup>12</sup> We prefer fluoroscopy alone during this phase of the procedure as this provides for essentially “real-time” imaging, which is helpful in verifying optimal cage sizing, fit, and positioning. If iCT is used to navigate LLIF cage placement, extreme care should be taken to ensure the accuracy of the navigation, which may be susceptible to error as a result of the impaction of the tools for disc space preparation



**Figure 7.** Percutaneous pedicle screws with integrated stylet tip (red) are used. The stylet tip is placed at the entry point for the pedicle screw, and the trajectory is optimized. (A) Axial and (B) sagittal.





**Figure 8.** As the pedicle screw is advanced, the trajectory is continuously monitored via navigation. Additionally, after the screw enters the vertebral body, the stylet tip is retracted (red tip no longer visible). (A) Coronal, (B) axial, and (C) sagittal.

as well as the augmentation in spinal alignment that occurs with placement of a disc height restoring cage. For these reasons, it is only until after the LLIF has been performed that the iliac crest pins, reference array, and intraoperative navigational scan are acquired.

### Case Series and Outcomes

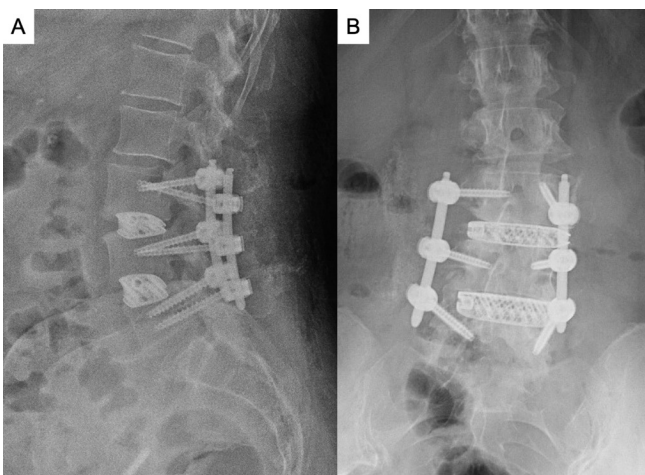
#### *Fluoroscopy-Guided Pedicle Screw Placement*

Drazin et al performed a retrospective propensity matched review of 20 patients evaluating single-position LLIF with posterior fixation compared with lateral followed by prone surgery.<sup>13</sup> This study involved the use of fluoroscopy alone for both the lateral cage placement and the pedicle screw placement. The authors found no difference between the techniques in relation to intraoperative blood loss, length of hospital stay, and clinical or radiographic outcome. The authors found an average decrease in operative time of 60 minutes per case using the single-position technique. Importantly, the authors cautioned against the use of the single-position technique in patients with difficult pedicle anatomy.

Blizzard et al reported a case series of 72 consecutive patients (300 pedicle screws) who underwent fluoroscopy-only single-position lateral cage placement and posterior pedicle screw fixation.<sup>14</sup> The authors found the average placement time per screw and average total operative time to be 5.9 min/screw and 87.9 minutes, respectively. Average fluoroscopy time was 15 s/screw. The authors reported a pedicle screw breach rate (as determined by postoperative CT) to be 5.1% with 2 patients (2.8%) requiring reoperation for screw malposition with subsequent resolution of radicular symptoms. The authors noted their complication rate was similar to that published in the literature and found the single-position technique to improve operative efficiency and resource utilization. Interestingly, the authors commented on the increased difficulty in S1 screw placement as a result of the added complexity of identifying the screw entry point in the lateral position in the sacrum using fluoroscopy.

#### iCT-Guided Pedicle Screws

Sellin et al conducted a small retrospective review of 4 patients who underwent single-position lateral interbody fusion with simultaneous placement of CT-guided pedicle screw fixation.<sup>15</sup> A total of 4 patients underwent L4-5 LLIF with 14 posterior pedicle screws placed. All patients were selected for single-position surgery due to medical comorbidities or other factors, which the senior authors deemed to put the patients at risk for prone surgery. Overall, the authors reported a satisfaction with this technique citing the potential for operative efficiency and decreased overall radiation exposure. However, the authors noted workflow issues and nuances that contributed to early technical difficulties. For example, the authors reported 2 of 14 pedicle screws (14%) were complicated by lateral breach requiring revision. Both screws were placed on the “downside,” and lateral breach was felt to be related to inability of the surgeon to medialize due



**Figure 9.** Postoperative x-ray images demonstrating intact hardware and increased disc space height at L3/4 and L4/5 with improved lumbar lordosis. (A) Lateral and (B) anteroposterior.

**Table.** Single-stage lateral lumbar interbody fusion publications.

Authors	Number of Patients	Design of Study	Simultaneous Lateral and Posterior Instrumentation (Parallel) or Sequential (Series)	Intraoperative Imaging for Pedicle Screw Placement	Total Operative Time (Average Minutes)	Pedicle Breach Rate	Rate of Screw Misplacement Requiring Revision	Return to OR for Screw Revision (n)
Drazin et al <sup>13</sup>	10 (SP), 10 (DP)	Retrospective	Series	Fluoroscopy	131 (SP), 190 (DP)	NR	NR	1(SP), 0 (DP)
Blizzard et al <sup>14</sup>	72 (SP), 0 (DP)	Retrospective	Series	Fluoroscopy	87.9	5.1%	2.8%	2
Ziino et al <sup>19</sup>	42 (SP), 24 (DP)	Retrospective	Series	Fluoroscopy	149 (SP), 226 (DP)	NR	NR	2 (SP), 0 (DP)
Sellin et al <sup>15</sup>	4 (SP), 0 (DP)	Retrospective	Parallel	Cone beam iCT	138 (SP)	14%	14%	1 (SP)
Huntsman et al <sup>20</sup>	55 (SP), 0 (DP)	Retrospective	Series	Robotic guidance: preop CT (14 pts), fan or cone beam iCT (41 pts)	155 (SP)	0	0	0
Hiyama et al <sup>16</sup>	19 (SP), 26 (DP)	Retrospective	Series	Fluoroscopy	98 (SP), 130 (DP)	NR	NR	NR
Ouchida et al <sup>17</sup>	51 (SP), 51 (DP)	Retrospective	Parallel	Fan beam iCT	93 (SP), 121 (DP)	9.5% (SP), 12.5% (DP)	0	0
Buckland et al <sup>18</sup>	237 (SP), 153 (DP)	Retrospective	Series	Fluoroscopy, iCT, iCT with robotic guidance	103 (SP), 306 (DP)	NR	1.56% (SP), 2.34% (DP)	NR

Abbreviations: CT, computed tomography; DP, dual position; iCT, intraoperative computed tomography; NR, not reported; SP, single position.

to obstruction from the operative bed—an important preoperative consideration. While encouraging, the generalizability of this series is potentially limited due to the small sample size and patient selection bias.

The 8 largest studies encompassing a total of 754 patients undergoing either single-position or multiple-position LLIF are summarized in the Table.<sup>13–20</sup> Retrospective studies evaluating single-position vs dual-position techniques tended to find single-position techniques associated with shorter operative times. Two studies performed the interbody placement and posterior instrumentation simultaneously, while the remaining 6 studies performed these techniques sequentially. While performance of both the lateral and posterior operations simultaneously should logically result in shorter operative times, other differences in study techniques and populations preclude this direct analysis. Regardless of single-position or multiposition technique, or type of imaging/navigation modality both the rates of pedicle screw misplacement requiring revision and rate of return to the OR for revision were low.

The work done thus far studying single-position LLIF techniques has raised questions that will need to be addressed with larger trials. For example, across studies with greater than 10 patients, the overall rates of screw misplacement requiring revision ranged from 0% to 2.8%. As a result of this overall low rate of pedicle screw misplacement, larger studies will be needed to evaluate whether this complication is at all attributable to the imaging modality, increased in frequency when instrumenting the

“downside” pedicle, and whether navigation techniques can be used to mitigate this risk. An additional important future focus of study is cost analysis. Fluoroscopy-based CT (cone beam) and true iCT (fan beam) have upfront costs of \$600,000 and \$1.2 million, respectively, in addition to yearly support, maintenance, and software costs.<sup>21</sup> However, the true cost of this equipment and burden to the healthcare system is significantly mitigated if these technologies prevent revision surgeries.<sup>22</sup> Last, efforts to study and decrease the radiation exposure to both the patient and surgical team are needed. In other lumbar MISS settings, fluoroscopy CT (cone beam) and true iCT (fan beam) patient radiation dose have been measured at 22.5 and 13.4 mSv, respectively.<sup>23,24</sup> In these settings, true iCT offering the ability to be protocolized to deliver lower radiation doses.<sup>22</sup> Studies specifically evaluating the patient and surgical team dose during LLIF are needed.

## CONCLUSIONS

LLIF is an important tool in the growing MISS armamentarium. Through continued innovation in intraoperative navigation technology, MISS instrumentation, and continued reappraisal of surgical technique, the LLIF technique continues to evolve. Innovators have previously described single-position LLIF with placement of the interbody cage and posterior instrumentation occurring simultaneously or sequentially and with a variety of operative adjuncts. Regardless of specific technique, early reports suggest this procedure is safely performed as a single stage, as evidenced by the low rate of complication

including misplacement of instrumentation. Larger studies are needed to further elucidate important questions regarding single-stage LLIF including analysis of cost, radiation exposure, and revision rates.

## REFERENCES

1. Greenough C. Point of view: a new microsurgical technique for minimally invasive anterior lumbar interbody fusion. *Spine*. 1997;22(6):700. doi:10.1097/00007632-199703150-00024
2. Ozgur BM, Aryan HE, Pimenta L, Taylor WR. Extreme lateral interbody fusion (XLIF): a novel surgical technique for anterior lumbar interbody fusion. *Spine J*. 2006;6(4):435–443. doi:10.1016/j.spinee.2005.08.012
3. Elowitz EH, Yanni DS, Chwajol M, Starke RM, Perin NI. Evaluation of indirect decompression of the lumbar spinal canal following minimally invasive lateral transpsoas interbody fusion: radiographic and outcome analysis. *Minim Invasive Neurosurg*. 2011;54(5–6):201–206. doi:10.1055/s-0031-1286334
4. Park H-Y, Ha K-Y, Kim Y-H, et al. Minimally invasive lateral lumbar interbody fusion for adult spinal deformity: clinical and radiological efficacy with minimum two years follow-up. *Spine (Phila Pa 1976)*. 2018;43(14):E813–E821. doi:10.1097/BRS.0000000000002507
5. Knight RQ, Schwaegler P, Hanscom D, Roh J. Direct lateral lumbar interbody fusion for degenerative conditions: early complication profile. *J Spinal Disord Tech*. 2009;22(1):34–37. doi:10.1097/BSD.0b013e3181679b8a
6. Rodgers WB, Gerber EJ, Patterson J. Intraoperative and early postoperative complications in extreme lateral interbody fusion: an analysis of 600 cases. *Spine (Phila Pa 1976)*. 2011;36(1):26–32. doi:10.1097/BRS.0b013e3181e1040a
7. Cappuccino A, Cornwall GB, Turner AWL, et al. Biomechanical analysis and review of lateral lumbar fusion constructs. *Spine (Phila Pa 1976)*. 2010;35(26 Suppl):S361–7. doi:10.1097/BRS.0b013e318202308b
8. Tempel ZJ, McDowell MM, Panczykowski DM, et al. Graft subsidence as a predictor of revision surgery following stand-alone lateral lumbar interbody fusion. *J Neurosurg Spine*. 2018;28(1):50–56. doi:10.3171/2017.5.SPINE16427
9. Kwee MM, Ho Y-H, Rozen WM. The prone position during surgery and its complications: a systematic review and evidence-based guidelines. *Int Surg*. 2015;100(2):292–303. doi:10.9738/INTSURG-D-13-00256.1
10. Guiroy A, Carazzo C, Camino-Willhuber G, et al. Single-position surgery versus lateral-then-prone-position circumferential lumbar interbody fusion: a systematic literature review. *World Neurosurg*. 2021;151:e379–e386. doi:10.1016/j.wneu.2021.04.039
11. Hood B, Vanni S. Minimally invasive extreme lateral trans-psoas approach to the lumbar spine: applications and techniques. *Spine Surgery*. 2012. doi:10.5772/36813
12. Park P. Three-dimensional computed tomography-based spinal navigation in minimally invasive lateral lumbar interbody fusion: feasibility, technique, and initial results. *Neurosurgery*. 2015;11 Suppl 2:259–267. doi:10.1227/NEU.0000000000000726
13. Drazin D, Kim TT, Johnson JP. Simultaneous lateral interbody fusion and posterior percutaneous instrumentation: early experience and technical considerations. *Biomed Res Int*. 2015;2015:458284. doi:10.1155/2015/458284
14. Blizzard DJ, Thomas JA. MIS Single-position lateral and oblique lateral lumbar interbody fusion and bilateral pedicle screw fixation: feasibility and perioperative results. *Spine (Phila Pa 1976)*. 2018;43(6):440–446. doi:10.1097/BRS.0000000000002330
15. Sellin JN, Mayer RR, Hoffman M, Ropper AE. Simultaneous lateral interbody fusion and pedicle screws (SLIPS) with CT-guided navigation. *Clin Neurol Neurosurg*. 2018;175:91–97. doi:10.1016/j.clineuro.2018.10.013
16. Hiyama A, Katoh H, Sakai D, Sato M, Tanaka M, Watanabe M. Comparison of radiological changes after single-position versus dual-position for lateral interbody fusion and pedicle screw fixation. *BMC Musculoskelet Disord*. 2019;20(1):601. doi:10.1186/s12891-019-2992-3
17. Ouchida J, Kanemura T, Satake K, Nakashima H, Ishikawa Y, Imagama S. Simultaneous single-position lateral interbody fusion and percutaneous pedicle screw fixation using O-arm-based navigation reduces the occupancy time of the operating room. *Eur Spine J*. 2020;29(6):1277–1286. doi:10.1007/s00586-020-06388-6
18. Buckland AJ, Ashayeri K, Leon C, et al. Single position circumferential fusion improves operative efficiency, reduces complications and length of stay compared with traditional circumferential fusion. *Spine J*. 2021;21(5):810–820. doi:10.1016/j.spinee.2020.11.002
19. Ziino C, Konopka JA, Ajiboye RM, Ledesma JB, Koltsov JCB, Cheng I. Single position versus lateral-then-prone positioning for lateral interbody fusion and pedicle screw fixation. *J Spine Surg*. 2018;4(4):717–724. doi:10.21037/jss.2018.12.03
20. Huntsman KT, Riggleman JR, Ahrendtsen LA, Ledonio CG. Navigated robot-guided pedicle screws placed successfully in single-position lateral lumbar interbody fusion. *J Robot Surg*. 2020;14(4):643–647. doi:10.1007/s11701-019-01034-w
21. Malham GM, Wells-Quinn T. What should my hospital buy next? Guidelines for the acquisition and application of imaging, navigation, and robotics for spine surgery. *J Spine Surg*. 2019;5(1):155–165. doi:10.21037/jss.2019.02.04
22. Hussain I, Cosar M, Kirnaz S, et al. Evolving navigation, robotics, and augmented reality in minimally invasive spine surgery. *Global Spine J*. 2020;10(2 Suppl):22S–33S. doi:10.1177/2192568220907896
23. Oertel MF, Hobart J, Stein M, Schreiber V, Scharbrodt W. Clinical and methodological precision of spinal navigation assisted by 3D intraoperative O-arm radiographic imaging. *J Neurosurg Spine*. 2011;14(4):532–536. doi:10.3171/2010.10.SPINE091032
24. Klingler J-H, Sircar R, Scheiwe C, et al. Comparative study of C-Arms for intraoperative 3-dimensional imaging and navigation in minimally invasive spine surgery part II: radiation exposure. *Clin Spine Surg*. 2017;30(6):E669–E676. doi:10.1097/BSD.0000000000000187

**Funding:** The author(s) received no financial support for the research, authorship, and/or publication of this article.

**Declaration of Conflicting Interests:** The authors declare that the article content was composed



in the absence of any commercial or financial relationships that could be construed as a potential conflict of interest with the exception of the following: Roger Härtl reports consulting fees from DePuy Synthes, Brainlab, and Ulrich; royalties from Zimmer Biomet; and other relationship (advisor) with RealSpine.

**Corresponding Author:** Roger Härtl, Department of Neurosurgery, New York Presbyterian Hospital/

Weill Cornell Medicine, 525 E 68th St, Box 99, New York, NY 10065, USA; roh9005@med.cornell.edu

Published 04 April 2022

This manuscript is generously published free of charge by ISASS, the International Society for the Advancement of Spine Surgery. Copyright © 2022 ISASS. To see more or order reprints or permissions, see <http://ijssurgery.com>.