

Endoscopic Posterior Cervical Decompression for Ossified Posterior Longitudinal Ligament: A Technical Note

ZHANG XIFENG, MD¹; JIAJING ZHANG, MD²; YUQIU YAN, MD²; RONGQING BU, MD²; HAITAO FAN, MD²; VINCENT HAGEL, MD³; ALBERT E. TELFEIAN, MD, PhD⁴; JORGE FELIPE RAMÍREZ LEÓN, MD^{5,6,7}; MORGAN P. LORIO, MD⁸; AND KAI-UWE LEWANDROWSKI, MD^{9,10}

¹Beijing Tsinghua Changgung Hospital, Beijing, China; ²Department of Minimally Invasive Spine Surgery, Aiyuhua L Hospital, Beijing, China; ³Asklepios Hospital Lindau, Spine Center, Lindau, Germany; ⁴Department of Neurosurgery, Rhode Island Hospital, The Warren Alpert Medical School of Brown University, Providence, RI, USA; ⁵Minimally Invasive Spine Center Bogotá, DC, Colombia; ⁶Reina Sofía Clinic Bogotá, DC, Colombia; ⁷Department of Orthopaedics Fundación, Universitaria Sanitas, Bogotá, DC, Colombia; ⁸Advanced Orthopedics, Altamonte Springs, FL, USA; ⁹Center For Advanced Spine Care of Southern Arizona, Tucson, AZ, USA; ¹⁰Department of Orthopaedics, Fundación Universitaria Sanitas, Bogotá, Bogotá, DC, Colombia

ABSTRACT

Background: Ossification of the posterior longitudinal ligament (OPLL) may cause cervical myelopathy. In its multilevel form, it may not be easy to manage. Minimally invasive endoscopic posterior cervical decompression may be an alternative to traditional laminectomy surgery.

Methods: Thirteen patients with multilevel OPLL and symptomatic cervical myelopathy were treated with endoscopic spine surgery from January 2019 to June 2020. In this consecutive observational cohort study, pre- and postoperative Japanese Orthopaedic Association (JOA) score and Neck Disability Index (NDI) were analyzed at a final follow-up of 2 years postoperatively.

Results: There were 13 patients consisting of 3 women and 10 men. The patient's average age was 51.15 years. At the final 2-year follow-up, the JOA score improved from a preoperative value of 10.85 ± 2.91 to 14.77 ± 2.13 postoperatively ($P < 0.001$). The corresponding NDI scores decreased from 26.61 ± 12.88 to 11.12 ± 10.85 ($P < 0.001$). There were no infections, wound complications, or reoperations.

Conclusion: Direct posterior endoscopic decompression for multilevel OPLL is feasible in symptomatic patients when executed at a high skill level. While 2-year outcomes were encouraging and on par with historic data obtained with traditional laminectomy, future studies will need to show whether any long-term shortcomings exist.

Level of Evidence: 3.

Endoscopic Minimally Invasive Surgery

Keywords: Ossified posterior longitudinal ligament, cervical myelopathy; posterior cervical endoscopy

INTRODUCTION

Ossification of the posterior longitudinal ligament (OPLL) is a multifactorial condition that causes cervical spinal canal stenosis. Symptomatic patients display clinical signs of myelopathy with or without radiculopathy.¹ The underlying cause is an ectopic hyperostosis and calcification of the posterior longitudinal ligament. It may occur at the posterior disc space or behind the vertebral body at single or multiple cervical levels in a contiguous or interrupted form. Skip levels may also exist. Genetic factors and a familial disposition have been implied.² The condition commonly affects the cervical spine but may also occur in the thoracic spine.¹

Traditionally, posterior cervical laminectomy has been the procedure of choice, particularly in those patients who suffer from multilevel OPLL with

long-segment compression of the anterior cervical spinal cord. However, laminectomy is plagued by wound problems, infection, long-term muscle atrophy, and postoperative kyphosis.^{3–5} The latter may produce acute anterior kinking of the cervical spinal cord, resulting in a decline in neurological function. Nowadays, posterior cervical laminectomy is preferably combined with an instrumented fusion, mainly when done for cervical spondylotic myelopathy.² However, fusion has its shortcomings with a higher complication rate, including C5-nerve palsy,⁶ and the long-term implication of adjacent segment disease prompting more surgery soon after the index operation^{7,8} similar to multilevel anterior cervical discectomy and fusion.⁹ Others have stipulated that the cervical spine is inherently stable in patients with multilevel OPLL and does not require fusion.⁸ In OPLL patients, an excellent long-term prognosis

does not depend on fusion.⁸ Laminoplasty has been promoted as a less complicated solution, but patients frequently complain of axial neck pain following the operation.¹⁰ Minimally invasive decompression surgeries have been promoted to mitigate these problems.^{11–15} However, most procedures are targeted to deal with smaller focused pathologies such as a herniated disc or foraminal stenosis.

Endoscopic surgery in the cervical spine has been popularized for herniated discs and foraminal stenosis. Its modern technology platform with high-speed drills and effective rongeurs allows for complex bony and soft tissue decompression maneuvers. In this technical note, the authors illustrate their endoscopic technique to achieve multilevel minimally invasive decompression in symptomatic OPLL patients through less than a 1-cm incision.

MATERIALS AND METHODS

Patients

There were 13 OPLL patients (3 women and 10 men). The patient's average age was 51.15 years. Among them, 4 patients had single-level, 3 patients had 2-level, and the remaining 6 patients had multilevel decompressive surgery. All patients had from upper limb motor dysfunction and numbness, 2 patients displayed lower limb motor dysfunction, and another 5 patients suffered from pain. Another patient had urinary retention with dysuria.

Inclusion/Exclusion and Radiographic Criteria

The preoperative workup included routine plain film x-ray imaging, computed tomography, and magnetic resonance imaging studies of the cervical spine. The inclusion criteria were as follows:

1. Preserved motor function in the limbs, sensory dysfunction, and positive pathological upper motor neuron signs.
2. Preoperative Japanese Orthopaedic Association (JOA) score ≤ 12 points, neck and shoulder pain, and upper limb pain visual analog scale > 6 points.
3. Advanced imaging findings showing compressive pathology, including cervical degenerative disease, spinal stenosis, and spinal cord compression consistent with the correlative clinical symptoms and signs.
4. Single- or multilevel cervical spinal stenosis due to OPLL.

The exclusion criteria were as follows:

1. Severe vertebral posterior marginal osteophyte formation.
2. Congenital developmental cervical spinal stenosis.
3. Giant cervical disc herniation.
4. Apparent cervical segmental instability.
5. Significant kyphosis.

Endoscopic Surgical Technique

All the operations were performed under local anesthesia in a prone position with the patients' head fixed on the operation table with a soft face cushion. Spinal cord monitoring was not used because we considered communication with patients in the sedated yet awake state the best electrophysiological monitoring modality.

For example, for endoscopic treatment of a C5-C6 compressive pathology, the patient was placed in a prone position on the operating table and the neck was flexed in capital flexion and cervical extension to facilitate access to the posterior elements. The C-arm was positioned over the surgical level(s) in the anterior-posterior plane under fluoroscopic control. The skin entry point was marked over the surgical level, typically 1.5 cm lateral to the centerline. After standard surgical preparation and layer-by-layer infiltration with local anesthesia, the 18-G spinal needle was advanced to the trailing edge of the C5 lamina. At this point, the lateral projection was checked to ensure the spinal needle used for placing the access cannula was in a good position in both planes. The guidewire was put through the spinal needle, which was then removed. A skin incision was made around both sides of the guidewire. The subcutaneous tissues and paraspinal musculature were divided to accommodate the working cannula of the cervical endoscope—typically a round cannula with a 7-mm inner working diameter. The endoscope was then used to visualize the posterior elements directly. The trailing edge of the C5 lamina was then debrided with rongeurs and a radiofrequency probe to expose the V point formed by the convergence of the lower trailing edge of the upper and the leading edge of the lower lamina. An endoscopic high-speed power burr was used to perform a laminectomy starting medially to the lateral canal at the medial border of the facet joint using the laminar Y formed by the convergence of the rostral and caudal lamina at the facet joint complex as a starting point. These laminectomies were complete with endoscopic Kerrison rongeurs and taken across the midline to decompress the spinal canal opposite the approach side. The same surgical steps were repeated on the other surgical levels.

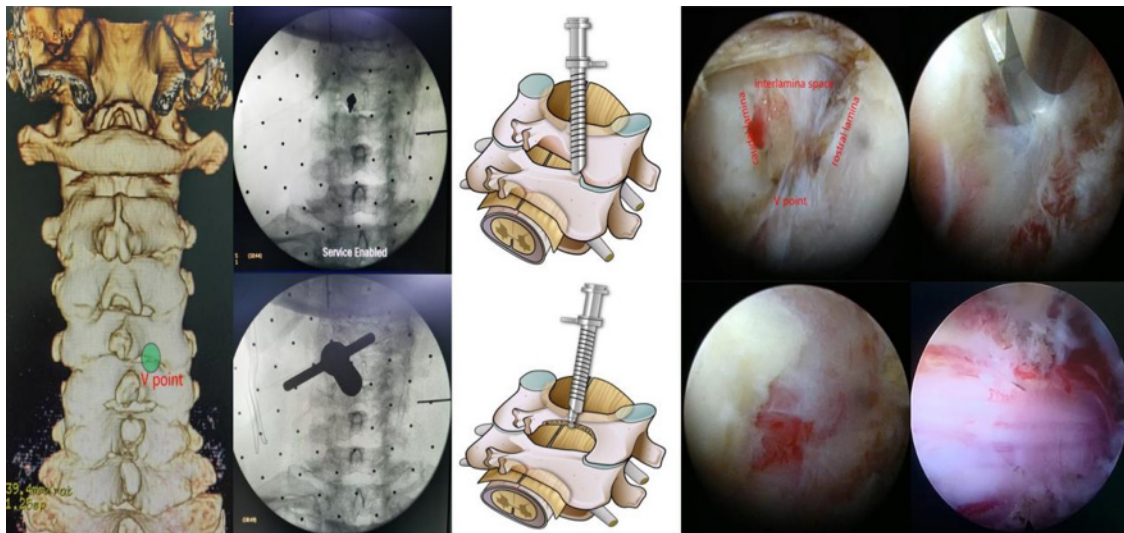


Figure 1. Key procedural steps of the endoscopic posterior decompression of OPLL are shown. The V point of the targeted segment is the landmark where the needle and working cannula can be placed safely. The bony decompression of the surgical lamina is then performed with a diamond burr, beginning medially to the most lateral border of the ligamentum flavum until it is completely exposed. Finally, the ligamentum flavum is removed with an endoscopic rongeur exposing the dura sac.

Upon completing the bony decompression, the ligamentum flavum was detached medially from the leading edge of the rostral lamina. The forceps removed any residual obstructing bone, along with the lower edge of the ligamentum flavum, to expose the spinal cord and the exiting nerve root. Upon completing the decompression, the wound was checked for hemostasis before withdrawing the endoscope and working cannula under endoscopic visualization even in muscle and subcutaneous tissue. In most of the patients, drains were not placed. Drains were placed in patients with a history of anticoagulant use and those with obvious bleeding observed during the operation. Figure 1 shows key procedural steps of the endoscopic posterior decompression of OPLL.

Postoperative Rehabilitation Program

Patients were allowed to ambulate as early as 4 hours after surgery with their cervical soft collar in place. Postoperatively, patients were admitted to the hospital for routine intravenous infusion of mannitol and dexamethasone rehydration treatment, as well as analgesic administration for pain control and to reduce the risk of postoperative spinal cord irritation from surgical manipulation and continuous intraoperative use of irrigation fluid during the endoscopy. Patients without excessive postoperative incisional pain or any other problems or obvious complications were typically discharged to their home after a 24-hour overnight observation stay. In the postoperative care, patients received

mannitol and steroid treatments according to published protocols.^{16–18}

Follow-Up and Primary Outcome Measures

For all patients, the pre- and postoperative JOA score and Neck Disability Index (NDI) were analyzed at a final follow-up of 2 years postoperatively.

Statistical Processing

The data were analyzed by SPSS version 27.0. The difference in primary outcomes measures was analyzed by paired *t* test. The data count was expressed as *n* (%), and mean and SD were used for descriptive statistics using a $P \leq 0.05$ to indicate statistical significance.

RESULTS

Paired *t* testing of the JOA scores showed a statistically significant reduction from a preoperative value of 14.77 ± 2.13 to a postoperative value of 10.85 ± 2.91 ($P < 0.001$). The corresponding Neck Disability Index scores decreased from 26.61 ± 12.88 to 11.12 ± 10.85 ($P < 0.001$). There were no infections, durotomies, wound complications, or reoperations. The mean operative time was 184.58 ± 95.19 minutes, and the median operative time was 125 minutes. The Table highlights the gender, age, and OPLL surgical levels for each of the 17 patients included in this study.

The technical caveats learned by the authors in this feasibility study are illustrated in the exemplary

Table. Gender, age, and surgical levels of ossified posterior longitudinal ligament study patients.

Case No.	Gender	Age, y	Surgical Levels
1	Male	66	C2-C4
2	Male	66	C2-C7
3	Male	54	C3-C4
4	Female	62	C3-C5
5	Male	58	C3-C6
6	Male	74	C3-C6
7	Female	76	C3-C7
8	Male	50	C3-T1
9	Male	72	C4-C5
10	Male	44	C4-C6
11	Female	74	C4-C7
12	Male	42	C5-C6
13	Male	54	C5-C6

description of the surgical management of a 62-year-old man (case 2), who had a chief complaint of repetitive neck and shoulder pain episodes for more than 2 years (Figure 2). Complaints worsened with weakness in the upper and lower extremities over the past 3 months before presenting for consultation in the first author's facility. Moreover, the patient reported difficulty holding objects and complained of unstable gait and limited walking endurance. Physical examination was consistent with cervical myelopathy. Upper motor neuron symptoms included a positive Hoffman's sign bilaterally and hyper-reflexia in both biceps, triceps, and patella tendon reflexes. The advanced imaging studies showed severe multisegment cervical spinal canal stenosis due to continuous OPLL from C2 to T1.

The endoscopic drill was used to score the lateral lamina's junction with the medial aspect of the lateral mass. Medially, the lamina was scored at the laminar junction with the spinous process. These bony cuts were then completed using endoscopic Kerrison rongeurs. The bone troughs cut are typically 2 to 3 mm in width. At this junction, the endoscopic hook is deployed through a spinal endoscope to improve the visualization of the soft tissue dissection required to free up the posterior lamina to complete the laminectomy. The authors found this technique helpful in dissecting and cutting the ligamentum flavum and fiber bundles typically attached to the dural sac. Once the dura mater is exposed on the lateral side, the whole process is completed on the medial side. After surgery completion, the fascia and skin are sutured. Postoperative x-ray images were not routinely taken on most patients. However, postoperative magnetic resonance imaging and computed tomography were done on all patients to evaluate the bony decompression and assess for the presence of morphological change of the neural tissue. Additional clinical example cases are provided in Figures 3 and 4.

DISCUSSION

OPLL is a rare condition that may cause clinical symptoms similar to cervical spondylotic myelopathy. The significant reduction of the space available for

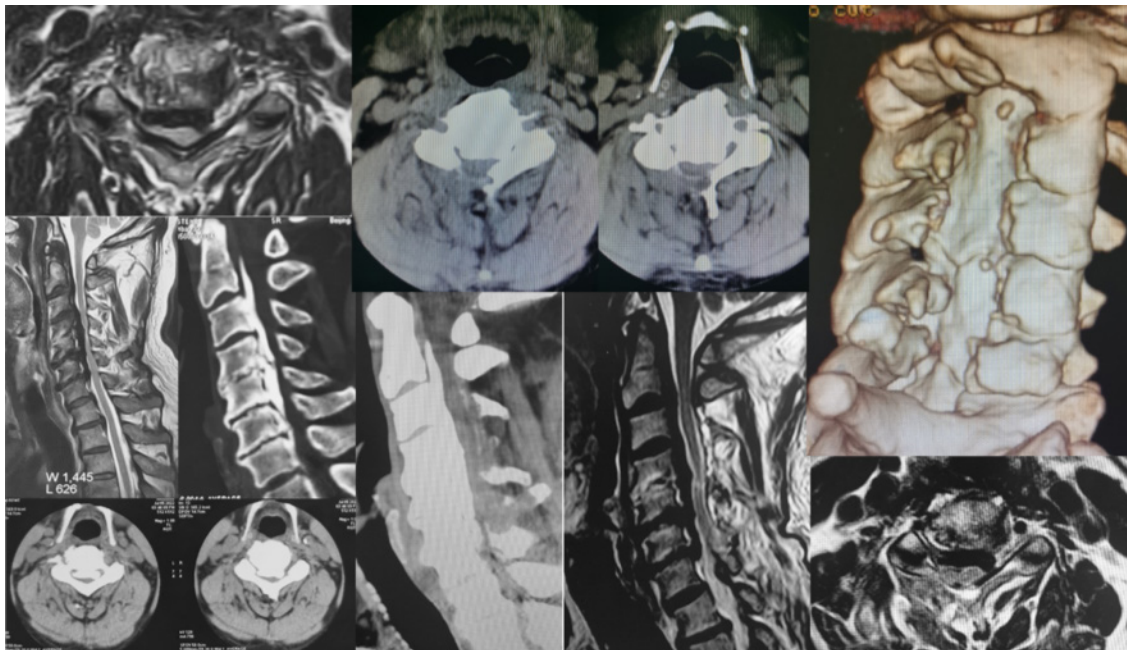


Figure 2. Axial and sagittal preoperative magnetic resonance imaging (MRI) and computed tomography (CT) image of a patient suffering from cervical spondylotic myelopathy due to ossified posterior longitudinal ligament are shown. The decompression was performed endoscopically under direct visualization employing a direct posterior approach. The postoperative image showed the cervical spine's decompression extent on axial and sagittal preoperative MRI and the 3-dimensional reconstruction CT image.

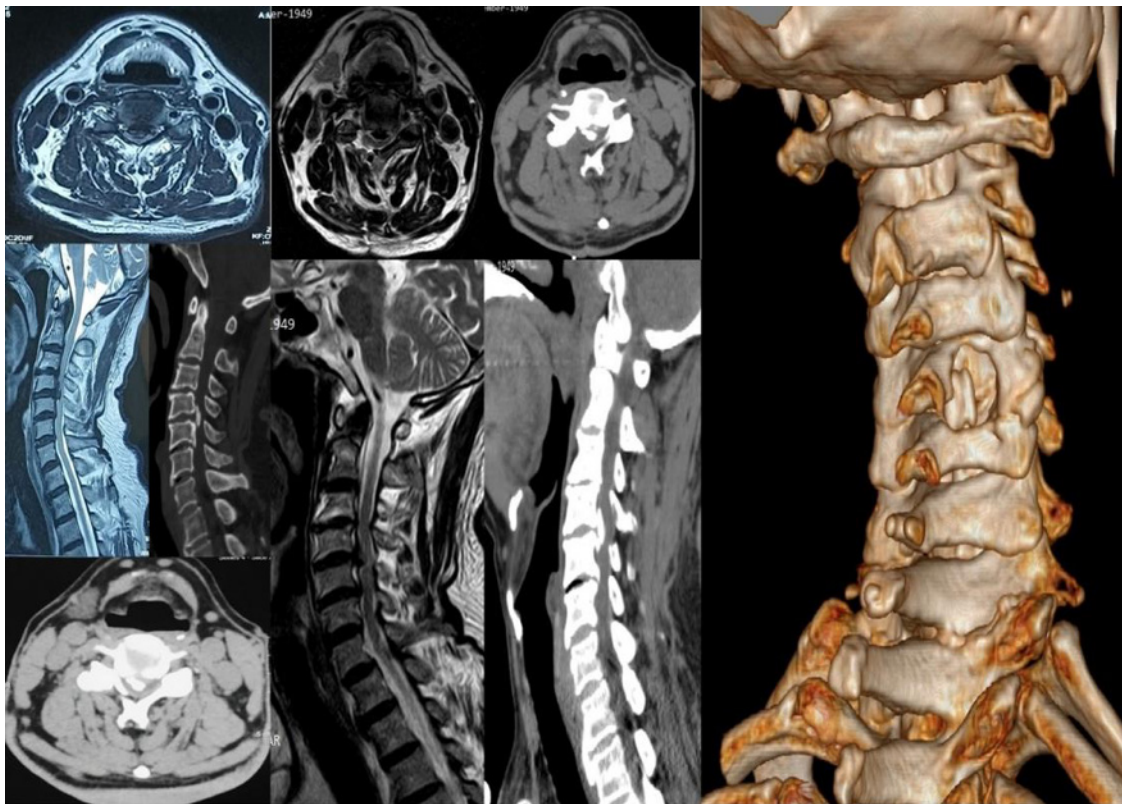


Figure 3. Preoperative magnetic resonance imaging and computed tomography (CT) image are shown of a patient with ossified posterior longitudinal ligament of C4-C5. The posterior endoscopic decompression was performed under local anesthesia. The postoperative 3-dimensional reconstruction CT image confirmed extensive canal decompression at the surgical level.

the spinal cord results in decreased neurological function.¹⁹⁻²⁷ Common symptoms include tingling or numbness in the arms, fingers, or hands, as well as weakness in the arms, shoulders, or hands. Some patients also report trouble grasping and holding on to items. Others describe impairment of their walking ability with imbalance and other coordination problems, loss of fine motor skills, and pain or stiffness in the neck.^{3,28-30} Spinal cord decompression is at the center of surgical treatment. Laminoplasty has been associated with improved

clinical outcomes.^{6,28,31-35} Its reported advantages include lower incidence of postlaminectomy kyphosis, adjacent segment disease following decompression fusion procedures with less blood loss, and diminished surgical trauma.^{3,34,36,37} The reported disadvantages include axial neck pain and closure of the laminoplasty site with recurrent cervical canal stenosis.^{10,26,38,39}

The surgical treatment of cervical myelopathy, regardless of whether it is due to OPLL or spondylotic genesis, is still based on various traditional

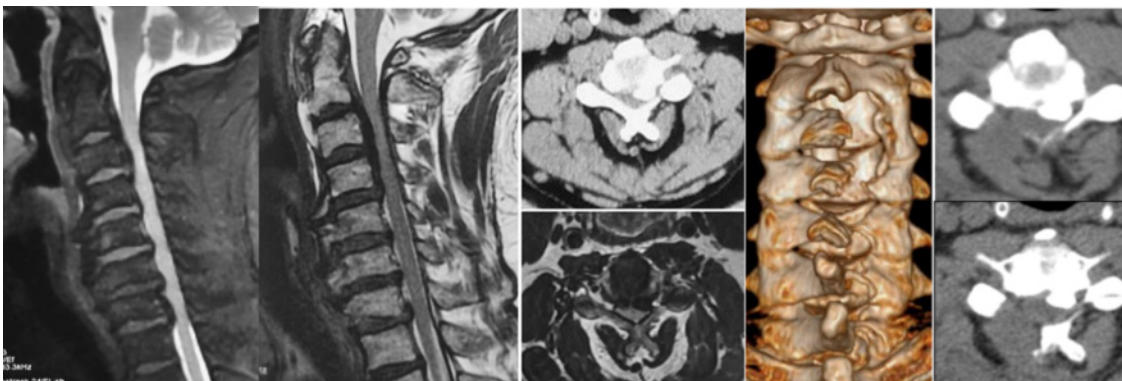


Figure 4. Preoperative magnetic resonance imaging and computed tomography (CT) image of another ossified posterior longitudinal ligament patient. Postoperative 3-dimensional reconstruction and axial CT images showed significant canal expansion after the posterior endoscopic decompression.

operations, mainly including anterior, posterior, and combined anterior and posterior surgery.^{3,4,12,24,40–44} The posterior approach is suitable for the compression of multiple cervical spinal cord segments.⁴³ In today's clinical context, extensive laminectomy seems outdated because of the postoperative scar tissue that can easily cause recurrent spinal cord compression. A single-hinge open-door cervical laminoplasty was first proposed in 1979.^{45,46} Various techniques have been popularized, including single trap door opening using anchors, to "Z"-shaped laminoplasty, open-door and double-door cervical spinal canal enlargement surgery. Although these procedures have a relatively positive long-term effect, problems such as C5 nerve root palsy, postoperative reclosure of the laminoplasty with recurrent central cervical canal stenosis, and postoperative kyphosis may occur.²⁶ Besides, it is reported in the literature that 45% to 80% of patients have postoperative axial pain, such as neck and shoulder pain, soreness, stiffness, muscle spasm, etc, and the duration of symptoms can last up to more than 10 years.^{5,23,25}

The full-endoscopic laminectomy decompression used in our feasibility study achieved sufficient decompression while preserving the spinous process, supraspinous ligament, interspinous ligament, and other anatomical structures attached to the posterior cervical muscles to the spinous process. In the authors' clinical experience, the endoscopic technique reduces tissue damage. A cervical endoscope is a valuable tool used to visualize and minimize the dissection necessary to loosen up the posterior laminoplasty bone block formed by detached laminae. Thus, the endoscopic technique presented by the authors aids in preserving the structural and functional integrity of the posterior cervical muscles, especially the splenius capitis, the semispinalis capitis muscles, and the C2 cervical spinal muscles, including the obliquus capitis inferior and the rectus capitis posterior major, which are frequently sacrificed during open surgery to gain sufficient access to the posterior cervical spine. Our patients did not see postoperative closure of the cervical spinal canal because a complete laminectomy was performed. While C5 nerve palsies did not occur, it is difficult to conclude, based on our small patient series, whether the minimal manipulation during the endoscopic decompression was responsible for that. This question should be investigated in a more extensive patient series. The authors recommend an early postoperative physical therapy and mobilization program to reduce axial neck pain and prevent

the decline of cervical motion. Bracing beyond 1 or 2 weeks postoperatively should be avoided.

CONCLUSIONS

Full-endoscopic decompression can be employed in skilled hands for minimally invasive posterior cervical laminectomy in OPLL patients. The endoscopic procedure can be used for cutting the bone groove and during the dissection of soft tissue attachments from the dural sac to facilitate the posterior expansion of the spinal canal. The decompression is achieved by contiguous drilling and piecemeal removal of small bony and soft tissue fragments. The authors' study is limited by the small patient numbers and observational nature. Clinical outcomes with this technique need to be studied in more extensive clinical trials beyond the 2-year follow-up to observe whether restenosis occurs.

REFERENCES

1. Abiola R, Rubery P, Mesfin A. Ossification of the posterior longitudinal ligament: etiology, diagnosis, and outcomes of nonoperative and operative management. *Global Spine J*. 2016;6(2):195–204. doi:10.1055/s-0035-1556580
2. Lee SE, Chung CK, Jahng T-A, Kim H-J. Long-term outcome of laminectomy for cervical ossification of the posterior longitudinal ligament. *J Neurosurg Spine*. 2013;18(5):465–471. doi:10.3171/2013.1.SPINE12779
3. Law MD, Bernhardt M, White AA. Cervical Spondylotic Myelopathy: a review of surgical indications and decision making. *Yale J Biol Med*. 1993;66(3):165–177.
4. Hohmann D, Liebig K. Surgical therapy of spondylogenic cervical myelopathy. indications and techniques. *Orthopade*. 1996;25(6):558–566. doi:10.1007/s001320050061
5. Epstein NE. Laminectomy for cervical myelopathy. *Spinal Cord*. 2003;41(6):317–327. doi:10.1038/sj.sc.3101477
6. Blizzard DJ, Caputo AM, Sheets CZ, et al. Laminoplasty versus laminectomy with fusion for the treatment of spondylotic cervical myelopathy: short-term follow-up. *Eur Spine J*. 2017;26(1):85–93. doi:10.1007/s00586-016-4746-3
7. Yokoyama K, Kawanishi M, Yamada M, Tanaka H, Ito Y, Kuroiwa T. Cervical facet dislocation adjacent to the fused motion segment. *J Neurosci Rural Pract*. 2016;7(1):133–136. doi:10.4103/0976-3147.172150
8. Chen Y, Guo Y, Chen D, Wang X, Lu X, Yuan W. Long-term outcome of laminectomy and instrumented fusion for cervical ossification of the posterior longitudinal ligament. *Int Orthop*. 2009;33(4):1075–1080. doi:10.1007/s00264-008-0609-9
9. Houten JK, Weinstein GR, Collins M. Long-term fate of C3-7 arthrodesis: 4-level ACDF versus cervical laminectomy and fusion. *J Neurosurg Sci*. 2021;65(4):402–407. doi:10.23736/S0390-5616.18.04563-0
10. Phan K, Scherman DB, Xu J, Leung V, Virk S, Mobbs RJ. Laminectomy and fusion vs Laminoplasty for multi-level cervical myelopathy: a systematic review and meta-analysis. *Eur Spine J*. 2017;26(1):94–103. doi:10.1007/s00586-016-4671-5

11. Hussain I, Schmidt FA, Kirnaz S, Wipplinger C, Schwartz TH, Härtl R. MIS approaches in the cervical spine. *J Spine Surg.* 2019;5(Suppl 1):S74–S83. doi:10.21037/jss.2019.04.21
12. Dahdaleh NS, Wong AP, Smith ZA, Wong RH, Lam SK, Fessler RG. Microendoscopic decompression for cervical spondylotic myelopathy. *Neurosurg Focus.* 2013;35(1):E8. doi:10.3171/2013.3.FOCUS135
13. Mikhael MM, Celestre PC, Wolf CF, Mroz TE, Wang JC. Minimally invasive cervical spine foraminotomy and lateral mass screw placement. *Spine (Phila Pa 1976).* 2012;37(5):E318–22. doi:10.1097/BRS.0b013e31823a43f9
14. Ruetten S, Komp M, Merk H, Godolias G. A new full-endoscopic technique for Cervical posterior foraminotomy in the treatment of lateral disc Herniations using 6.9-mm endoscopes: prospective 2-year results of 87 patients. *Minim Invasive Neurosurg.* 2007;50(4):219–226. doi:10.1055/s-2007-985860
15. Adamson TE. Microendoscopic posterior cervical laminoforaminotomy for unilateral radiculopathy: results of a new technique in 100 cases. *J Neurosurg.* 2001;95(1 Suppl):51–57. doi:10.3171/spi.2001.95.1.0051
16. Eryilmaz F, Farooque U. The efficacy of combined medication with methylprednisolone and erythropoietin in the treatment of ischemia-reperfusion injury to the spinal cord in patients with cervical spondylotic myelopathy. *Cureus.* 2021;13(3):e14018. doi:10.7759/cureus.14018
17. Harris P, Karmi MZ, McClemont E, Matlhoko D, Paul KS. The prognosis of patients sustaining severe cervical spine injury (C2-C7 inclusive). *Spinal Cord.* 1980;18(5):324–330. doi:10.1038/sc.1980.59
18. Sarant G, Chipman C. Early management of cervical spine injuries. *Postgrad Med.* 1982;71(6):164–171. doi:10.1080/00325481.1982.11716100
19. Yuan H, Zhang X, Zhang L-M, Yan Y-Q, Liu Y-K, Lewandowski K-U. Comparative study of curative effect of spinal endoscopic surgery and anterior cervical decompression for cervical spondylotic myelopathy. *J Spine Surg.* 2020;6(Suppl 1):S186–S196. doi:10.21037/jss.2019.11.15
20. Qi Q, Huang S, Ling Z, et al. A new diagnostic medium for cervical spondylotic myelopathy: dynamic somatosensory evoked potentials. *World Neurosurg.* 2020;133:e225–e232. doi:10.1016/j.wneu.2019.08.205
21. Soufi K, Nouri A, Martin AR. Degenerative Cervical Myelopathy and spinal cord injury: introduction to the special issue. *J Clin Med.* 2022;11(15):4253. doi:10.3390/jcm11154253
22. Li X, An B, Gao H, et al. Surgical results and prognostic factors following percutaneous full endoscopic posterior decompression for thoracic myelopathy caused by ossification of the ligamentum flavum. *Sci Rep.* 2020;10(1):1305. doi:10.1038/s41598-020-58198-x
23. Li Q, Han X, Wang R, Zhang Y, Liu P, Dong Q. Clinical recovery after 5 level of posterior decompression spine surgeries in patients with Cervical Spondylotic Myelopathy: A retrospective cohort study. *Asian Journal of Surgery.* 2020;43(5):613–624. doi:10.1016/j.asjsur.2019.08.003
24. El-Ghandour NMF, Soliman MAR, Ezzat AAM, Mohsen A, Zein-Elabedin M. The safety and efficacy of anterior versus posterior decompression surgery in degenerative Cervical Myelopathy: a prospective randomized trial. *J Neurosurg Spine.* 2020;1–9. doi:10.3171/2020.2.SPINE191272
25. Dobran M, Mancini F, Paracino R, et al. Laminectomy versus open-door laminoplasty for cervical spondylotic myelopathy: a clinical outcome analysis. *Surg Neurol Int.* 2020;11:73. doi:10.25259/SNI_85_2020
26. Yuan X, Wei C, Xu W, Gan X, Cao S, Luo J. Comparison of laminectomy and fusion vs laminoplasty in the treatment of multilevel cervical spondylotic myelopathy: a meta-analysis. *Medicine (Baltimore).* 2019;98(13):e14971. doi:10.1097/MD.00000000000014971
27. Lin Y, Rao S, Li Y, Zhao S, Chen B. Posterior percutaneous full-endoscopic cervical laminectomy and decompression for cervical stenosis with myelopathy: a technical note. *World Neurosurgery.* 2019;124:350–357. doi:10.1016/j.wneu.2018.12.180
28. Kato S, Oshima Y, Oka H, et al. Comparison of the Japanese Orthopaedic Association (JOA) score and modified JOA (mJOA) score for the assessment of cervical myelopathy: a multicenter observational study. *PLoS ONE.* 2015;10(4):e0123022. doi:10.1371/journal.pone.0123022
29. Jho HD. Spinal cord decompression via microsurgical anterior foraminotomy for spondylotic cervical myelopathy. *Minim Invasive Neurosurg.* 1997;40(4):124–129. doi:10.1055/s-2008-1053432
30. Hattori T, Sakakibara R, Yasuda K, Murayama N, Hirayama K. Micturitional disturbance in cervical spondylotic myelopathy. *Journal of Spinal Disorders.* 1990;3(1):16. doi:10.1097/00002517-199003000-00003
31. Deora H, Kim S-H, Behari S, et al. Anterior surgical techniques for cervical spondylotic myelopathy: WFNS spine committee recommendations. *Neurospine.* 2019;16(3):408–420. doi:10.14245/ns.1938250.125
32. An B, Li X-C, Zhou C-P, et al. Percutaneous full endoscopic posterior decompression of thoracic myelopathy caused by ossification of the ligamentum flavum. *Eur Spine J.* 2019;28(3):492–501. doi:10.1007/s00586-018-05866-2
33. Minamide A, Yoshida M, Simpson AK, et al. Microendoscopic laminotomy versus conventional laminoplasty for cervical spondylotic myelopathy: 5-year follow-up study. *J Neurosurg Spine.* 2017;27(4):403–409. doi:10.3171/2017.2.SPINE16939
34. Laiginhas ARA, Silva PA, Pereira P, Vaz R. Long-term clinical and radiological follow-up after laminectomy for cervical spondylotic myelopathy. *Surg Neurol Int.* 2015;6:162. doi:10.4103/2152-7806.167211
35. Oshima Y, Takeshita K, Inanami H, et al. Cervical microendoscopic interlaminar decompression through a midline approach in patients with cervical myelopathy: a technical note. *J Neurol Surg A Cent Eur Neurosurg.* 2014;75(6):474–478. doi:10.1055/s-0034-1373663
36. Oshima Y, Seichi A, Takeshita K, et al. Natural course and prognostic factors in patients with mild cervical spondylotic myelopathy with increased signal intensity on T2-weighted magnetic resonance imaging. *Spine (Phila Pa 1976).* 2012;37(22):1909–1913. doi:10.1097/BRS.0b013e318259a65b
37. Kato Y, Iwasaki M, Fuji T, Yonenobu K, Ochi T. Long-term follow-up results of laminectomy for cervical myelopathy caused by ossification of the posterior longitudinal ligament. *J Neurosurg.* 1998;89(2):217–223. doi:10.3171/jns.1998.89.2.0217
38. Yabuki S, Kikuchi S. Endoscopic surgery for cervical myelopathy due to calcification of the ligamentum flavum. *J Spinal Disord Tech.* 2008;21(7):518–523. doi:10.1097/BSD.0b013e31815a6151
39. Yabuki S, Kikuchi S. Endoscopic partial laminectomy for cervical myelopathy. *J Neurosurg Spine.* 2005;2(2):170–174. doi:10.3171/spi.2005.2.2.0170
40. Hitchon PW, Woodroffe RW, Noeller JA, Helland L, Hramakova N, Nourski KV. Anterior and posterior approaches

for cervical myelopathy: clinical and radiographic outcomes. *Spine (Phila Pa 1976)*. 2019;44(9):615–623. doi:10.1097/BRS.0000000000002912

41. Yadav YR, Rathe S, Parihar V, Dubey A, Dubey MN. Endoscopic partial corpectomy using anterior decompression for cervical myelopathy. *Neurol India*. 2018;66(2):444–451. doi:10.4103/0028-3886.227270

42. Yadav Y, Parihar V, Rathe S, Kher Y, Bhatele P. Endoscopic decompression of cervical spondylotic myelopathy using posterior approach. *Neurol India*. 2014;62(6):640. doi:10.4103/0028-3886.149388

43. König SA, Spetzger U. Surgical management of cervical spondylotic myelopathy - indications for anterior, posterior or combined procedures for decompression and stabilisation. *Acta Neurochir (Wien)*. 2014;156(2):253–258. doi:10.1007/s00701-013-1955-y

44. Jho HD. Decompression via microsurgical anterior foraminotomy for cervical spondylotic myelopathy. *J Neurosurg*. 1997;86(2):297–302. doi:10.3171/jns.1997.86.2.0297

45. Casella E, Chiappetta F, Dell'Aquila G, Fiume D, Massari A, Scarda G. Surgical treatment of cervical spondylogenic myelopathy (surgical indications and long-term results). *Riv Neurobiol*. 1979;25(4):435–448.

46. Hattori S, Saiki K, Kawai S. Diagnosis of the level and severity of cord lesion in cervical spondylotic myelopathy. *Spine (Phila Pa 1976)*. 1979;4(6):478–485. doi:10.1097/00007632-197911000-00005

Funding: The authors received no financial support for the research, authorship, and/or publication of this article.

Declaration of Conflicting Interests: The authors have no direct or indirect conflicts. This manuscript is not meant for or intended to endorse any products or push any other agenda other than the associated clinical outcomes with endoscopic spine surgery. The motive for compiling this clinically relevant information is by no means created and/or correlated to directly enrich anyone due to its publication. This publication was intended to substantiate cervical endoscopic spinal surgery concepts to facilitate technology advancements.

Corresponding Author: Kai-Uwe Lewandrowski, Center For Advanced Spine Care of Southern Arizona, 4787 E Camp Lowell Drive, Tucson, AZ 85712, USA; business@tucsonspine.com

Published 25 May 2023

This manuscript is generously published free of charge by ISASS, the International Society for the Advancement of Spine Surgery. Copyright © 2023 ISASS. To see more or order reprints or permissions, see <http://ijssurgery.com>.