

Revision Surgery for Proximal Junctional Kyphosis and the Role for Addressing Residual Deformity

JOHN C.F. CLOHISY, MD¹ AND HAN JO KIM, MD¹

¹Department of Orthopaedics, Hospital for Special Surgery, New York, NY, USA

ABSTRACT

Proximal junctional kyphosis (PJK) is a common complication of adult spinal deformity surgery. Initially described in Scheuermann kyphosis and adolescent scoliosis, PJK now represents a wide spectrum of diagnoses and severities. Proximal junctional failure (PJF) is the most severe form of PJK. Revision surgery for PJK may improve outcomes in the setting of intractable pain, neurological deficits, and/or progressive deformity. Accurate diagnosis of the driver(s) of PJK and a surgical strategy that addresses these factors are required to optimize outcomes for revision surgery and to avoid recurrent PJK. One such factor is residual deformity. Recent investigations on recurrent PJK have identified radiographic parameters that may be useful in revision surgery to minimize the risk of recurrent PJK. In this review, we discuss classification systems used to guide sagittal plane correction and literature investigating their utility in predicting and preventing PJK/PJF, we review the literature on revision surgery for PJK and addressing residual deformity, and we present illustrative cases.

Focus Issue Article

Keywords: proximal junctional kyphosis, proximal junctional failure, adult spinal deformity, revision surgery, postoperative complications

INTRODUCTION

Definitions, Clinical Significance, and Risk Factors

Proximal junctional kyphosis (PJK) is a common complication of adult spinal deformity (ASD) surgery with an incidence of 20% to 40% in most reports.^{1–7} PJK was first described in Scheuermann's kyphosis⁸ and adolescent idiopathic scoliosis⁹ and now represents a wide spectrum of diagnoses and severities.^{4,10,11} The most common definition for radiographic PJK is the Glattes criteria: (1) a postoperative proximal junctional angle (PJA) $\geq 10^\circ$ and (2) at least 10° greater than the preoperative measurement.¹ Proximal junctional failure (PJF) is the most severe form of PJK in which structural failure of the vertebral body or posterior ligamentous complex occurs, and revision surgery is necessary.^{10–13} PJK and PJF have been associated with increased pain and disability, and cases of severe neurological deficit in progressive PJK with vertebral subluxation have been reported.^{6,14–16}

Risk factors for PJK and PJF are well-documented in the literature and include bone quality, the integrity of the posterior tension band, construct rigidity, surgical overcorrection, and other surgical, radiographic, and patient-specific factors.¹⁷ Various strategies for preventing PJK have been described. Risk factors and prevention strategies are presented in the Table.^{17–20}

Revision surgery for PJK/PJF may be indicated in the setting of intractable pain, neurological deficits, and/or progressive deformity¹⁰ and has favorable outcomes.²¹ Studies report revision surgery rates ranging from 10% to 47% in patients with PJK.^{7,22} These procedures have high complication rates²³ and carry a significant economic burden with an estimated cost of \$55,000 and up to \$195,000 per episode.^{24,25} Thus, accurate diagnosis of the underlying driver of recurrent PJK, preoperative optimization, successful execution of a sound surgical plan, and effective perioperative management are critically important to optimize outcomes and prevent further complications. Revision surgery generally involves extending the fusion proximally to stabilize the spine in a more appropriate sagittal position and may also involve correcting the residual deformity. In this review, we discuss classification systems used to guide sagittal plane correction and literature investigating their utility in predicting and preventing PJK/PJF, we review the literature on revision surgery for PJK and addressing residual deformity, and we present illustrative cases.

ALIGNMENT TARGETS AND PJK/PJF

Optimizing health-related quality of life (HRQOL) and minimizing mechanical complications, including PJK and PJF, are critical goals of ASD surgery.

Table. Risk factors and potential prevention strategies for PJK and PJF.

Risk Factors	Prevention Techniques
Surgical	
Disruption of posterior soft tissues	Meticulous dissection at UIV and care to protect facet capsule of the level above
Rigidity of instrumentation	Use of hooks vs screws at proximal level, not engaging all screw threads proximally, use of transition rods and tethers
Choice of vertebral levels	UIV in the lower thoracic spine increases the risk of failure and vertebral fracture, UIV in the upper thoracic spine may increase the risk of junctional kyphosis, and lower instrumented vertebra to the sacrum/pelvis may increase the risk of PJK/PJF
Choice of approach	Avoid combined anterior-posterior approaches if feasible
Degree of correction: high SVA correction, increased correction of lumbar lordosis	Optimize global sagittal alignment, SVA of 0 cm may not be optimal for all patients, and PJK may be a compensatory mechanism for overcorrection; consider age-adjusted alignment targets, “ideal” Roussouly type, Global Alignment and Proportion Score
UIV loading	Under-loading of the UIV (decreased bending moment) associated with PJK/PJF
Radiographic	
Increased preoperative thoracic kyphosis	Nonmodifiable
Increased preoperative proximal junctional angle ($>5^\circ$)	Ensure the construct includes any levels with junctional kyphosis $>5^\circ$
Patient Specific	
Advanced age (>55 y)	Nonmodifiable
Body mass index	Encourage weight loss and nutrition counseling
Osteopenia/osteoporosis	Vertebral augmentation and preoperative optimization (consider interventions such as intermittent teriparatide treatment)
Lower muscularity and fatty degeneration in the thoracolumbar region	Consider UIV in the upper rather than lower thoracic in these patients
Higher preoperative thoracic spine flexibility associated with PJK	Obtain preoperative supine radiographs to identify patients at risk of thoracic spine flattening during positioning

Abbreviations: PJF, proximal junctional failure; PJK, proximal junctional kyphosis; SVA, sagittal vertical axis; UIV, upper instrumented vertebra.

Note: Modified from: Kim HJ, Iyer S. Proximal junctional kyphosis. *J Am Acad Orthop Surg.* 2016;24(5):318–326. doi:10.5435/JAAOS-D-14-00393.

Classification systems have been developed to define ideal alignment and guide sagittal plane correction.^{26–30}

The Roussouly classification defines ideal sagittal profiles in asymptomatic subjects based on sacral slope, the apex of the lumbar lordosis, and the shape of the thoracolumbar spine.^{26,30} The Scoliosis Research Society (SRS)-Schwab alignment targets of pelvic incidence (PI) minus lumbar lordosis (PI–LL) $\leq 10^\circ$, pelvic tilt $\leq 20^\circ$, and sagittal vertical axis (SVA) < 4 cm were effective in predicting disability in ASD;²⁸ however, it was unclear whether achieving the Schwab criteria influenced the risk of mechanical complications after ASD surgery. Age-adjusted alignment targets were subsequently developed based on HRQOL data from asymptomatic subjects and call for less rigorous correction with increasing age;²⁷ these targets may have the potential to reduce PJK/PJF.³¹ The Global Alignment and Proportion (GAP) score defines ideal alignment based on PI and patient age; in this system, the greater disproportion is associated with a higher risk of mechanical complications after ASD surgery.²⁹

Attempts to validate alignment targets in predicting and preventing mechanical symptoms such as PJK/PJF have shown mixed results.^{32–38} A small retrospective cohort study on 39 patients found that both the SRS-Schwab classification and the GAP score could predict mechanical complications in ASD surgery and that the GAP score was more effective in discriminating between patients who would and those who would not

experience a mechanical complication (area under curve [AUC] 0.86 vs 0.69, $P = 0.003$).³² In a retrospective study of 96 patients who had surgery for adult scoliosis, 72% of patients who did not match the ideal Roussouly profile postoperatively had mechanical complications compared with 15% of matched patients ($P < 0.001$). Furthermore, multivariate analysis found Roussouly type mismatch to be one of the most important variables associated with mechanical complications (OR 41.9, 95% CI 5.5–315.6, $P < 0.001$).³³ It is important to note that mechanical complications in these studies included PJK and PJF among other types of mechanical complications such as rod fractures and pseudarthrosis. In addition, their inclusion criteria did not include instrumentation to the ilium, which has been shown to be a risk factor for PJK and PJF. The confounding effects of these factors should be considered when interpreting the results of the studies done around the GAP score.

A retrospective study of 233 consecutively treated ASD patients reported that patients who were “not restored” to their ideal Roussouly type were nearly 5 times more likely to undergo revision surgery for mechanical failure than patients who were “restored.”³⁴ A multicenter retrospective study of 290 patients who had surgery for ASD found that the risk of developing a mechanical complication, if the Roussouly type was not restored, was 3 times higher (95% CI 1.5–4.3, $P < 0.001$) than if the Roussouly type was restored.³⁵ A recent post hoc analysis of patients from the multicenter

Adult Symptomatic Lumbar Scoliosis trial³⁹ examined PJK and pseudarthrosis rates in this cohort and compared the rates with respect to age-adjusted targets and GAP ideal measures.³⁷ In this study, the GAP score and age-adjusted alignment targets for pelvic tilt, PI–LL mismatch, and T1 pelvic angle had poor ability to predict mechanical complications (AUC 0.57, 0.52, 0.54, and 0.48, respectively).³⁷ A recent retrospective study on 409 patients from a multicenter ASD database introduced the concept of the “Sagittal age-adjusted score” (SAAS)³⁶ in which numerical values are assigned to the difference between a patient’s postoperative sagittal alignment and ideal alignment according to the previously defined age-adjusted norms for PI–LL, pelvic tilt, and T1-pelvic angle.²⁷ In this study, the SAAS increased as PJK worsened (SAAS = 0.2 for no PJK to 4.0 for PJF, $P < 0.001$) and had a significant association with HRQOL, but external validation is required. Finally, a recent systematic review of 11 retrospective studies found the GAP score to be moderately accurate in predicting mechanical complications (mean AUC 0.68); however, the included studies were of poor quality with a high risk of bias.³⁸ Collectively, these studies indicate that radiographic alignment targets alone are not sufficient in predicting mechanical complications including PJK/PJF and underscore the importance of surgical and patient factors in preventing mechanical complications.³⁷

REVISION SURGERY FOR PJK AND PJF

Surgical Revision Strategies

PJK may be managed nonoperatively with routine monitoring for symptom progression; however, revision surgery for PJK/PJF may be indicated in the setting of intractable pain, neurological deficits, and/or progressive deformity.¹⁰ Revision surgery for PJK and PJF will vary based on each patient’s unique presentation, and surgical strategies must be tailored to each individual patient to achieve optimal outcomes. Proximal fusion extension with or without decompression may be all that is required if the spine is flexible; however, osteotomies may be indicated based on a patient’s current alignment in the setting of a rigid spine proximal to a prior fusion construct or for severe kyphotic deformities.^{40,41} Those patients with prior fusions leaving the thoracic spine in relative hyperkyphosis in relation to their PI and lumbar lordosis have different PI–LL mismatch targets compared with those who have flexible kyphosis or hypokyphosis in the thoracic spine. These regional alignments should be considered in

realignment operations. Posterior column osteotomies (PCOs) may be used to restore sagittal alignment if intervertebral discs are mobile, whereas higher-grade osteotomies such as pedicle subtraction osteotomy or vertebral column resection (VCR) may be necessary in cases of severe or rigid deformity.⁴⁰ For PJK due to overcorrection or hyperlordosis, PCOs may be used and distraction performed across the osteotomy sites to reduce lordosis; however, 3-column osteotomies may be required to decrease lordosis if the segment of correction is circumferentially fused.⁴¹ Anterior column support with structural bone graft or cages may help to obtain sagittal correction and maximize fusion rates, especially when anterior column bone loss is present.⁴⁰

For level selection, Cerpa et al recommend selecting an upper instrumented vertebra (UIV) at least 2 or 3 levels proximal to the level of junctional kyphosis, avoiding a UIV close to the apex of the thoracic kyphosis, including areas of increased kyphosis in the revision fusion construct, and planning the UIV such that the new PJA is either neutral or lordotic.⁴¹

Martini et al recommend reducing biomechanical stress at the UIV by preserving proximal muscle attachments, preserving the facet joints at the upper instrumented level, and contouring rods to avoid excessive tension when they are secured proximally.⁴²

Surgical Technique

Our preferred technique for revision surgery for PJK/PJF is like that described by Kim et al.²¹ Neuromonitoring is used, and the patient is typically positioned using 10 to 15 lb traction through Gardner-Wells tongs. The fusion mass is inspected for motion, and loosened pedicle screws are replaced. Additional instrumentation is placed proximally up to the planned new UIV, and osteotomies are then performed according to the degree of correction required and the flexibility of the deformity. Fusion is achieved using local autograft, allograft, and recombinant bone morphogenetic protein-2 (rhBMP-2). Titanium interbody cages filled with local autograft and rhBMP-2 are used if anterior column support is necessary.

Potential Need to Address Residual Deformity

When planning and performing revision surgery for PJK/PJF, the decision must be made to perform an isolated extension of the prior fusion or to also address any residual sagittal malalignment.

A recent retrospective study of 151 patients who underwent revision surgery for PJK compared recurrent PJK rates between patients who had only a proximal

extension of the fusion to those who had proximal fusion extension combined with sagittal correction.⁴³ Sagittal correction was considered to have been performed if the ideal alignment was achieved in one or more sagittal alignment criteria (GAP score, Roussouly type, and SAAS). The authors found that patients proportioned according to the GAP criteria after the revision had lower rates of recurrent PJK than those who were not (23% vs 42%, OR 0.3, 95% CI 0.1–0.8, $P = 0.024$). Adjusted analysis showed that patients who were ideally aligned in 1 of the 3 alignment criteria had lower rates of recurrent PJK (36% vs 53%, OR 0.4, 95% CI 0.1–0.9, $P = 0.035$) and recurrent PJF (OR 0.1, 95% CI 0.02–0.7, $P = 0.015$). None of the patients who were ideally aligned in 2 of the 3 criteria developed PJF. The authors concluded that addressing residual deformity in addition to the proximal extension of fusion may reduce the likelihood of recurrent PJK following revision surgery; however, no minimum follow-up was reported beyond the first postoperative visit at 3.3 ± 3.1 months (median 1.8 months), and the study is limited by a small event rate of 19 PJF occurrences.

In general, the preoperative workup should identify the driver(s) of PJK, and revision surgery should address them. Realignment goals in revision surgery for PJK are like the goals for primary ASD surgery⁴¹ and should consider each patient's symptoms, bone quality, medical comorbidities, and ability to withstand and recover from surgery.

Outcomes of Revision Surgery for PJK/PJF

Evidence on outcomes of revision surgery for PJK/PJF is limited.^{10,21,44,45} In a series of 23 patients managed with revision fusion extension for PJF after ASD surgery, 12 patients developed major complications and 11 (48%) patients had recurrent PJK/PJF at the new UIV, with 9 patients undergoing additional revision procedures.¹⁰ A study of 32 patients who underwent revision surgery for PJK due to fracture and non-fracture etiologies reported a recurrent PJK rate of 19% and an overall revision surgery rate of 6%.²¹ Revision surgery in this study was associated with improvement in mean Oswestry scores ($P < 0.001$) and SRS total scores ($P < 0.001$), and postrevision outcomes were similar regardless of the etiology of the PJK.²¹ A retrospective study of 70 patients with a minimum 2-year follow-up from a prospective multicenter ASD database by Kim et al reported a recurrent PJK rate of 45.7%.⁴⁴ Patients who developed recurrent PJK had larger anterior malalignment (higher thoracic pelvic angle [TPA], higher SVA, and higher C2-T3 SVA) and larger correction

of the global sagittal alignment (TPA and SVA) performed in the revision surgery than those who did not develop recurrent PJK.⁴⁴ Prerevision TPA (OR 1.060, 95% CI 1.002–1.121, $P = 0.042$), prerevision C2-T3 SVA (OR 1.040, 95% CI 1.007–1.073, $P = 0.016$), and change in SVA at revision surgery (OR 0.981, 95% CI 0.968–0.994, $P = 0.005$) were independent predictors of recurrent PJK.⁴⁴ In a combined analysis of preoperative alignment and correction, only the change in SVA at revision surgery was a significant predictor of revision PJK.⁴⁴ It is possible that extension of fusion proximally into the cervical spine for patients with a high C2-T3 SVA may decrease the risk of recurrent PJK and the potential need for additional revision surgery; however, this has yet to be definitively shown. In a cohort of 39 patients who had surgery for PJK, Funao et al⁴⁵ reported a recurrent PJK rate of 31%; significant risk factors for recurrent PJK included initial PJA $>40^\circ$, preoperative sagittal imbalance with an SVA >10 cm, and greater correction of thoracic kyphosis ($>15^\circ$) and SVA (>5.0 cm). HRQOL measures improved significantly after revision surgery for PJK; however, postoperative SRS-22r activity scores were worse in patients who had recurrent PJK than in those who did not have recurrent PJK.⁴⁵

Case Example 1

A 59-year-old woman with a history of multiple spinal surgeries presented to our office with upper back pain and “hunched over” posture (Figure 1). She had undergone a T11-pelvis fusion for scoliosis 4 years prior complicated by infection managed with debridement and irrigation surgery. She developed symptomatic pseudarthrosis and underwent revision posterior spinal fusion with instrumentation T4-pelvis with interbody fusions performed at L4-L5 and L5-S1. She presented to our office 9 months after this revision surgery. She had incomplete relief in her symptoms with bracing and narcotic pain medications. She had a history of hypertension and was a nonsmoker. Physical examination was notable for tenderness in the upper thoracic spine and clinically evident upper thoracic kyphosis. The imaging workup demonstrated lucencies around her pelvic instrumentation and pedicle screw pullout/loosening at T4-T6 with spondylolisthesis T3 on T4. She had an L5-S1 pseudarthrosis with an otherwise solid-appearing lumbar fusion mass. Alignment parameters showed a low-grade PI, no significant PI–LL mismatch, and elevated pelvic tilt. Magnetic resonance imaging (MRI) was negative for high-grade compression. Dual-energy x-ray absorptiometry findings were consistent

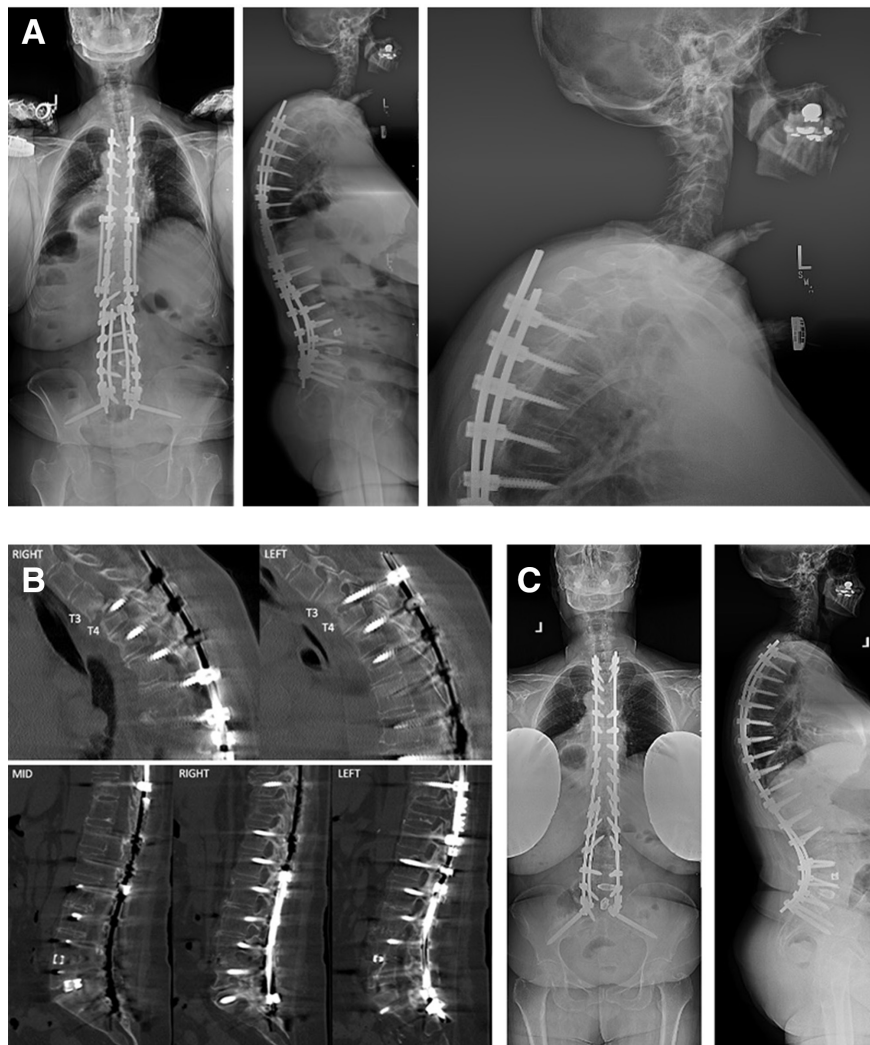


Figure 1. (A). Preoperative x-ray images showed lucencies around pelvic instrumentation and pedicle screw pullout/loosening at T4-T6 with spondylolisthesis at T3-T4. Alignment parameters showed a low-grade PI, no significant PI-LL mismatch, and elevated pelvic tilt: PI 37°, LL 28°, PI-LL 9°, PT 27°, TK 63°, and SVA 23 mm. (B) Computed tomography images showed lucencies around pedicle screws T4-T6 and pedicle screw pullout with spondylolisthesis T3-T4 and L5-S1 pseudarthrosis. (C) 6-month postoperative x-ray images after revision posterior spinal fusion with instrumentation T2-pelvis and L3 pedicle subtraction osteotomy. Alignment parameters show that the pelvic tilt has normalized. PI 37°, LL 53°, PI-LL -16°, PT 14°, TK 63°, and SVA -44 mm. PI, pelvic incidence; LL, lumbar lordosis; PI-LL, PI LL mismatch; PT, pelvic tilt; TK, thoracic kyphosis; SVA, sagittal vertical axis

with osteopenia (T-score bilateral femora -2.1). She underwent revision posterior spinal fusion with instrumentation T2-pelvis and L3 pedicle subtraction osteotomy (PSO) to address her PJF and correct her pseudarthrosis and residual deformity.

Case Example 2

A 73-year-old woman with a history of multiple spinal surgeries presented to our office with back pain and an inability to stand up straight (Figure 2). She had undergone T10-S1 fusion with lateral interbody fusions T12-L5 11 years prior to presentation. This surgery was complicated by T9 compression fracture for which she underwent in situ fixation with a proximal extension of her fusion to T6. The T6-T9 instrumentation was removed after the fracture

healed. Her surgeries had also been complicated by a left flank hernia for which she had multiple attempted repairs and a right foot drop. She also had a C4-C7 anterior cervical discectomy and fusion performed 1 year prior. She had a history of hypertension, rheumatoid arthritis, and osteoporosis. She had received teriparatide treatment for 2 years and was receiving zoledronic acid injections directed by a bone health physician. Physical examination was notable for a hunched-over posture when she attempted to stand straight. She retroverted her pelvis, extended her hips, and flexed her knees to maintain a horizontal gaze. She had 0/5 strength in the right tibialis anterior and extensor hallucis longus but otherwise had 5/5 strength throughout. Imaging demonstrated a positive sagittal imbalance secondary to an iatrogenic flatback deformity. Thoracic kyphosis measured

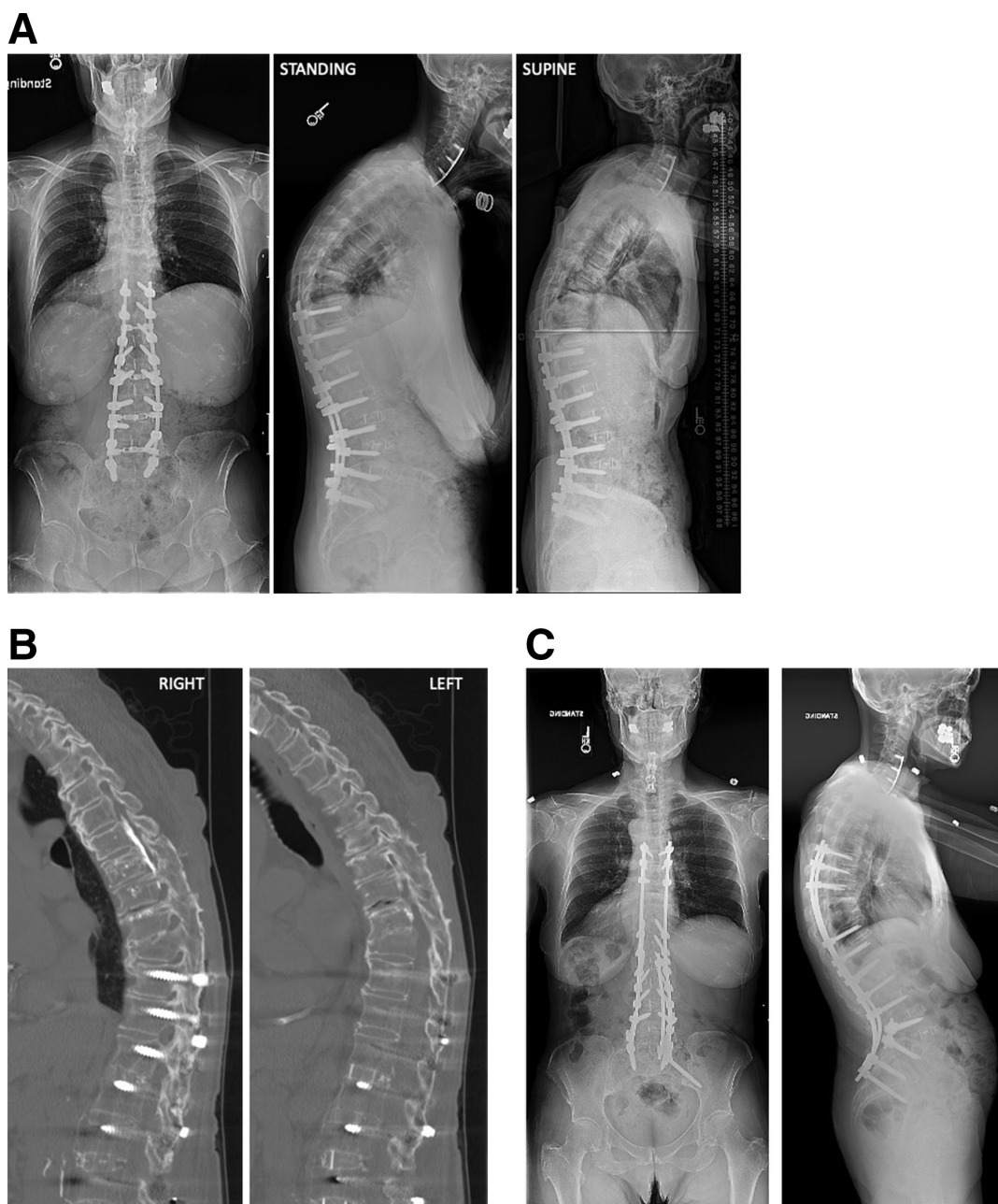


Figure 2. (A) Preoperative x-ray images show instrumentation from prior T10-S1 fusion with interbody fusion T12-L5. There is a positive sagittal imbalance secondary to flatback deformity with a healed T9 compression fracture. PI 74°, LL 57°, PI-LL 17°, PT 34°, TK 66° (50° supine), and SVA 83 mm. (B) Computed tomography (CT) image showed an intact fusion mass T6-S1 and hyperostosis T3-T5 resulting in a spine that is functionally fused T3-S1 except for vacuum phenomena at T6-T7 and T7-T8 indicating motion at these levels (with a decrease in kyphosis on supine radiographs). Also noted are screw tracts from prior T6-T9 fixation and cement augmentation in the midthoracic spine. Full lumbar CT image not shown. (C) Postoperative day 5 x-ray images after revision posterior spinal fusion with instrumentation T5-pelvis and L4 pedicle subtraction osteotomy. PI 74°, LL 86°, PI-LL -12°, PT 18°, and SVA -37 mm. PI, pelvic incidence; LL, lumbar lordosis; PT, pelvic tilt; TK, thoracic kyphosis; SVA, sagittal vertical axis.

66° and corrected to 50° supine, and there was a healed compression fracture at T9. There was also hyperostosis with bridging osteophytes T3-T5 and prior cement augmentation in the midthoracic spine. Computed tomography myelogram was negative for high-grade compression. A dual-energy x-ray absorptiometry image was consistent with osteoporosis (T-score left radius -2.7). She underwent revision posterior spinal fusion with instrumentation

T5-pelvis and L4 PSO to address the PJK and residual flatback deformity.

Case Example 3

A 68-year-old man presented to our office with complaints of severe midthoracic back pain and inability to stand upright (Figure 3). He had a history of adult scoliosis and

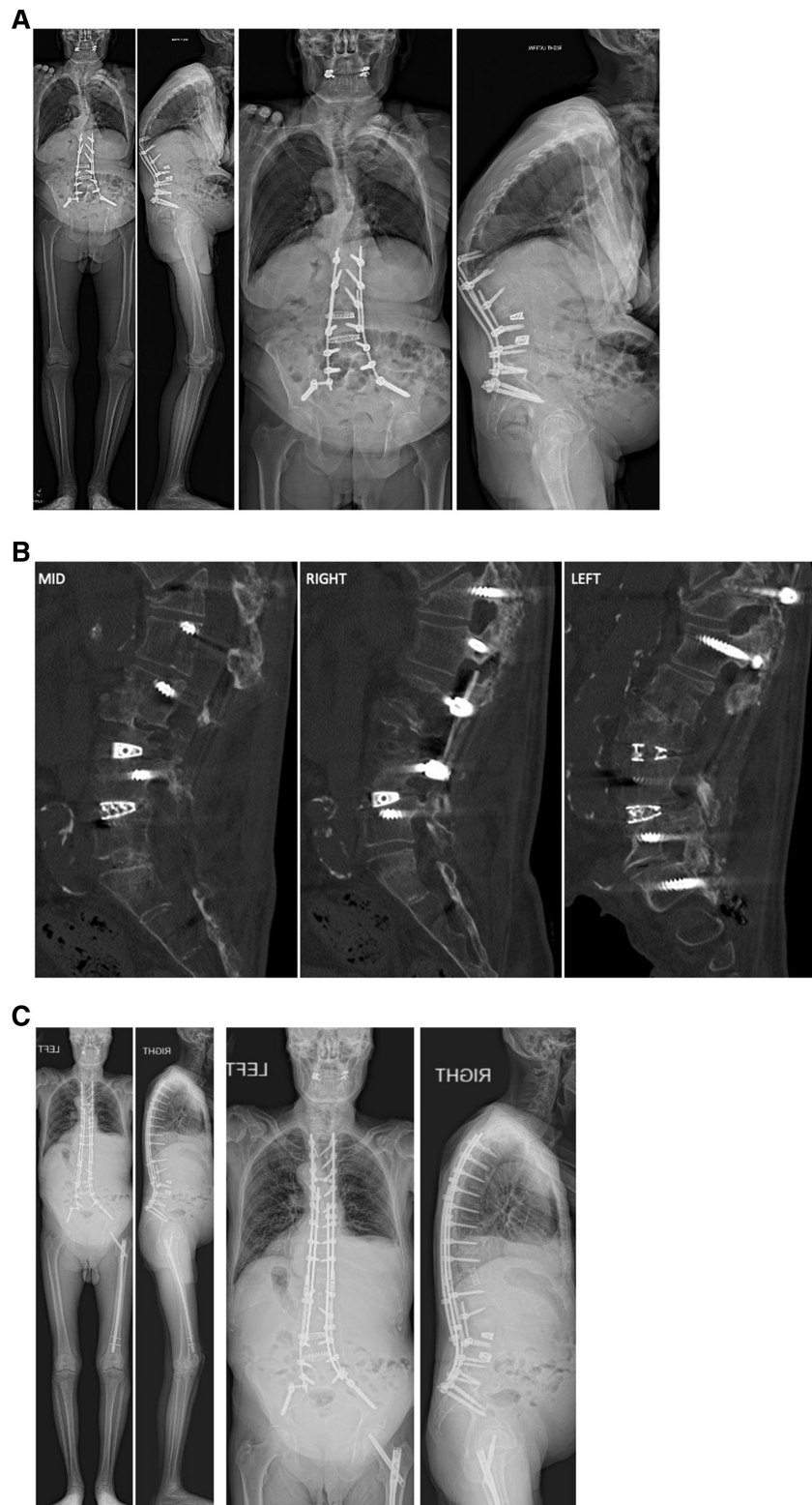

Figure 3. (A) Preoperative x-ray images show prior T12-S1/pelvis fusion with proximal junctional failure (PJF). There is a positive sagittal imbalance secondary to PJF. PI 35°, LL 27°, PI-LL 8°, PT 30°, SVA 182 mm, and PJA 50°. (B) Lumbar computed tomography image showed a T12 compression fracture, an L5-S1 pseudarthrosis, and an otherwise solid fusion mass T12-L5. (C) 2.5-year postoperative x-ray images after revision posterior spinal fusion with instrumentation T4-S1/pelvis and T12 VCR. Alignment parameters show that the pelvic tilt has normalized, and global sagittal alignment has improved without evidence of recurrent proximal junctional kyphosis. PI 35°, LL 27°, PI-LL 8°, PT 12°, and SVA 107 mm. PI, pelvic incidence; LL, lumbar lordosis; PT, pelvic tilt; TK, thoracic kyphosis; SVA, sagittal vertical axis; PJA, proximal junctional angle.

had undergone lateral lumbar interbody fusions at L2-L3 and L3-L4, posterior spinal fusion with instrumentation T12-S1/pelvis, L3 PSO, and L5-S1 posterior lumbar interbody fusion 1 year prior to presentation. The back pain and postural issues began within a few months of his spinal surgery. He used a cane for ambulation and had failed non-operative treatment. His medical history was notable for alcoholic cirrhosis and hypertension. On examination, he had 4/5 strength in bilateral hip flexors and was otherwise neurologically intact. He was unable to stand up straight, and there was prominent instrumentation at the midthoracic spine. He had a right flank hernia from his prior lateral lumbar surgery. Imaging demonstrated instrumentation from his previous surgery with a T12 compression fracture and PJF. Radiographic parameters included a PJA of 50°, PI 35°, LL 27°, PI-LL mismatch 8°, positive sagittal imbalance secondary to PJF, and compensatory pelvic retroversion with an elevated pelvic tilt of 30°. CT showed an L5-S1 pseudarthrosis and an otherwise solid fusion mass at T12-L5. MRI was negative for high-grade stenosis throughout the entire spine. He underwent revision posterior spinal fusion with instrumentation T4-S1/pelvis with a T12 VCR and ligamentous augmentation T3-T4 using a crosslink and Mersilene tape. He sustained a right proximal femur fracture 2 years after his spine surgery in a mechanical fall and underwent cephalomedullary nailing. Otherwise, the back pain and postural issues that he had preoperatively have resolved as of most recent 2.5-year follow-up.

SUMMARY

PJK is a common complication of ASD surgery that may lead to poor outcomes. The etiology of PJK is multifactorial, and a combination of surgical, radiographic, and patient-specific risk factors contribute. PJK prevention strategies and sagittal alignment targets may be useful in reducing PJK rates; however, strong evidence supporting their efficacy in preventing PJK is lacking. In the setting of severe pain, neurological deficits, and/or progressive deformity, revision surgery may improve outcomes. Revision surgery strategies for PJK will vary based on a patient's unique presentation, and residual deformity should be corrected if present. It is of paramount importance that the drivers of PJK are recognized and addressed to optimize outcomes and avoid recurrent PJK.

REFERENCES

1. Glattes RC, Bridwell KH, Lenke LG, Kim YJ, Rinella A, Edwards C. Proximal junctional kyphosis in adult spinal deformity following long instrumented posterior spinal fusion: incidence, outcomes, and risk factor analysis. *Spine (Phila Pa 1976)*. 2005;30(14):1643–1649. doi:10.1097/01.brs.0000169451.76359.49
2. Kim HJ, Lenke LG, Shaffrey CI, Van Alstyne EM, Skelly AC. Proximal junctional kyphosis as a distinct form of adjacent segment pathology after spinal deformity surgery: a systematic review. *Spine (Phila Pa 1976)*. 2012;37(22 Suppl):S144–S164. doi:10.1097/BRS.0b013e31826d611b
3. Lee J-H, Kim J-U, Jang J-S, Lee S-H. Analysis of the incidence and risk factors for the progression of proximal junctional kyphosis following surgical treatment for lumbar degenerative kyphosis: minimum 2-year follow-up. *Br J Neurosurg*. 2014;28(2):252–258. doi:10.3109/02688697.2013.835369
4. Yagi M, King AB, Boachie-Adjei O. Incidence, risk factors, and natural course of proximal junctional kyphosis: surgical outcomes review of adult idiopathic scoliosis. minimum 5 years of follow-up. *Spine (Phila Pa 1976)*. 2012;37(17):1479–1489. doi:10.1097/BRS.0b013e31824e4888
5. Denis F, Sun EC, Winter RB. Incidence and risk factors for proximal and distal junctional kyphosis following surgical treatment for Scheuermann kyphosis: minimum five-year follow-up. *Spine (Phila Pa 1976)*. 2009;34(20):E729–E734. doi:10.1097/BRS.0b013e3181ae2ab2
6. Kim HJ, Bridwell KH, Lenke LG, et al. Proximal junctional kyphosis results in inferior SRS pain subscores in adult deformity patients. *Spine (Phila Pa 1976)*. 2013;38(11):896–901. doi:10.1097/BRS.0b013e3182815b42
7. Kim YJ, Bridwell KH, Lenke LG, Glattes CR, Rhim S, Cheh G. Proximal junctional kyphosis in adult spinal deformity after segmental posterior spinal instrumentation and fusion: minimum five-year follow-up. *Spine (Phila Pa 1976)*. 2008;33(20):2179–2184. doi:10.1097/BRS.0b013e31817c0428
8. Lowe TG, Kasten MD. An analysis of sagittal curves and balance after Cotrel-Dubousset instrumentation for kyphosis secondary to Scheuermann's disease. A review of 32 patients. *Spine (Phila Pa 1976)*. 1994;19(15):1680–1685. doi:10.1097/00007632-199408000-00005
9. Lee GA, Betz RR, Clements DH, Huss GK. Proximal kyphosis after posterior spinal fusion in patients with idiopathic scoliosis. *Spine (Phila Pa 1976)*. 1999;24(8):795–799. doi:10.1097/00007632-199904150-00011
10. Yagi M, Rahm M, Gaines R, et al. Characterization and surgical outcomes of proximal junctional failure in surgically treated patients with adult spinal deformity. *Spine (Phila Pa 1976)*. 2014;39(10):E607–E614. doi:10.1097/BRS.0000000000000266
11. Lau D, Clark AJ, Scheer JK, et al. Proximal junctional kyphosis and failure after spinal deformity surgery: a systematic review of the literature as a background to classification development. *Spine (Phila Pa 1976)*. 2014;39(25):2093–2102. doi:10.1097/BRS.0000000000000627
12. Hostin R, McCarthy I, O'Brien M, et al. Incidence, mode, and location of acute proximal junctional failures after surgical treatment of adult spinal deformity. *Spine*. 2013;38(12):1008–1015. doi:10.1097/BRS.0b013e318271319c
13. Hart R, McCarthy I, O'Brien M, et al. Identification of decision criteria for revision surgery among patients with proximal junctional failure after surgical treatment of spinal deformity. *Spine*. 2013;38(19):E1223–E1227. doi:10.1097/BRS.0b013e31829fedde
14. Kim HJ, Bridwell KH, Lenke LG, et al. Patients with proximal junctional kyphosis requiring revision surgery have higher postoperative lumbar lordosis and larger sagittal balance

corrections. *Spine*. 2014;39(9):E576–E580. doi:10.1097/BRS.0000000000000246

15. Hassanzadeh H, Gupta S, Jain A, El Dafrawy MH, Skolasky RL, Kebaish KM. Type of anchor at the proximal fusion level has a significant effect on the incidence of proximal junctional kyphosis and outcome in adults after long posterior spinal fusion. *Spine Deform*. 2013;1(4):299–305. doi:10.1016/j.jspd.2013.05.008

16. Watanabe K, Lenke LG, Bridwell KH, Kim YJ, Koester L, Hensley M. Proximal junctional vertebral fracture in adults after spinal deformity surgery using pedicle screw constructs: analysis of morphological features. *Spine (Phila Pa 1976)*. 2010;35(2):138–145. doi:10.1097/BRS.0b013e3181c8f35d

17. Kim HJ, Iyer S. Proximal junctional kyphosis. *J Am Acad Orthop Surg*. 2016;24(5):318–326. doi:10.5435/JAAOS-D-14-00393

18. Katsuura Y, Lafage R, Kim HJ, et al. Alignment targets, curve proportion and mechanical loading: preliminary analysis of an ideal shape toward reducing proximal junctional kyphosis. *Global Spine J*. 2022;12(6):1165–1174. doi:10.1177/2192568220987188

19. Hyun SJ, Kim YJ, Rhim SC. Patients with proximal junctional kyphosis after stopping at thoracolumbar junction have lower muscularity, fatty degeneration at the thoracolumbar area. *Spine J*. 2016;16(9):1095–1101. doi:10.1016/j.spinee.2016.05.008

20. Lovecchio F, Lafage R, Elysee JC, et al. The utility of supine radiographs in the assessment of thoracic flexibility and risk of proximal junctional kyphosis. *J Neurosurg Spine*. 2021;35(1):1–7. doi:10.3171/2020.11.SPINE201565

21. Kim Y-C, Lenke LG, Bridwell KH, et al. Results of revision surgery for proximal junctional kyphosis following posterior segmental instrumentation: minimum 2-year postrevision follow-up. *Spine (Phila Pa 1976)*. 2016;41(24):E1444–E1452. doi:10.1097/BRS.0000000000001664

22. Hart R, McCarthy I, O'Brien M, et al. Identification of decision criteria for revision surgery among patients with proximal junctional failure after surgical treatment of spinal deformity. *Spine (Phila Pa 1976)*. 2013;38(19):E1223–7. doi:10.1097/BRS.0b013e31829fedde

23. Smith JS, Klineberg E, Lafage V, et al. Prospective multicenter assessment of perioperative and minimum 2-year postoperative complication rates associated with adult spinal deformity surgery. *J Neurosurg Spine*. 2016;25(1):1–14. doi:10.3171/2015.11.SPINE151036

24. Safae MM, Dalle Ore CL, Zygorakis CC, Deviren V, Ames CP. The unreimbursed costs of preventing revision surgery in adult spinal deformity: analysis of cost-effectiveness of proximal junctional failure prevention with ligament augmentation. *Neurosurg Focus*. 2018;44(5):E13. doi:10.3171/2018.1.FOCUS17806

25. Theologis AA, Miller L, Callahan M, et al. Economic impact of revision surgery for proximal junctional failure after adult spinal deformity surgery: a cost analysis of 57 operations in a 10-year experience at a major deformity center. *Spine (Phila Pa 1976)*. 2016;41(16):E964–E972. doi:10.1097/BRS.0000000000001523

26. Roussouly P, Gollogly S, Berthonnaud E, Dimnet J. Classification of the normal variation in the sagittal alignment of the human lumbar spine and pelvis in the standing position. *Spine (Phila Pa 1976)*. 2005;30(3):346–353. doi:10.1097/01.brs.0000152379.54463.65

27. Lafage R, Schwab F, Challier V, et al. Defining spinopelvic alignment thresholds: should operative goals in adult spinal deformity surgery account for age? *Spine (Phila Pa 1976)*. 2016;41(1):62–68. doi:10.1097/BRS.0000000000001171

28. Schwab FJ, Blondel B, Bess S, et al. Radiographical spinopelvic parameters and disability in the setting of adult spinal deformity: a prospective multicenter analysis. *Spine (Phila Pa 1976)*. 2013;38(13):E803–E812. doi:10.1097/BRS.0b013e318292b7b9

29. Yilgor C, Sogunmez N, Boissiere L, et al. Global alignment and proportion (GAP) score: development and validation of a new method of analyzing spinopelvic alignment to predict mechanical complications after adult spinal deformity surgery. *J Bone Joint Surg Am*. 2017;99(19):1661–1672. doi:10.2106/JBJS.16.01594

30. Laouissat F, Sebaaly A, Gehrchen M, Roussouly P. Classification of normal sagittal spine alignment: refounding the roussouly classification. *Eur Spine J*. 2018;27(8):2002–2011. doi:10.1007/s00586-017-5111-x

31. Lafage R, Schwab F, Glassman S, et al. Age-adjusted alignment goals have the potential to reduce PJK. *Spine (Phila Pa 1976)*. 2017;42(17):1275–1282. doi:10.1097/BRS.0000000000002146

32. Jacobs E, van Royen BJ, van Kuijk SMJ, et al. Prediction of mechanical complications in adult spinal deformity surgery—the GAP score versus the Schwab classification. *Spine J*. 2019;19(5):781–788. doi:10.1016/j.spinee.2018.11.013

33. Pizones J, Moreno-Manzanaro L, Sánchez Pérez-Gruoso FJ, et al. Restoring the ideal roussouly sagittal profile in adult scoliosis surgery decreases the risk of mechanical complications. *Eur Spine J*. 2020;29(1):54–62. doi:10.1007/s00586-019-06176-x

34. Bari TJ, Hansen LV, Gehrchen M. Surgical correction of adult spinal deformity in accordance to the Roussouly classification: effect on postoperative mechanical complications. *Spine Deform*. 2020;8(5):1027–1037. doi:10.1007/s43390-020-00112-6

35. Sebaaly A, Gehrchen M, Silvestre C, et al. Mechanical complications in adult spinal deformity and the effect of restoring the spinal shapes according to the roussouly classification: a multicentric study. *Eur Spine J*. 2020;29(4):904–913. doi:10.1007/s00586-019-06253-1

36. Lafage R, Smith JS, Elysee J, et al. Sagittal age-adjusted score (SAAS) for adult spinal deformity (ASD) more effectively predicts surgical outcomes and proximal junctional kyphosis than previous classifications. *Spine Deform*. 2022;10(1):121–131. doi:10.1007/s43390-021-00397-1

37. Dial BL, Hills JM, Smith JS, et al. The impact of lumbar alignment targets on mechanical complications after adult lumbar scoliosis surgery. *Eur Spine J*. 2022;31(6):1573–1582. doi:10.1007/s00586-022-07200-3

38. Quarto E, Zanirato A, Pellegrini M, et al. GAP score potential in predicting post-operative spinal mechanical complications: a systematic review of the literature. *Eur Spine J*. 2022;31(12):3286–3295. doi:10.1007/s00586-022-07386-6

39. Kelly MP, Lurie JD, Yanik EL, et al. Operative versus non-operative treatment for adult symptomatic lumbar scoliosis. *J Bone Joint Surg Am*. 2019;101(4):338–352. doi:10.2106/JBJS.18.00483

40. Nguyen NLM, Kong CY, Hart RA. Proximal junctional kyphosis and failure—diagnosis, prevention, and treatment. *Curr Rev Musculoskelet Med*. 2016;9(3):299–308. doi:10.1007/s12178-016-9353-8

41. Cerpa M, Sardar Z, Lenke L. Revision surgery in proximal junctional kyphosis. *Eur Spine J*. 2020;29(Suppl 1):78–85. doi:10.1007/s00586-020-06320-y

42. Martini C, Langella F, Mazzucchelli L, Lamartina C. Revision strategies for failed adult spinal deformity surgery. *Eur Spine J*. 2020;29(Suppl 1):116–125. doi:10.1007/s00586-019-06283-9

43. Passias PG, Krol O, Williamson TK, et al. The benefit of addressing malalignment in revision surgery for proximal junctional

kyphosis following ASD surgery. *Spine (Phila Pa 1976)*. 2022. doi:10.1097/BRS.0000000000004476

44. Kim HJ, Wang S-J, Lafage R, et al. Recurrent proximal junctional kyphosis: incidence, risk factors, revision rates, and outcomes at 2-year minimum follow-up. *Spine (Phila Pa 1976)*. 2020;45(1):E18–E24. doi:10.1097/BRS.0000000000003202

45. Funao H, Kebaish FN, Skolasky RL, Kebaish KM. Recurrence of proximal junctional kyphosis after revision surgery for symptomatic proximal junctional kyphosis in patients with adult spinal deformity: incidence, risk factors, and outcomes. *Eur Spine J*. 2021;30(5):1199–1207. doi:10.1007/s00586-020-06669-0

Funding: The authors received no financial support for the research, authorship, and/or publication of this article.

Declaration of Conflicting Interests:

Dr Kim reports grants/contracts from ISSGF (paid to institution); royalties/licenses from Zimmer Biomet, K2M/Stryker, and Acuity Surgical; consulting fees from Nuvasive; participation on a data safety monitoring board or advisory board for Vivex Biology and Aspen Medical; and other financial interests from AO Spine. Dr. Clohisy does not have any relevant financial or non-financial interests to disclose.

Disclosures: Dr Kim reports grants/contracts from ISSGF (paid to institution); royalties/licenses from Zimmer Biomet, K2M/Stryker, and Acuity Surgical; consulting fees from Nuvasive; participation on a data safety monitoring board or advisory board for Vivex Biology and Aspen Medical; and other financial interests from AO Spine. Dr. Clohisy does not have any relevant financial or nonfinancial interests to disclose.

Ethics approval: All procedures performed in studies involving human participants were in accordance with the ethical standards of the institutional and/or national research committee and with the 1964 Helsinki declaration and its later amendments or comparable ethical standards.

Corresponding Author: Han Jo Kim; hanjok-immmd@gmail.com

Published 22 June 2023

This manuscript is generously published free of charge by ISASS, the International Society for the Advancement of Spine Surgery. Copyright © 2023 ISASS. To see more or order reprints or permissions, see <http://ijssurgery.com>.