

A Review of Symptomatic Lumbosacral Transitional Vertebrae: Bertolotti's Syndrome

Kadir Abul

Int J Spine Surg 2024, 18 (1) 81-82

doi: <https://doi.org/10.14444/8571>

<http://ijssurgery.com/content/18/1/81>

This information is current as of April 28, 2024.

Email Alerts Receive free email-alerts when new articles cite this article. Sign up at:
<http://ijssurgery.com/alerts>

A Review of Symptomatic Lumbosacral Transitional Vertebrae: Bertolotti's Syndrome

KADIR ABUL, MD¹

¹Department of Orthopedics and Traumatology, Basaksehir Pine and Sakura City Hospital, Istanbul, Turkey

Keywords: transitional vertebrae

Dear Editor,

I read with interest the article by Jancuska, Spivak, and Bendo in which they give a comprehensive and excellent review of the transitional anomalies of the human spine.¹ In Figure 4 of their article, they give an example of “a case of L6 vertebra with type IIa transition” and state that the images show 25 presacral mobile vertebrae (Figure 1). A closer inspection reveals that

counting the vertebral levels caudally from C2 reveals that this case has 24 presacral vertebrae and probably 5 lumbar vertebrae (Figure 2). I believe that the authors probably included this image by mistake.

The case example shown here could belong to a normal spinal skeleton with 7 cervical, 12 thoracic, and 5 lumbar vertebrae if only the sagittal magnetic resonance imaging slices are considered. Coronal radiographs of the entire spine or computed tomography images are needed to determine the actual number of lumbar vertebrae or to determine whether this is a case with transitional abnormalities. Being aware of the great importance of this article in the literature, I suggest that the authors correct this information, which I believe resulted from an error.

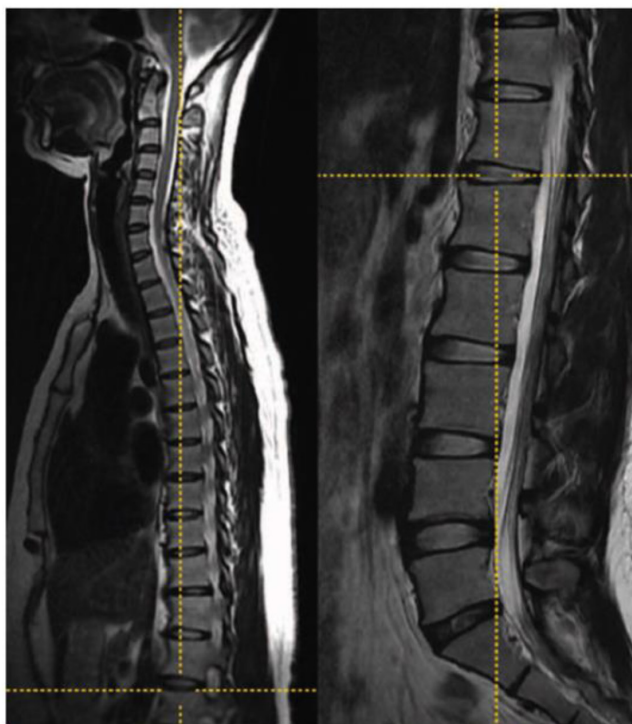


Fig. 4. A case of L6 vertebra with type IIa transition. Left, T2-weighted sagittal cervicothoracic and (right) lumbar images in the cross-referencing mode of the picture archiving and communication system. This simultaneously demonstrates the marker at the T12–L1 disc space. Counting the vertebral levels caudally from C2 reveals this patient to have 25 presacral vertebrae or 6 lumbar vertebrae.⁵

Figure 1. The image is from Figure 4 of the original article by Jancuska et al.¹ The authors give an example of a case with 25 presacral vertebrae from Paik et al's article,² which shows a case with 6 lumbar vertebrae after cross-referencing showing the T12–L1 level. It can be clearly seen that the case has 5 presacral lumbar vertebrae and a total of 24 presacral vertebrae.

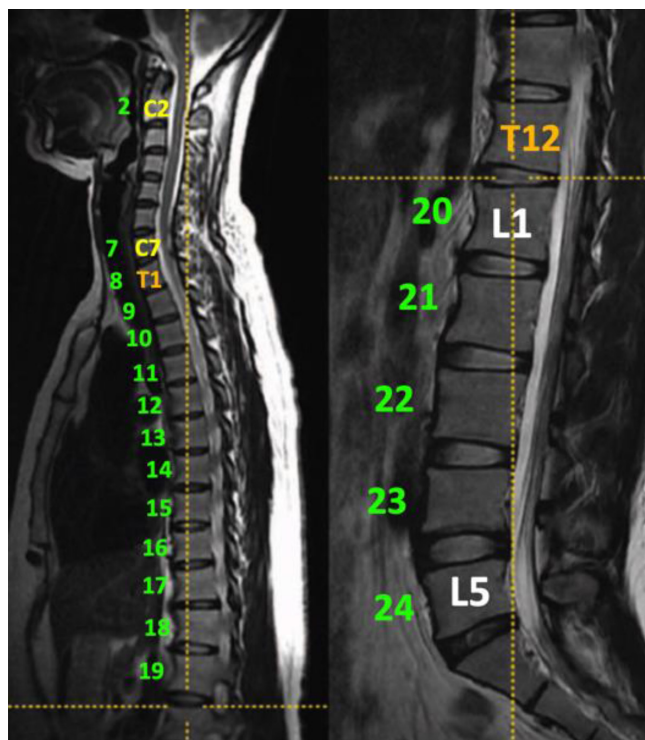


Figure 2. Counting the vertebral levels caudally from C2 reveals this patient to have 24 presacral vertebrae and probably 5 lumbar vertebrae.

REFERENCES

1. Jancuska JM, Spivak JM, Bendo JA. A review of symptomatic lumbosacral transitional vertebrae: bertolotti's syndrome. *Int J Spine Surg.* 2015;9:42. doi:10.14444/2042
2. Paik NC, Lim CS, Jang HS. Numeric and morphological verification of lumbosacral segments in 8280 consecutive patients. *Spine.* 2013;38(10):E573–E578. doi:10.1097/BRS.0b013e31828b7195

Funding: The author received no financial support for the authorship or publication of this letter.

Declaration of Conflicting Interests: The author reports no conflicts of interest in this work.

Corresponding Author: Kadir Abul, Department of Orthopedics and Traumatology, Başakşehir Çam and Sakura City Hospital, Istanbul 34077, Turkey; doktorkadir@gmail.com

Published 25 January 2024

This manuscript is generously published free of charge by ISASS, the International Society for the Advancement of Spine Surgery. Copyright © 2024 ISASS. To see more or order reprints or permissions, see <http://ijssurgery.com>.