

Qualitative Evaluation of Paraspinal Musculature After Minimally Invasive Lumbar Decompression: A Prospective Study

Ramon Oliveira Soares, Nelson Astur, Lucas Rabello de Oliveira, Michel Kanas, Marcelo Wajchenberg and Delio Eulálio Martins

Int J Spine Surg 2024, 18 (4) 448-454

doi: <https://doi.org/10.14444/8631>

<https://www.ijssurgery.com/content/18/4/448>

This information is current as of May 2, 2025.

Email Alerts Receive free email-alerts when new articles cite this article. Sign up at:
<http://ijssurgery.com/alerts>

Qualitative Evaluation of Paraspinal Musculature After Minimally Invasive Lumbar Decompression: A Prospective Study

RAMON OLIVEIRA SOARES, MD¹; NELSON ASTUR, MD, PhD^{1,2}; LUCAS RABELLO DE OLIVEIRA, MD¹; MICHEL KANAS, MD^{1,2}; MARCELO WAJCHENBERG, MD, PhD^{1,2}; AND DELIO EULÁLIO MARTINS, MD, PhD^{1,2}

¹Orthopaedic and Trauma Department, Hospital Israelita Albert Einstein, São Paulo, SP, Brazil; ²Spine Surgery Department, Instituto Cohen Ortopedia, São Paulo, SP, Brazil

 ROS, 0000-0002-3861-4150;  NA, 0000-0002-2608-2118;  LRdO, 0000-0002-0815-7999;  MK, 0000-0002-2179-3666;  MW, 0000-0003-1961-6537;  DEM, 0000-0001-5510-3507

ABSTRACT

Background: To quantify fatty infiltration and degree of paraspinal muscle degeneration in patients submitted to tubular microdiscectomy and conventional open microdiscectomy.

Methods: A prospective cohort of patients was submitted to microdiscectomy for lumbar disc herniation after failure of conservative treatment. Selection of the technique was based on the surgeon's preference. Analysis of the multifidus muscle was performed using the Goutallier system and the percentage of fat in the muscle. Preoperative and 1-year postoperative T2-weighted magnetic resonance imaging was used, and statistical analysis was carried out using the Wilcoxon test and Spearman correlation test using a significance level of 5%.

Results: Thirty-two patients were included in the study. The percentage of fatty infiltration in the muscle increased on both sides of the spine 1 year after surgery, although only the ipsilateral side presented statistical significance in patients submitted to conventional microdiscectomy (43.3% preoperative and 57.8% postoperative). Muscular degeneration increased significantly ipsilateral to the disc herniation according to the Goutallier classification (grades 1–2) for both interventions. No statistically significant difference was found for fatty infiltration scores or for the degree of muscular degeneration of the multifidus in the comparative analysis of the methods.

Conclusions: Muscular damage resulting from surgery of lumbar disc herniation significantly increases fatty infiltration and degeneration of the multifidus. Muscular degeneration was associated with worsening back pain.

Clinical Relevance: While no significant difference was found between the techniques, the tubular minimally invasive approach shows a tendency for less muscle damage. These findings highlight the importance of minimizing muscle injury during surgery to improve postoperative recovery and long-term outcomes.

Level of Evidence: 4.

Minimally Invasive Surgery

Keywords: minimally invasive surgical procedures, muscle injury atrophy, microdiscectomy, comparative analysis, fatty infiltration, Goutallier classification

INTRODUCTION

The paraspinal musculature, particularly the multifidus muscle, plays a critical role in maintaining the stability and biomechanical function of the spine.^{1,2}

There is growing interest in understanding its normal physiology and pathological states^{3,4} given its relation to the physiopathology of degenerative diseases of the spine, chronic lumbar pain, and scoliosis.^{1,5,6} Among degenerative diseases, lumbar disc herniation is 1 of the most common conditions.¹ Discectomy has long been the standard surgical procedure for treating patients with persistent symptomatic lumbar disc herniation,

with good results in terms of satisfaction and improvement of sciatic pain.⁷ However, similar to other surgical procedures of the lumbar spine that require conventional posterior approaches, the retraction and resection of spinous process muscles (to ensure an adequate field of view) can result in ischemia and denervation of the paraspinal musculature.^{8,9} These changes lead to atrophy of the spinal musculature and can result in reduced biomechanical capacity of the trunk and an unfavorable long-term prognosis in terms of clinical outcomes, primarily represented by residual lumbar pain.^{2,10}

With recent less invasive surgical techniques, one can reduce damage to the paraspinal musculature related to the surgical approach by applying tubular retractors for intramuscular separation. Although the literature shows similar results for tubular and conventional techniques, it is believed that less dissection has potential clinical benefits, which include a reduction in blood loss, reduced postoperative lumbar pain, shorter hospitalization, lower incidence of infection, and faster return to daily activities.^{10,11} However, few studies specifically quantify changes in the multifidus after tubular microdiscectomy. Existing studies present limitations related to sample size, follow-up time, and a lack of correlation between evaluation of the musculature and presented clinical outcomes.^{8,10,11}

The objective of this study was to quantify fatty infiltration and the degree of degeneration of the paraspinal musculature in patients who underwent tubular microdiscectomy and conventional open microdiscectomy.

Our study hypothesized that the tubular intra/intermuscular technique would cause less postoperative muscular tissue damage than the traditional midline approach to spinal surgery. We focused on the degree of fatty infiltration, as measured by Goutallier grade changes, to assess this. Our primary judgment criterion was the comparison of preoperative and 1-year postoperative Goutallier grades in magnetic resonance imaging (MRI) scans.

PATIENTS AND METHODS

This prospective cohort study was conducted at a tertiary private hospital after obtaining approval from the research ethics committee. The study included a consecutive series of patients aged 18 to 65 years with herniated lumbar disc referred for single-level unilateral decompression surgery between January 2017 to March 2019. After signing an informed consent and agreeing to participate, patients were assigned nonrandomly to 2 groups with different surgical techniques based on the surgeon's preference: Group 1 underwent 1-level conventional open midline approach microdiscectomy surgery and group 2 underwent microdiscectomy surgery with the use of a lumbar tubular retractor approach. All patients were prospectively followed for 1 year with questionnaires on quality of life, pain, and dysfunction, applied by the same research secretary, prior to surgery and during the first year after surgery. To be included, all patients underwent an MRI of the lumbosacral spine before surgery and 1 year after surgery. Patients with a history of reoperation, previous infectious, oncological disease, or spinal fracture,

as well as those with incomplete medical histories, were excluded from the study.

Surgical Technique

In the conventional open midline microdiscectomy surgery, the patient was prone positioned under general anesthesia. After vertebral level confirmation through fluoroscopy, a 3-cm skin incision was made at the midline, and the paraspinal muscles were then subperiosteally dissected only at the laminectomy side. A Caspar-type retractor (Taylor, Aesculap, Tuttlingen, Germany) was placed against the ipsilateral side of the spinous process and lateral musculature. A hemilaminectomy and flavectomy were performed to expose the disc space, followed by a standard discectomy.

For the tubular retractor microdiscectomy group, a 1- to 2-cm incision was made 1 cm lateral to the midline at the level of interest. Lumbar fascia was identified and incised. Sequential tubular dilators were introduced through the paraspinal muscles followed by the placement of an 18-mm tubular retractor. A standard microdiscectomy was then performed.

Clinical Analysis

In this study, demographic data were collected for each participant including age, sex, height, weight, and body mass index (BMI). Clinical evaluation was conducted using validated questionnaires administered both before and 1 year after surgery. The Oswestry Disability Index (ODI)¹² was used to evaluate function. The visual analog scale (VAS) was used to assess lumbar pain. Lastly, EuroQol (EQ-5D)¹³ was used to assess the participants' quality of life. All questionnaires were administered by the same research secretary to ensure consistency in the data collected.

Radiographic Analysis

The evaluation of fatty infiltration and muscular degeneration was conducted using an MRI of patients included in the study and extracted from a digital platform (Carestream Health, Inc., 2020). T2-weighted axial images of the operated intervertebral disc level were used for this classification, with analysis performed on the paraspinal muscles at both the ipsilateral and contralateral sides of the operated level before and 1 year after surgery. The degree of paraspinal muscle degeneration was classified using a modified Goutallier scale, which was used to quantify the amount of fatty degeneration of the muscles using a grading scale from 0 to 4 defined as follows: grade 0 indicates no

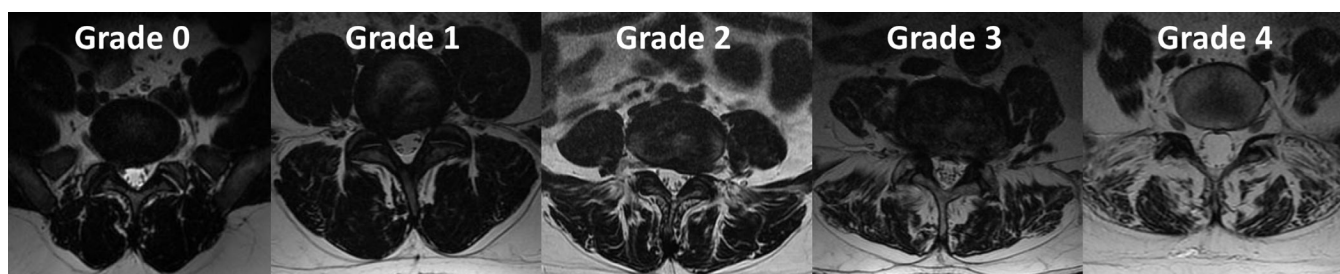


Figure 1. Image representation of the modified Goutallier scale: grade 0 indicates no intramuscular fat; grade 1 indicates some fatty streaks present; grade 2 indicates fat that is evident but less than muscle tissue; grade 3 indicates amounts of fat that are equal to the amount of muscle; and grade 4 indicates more fat than muscle tissue.

intramuscular fat; grade 1 indicates some fatty streaks present; grade 2 indicates fat that is evident but less than muscle tissue; grade 3 indicates amounts of fat that are equal to the amount of muscle; and grade 4 indicates more fat than muscle tissue (Figure 1).¹⁴

Quantitative analysis was conducted with ImageJ software (version 1.43, U.S. National Institutes of Health, Bethesda, Maryland, USA) according to the methodology proposed by Battaglia et al.¹⁵ The software interprets the intensity of gray levels and pixels using a monochromatic scale with values that range from 0 to 256. For the measurement in pixels, the area of the multifidus muscle was selected manually at both the operated and nonoperated side (Figure 2).

Independent analysis was performed by 2 examiners who did not participate in the image selection process: a spine surgeon with more than 5 years of experience and a second-year intern specializing in spine surgery. Concordance between examiners was determined using the Kappa coefficient, resulting in a good concordance level between 0.6 and 0.8, and the Lin coefficient, also

resulting in good concordance levels between 0.8 and 0.9.

Statistical Analysis

To characterize study participants, a descriptive analysis was carried out based on measurements of averages, SDs, minimums, medians, and maximums. The nonparametric Wilcoxon signed-rank test was used to compare the degeneration of paraspinal muscles before and after surgery, as well as to assess differences in degeneration and clinical variables based on type of surgery and sex. The nonparametric Spearman's rank-order correlation test was used to analyze the association between muscular degeneration, clinical outcomes, age, and BMI. A significance level of $P < 0.05$ was adopted for all analyses.

RESULTS

A total of 32 patients completed all questionnaires and imaging studies after 1 year of follow-up and were included in the analysis. The mean age of the participants was 46 ± 14 years, of which 53.1% were men. The mean BMI was 26.52 ± 7 (Table 1).

Regarding the level of surgery, 6.89% of the patients were operated on at the L3-L4 level, 44.82% L4-L5, and 48.27% L5-S1. In terms of surgery type, 40.62% (13 patients) had a conventional microdiscectomy and were included in group 1, while 59.38% (19 patients) underwent tubular microdiscectomy and composed group 2.

Table 2 and Figure 3 show that radiating pain had a greater mean and median score than low back pain on the VAS before surgery, and radiating pain generally decreased more than low back pain after surgery. More than half of the patients scored 0 on a scale of 0 to 10 for radiating pain after surgery. The ODI and EQ-5D scales also showed large reductions in their means between the 2 periods, with the mean ODI going from 46.62 to

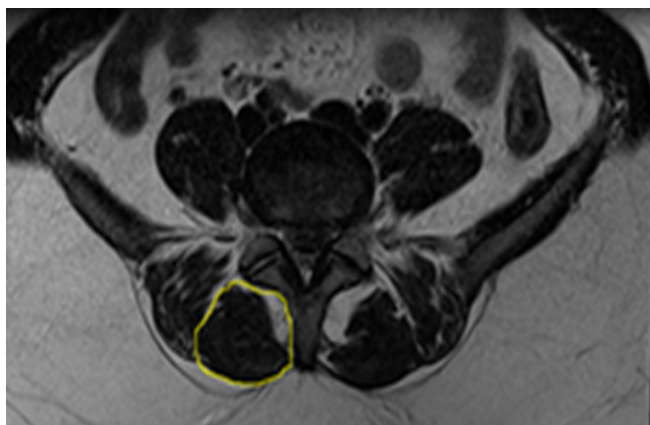


Figure 2. Selection of the multifidus muscle (represented in the yellow circle) using ImageJ software. The obtained image was then converted to an 8-bit scale. The standard calibration was determined using the psoas muscle as the lower limit and the subcutaneous fat as the upper limit. The relative amount of fat is represented by the number of pixels present, expressed as a percentage. A comparison of the 2 sides was made between the 2 groups and participants, using the nonoperated side as a control.

Table 1. Demographic and clinical data.

Variable	Mean	SD	Minimum	Median	Maximum
Age, y	46.19	13.22	22	43.5	79
BMI	26.52	3.69	19.03	26.84	34.89
Time to MRI, mo	13.84	3.95	7	13	24

Abbreviations: BMI, body mass index; MRI, magnetic resonance imaging.

Table 2. Descriptive measures of the clinical variables of the research participants, by moment.

Clinical Variable	Preoperative Scores		Postoperative Scores	
	Mean	Median (Min; Max)	Mean	Median (Min; Max)
VAS back pain	5.80	6 (0; 10)	2.31	1 (0; 9)
VAS leg pain	7.33	8 (0; 10)	2.15	0 (0; 9)
ODI	46.62	41 (12; 88)	13.85	12 (0; 46)
EQ-5D	46.67	50 (10; 80)	13.85	10 (0; 50)

Abbreviations: EQ-5D, EuroQol; ODI, Oswestry Disability Index; VAS, visual analog scale.

13.85 points and the EQ-5D going from 46.67 to 13.85 points.

For both procedures, there was an increase in fatty infiltration on both sides according to the results of the image analysis by ImageJ. Patients who underwent tubular microdiscectomy (group 2) presented a 3.29% increase of fatty infiltration on the operated side, although this increase was not statistically significant. The same patients presented a statistically significant increase in the considered Goutallier interval (1–3; $P = 0.037$). The results on the nonoperated side (control) did not reach statistical significance for either analysis (Table 3).

Patients submitted to conventional open microdiscectomy (group 1) presented no statistically significant difference between the methods used for the nonoperated side. However, there was a statistically significant increase in the percentage of fatty infiltration (21.17%, $P = 0.020$) on the operated side. This increase was also observed in the Goutallier classification ($P = 0.002$),

which was represented by an increase in the median (1–2). No statistical difference was found between tubular and conventional microdiscectomy for fatty infiltration scores and for the degree of multifidus muscle degeneration. Table 4

Regarding clinical outcomes, improvement was observed in patients who underwent both procedures, with no statistically significant difference between the 2 groups. Correlation analysis between the methods used for evaluating the degree of muscular degeneration and clinical results revealed a statistically significant association between variations in the Goutallier scale and the perception of lumbar pain, as measured by the VAS for lumbar pain. Table 5

Specifically, higher Goutallier classifications (indicative of greater fatty degeneration) were associated with poorer clinical outcomes, characterized by worsening of pain and a diminished perception of improvement.

DISCUSSION

The paraspinal musculature, particularly the multifidus muscles, plays a vital role in the physiological load transport and functional movement of the spinal column, as well as in stability.^{1,2} The correlation between paraspinal muscular injury and lumbar surgery has been established, particularly with the increasing use of less invasive techniques.^{3,4,8–11,16,17} However, only a limited number of studies have compared postoperative differences in the paraspinal musculature between minimally

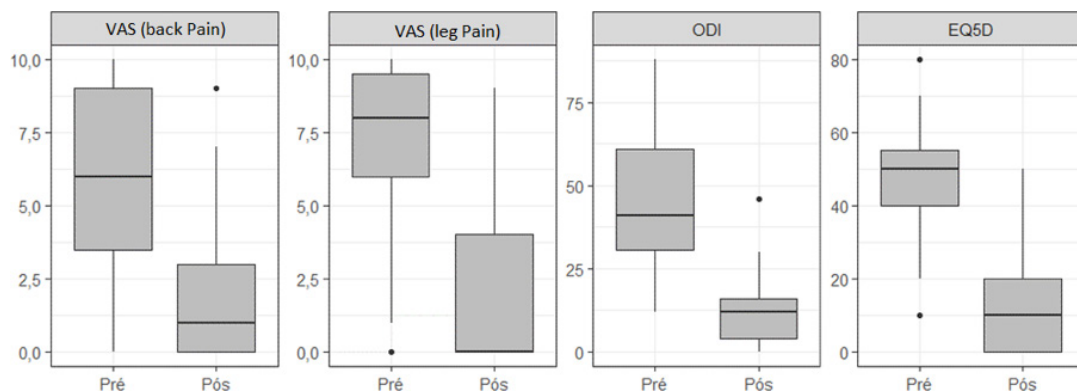
**Figure 3.** . Boxplots of the clinical variables of the research participants, by time point.

Table 3. Evaluation of fatty percentage according to the procedure performed.

Outcome Measure	Midline Lumbar Microdiscectomy		Tubular Lumbar Microdiscectomy	
	Ipsilateral	Contralateral	Ipsilateral	Contralateral
Fatty Multifidus Infiltration, %				
Preoperative	36.62 (29.63; 59.04)	41.5 (33.87; 53.38)	44.92 (38.42; 51.39)	36.78 (27.73; 61.28)
Postoperative	57.79 (48.49; 66.17)	47.63 (32.05; 60.24)	48.21 (28.41; 55.95)	42.74 (33.18; 54.36)
<i>P</i>	0.020	0.465	1.0	0.946
Muscular Degeneration (Goutallier)				
Preoperative	1 (1; 2)	1 (1; 2)	1 (1; 2)	1 (1; 2)
Postoperative	2 (1; 2)	1 (1; 2)	1 (1; 3)	1 (1; 2)
<i>P</i>	0.002	0.145	0.037	>0.99

Note: Values are shown as median (minimum; maximum) . *P* < 0.005.

Table 4. Comparison between the 2 methods with regard to variation in muscular degeneration.

Outcome Measure	Ipsilateral		Contralateral	
	Fatty Multifidus Infiltration (%)	Muscular Degeneration (Goutallier)	Fatty Multifidus Infiltration (%)	Muscular Degeneration (Goutallier)
Tubular lumbar microdiscectomy	-3.02 (-5.62; 15)	0 (0; 1)	0.38 (-3.63; 5.2)	0 (0; 0)
Midline lumbar microdiscectomy	16.43 (-6.1; 26.97)	1 (0; 1)	2.48 (-12.78; 15.21)	0 (0; 0)
<i>P</i>	0.108	0.451	0.520	0.149

Note: Values are shown as mean (minimum; maximum) . *P* < 0.005.

Table 5. Correlation between variation in the clinical results and variation in the percentage of fat.

Clinical Variable	Ipsilateral		Contralateral	
	Fatty Multifidus Infiltration (%)	Muscular Degeneration (Goutallier)	Fatty Multifidus Infiltration (%)	Muscular Degeneration (Goutallier)
VAS back pain	0.05 (0.9)	0.83 (0.006)	0.01 (0.98)	-0.16 (0.69)
VAS leg pain	0.59 (0.097)	-0.23 (0.55)	0.43 (0.25)	0.05 (0.89)
ODI	-0.02 (0.97)	0.14 (0.72)	-0.15 (0.67)	-0.55 (0.13)
EQ-5D	0.37 (0.29)	-0.27 (0.45)	0.29 (0.41)	-0.04 (0.9)

Abbreviations: EQ-5D, EuroQol; ODI, Oswestry Disability Index; VAS, visual analog scale.

Note: Values are shown as median (*P* value). *P* < 0.005.

invasive techniques and the conventional posterior lumbar approach.^{8,11,16,17}

In the context of surgical treatment of lumbar disc herniation, this study aimed to quantify fatty infiltration and the degree of paraspinal muscle degeneration in patients who underwent tubular microdiscectomy compared with conventional microdiscectomy. We observed that in patients undergoing tubular microdiscectomy, there was a statistically significant difference in changes in the multifidus muscles according to the Goutallier classification. In the quantitative analysis of the percentage of infiltration, there was an average increase of 3.19%, which was 6 times smaller than that of patients who underwent conventional microdiscectomy (21.17%). Patients who underwent tubular lumbar microdiscectomy had minimal muscular degeneration in the short term (1.2% of fatty infiltration), similar to the contralateral side.¹¹ Similar results were found in other studies that used minimally invasive techniques.

Bresnahan et al⁸ compared the open approach for lumbar stenosis and observed that decompression by less invasive methods had a significantly lower impact on the paraspinal musculature. Fan et al¹⁶ compared the atrophy in the multifidus muscle in patients who underwent a posterior interbody fusion with percutaneous screws (MIS-transforaminal lumbar interbody fusion) to open posterior lumbar interbody fusion. Although the authors were comparing different techniques and a wide range of indications for patients within a spectrum of degenerative diseases, they were able to show significantly lower muscular atrophy in the percutaneous cohort compared with the open cohort. These results may be related to a lower inflammatory response at the lesion site, with smaller amounts of systemic IL-6 and serum C-reactive protein.¹⁸ The increase in the expression of proinflammatory cytokines plays an active role in the multifidus muscle and may contribute to the formation of fibrosis and fat infiltration, inhibiting the proliferation and differentiation

of cells and hindering the regeneration of muscular fiber.^{19,20}

There was no statistically significant difference between the considered techniques, which may be related to the sample size of this study. However, Arts et al¹⁰ conducted a double-blinded randomized clinical trial involving 216 patients and similarly found no difference in the degree of atrophy between tubular microdiscectomy and conventional open microdiscectomy or in the percentage of patients showing an increase in the muscular atrophy score.

As expected, both groups presented statistically significant improvement in terms of pain, function, and quality of life. The similar and favorable clinical results of tubular and standard microdiscectomy are well described in the literature.^{21,22} There was a statistically significant relationship between lumbar pain and the degree of degeneration when clinical results were associated with those obtained in the evaluation of the quantification of muscular degeneration. In other words, a greater degree of muscular degeneration was associated with worsening of lumbar pain postoperatively. The involvement of the paraspinal musculature may be one of the possible mediators, directly influencing pain and disability after treatment.²³ The inflammatory response triggered by the surgical iatrogenic lesion and consequent muscular dysfunction can lead to segmental instability, which is responsible for the pain process in the short and long term.²⁴

Fan et al¹⁶ found a significant correlation between muscular damage during surgery and muscular atrophy of the multifidus in the long term, as well as fatty infiltration. Furthermore, these degenerative changes in the multifidus were also significantly correlated with worse long-term clinical outcomes. However, the literature remains controversial. Ohtori et al²⁵ reported that all of their patients presented with muscular degeneration 12 months after surgery, but lumbar pain decreased after surgery and was not associated with any type of muscular degeneration after surgery, as identified by MRI of the lumbar spine.

Limitations

Although statistically significant differences were found, the number of cases evaluated is relatively small. However, to the best of our knowledge, the current study is the largest radiographic and prospective clinical analysis of patients submitted to primary tubular microdiscectomy, with a control group submitted to conventional microdiscectomy. Furthermore, the lack of correlation of the results with age, BMI, and time of MRI indicates less heterogeneity between the groups. Another

possible limitation is the inability to differentiate fibrous scar tissue and fat tissue in the analysis of musculature with the methods chosen. However, the method used to analyze fat percentage has been described and employed in various works, including the study of other lumbar pathologies.⁶ The validity and reproducibility of the relationship between the modified Goutallier classification and degenerative disc diseases have been the object of research, with excellent correlation.¹⁴

CONCLUSION

The study found that both tubular and open microdiscectomy lead to increased fatty infiltration in the paraspinal musculature 1 year after surgery, with no statistical difference between the 2 techniques. However, the tubular technique did show a tendency toward a lower rate of muscular degeneration and fatty infiltration compared with the open technique. There is a significant relationship between the degree of muscular degeneration and worse postoperative lumbar pain. Moreover, higher degrees of fatty infiltration in the muscle after microdiscectomy are related to higher scores of lumbar pain.

REFERENCES

1. Altinkaya N, Cekinmez M. Lumbar multifidus muscle changes in unilateral lumbar disc herniation using magnetic resonance imaging. *Skeletal Radiol*. 2016;45(1):73–77. doi:10.1007/s00256-015-2252-z
2. Cholewicki J, Panjabi MM, Khachatryan A. Stabilizing function of trunk flexor-extensor muscles around a neutral spine posture. *Spine*. 1997;22(19):2207–2212. doi:10.1097/00007632-199710010-00003
3. Kulig K, Scheid AR, Beauregard R, Popovich JM, Beneck GJ, Colletti PM. Multifidus morphology in persons scheduled for single-level lumbar microdiscectomy. *Am J Phys Med Rehabil*. 2009;88(5):355–361. doi:10.1097/PHM.0b013e31819c506d
4. Sihvonen T, Hernö A, Paljärvi L, Airaksinen O, Partanen J, Tapaninaho A. Local denervation atrophy of paraspinal muscles in postoperative failed back syndrome. *Spine*. 1993;18(5):575–581. doi:10.1097/00007632-199304000-00009
5. Takayama K, Kita T, Nakamura H, et al. New predictive index for lumbar paraspinal muscle degeneration associated with aging. *Spine*. 2016;41(2):E84–E90. doi:10.1097/BRS.0000000000001154
6. Wajchenberg M, Astur N, Fernandes EA, et al. Assessment of fatty infiltration of the multifidus muscle in patients with adolescent idiopathic scoliosis through evaluation by magnetic resonance imaging compared with histological analysis: a diagnostic accuracy study. *J Pediatr Orthop B*. 2019;28(4):362–367. doi:10.1097/BPB.0000000000000578
7. Mixter WJ, Barr JS. Rupture of the intervertebral disc with involvement of the spinal canal. *N Engl J Med*. 1934;211(5):210–215. doi:10.1056/NEJM193408022110506

8. Bresnahan LE, Smith JS, Ogden AT, et al. Assessment of paraspinal muscle cross-sectional area after lumbar decompression. *Clin Spine Surg.* 2017;30(3):E162–E168. doi:10.1097/BSD.0000000000000038
9. Motosuneya T, Asazuma T, Tsuji T, Watanabe H, Nakayama Y, Nemoto K. Postoperative change of the cross-sectional area of back musculature after 5 surgical procedures as assessed by magnetic resonance imaging. *J Spinal Disord Tech.* 2006;19(5):318–322. doi:10.1097/01.bsd.0000211205.15997.06
10. Arts M, Brand R, van der Kallen B, Lycklama à Nijeholt G, Peul W. Does minimally invasive lumbar disc surgery result in less muscle injury than conventional surgery? A randomized controlled trial. *Eur Spine J.* 2011;20(1):51–57. doi:10.1007/s00586-010-1482-y
11. Tabaraee E, Ahn J, Bohl DD, Phillips FM, Singh K. Quantification of multifidus atrophy and fatty infiltration following a minimally invasive microdiscectomy. *Int J Spine Surg.* 2015;9(1–7):25. doi:10.14444/2025
12. Vigatto R, Alexandre NMC, Filho HRC. Development of a Brazilian Portuguese version of the Oswestry Disability Index. *Spine.* 2007;32(4):481–486. doi:10.1097/01.brs.0000255075.11496.47
13. Ferreira PL, Ferreira LN, Pereira LN. Contribution for the validation of the Portuguese version of EQ-5D. *Acta Med Port.* 2013;26(6):664–675. doi:10.20344/amp.1317
14. Tamai K, Chen J, Stone M, et al. The evaluation of lumbar paraspinal muscle quantity and quality using the Goutallier classification and lumbar indentation value. *Eur Spine J.* 2018;27(5):1005–1012. doi:10.1007/s00586-018-5485-4
15. Battaglia PJ, Maeda Y, Welk A, Hough B, Kettner N. Reliability of the Goutallier classification in quantifying muscle fatty degeneration in the lumbar multifidus using magnetic resonance imaging. *J Manipul Physiol Ther.* 2014;37(3):190–197. doi:10.1016/j.jmpt.2013.12.010
16. Fan S, Hu Z, Zhao F, Zhao X, Huang Y, Fang X. Multifidus muscle changes and clinical effects of one-level posterior lumbar interbody fusion: minimally invasive procedure versus conventional open approach. *Eur Spine J.* 2010;19(2):316–324. doi:10.1007/s00586-009-1191-6
17. Fu C-J, Chen W-C, Lu M-L, Cheng C-H, Niu C-C. Comparison of paraspinal muscle degeneration and decompression effect between conventional open and minimal invasive approaches for posterior lumbar spine surgery. *Sci Rep.* 2020;10(1):14635. doi:10.1038/s41598-020-71515-8
18. Huang T-J, Hsu R-W, Li Y-Y, Cheng C-C. Less systemic cytokine response in patients following microendoscopic versus open lumbar discectomy. *J Orthop Res.* 2005;23(2):406–411. doi:10.1016/j.orthres.2004.08.010
19. James G, Sluka KA, Blomster L, et al. Macrophage polarization contributes to local inflammation and structural change in the multifidus muscle after intervertebral disc injury. *Eur Spine J.* 2018;27(8):1744–1756. doi:10.1007/s00586-018-5652-7
20. Bentzinger CF, Wang YX, Dumont NA, Rudnicki MA. Cellular dynamics in the muscle satellite cell niche. *EMBO Rep.* 2013;14(12):1062–1072. doi:10.1038/embor.2013.182
21. Clark AJ, Safaee MM, Khan NR, Brown MT, Foley KT. Tubular microdiscectomy: techniques, complication avoidance, and review of the literature. *Neurosurg Focus.* 2017;43(2):E7. doi:10.3171/2017.5.FOCUS17202
22. Alvi MA, Kerezoudis P, Wahood W, Goyal A, Bydon M. Operative approaches for lumbar disc herniation: a systematic review and multiple treatment meta-analysis of conventional and minimally invasive surgeries. *World Neurosurg.* 2018;114:391–407. doi:10.1016/j.wneu.2018.02.156
23. Stevens S, Agten A, Timmermans A, Vandenabeele F. Unilateral changes of the multifidus in persons with lumbar disc herniation: a systematic review and meta-analysis. *Spine J.* 2020;20(10):1573–1585. doi:10.1016/j.spinee.2020.04.007
24. Linzer P, Filip M, Šámal F, et al. Comparison of biochemical markers of muscle damage and inflammatory response between the open discectomy, microsurgical discectomy, and microsurgical discectomy using tubular retractor. *J Neurol Surg A Cent Eur Neurosurg.* 2015;76(5):384–391. doi:10.1055/s-0034-1393929
25. Ohtori S, Orita S, Yamauchi K, et al. Classification of chronic back muscle degeneration after spinal surgery and its relationship with low back pain. *Asian Spine J.* 2016;10(3):516. doi:10.4184/asj.2016.10.3.516

Funding: The authors received no financial support for the research, authorship, and/or publication of this article.

Competing interests: The Authors declares that there is no conflict of interest

Disclosures: This research received no specific grant from any funding agency in the public, commercial, or not-for-profit sectors.

Patient consent for publication: Participants signed a free and informed consent form. All participants were informed of what their participation would consist of, as well as the risks, benefits, duties, and rights involved in agreeing to participate.

Ethics Approval: All procedures performed in studies involving human participants were in accordance with the ethical standards of the institutional and/or national research committee and with the 1964 Helsinki Declaration and its later amendments or comparable ethical standards. The study was approved by the Bioethics Committee of the Universidade Anhembí Morumbi/Instituto Superior de Comunicação Publicitária - ISCP/SP (CAAE 27043519.0.0000.5492).

Corresponding Author: Lucas Rabello de Oliveira, Hospital Israelita Albert Einstein, Av. Albert Einstein, 627 - Jardim Leonor, São Paulo, SP, Brazil; lucas.sro2@gmail.com

Published 26 August 2024

This manuscript is generously published free of charge by ISASS, the International Society for the Advancement of Spine Surgery. Copyright © 2024 ISASS. To see more or order reprints or permissions, see <http://ijssurgery.com>.