

Biportal Endoscopic Transforaminal Lumbar Interbody Fusion: How to Improve Fusion Rate?

Hyun-Jin Park, John I. Shin, Ki-Han You, Jason I. Yang, Nathan Kim, Yong H. Kim, Min-Seok Kang and Sang-Min Park

Int J Spine Surg 2024, 18 (5) 582-588

doi: <https://doi.org/10.14444/8648>

<https://www.ijssurgery.com/content/18/5/582>

This information is current as of May 3, 2025.

Email Alerts Receive free email-alerts when new articles cite this article. Sign up at:
<http://ijssurgery.com/alerts>

Biportal Endoscopic Transforaminal Lumbar Interbody Fusion: How to Improve Fusion Rate?

HYUN-JIN PARK, MD, PhD^{1*}; JOHN I. SHIN, MD^{2*}; KI-HAN YOU, MD¹; JASON I. YANG, MD³; NATHAN KIM, MD⁴; YONG H. KIM, MD⁴; MIN-SEOK KANG, MD⁵; AND SANG-MIN PARK, MD⁶

¹Department of Orthopedic Surgery, Spine Center, Hallym University College of Medicine, Kangnam Sacred Heart Hospital, Seoul, South Korea; ²Department of Orthopedic Surgery, Cooperman Barnabas Medical Center/Jersey City Medical Center—RWJBarnabas Health, Jersey, NJ, USA; ³Department of Orthopedic Surgery, Rutgers—Robert Wood Johnson University Hospital, RWJBarnabas Health, New Brunswick, NJ, USA; ⁴Department of Orthopedic Surgery, NYU Langone Health, New York, NY, USA; ⁵Department of Orthopedic Surgery, Korea University College of Medicine, Anam Hospital, Seoul, Republic of Korea; ⁶Spine Center and Department of Orthopedic Surgery, Seoul National University College of Medicine and Seoul National University Bundang Hospital, Seongnam, South Korea

*Hyun-Jin Park and John I. Shin contributed equally to the work.

ABSTRACT

Background: Biportal endoscopic transforaminal lumbar interbody fusion (BE-TLIF) is a minimally invasive surgical technique for treating degenerative lumbar spine conditions. It offers advantages such as reduced soft tissue trauma and lower infection rates, but certain technical aspects may be challenging. The current study aims to identify strategies to enhance the fusion rate in BE-TLIF by addressing these specific challenges.

Methods: A literature review was conducted on techniques to improve fusion rates in BE-TLIF.

Results: The review suggests that lateral-based portals supplemented with medial portals allowed for safe insertion of interbody cages with large footprint. Direct visualization of the disc space with a 30° endoscope assisted with better disc space preparation. Facetectomies performed with osteotomes, rather than burrs, ensured maximum retrieval of autologous bone graft. Utilizing bone morphogenetic proteins with sustained release carriers such as hydroxyapatite can be useful to increase fusion rates of BE-TLIF.

Conclusions: To our knowledge, the current literature is the first comprehensive review of strategies to enhance fusion rates in BE-TLIF. The proposed techniques and biological adjuncts are effective means to address key challenges associated with the procedure, and such strategies would potentially shorten the learning curve and improve clinical outcomes. Further clinical studies are required to validate these findings and establish standardized protocols.

Clinical Relevance: These findings provide practical solutions to overcome common challenges in BE-TLIF. The suggested techniques would reduce the incidence of pseudarthrosis, improve patient outcomes, and ultimately offer a safer and more reliable option for lumbar interbody fusion patients.

Level of Evidence: 5.

Endoscopic Minimally Invasive Surgery

Keywords: biportal endoscopy, transforaminal lumbar interbody fusion, pseudoarthrosis, fusion rate

INTRODUCTION

Biportal endoscopic spine surgery is the most recent development within the realm of minimally invasive spine surgery. The basic concept of the approach is the use of 2 portals—1 for the endoscope and the other for the instruments—to address various degenerative spinal pathologies.^{1,2} This ultra-minimally invasive approach offers a multitude of benefits including, but not limited to, less soft tissue trauma, less estimated blood loss, and improved early postoperative pain,^{3,4} which may facilitate shorter length of stay or reduction in postoperative analgesics use. Moreover, the surgical site infection rate may be lower than that of the traditional open surgeries since the surgical site is constantly being irrigated with saline, as in arthroscopy surgeries.⁵

The use cases of the biportal endoscopic approach have expanded from decompressions for herniated discs³ or stenosis⁶ to lumbar interbody fusions with instrumentation for degenerative spondylolisthesis.⁷ Numerous recent reports demonstrate the efficacy of biportal endoscopic transforaminal lumbar interbody fusion (BE-TLIF) and demonstrate fusion rates comparable to that of traditional open approaches at a minimum of 1-year follow-up.^{7–9} However, concerns exist regarding some aspects of the approach that may result in pseudarthrosis.

Since the working space for the biportal endoscopic approach is small, the risk of nerve or dural tear may be higher when inserting the interbody cage. This risk may render the discectomy and disc space preparation inadequate and could nudge surgeons to utilize smaller

interbody devices. There is also a concern of not being able to retrieve as much local autologous bone graft as other techniques. The continuous saline irrigation at the surgical site may wash out the bone graft and other fusion materials. Finally, the learning curve for the technique may not be favorable for this relatively new approach. All these factors increase the risk of pseudarthrosis.

To our knowledge, there is a lack of literature on strategies to minimize pseudarthrosis in BE-TLIF. In the current report, the authors aim to provide surgical tips and tricks to enhance the fusion rate to help make the learning curve more amenable.

OVERVIEW OF BE-TLIF TECHNIQUES

The general sequence of the BE-TLIF is similar to that of the traditional TLIF. After induction of general anesthesia, the patient is positioned prone on a radiolucent Jackson spine table with cradles. Facetectomy and central decompression are performed as needed followed by discectomy and endplate preparation. Then, graft and cage of choice are inserted through Kambin's triangle. Finally, pedicle screws and rods are inserted percutaneously, and the incisions are closed. Interbody cages and posterior instrumentations are typically utilized to stabilize the segment until complete fusion takes place, which takes about 6 months to a year. Percutaneous pedicle screws were applied to all patients. Percutaneous screw fixation is typically preferred due to its minimally invasive nature, which can result in reduced blood loss, shorter hospital stays, and quicker recovery times.¹⁰ The stand-alone technique has previously been reported to carry an increased risk of pseudoarthrosis and subsidence. Pedicle screw augmentation has been demonstrated to enhance the stability of the

surgical segment.¹¹ There is no significant difference in stability between traditional pedicle screw fixation and percutaneous screw fixation, with both techniques demonstrating comparable efficacy.^{12,13} Furthermore, known strategies for achieving successful lumbar interbody fusion and minimizing pseudarthrosis include, but not limited to, adequate discectomy and disc space preparation, the use of a cage with a larger footprint, and inclusion of autologous bone graft. Strategies that can be employed with biportal endoscopic approach to address each of these points are discussed in detail in the following paragraphs.

Technical Strategies

Contralateral Facetectomy Using Multiportal Technique

There are 2 described locations in terms of surgical incisions for BE-TLIF. The first method utilizes 2 incisions dorsal to the pedicles as seen in Figure 1A.¹⁴ Establishing such portals is advantageous in performing central and contralateral decompression; however, the corridor through which the cage is inserted is more upright and narrower, making safe insertion of larger cages challenging.

The other described method that will be discussed more thoroughly in the current article involves the establishment of 2 portals approximately 2 cm from the lateral margin of the pedicles as demonstrated in Figure 1B (labeled as P + 2[L], P + 2[R] portal).^{15,16} This approach renders complete facetectomy and skeletonization of the caudal pedicle much easier. The angle of approach to the disc space becomes oblique, widening the corridor and making the insertion of a larger cage safer and feasible (Figure 1B).

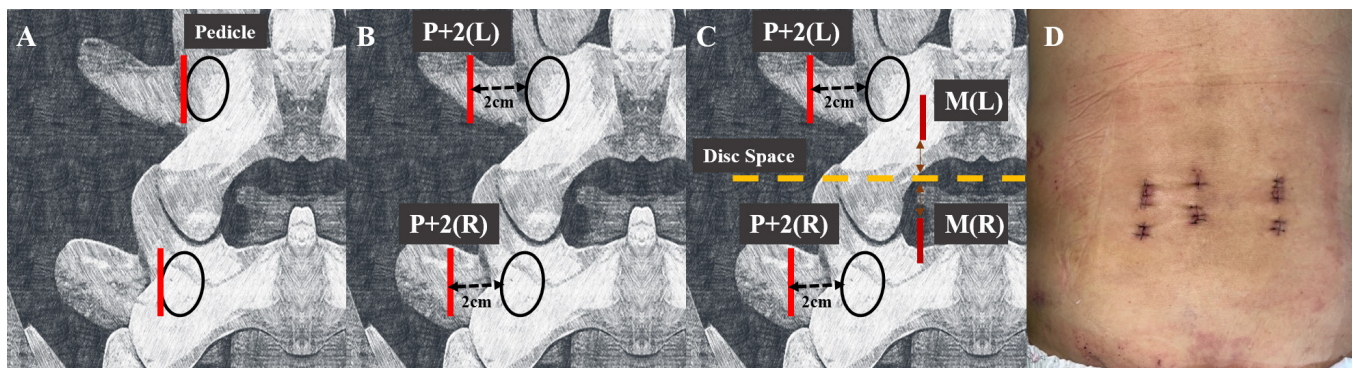


Figure 1. Diagrams and a photograph for the left-sided approach. (A) Utilization of 2 incisions over the pedicle for biportal endoscopic transforaminal lumbar interbody fusion (BE-TLIF). (B) Utilization of 2 laterally based incisions (P + 2) for BE-TLIF. (C) Portals used for multiportal technique. The 2 lateral-based portals (P + 2) are used for ipsilateral facetectomy, and the 2 medially based portals (M) are used for central decompression and contralateral facetectomy. (D) An example of surgical incision for multiportal technique for one level BE-TLIF. Abbreviations: P, pedicle; M, medial; L, left; R, right. P + 2 refers to incisions are made 2 cm lateral to the lateral margin of the pedicle.

A downside to this approach, however, is the difficulty of contralateral facetectomy and decompression. To address this shortcoming, 2 additional portals are established medial to the pedicles as shown in Figure 1C (called M [L], M[R] portal). These portals are used for decompression and contralateral facetectomy as previously described prior to the endplate preparation and cage insertion.¹⁶ The contralateral facetectomy provides additional autologous bone graft and makes the segment more mobile, which, in turn, decreases the risk of endplate injury during cage insertion. Since the M portals are not used for retrieving autologous bone graft or cage insertion, these portals can be made smaller for cosmesis (Figure 1D).

Discectomy and Endplate Preparation

After completion of ipsilateral and contralateral decompression using the M portals, the P + 2 portals are utilized to ensure complete removal of the facet joint and skeletonization of the pedicle of the caudal vertebra. The ligamentum flavum under the facet joint is then removed carefully to expose Kambin's triangle for discectomy and disc space preparation.

Complete discectomy and adequate endplate preparation, while avoiding endplate injury, are prerequisites for successful fusion without subsidence or pseudarthrosis. Discectomy and disc space preparation from posterior-based approaches are performed without direct visualization. No data are available on the adequacy of disc space preparation *in vivo*; however, a cadaveric study by Rihn et al with 40 lumbar levels compared the process in minimally invasive vs open approach and demonstrated that the percentage of disc material removed was approximately 75% for either

approach. The posterior contralateral quadrant of the disc space was the area with the lowest percentage of disc removed. Endplate violation rates were 15% and 5% in minimally invasive surgery and open approaches, respectively.¹⁷ Another cadaveric study involving 24 disc levels compared mini-open approaches for anterior lumbar interbody fusion, posterior lumbar interbody fusion, TLIF, and lateral lumbar interbody fusion. For TLIF, the Nuvasive MAS system was utilized. While all the approaches demonstrated adequate endplate preparation for interbody fusion, endplate damage was significantly higher in the TLIF group at 48% of the relative endplate area damage.¹⁸

With the biportal endoscopic approach, 1 of the M portals that is more in line with the disc space can be used for the endoscope to view the disc space to confirm the adequacy of discectomy and disc space preparation as seen in Figure 1A. Angled curettes and upgoing pituitary rongeurs could be used to address the contralateral disc space. The 0° and 30° scopes can be utilized to visualize the ipsilateral and contralateral disc space, respectively (Figure 2B, 2C). This real-time feedback would help surgeons to perform more complete discectomy without incurring inadvertent endplate damage.

Cage Insertion and Positioning on Apophyseal Ring

The local autologous bone graft and bone extenders such as demineralized bone matrix or allograft bone chips are placed at the window within the cage. If bone morphogenic protein (BMP) is used, it should be placed at the centermost position, packaged within other graft materials to prevent leakage of BMP, which could result

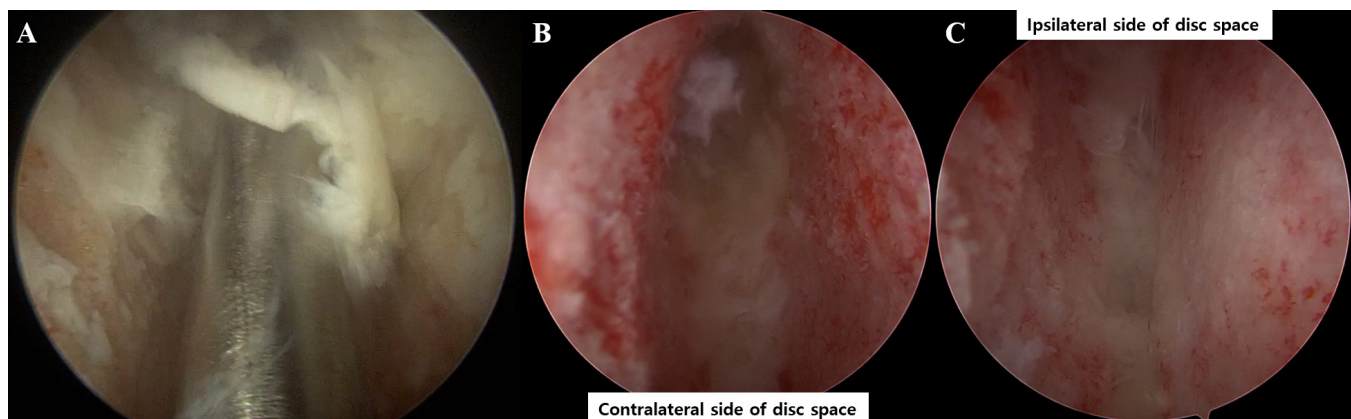


Figure 2. Intraoperative visualization of the disc space is demonstrated. (A) Disc space preparation with a curette with direct visualization. (B) Intraoperative endoscopic picture taken with a 30° scope while assessing the adequacy of contralateral disc space preparation, which is shown at the top of the photo. (C) Image taken with a 30° scope while assessing the disc space preparation on the ipsilateral side, which is toward the bottom of the photo. Both images B and C show adequate endplate preparation without residual disc or cartilage while avoiding endplate damage.

in undesirable outcomes such as the formation of bone in the spinal canal.

During cage insertion, 1 of the M portals can be used to visualize the traversing nerve root, while the exiting root is retracted through 1 of the P + 2 portals not being used for cage insertion. Using fluoroscopy and direct visualization, the surgeon can assess the point at which the cage should be turned horizontally. The M portal can be used for the tamp to rotate the cage because the more medially based portal can accommodate the force vector that is more amenable for cage rotation. Ideally, the cage should be horizontally placed with bilateral ends resting on the apophyseal ring, which is the stronger structure on the surface of the endplate (Figure 3). Such positioning decreases the risk of subsidence, and this is thought to be 1 of the advantages in lateral lumbar interbody fusions.^{19,20}

Finally, to decrease the chance of endplate damage during cage insertion, we recommend contralateral facetectomy to render the segment more mobile, which, in turn, would make the cage insertion easier and decrease the degree of point-loading of pressure on the endplates. The contralateral facetectomy can be performed using the 2 medial portals as described previously.¹⁶

Device and Graft Selection

Cage Footprint

Cages with large footprints would enhance the segmental stability and more evenly distribute the loading between the adjacent vertebrae at the endplate, resulting in less likelihood of endplate point-loading and resultant subsidence. Moreover, larger cages generally have bigger hollow space within the cage to accommodate larger graft volume.

Inserting a large cage safely without causing neurological injury may be a challenge, especially in minimally invasive approaches. For example, in cases of minimally invasive TLIF (MI-TLIF) utilizing a tubular retractor, the size of the graft is limited by the diameter of the tube because it needs to accommodate both the nerve root retractor and the cage. This is perhaps why uni- or bidirectional expandable cages are commonly used with tubular MI-TLIF cases.²¹ On the other hand, inserting a cage with a large footprint with direct visualization is feasible using a biportal endoscopic approach with the use of the more laterally based approach as mentioned previously (Figure 3).

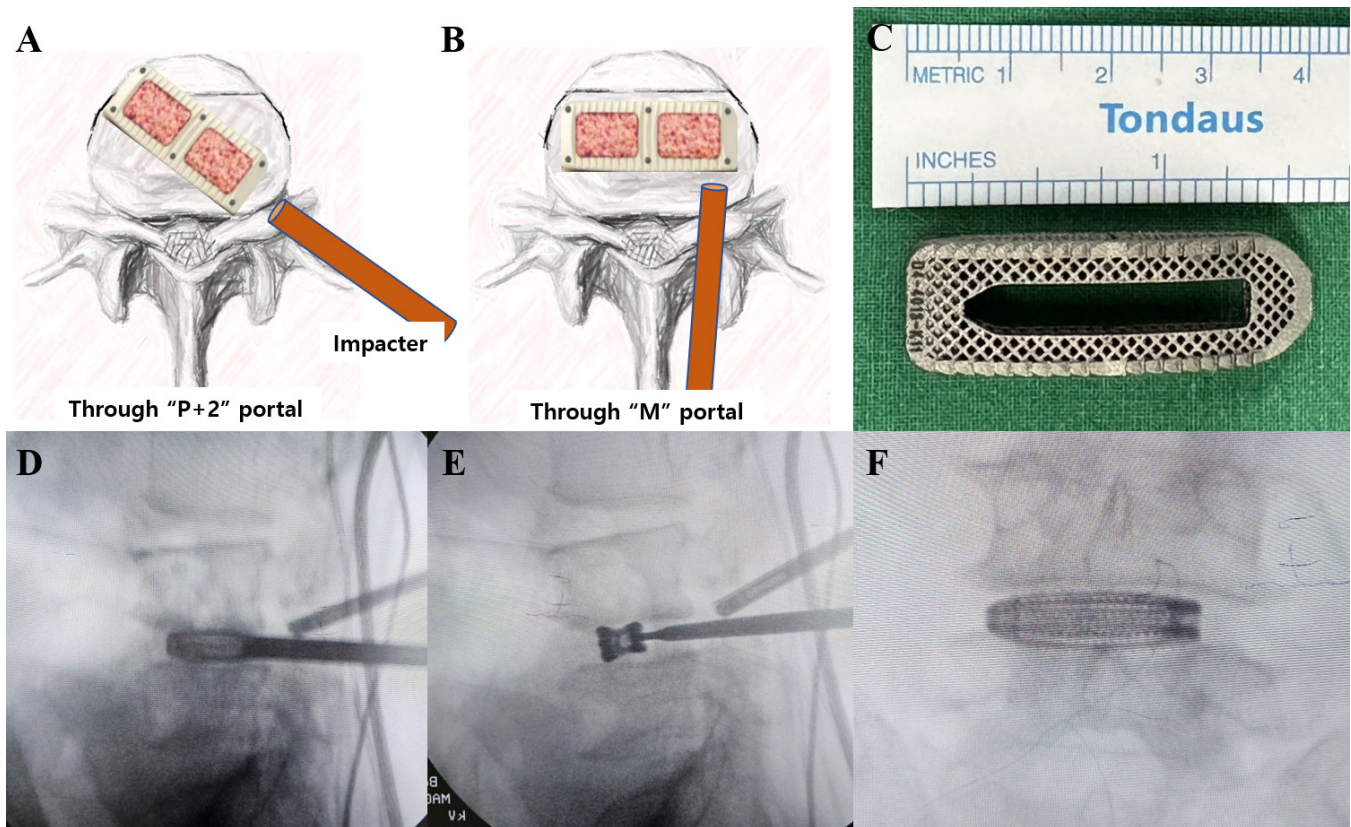


Figure 3. (A) Insertion of the cage through a P + 2 portal. (B) Use of a tamp through an M portal to turn the cage horizontally. Note the position of the cage abutting the apophyseal ring bilaterally. (C) The cage used that is shown in the fluoroscopy images. (D) Intraoperative fluoroscopy image during cage insertion prior to turning the cage. (E) The cage being turned horizontally using a tamp through an M portal. (F) Anteroposterior fluoroscopy image of the cage after insertion.

3D-Printed Porous Cage

The ease with which larger cages can be inserted enables surgeons to take advantage of a recent innovation in cage design that aids fusion. The advent of 3D printing in cage manufacturing deserves special attention. Such technology has enabled increased surface porosity, which has been shown to improve osteointegration and decrease micromotion.^{22–24} Another benefit of the porosity is the decreased Young's modulus that better mimics that of cortical bone.²⁵ Multiple animal studies demonstrated superior osseointegration on micro-computed tomography and histological analysis compared with polyetheretherketone (PEEK) or titanium-coated PEEK cages.^{26,27} A 2024 systematic review and meta-analysis evaluating studies comparing 3D-printed titanium and PEEK for the treatment of lumbar degenerative disease found significantly higher fusion rates and grade 1 fusion rates in the 3D-printed titanium group at 6 months with no significant difference between the 2 groups at 1 year. The subsidence rate at 1 year was significantly higher in the PEEK group.²⁸ The 3D-printed titanium cages have not been used much in MI-TLIF cases due to the large dimensions of the cage. However, utilization of such a cage would be feasible with a biportal endoscopic approach.

Biologics

A recent meta-analysis pooled more than 1500 patients from 40 studies analyzed and compared MI-TLIF fusion rates using different bone grafts. The highest fusion rate of 99.1% was demonstrated with the use of autologous local bone graft, bone extender, and BMP. In cases where BMP was not utilized, the highest

fusion rate was 93.1% with the use of autologous local bone graft and bone extenders.²⁹ This leads to the conclusion that using as much autologous local bone graft as possible, and the use of BMP, would be efficacious in enhancing fusion rates.

A strategy to maximize obtainment of local autograft is the use of osteotomes during ipsilateral and contralateral facetectomies instead of using burrs, which would result in loss of bone dust due to continuous saline irrigation. Osteotomes of varying sizes and angles may be utilized (Figure 4A). The facetectomies should be performed in piecemeal fashion (Figure 4B) because a large bony fragment may not be easily removed through the portal using a pituitary rongeur.

With the use of BMP, there is a concern of ectopic ossification, especially in the setting of continuous saline irrigation at the surgical site. BMP release, based on the carrier, can be classified as a burst or sustained release. The burst release allows for earlier fusion but carries the risk of ectopic ossification and local inflammatory reactions, while the sustained release may require more time for bone formation but reduces ectopic bone growth and inflammatory responses.³⁰ If the carrier with burst release characteristic is used, the carrier can be embedded within other graft materials prior to packing it in the cage window to shield the BMP from saline flow as much as possible. Another strategy is to utilize carriers that accommodate for sustained release of BMP. These include hydroxyapatite³¹ and heparin microparticles³² carriers, and the slow release decreases unwanted ectopic formation of bone and loss of BMP with saline irrigation.

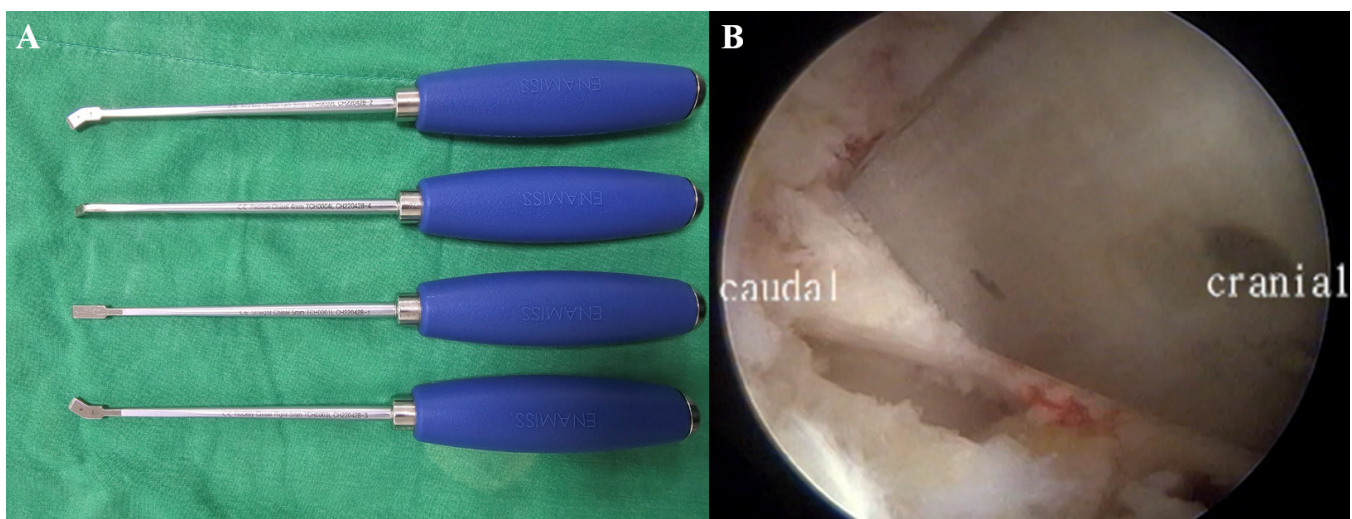


Figure 4. (A) Osteotomes with varying angles used for facetectomy. (B) Intraoperative endoscopic view during facetectomy using an osteotome.

Limitations

While our study offers a comprehensive review of strategies to improve fusion rates in BE-TLIF, these strategies have yet to be validated through extensive clinical trials. Future research, particularly studies with larger sample sizes and multicenter collaborations, will be essential to confirm the efficacy and safety of the proposed techniques.

CONCLUSION

This report aims to aid surgeons in improving fusion rates and shortening the learning curve for BE-TLIFs. The use of additional laterally based portals, in combination with medial portals, permits the secure insertion of larger cages. Direct visualization of the disc space is achievable with the use of a 30° scope. The procedure for contralateral facetectomy using an osteotome is optimal for obtaining autologous bone graft and maintaining segment mobility. Utilizing a larger footprint cage positioned against the apophyseal ring minimizes the risk of subsidence and pseudarthrosis.

REFERENCES

1. Son SK, Kim DH, Aygun H. The basics and concepts of unilateral biportal endoscopy. In: Heo DH, Park CW, Son SK, Eum JH, eds. *Unilateral Biportal Endoscopic Spine Surgery*. Springer; 2022. doi:10.1007/978-981-16-8201-8_2
2. Park J, Ahn DK, Choi DJ. Treatment concept and technical considerations of biportal endoscopic spine surgery for lumbar spinal stenosis. *Asian Spine J*. 2024;18(2):301–323. doi:10.31616/asj.2023.0409
3. Kim SK, Kang SS, Hong YH, Park SW, Lee SC. Clinical comparison of unilateral biportal endoscopic technique versus open microdiscectomy for single-level lumbar discectomy: a multicenter, retrospective analysis. *J Orthop Surg Res*. 2018;13(1). doi:10.1186/s13018-018-0725-1
4. Min WK, Kim JE, Choi DJ, Park EJ, Heo J. Clinical and radiological outcomes between biportal endoscopic decompression and microscopic decompression in lumbar spinal stenosis. *J Orthop Sci*. 2020;25(3):371–378. doi:10.1016/j.jos.2019.05.022
5. Kang MS, You KH, Hwang JY, et al. In vivo comparison of positive microbial culture by wound irrigation methods: biportal endoscopic versus open microscopic transforaminal lumbar interbody fusion. *Spine*. 2024;49(13):941–949. doi:10.1097/BRS.0000000000004812
6. Heo DH, Quillo-Olvera J, Park CK. Can percutaneous biportal endoscopic surgery achieve enough canal decompression for degenerative lumbar stenosis? prospective case-control study. *World Neurosurg*. 2018;120:e684–e689. doi:10.1016/j.wneu.2018.08.144
7. Park MK, Park SA, Son SK, Park WW, Choi SH. Clinical and radiological outcomes of unilateral biportal endoscopic lumbar interbody fusion (ULIF) compared with conventional posterior lumbar interbody fusion (PLIF): 1-year follow-up. *Neurosurg Rev*. 2019;42(3):753–761. doi:10.1007/s10143-019-01114-3
8. Kang MS, You KH, Choi JY, Heo DH, Chung HJ, Park HJ. Minimally invasive transforaminal lumbar interbody fusion using the biportal endoscopic techniques versus microscopic tubular technique. *Spine J*. 2021;21(12):2066–2077. doi:10.1016/j.spinee.2021.06.013
9. Heo DH, Park CK. Clinical results of percutaneous biportal endoscopic lumbar interbody fusion with application of enhanced recovery after surgery. *Neurosurg Focus*. 2019;46(4). doi:10.3171/2019.1.FOCUS18695
10. Payer M. “Minimally invasive” lumbar spine surgery: a critical review. *Acta Neurochir*. 2011;153(7):1455–1459. doi:10.1007/s00701-011-1023-4
11. Jiang L, Liu L, Dong L, Xu Z, Zhang X, Qian L. Comparison of instrumented and stand-alone lateral lumbar interbody fusion for lumbar degenerative disease: a systematic review and meta-analysis. *BMC Musculoskelet Disord*. 2024;25(1). doi:10.1186/s12891-024-07214-6
12. Foley KT, Gupta SK. Percutaneous pedicle screw fixation of the lumbar spine: preliminary clinical results. *J Neurosurg*. 2002;97(1 Suppl):7–12. doi:10.3171/spi.2002.97.1.0007
13. Foley KT, Gupta SK, Justis JR, Sherman MC. Percutaneous pedicle screw fixation of the lumbar spine. *Neurosurg Focus*. 2001;10(4):1–9. doi:10.3171/foc.2001.10.4.11
14. Heo DH, Hong YH, Lee DC, Chung HJ, Park CK. Technique of biportal endoscopic transforaminal lumbar interbody fusion. *Neurospine*. 2020;17(Suppl 1):S129–S137. doi:10.14245/ns.2040178.089
15. You KH, Hwang JY, Hong SH, Kang MS, Park SM, Park HJ. Biportal endoscopic extraforaminal lumbar interbody fusion using a 3D-printed porous titanium cage with large footprints: technical note and preliminary results. *Acta Neurochir*. 2023;165(6):1435–1443. doi:10.1007/s00701-023-05605-7
16. Kang MS, Chung HJ, Jung HJ, Park HJ. How I do it? extraforaminal lumbar interbody fusion assisted with biportal endoscopic technique. *Acta Neurochir*. 2021;163(1):295–299. doi:10.1007/s00701-020-04435-1
17. Rihn JA, Gandhi SD, Sheehan P, et al. Disc space preparation in transforaminal lumbar interbody fusion: a comparison of minimally invasive and open approaches. *Clin Orthop Relat Res*. 2014;472(6):1800–1805. doi:10.1007/s11999-014-3479-z
18. Tatsumi R, Lee YP, Khajavi K, Taylor W, Chen F, Bae H. In vitro comparison of endplate preparation between four mini-open interbody fusion approaches. *Eur Spine J*. 2015;24 Suppl 3:372–377. doi:10.1007/s00586-014-3708-x
19. Alkalay RN, Adamson R, Groff MW. The effect of interbody fusion cage design on the stability of the instrumented spine in response to cyclic loading: an experimental study. *Spine J*. 2018;18(10):1867–1876. doi:10.1016/j.spinee.2018.03.003
20. Salzmänn SN, Shue J, Hughes AP. Lateral lumbar interbody fusion-outcomes and complications. *Curr Rev Musculoskelet Med*. 2017;10(4):539–546. doi:10.1007/s12178-017-9444-1
21. Lener S, Wipplinger C, Hernandez RN, et al. Defining the MIS-TLIF: a systematic review of techniques and technologies used by surgeons worldwide. *Glob Spine J*. 2020;10(2 Suppl):151S–167S. doi:10.1177/2192568219882346
22. Wu S-H, Li Y, Zhang Y-Q, et al. Porous titanium-6 aluminum-4 vanadium cage has better osseointegration and less micromotion than a poly-ether-ether-ketone cage in sheep vertebral fusion. *Artif Organs*. 2013;37(12):E191–E201. doi:10.1111/aor.12153
23. Fujibayashi S, Takemoto M, Neo M, et al. A novel synthetic material for spinal fusion: a prospective clinical trial of porous

bioactive titanium metal for lumbar interbody fusion. *Eur Spine J.* 2011;20(9):1486–1495. doi:10.1007/s00586-011-1728-3

24. Chang SY, Kang DH, Cho SK. Innovative developments in lumbar interbody cage materials and design: a comprehensive narrative review. *Asian Spine J.* 2024;18(3):444–457. doi:10.31616/asj.2023.0407

25. Taniguchi N, Fujibayashi S, Takemoto M, et al. Effect of pore size on bone ingrowth into porous titanium implants fabricated by additive manufacturing: an in vivo experiment. *Mater Sci Eng C Mater Biol Appl.* 2016;59:690–701. doi:10.1016/j.msec.2015.10.069

26. McGilvray KC, Easley J, Seim HB, et al. Bony ingrowth potential of 3D-printed porous titanium alloy: a direct comparison of interbody cage materials in an in vivo ovine lumbar fusion model. *Spine J.* 2018;18(7):1250–1260. doi:10.1016/j.spinee.2018.02.018

27. Laratta JL, Vivace BJ, López-Peña M, et al. 3D-printed titanium cages without bone graft outperform PEEK cages with autograft in an animal model. *Spine J.* 2022;22(6):1016–1027. doi:10.1016/j.spinee.2021.12.004

28. Duan Y, Feng D, Li T, Wang Y, Jiang L, Huang Y. Comparison of lumbar interbody fusion with 3D-printed porous titanium cage versus polyetheretherketone cage in treating lumbar degenerative disease: a systematic review and meta-analysis. *World Neurosurg.* 2024;183:144–156. doi:10.1016/j.wneu.2023.12.111

29. Parajón A, Alimi M, Navarro-Ramírez R, et al. Minimally invasive transforaminal lumbar interbody fusion: meta-analysis of the fusion rates. what is the optimal graft material? *Neurosurgery.* 2017;81(6):958–971. doi:10.1093/neuros/nyx141

30. Tateiwa D, Kaito T. Advances in bone regeneration with growth factors for spinal fusion: a literature review. *N Am Spine Soc J.* 2023;13. doi:10.1016/j.xnsj.2022.100193

31. Xie G, Sun J, Zhong G, Liu C, Wei J. Hydroxyapatite nanoparticles as a controlled-release carrier of BMP-2: absorption and release kinetics in vitro. *J Mater Sci Mater Med.* 2010;21(6):1875–1880. doi:10.1007/s10856-010-4038-0

32. Hettiaratchi MH, Krishnan L, Rouse T, Chou C, McDevitt TC, Guldberg RE. Heparin-mediated delivery of bone morphogenetic protein-2 improves spatial localization of bone regeneration. *Sci Adv.* 2020;6(1). doi:10.1126/sciadv.aay1240

Funding: The authors received no financial support for the research, authorship, and/or publication of this article.

Declaration of Conflicting Interests: The authors report no conflicts of interest in this work.

Corresponding Author: Sang-Min Park, Spine Center and Department of Orthopedic Surgery, Seoul National University College of Medicine and Seoul National University Bundang Hospital, 82, Gumi-ro 173 Beon-gil, Bundang-gu, Seongnam-si, Gyeonggi-do 13620, Republic of Korea; grottyx@gmail.com

Published 27 September 2024

This manuscript is generously published free of charge by ISASS, the International Society for the Advancement of Spine Surgery. Copyright © 2024 ISASS. To see more or order reprints or permissions, see <http://ijssurgery.com>.