

## Selective Direct Vertebral Rotation Instrumentation for the Correction of Adolescent Idiopathic Scoliosis Lenke 5 Curve

Emmanuel Alonge, HongQi Zhang, Chaofeng Guo and Wang Yuxiang

*Int J Spine Surg* 2025, 19 (1) 96-103

doi: <https://doi.org/10.14444/8700>

<https://www.ijssurgery.com/content/19/1/96>

This information is current as of May 4, 2025.

---

**Email Alerts** Receive free email-alerts when new articles cite this article. Sign up at:  
<http://ijssurgery.com/alerts>

# Selective Direct Vertebral Rotation Instrumentation for the Correction of Adolescent Idiopathic Scoliosis Lenke 5 Curve

EMMANUEL ALONGE, MD<sup>1,2</sup>; HONGQI ZHANG, MD<sup>1,2</sup>; CHAOFENG GUO, MD<sup>1,2</sup>; AND WANG YUXIANG, MD<sup>1,2</sup>

<sup>1</sup>Department of Spinal Surgery and Orthopaedics, Xiangya Hospital Central South University, Changsha, Hunan Province, China; <sup>2</sup>National Clinical Research Center for Geriatric Disorders, Xiangya Hospital Central South University, Changsha, China

## ABSTRACTS

**Background:** Direct vertebral rotation (DVR) effectiveness in improving scoliosis correction outcomes remains unclear and requires further investigation.

**Purpose:** This study aimed to evaluate the effectiveness of short and extended fusion techniques using en-bloc DVR in correcting adolescent idiopathic scoliosis (AIS) classified as Lenke 5 curve (5C).

**Materials and Methods:** This retrospective study included 90 randomly selected AIS patients with Lenke 5C who underwent posterior spinal instrumentation surgery using en-bloc DVR between 2014 and 2021. Patients were divided into 2 groups: (1) extended fusion, Group A ( $n = 40$ ): upper instrumented vertebra = upper-end vertebra +1 or +2 or (2) short fusion, Group B ( $n = 50$ ): upper instrumented vertebra = upper-end vertebra. Radiographic parameters were compared preoperatively and at postoperative follow-ups of 6 months, 3 years, and more.

**Results:** The mean follow-up duration was  $37.5 \pm 6$  months for Group A and  $40.0 \pm 8$  months for Group B ( $P = 0.596$ ). The coronal balance correction rate was comparable between the 2 groups, with no significant differences observed at the final follow-up. Significant differences were noted in the fused segment, with Group A having an average fusion rate of  $6.8 \pm 0$  compared with  $6.3 \pm 0$  in Group B ( $P = 0.001$ ). TK and lumbar lordosis measurements at the final follow-up did not show significant differences between the groups. However, substantial differences were observed in rib hump correction, with Group A demonstrating a better correction rate than Group B at both 6 months and the last follow-up ( $P = 0.001$  for both time points).

**Conclusion:** Selective DVR spinal instrumentation effectively corrects AIS Lenke 5C. However, extended fusion demonstrates more efficient correction and greater improvement in the patient's cosmetic appearance, including better thoracic curve correction, rib hump correction, and shoulder balance, compared with short-level fusion.

Other and Special Categories

Keywords: adolescent idiopathic scoliosis, posterior only, direct vertebrae rotation, Enbloc, Lenke 5C

## INTRODUCTION

Surgical correction of adolescent idiopathic scoliosis (AIS) Lenke 5 curve (5C) aims to prevent curve progression, achieve maximum deformity correction, and achieve a balanced spine with adequate sagittal alignment and minimal spine fusion.<sup>1</sup> Direct vertebral rotation (DVR) emerged with the hope of enhancing the correction of deformed spines, overcoming thoracoplasty-related problems in rib hump reduction, optimizing correction in the coronal and sagittal planes, and further helping to minimize fusion level.<sup>2–5</sup> DVR procedures include apex vertebrae derotation (levels of highest rotation and translation due to spinal deformity) and axial spinal deformity correction.

Few studies have reported the use of DVR to correct idiopathic scoliosis, demonstrating substantial improvements in coronal and sagittal balance as well

as deformity correction.<sup>2–5</sup> DVR is typically performed using pedicle screw fusions, either selectively or en-bloc, often sparing the thoracic spine.<sup>2–6</sup> In cases where the apex of the curve is below L2 in AIS Lenke 5C, fusions down to L4 are occasionally required, leaving only 2 mobile discs below the fusion level. Recently, surgeons have aimed to reduce the length of fusion by applying criteria initially described for the anterior approach.<sup>7</sup> Concerns about adjacent segment degeneration drive this approach because of the potential 3-dimensional correction potential of pedicle screws.

On the contrary, some studies have reported that en-bloc DVR does not significantly affect the thoracic rib hump in patients. Additionally, there are concerns regarding an increase in postsurgical thoracic kyphosis (TK) and the progression of compensatory thoracic curves in AIS Lenke 5 C.<sup>4,6</sup> The progression of compensatory thoracic curves has been linked to postoperative

shoulder imbalance.<sup>8</sup> Despite these findings, there is no convincing evidence that DVR enhances clinical outcomes or improves patient self-assessment. Therefore, our objective was to compare the radiographic and clinical outcomes of short vs extended fusion using en-bloc DVR in posterior spinal instrumentation for correcting AIS Lenke 5C.

## MATERIALS AND METHODS

After receiving approval from the Institutional Review Board (No. 21017033559), we conducted a stratified randomized retrospective review of data from our department involving 100 patients diagnosed with AIS Lenke 5C who underwent posterior surgical intervention between 2014 and 2021.

The preoperative plan was to terminate the instrumentation at T10, but the final decision regarding the upper instrumented vertebra (UIV) was made intraoperatively. DVR maneuvers were employed to level the disc above the UIV and reduce the rib hump. Using fluoroscopic guidance, if a parallel shoulder level or a nearly parallel disc above T10 was achieved, the instrumentation was concluded at T10. If this alignment was not attained and there is still an obvious rib hump appearance, the instrumentation was extended to T9 or T8.

The patients were divided into 2 groups based on the instrumentation levels:

- **Group A (extended):** UIV = upper-end vertebra (UEV) +1 or +2.
- **Group B (short):** UIV = UEV.

The selection criteria for inclusion in the study were as follows:

1. Patients with AIS Lenke 5C.
2. Patients who received en-bloc DVR instrumentation with either UIV = UEV + 1 or +2 or UIV = UEV.
3. Patients who had radiographic measurements taken preoperatively during the initial in-clinic evaluation, typically at 6 months postsurgery, and had a minimum follow-up of 3 years. Clinical, surgical, and radiological data were collected.
4. Patients aged between 10 and 18 years.

Patients with different correction forms or those older than 18 years were excluded from the study.

## Clinical Examination

Patients underwent a thorough physical examination before surgery, at the time of discharge, and during subsequent checkups. This examination included assessing their balance in the coronal and sagittal planes and measuring their thoracic rib hump using the Adam test with a scoliometer. Generally, a rotation of greater than 40° indicates scoliosis. Pre- and postoperative measurements of the thoracic rib hump were recorded and analyzed.

## Surgical Procedure

All included patients received all screw/en-bloc posterior pedicle screw instrumentation. After the pedicle screw fixation, all patients underwent posterior apical release and Ponte osteotomy (preceding corrective maneuvers, rod contouring by 90° of the concave side, and mild under contouring of the convex side). All patients underwent DVR using the Smartlink Medtronic Vertebral Manipulator Device. After performing a 90° rod derotation to correct the curve, the Smartlink device was installed over the level above and below the apex screws.

All screws were employed to achieve an effective axial correction/derotation. After the Smartlink Device build was put together, forceful derotation was carried out en-bloc using 3 layers joined by a single stiff construct to provide uniform derotation force to the entire apex. In the process of derotation, intraoperative monitoring of the spinal cord (motor evoked potential, somatosensory evoked potential, and lumbar nerve root electromyography with pedicle screw stimulation) was performed.

## Radiographic Measurement and Clinical Assessment

The patient's preoperative, 6-month postoperative, 2-year postoperative, and later radiographs were obtained according to the institutional regulation approval, and the patient's consent report was taken before data collection. Following the recommendations of the Spinal Deformity Group, radiographic measures were taken. Measurements were conducted using the Surgimap software by an experienced spinal surgeon. These measurements comprised the correction rate, coronal and sagittal balances, TK (T5–12), lumbar lordosis (L1–S1), and the Cobb angles of the lumbar and thoracic curves. The coronal balance was calculated as the absolute displacement value between the C7 plumb line and the center sacral vertical line on the AP

radiograph. The sagittal balance was calculated by the absolute displacement value from the C7 plumb line to the posterior superior corner of the sacrum on the lateral radiograph. Radiographic shoulder height (RSH) was used to assess shoulder balance. Furthermore, we evaluated the pelvic oblique angle (the angle between the horizontal and line tangent to the 2 iliac crests was used to calculate the pelvic oblique (pelvic coronal obliquity angle value  $\geq 3^\circ$ ). Furthermore, the postsurgical radiography complications such as “adding-on” (defined as distalization of the end vertebra with a more than  $5^\circ$  rise in Cobb angle or greater than  $5^\circ$  increase in disc angulation below the lowest instrumented vertebrae and proximal junctional angle (PJA  $> 10$  and at least 10 larger than the comparable preoperative measurement were used to define proximal junctional kyphosis) were assessed.

### SRS-22 Questionnaire

At the last follow-up, the SRS-22 questionnaire was assessed as a clinical outcome.

### Statistical Analysis

The Student's *t* and Mann-Whitney *U* tests were used to determine the statistical significance of differences in the analyzed groups. In noncompliance homogeneity of variance and normal distribution ( $P < 0.05$ ), the *t* test could not be used, so the Mann-Whitney *U* test was chosen instead. The relationship between the 2 attributes was ascertained using the correlation coefficient. A *P* value of 0.05 or lower indicated statistical significance.

## RESULTS

A total of 90 patients with AIS classified as Lenke 5C met the inclusion criteria from an initial pool of 100 patients. Group A consisted of 40 patients with a mean age of 15.2 years (range, 11–18 years). Group B included 50 patients with a mean age of 14.6 years (range, 10–18 years).

Groups A and B had mean follow-up durations of  $37.5 \pm 6$  months and  $40.0 \pm 8$  months, respectively. The average Risser sign for both groups was identical, with Group A at  $3.2 \pm 0$  and Group B also at  $3.2 \pm 0$ . In terms of fused segments, there was a statistically significant difference between the groups. Group A averaged  $6.8 \pm 0$  fused segments, while Group B averaged  $6.3 \pm 0$  fused segments. The levels of Ponte osteotomy in each group were not statistically significant. Group B had an average osteotomy level of  $3.2 \pm 0$  segments, whereas

**Table 1.** Patient characteristics and surgical demographics.

Variable	Group A (n = 40)	Group B (n = 50)	P
Age, y	15.2 $\pm$ 1	14.6 $\pm$ 2	0.200
Sex, n, M/F	6/34	7/43	
Risser ( $^\circ$ )	3.2 $\pm$ 0	3.2 $\pm$ 0	0.965
Ponte	3.1 $\pm$ 0	3.2 $\pm$ 0	0.825
Follow-up, mo	37.5 $\pm$ 6	40.0 $\pm$ 8	0.596
Blood loss, mL	476 $\pm$ 76	448 $\pm$ 65	0.063
Surgical time, min	284.5 $\pm$ 65	279.4 $\pm$ 49	0.647
Fused segment	6.8 $\pm$ 0	6.3 $\pm$ 0	0.001

Note: Data presented as mean  $\pm$  SD unless otherwise specified.

Group A had an average osteotomy level of  $3.1 \pm 0$  segments.

Regarding clinical results, the mean operational duration of Group A was  $284.5 \pm 65$  minutes, while Group B averaged  $279.4 \pm 49$  minutes. The mean intraoperative blood loss in Group A was  $474 \pm 76$  mL and in Group B was  $441 \pm 65$  mL (Table 1).

### Radiography Data

The average preoperative Cobb angles for the thoracolumbar/lumbar (TL/L) curves in each group were as follows: Group A had an average of  $52.1^\circ \pm 30^\circ$ , while Group B averaged  $52.8^\circ \pm 30^\circ$ . Conversely, the preoperative compensatory thoracic curves in both groups were not statistically significant, with Group A averaging  $18.6^\circ \pm 40^\circ$  and Group B averaging  $18.6^\circ \pm 60^\circ$ . Six months after surgery, the Cobb angles for the thoracic and TL/L curves were corrected to  $4.8^\circ \pm 30^\circ$  and  $3.6^\circ \pm 20^\circ$  in Group A, while Group B showed corrections to  $6.7^\circ \pm 50^\circ$  and  $4.6^\circ \pm 40^\circ$ , respectively.

The 6-month postsurgical correction rates were not statistically significant in either group. As shown in Table 2, Group A maintained a better correction rate at the last follow-up than Group B for both thoracic and TL/L Cobb angles. Notably, while the correction rate for the TL/L curve was not statistically significant, the correction for the thoracic curve was significant. The preoperative sagittal vertical axis measurements for both groups were  $20.9 \pm 20$  mm for Group A and  $17.6 \pm 18$  mm for Group B. Six months postsurgery, Group A had an average sagittal vertical axis of  $21.4 \pm 19$  mm. In comparison, Group B had an average of  $17.0 \pm 13$  mm. Despite these changes, there was no significant difference in the number of follow-up visits required after surgery. However, at the 6-month follow-up, sagittal balance had significantly improved in both groups and remained relatively stable during the subsequent postoperative follow-up period.

The preoperative average coronal alignment in both groups was statistically insignificant. However, 6 months after surgery, both groups demonstrated



**Table 2.** Comparison of radiography parameters by group.

Variable	Group A	Group B	P
TK (°)			
Preoperative	23.1 ± 10	22.1 ± 10	0.653
6-mo postoperative	24.1 ± 9	27.1 ± 12	0.212
Last follow-up	29.3 ± 11	30.1 ± 11	0.871
LL (°)			
Preoperative	52.0 ± 11	50.6 ± 12	0.569
6-mo postoperative	50.8 ± 10	54.1 ± 9	0.123
Last follow-up	51.8 ± 10	55.3 ± 8	0.081
Coronal alignment, mm			
Preoperative	17.9 ± 15	14.8 ± 14	0.319
6-mo postoperative	11.4 ± 11	9.7 ± 9	0.443
Last follow-up	13.6 ± 9	10.7 ± 8	0.208
SVA, mm			
Preoperative	20.9 ± 20	17.6 ± 18	0.404
6-mo postoperative	21.4 ± 19	17.0 ± 13	0.223
Last follow-up	23.8 ± 18	20.4 ± 15	0.340
Thoracic curve (°)			
Preoperative	18.6 ± 4	18.6 ± 6	0.964
6-mo postoperative	4.8 ± 3	6.7 ± 5	0.045
Last follow-up	5.3 ± 3	7.3 ± 4	0.022
Major curve (°)			
Preoperative	52.1 ± 3	52.8 ± 3	0.361
6-mo postoperative	3.6 ± 2	4.6 ± 4	0.060
Last follow-up	4.9 ± 3	5.7 ± 4	0.435
RSH, mm			
Pre	1.7 ± 1	1.7 ± 1	0.835
6-mo postoperative	1.2 ± 0	1.6 ± 1	0.089
Last follow-up	1.3 ± 0	2.5 ± 1	0.028
Pelvic obliquity, mm			
Preoperative	1.9 ± 1	2.2 ± 1	0.306
6-mo postoperative	2.0 ± 1	2.0 ± 1	0.930
Last follow-up	2.0 ± 1	2.0 ± 1	0.973
Curve flexibility (°)			
Thoracic	21.4 ± 1	20.9 ± 1	0.133
Lumbar	56.7 ± 3	57.5 ± 3	0.278
Adding on (°)			
Preoperative	2.9 ± 2	2.9 ± 2	0.628
Post 6 mo	1.3 ± 1	1.1 ± 0	0.909
Last follow-up	1.3 ± 0	1.1 ± 0	0.582
PJA (°)			
Preoperative	4.8 ± 4	3.7 ± 3	0.353
6-mo postoperative	7.4 ± 6	4.4 ± 3	0.062
Last follow-up	8.6 ± 6	6.2 ± 5	0.010
Rib hump (°)			
Preoperative	9.7 ± 0	9.6 ± 0	0.511
6-mo postoperative	3.7 ± 0	4.1 ± 0	0.001
Last follow-up	3.9 ± 0	4.4 ± 0	0.000

Abbreviations: LL, lumbar lordosis; PJA, proximal junctional angle; RSH, radiographic shoulder height; SVA, sagittal vertical axis; TK, thoracic kyphosis.

significant improvements. At the 6-month postoperative follow-up, Group A had a coronal balance outcome of  $11.4 \pm 11$ , while Group B averaged  $9.7 \pm 9$ . In subsequent follow-up visits, as shown in Table 2, both groups exhibited statistically insignificant differences in maintaining good coronal balance. When comparing radiographic parameters such as lumbar lordosis (LL) and TK, there were no statistically significant differences preoperatively in either group. However, these parameters are essential for determining the success of AIS Lenke 5C correction. Six months postsurgery, LL showed significant improvement in both groups, with Group A averaging  $50.8 \pm 10$  and Group B averaging

$54.1 \pm 9$ . In the final follow-up, Group B demonstrated a slight increase in LL, averaging  $55.3 \pm 8$  compared with Group A's average of  $51.8 \pm 10$ . Nonetheless, the differences between the groups were not statistically significant ( $P = 0.081$ ). Regarding TK, the preoperative averages were also insignificant: Group A had an average of  $23.1 \pm 10$ , while Group B averaged  $22.1 \pm 10$ . There were no statistically significant differences between the groups at the 6-month follow-up. However, both groups showed improvements and well-maintained TK angles at the last check-up, with no substantial differences observed ( $P = 0.871$ ).

Both groups showed no significant changes in preoperative RSH and pelvic obliquity. However, at the 6-month postoperative follow-up, Group A exhibited superior shoulder balance compared with Group B, with statistically significant differences. Specifically, at the last postoperative visit, Group A maintained a better shoulder balance than Group B, with an average of  $1.3 \pm 0$  mm for Group A and  $2.5 \pm 1$  mm for Group B ( $P = 0.028$ ). In contrast, both groups demonstrated no significant changes in pelvic obliquity during the preoperative assessments and subsequent postoperative visits. A Pearson correlation test was conducted to explore the relationship between pelvic obliquity and RSH; however, no correlation was established.

Preoperatively, the rates of postoperative radiological complications, including adding-on and PJA, were not statistically significant in either group. However, at the 6-month postoperative follow-up, changes in these parameters were observed. Group A exhibited a higher average PJA of  $7.4 \pm 6$  compared with Group B's average of  $4.4 \pm 3$ , although this difference did not reach statistical significance ( $P = 0.062$ ). In contrast, significant differences between the groups were observed at the last follow-up visit. The rates of adding-on at the preoperative, 6 months, and last follow-up assessments remained statistically insignificant in both groups.

The average thoracic rib hump preoperatively was  $9.7 \pm 0.0$  in Group A and  $9.6 \pm 0.0$  in Group B ( $P = 0.511$ ; Table 2). At the 6-month follow-up, Group A demonstrated superior correction of the thoracic rib hump, with an average of  $3.7 \pm 0.0$  compared with Group B's  $4.1 \pm 0.0$  ( $P = 0.001$ ). This statistically significant difference was maintained at the last follow-up, with Group A continuing to show better correction of the thoracic rib hump than Group B ( $P = 0.001$ ).

### Clinical Outcomes

The SRS-22 questionnaire results from the last follow-up visit indicated statistically significant

**Table 3.** SRS-22 questionnaire outcomes before and after surgery.

SRS-22 Questionnaire Component	Preoperative			Last Follow-Up		
	Group A	Group B	<i>P</i>	Group A	Group B	<i>P</i>
Function	4.3 ± 0.3	4.4 ± 0.2	0.074	4.2 ± 0.2	4.1 ± 0.2	0.082
Pain	4.6 ± 0.2	4.5 ± 0.3	0.617	4.4 ± 0.2	4.3 ± 0.4	0.325
Self-image	3.8 ± 0.3	2.8 ± 0.5	0.060	4.3 ± 0.2	4.3 ± 0.2	0.868
Mental health	3.8 ± 0.2	3.8 ± 0.3	0.692	4.3 ± 0.3	4.0 ± 0.2	0.006
Satisfaction	3.1 ± 0.2	3.1 ± 0.2	0.728	4.5 ± 0.1	4.1 ± 0.3	0.001

Abbreviation: SRS, Scoliosis Research Society.

differences in mental health and satisfaction between the 2 groups, with Group A showing better outcomes, as illustrated in Table 3. Throughout the surgical procedure and the postoperative period, no serious complications were recorded. This includes, but is not limited to, deep wound infections, loss of intraoperative monitoring, paralysis, pseudarthrosis, or the need for revision procedures.

## DISCUSSION

AIS Lenke 5C correction aims to address spinal curves while ensuring patient stability, preventing further deterioration, preserving function, and enhancing appearance. Recent discussions have centered around the optimal instrumentation level for correcting this deformity, with ongoing controversies regarding postsurgical shoulder imbalance, lower instrumentation levels, rib hump, and progression of the nonstructural thoracic curve.<sup>5,9–11</sup> Despite the debates, several authors have advocated for short-level instrumentation to preserve lumbar segments for better mobility and flexibility. However, the aesthetic and postural implications of rib hump and compensatory thoracic curves remain critical considerations in the treatment of AIS Lenke 5C.<sup>3,9,12,13</sup>

Patient satisfaction after correction is closely linked to the reduction of rib prominence.<sup>2,14,15</sup> Both thoracolumbar curvature and thoracic rib hump can negatively impact aesthetics, leading to increased self-consciousness, especially in cases of waist asymmetry. Shoulder imbalance is another critical factor influencing the treatment of AIS patients.<sup>14</sup> It is commonly observed in adult scoliosis<sup>14,16–18</sup> and has gained attention in the context of postoperative correction of AIS.<sup>16</sup>

DVR has emerged as a popular adjunct to surgical treatment for AIS due to its advantages in apical derotation, axial correction, segment preservation, and overall curve correction compared with other techniques.<sup>3–6</sup> However, questions regarding its function, safety, and effectiveness remain. This study primarily focuses on the use of en-bloc DVR to correct AIS Lenke 5C. Our

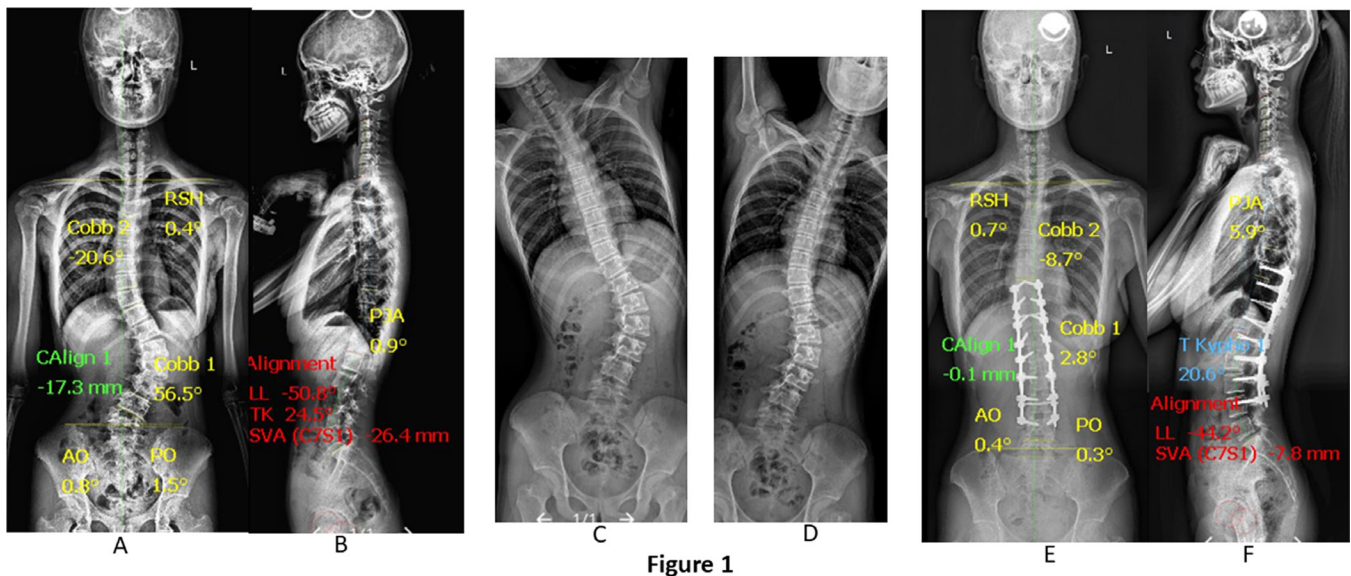
objective is to evaluate the impact of this technique's short and extended-level instrumentations on various factors, including UIV level, rib hump, shoulder imbalance, radiographic outcomes, and clinical efficiency.

En-bloc DVR employs all pedicle screw fixation to achieve better derotation and enhanced correction stability. Surgical times were comparable between groups, as the same surgeon performed all procedures. Furthermore, the correction rates were also similar in both groups.

Patients with AIS Lenke 5C often face challenges with the postoperative progression of compensatory thoracic curves, which is a leading factor contributing to shoulder imbalance.<sup>2,17</sup> Our outpatient records indicate that many patients report this issue. While previous studies have suggested that uninstrumented compensatory thoracic curves can adapt to the instrumented major curve after posterior selective TL/L fusion, a recent study reported a loss of compensatory thoracic curve over long-term follow-up.<sup>19</sup> In contrast to earlier reports, our study with en-bloc DVR showed superior corrections of compensatory thoracic curves at both 6 months and final follow-ups in Group A compared with Group B, which were attributed to the extended UIV level in Group A. However, Group A thoracic curve correction was maintained compared with Group B, and there were better thoracic curve angles of 5.3° compared with earlier reported cases of 13.4° with short fusion DVR.<sup>8</sup>

Throughout the required 3-year follow-up, both groups maintained a coronal and sagittal balance. By reducing the rib hump and correcting the compensatory thoracic curvature, we hope to achieve improved body postures and coronal and sagittal equilibrium. Both groups had significant improvement in both coronal and sagittal balance.

Previous studies with the use of short fusion DVR stressed that overcorrection is more likely to create coronal imbalance after distal fusion extension, as was found in studies by Ohrt-Nissen et al<sup>20</sup> and Ogura et al.<sup>21</sup> They examined the effect of the lowest instrumented

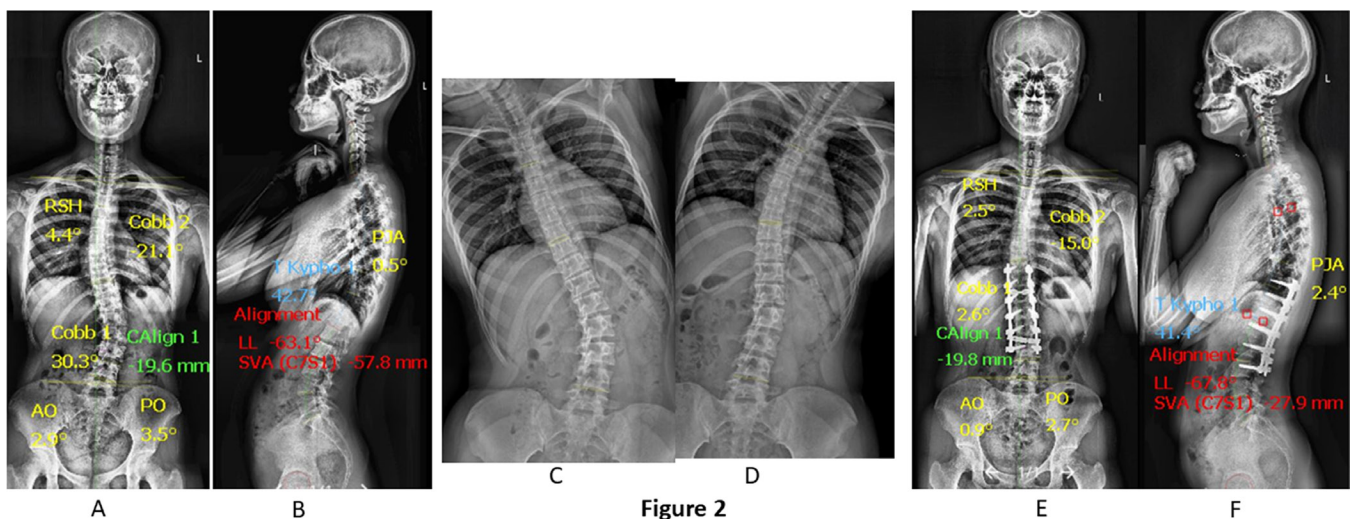


**Figure 1.** A 15-year-old girl with adolescent idiopathic scoliosis Lenke 5 curve. (A and B) Preoperative posteroanterior and lateral standing radiograph. (C and D) Preoperative bending radiography. (E and F) Three-year postoperative posteroanterior and lateral radiograph. The patient was treated with posterior en-bloc direct vertebral rotation (DVR) with upper instrumented vertebra (UIV) = upper-end vertebra (UEV) + 1.

vertebrae on a Lenke 5C curve and mid-term surgical outcomes for a short fusion strategy for AIS Lenke 5C. In contrast to their reports, our study group with a higher fusion level recorded a well-maintained coronal balance at the final follow-up visitation, as shown in Figure 1 compared with Figure 2.

The cosmetic appearance of patients has been emphasized as one of the factors that surgeons need to consider prior to spinal deformity correction.<sup>22</sup> The rib hump in patients with AIS is a significant factor influencing postoperative appearance. Axial vertebral correction and its role in rib hump reduction remain contentious

topics. Many researchers argue that rib hump deformity primarily arises from asymmetric rib growth rather than vertebral rotation.<sup>5,23</sup> Although apical thoracic rotation measurements correlate with axial vertebral rotation, this correlation has its limits. Even after significant vertebral derotation, a residual rib hump can persist due to the fixed nature of rib deformities and the potential for continued asymmetric rib growth in patients with remaining growth potential, which may lead to a relapse of thoracic deformity. Clinical studies have generally not found any significant benefits of DVR on rib hump reduction compared with techniques that do not



**Figure 2.** A 16-year-old girl with adolescent idiopathic scoliosis Lenke 5 curve. (A and B) Preoperative posteroanterior and lateral standing radiograph. (C and D) Preoperative bending radiography. (E and F) Three years postoperative posteroanterior and lateral radiograph. She was treated with posterior en-bloc direct vertebral rotation (DVR) with upper instrumented vertebra (UIV) = upper-end vertebra (UEV).



involve derotation. Additionally, obtaining reliable and repeatable apical thoracic rotation measurements can be challenging, leading researchers to view these measurements as supplementary outcome indicators. A previous study using short fusion en-bloc DVR compared with non-DVR stated the immediate impact of DVR leveling of the rib hump; conversely, they noted no differences between the 2 techniques at the final follow-up.<sup>4</sup> Contrary to the previous study, there were improvements in Group A in our study compared with group B at 6 months and last follow-up visitation in rib hump changes, with statistical significances in both groups on 2 different follow-ups.

Shoulder balance in patients with Lenke 5C is not well understood, with disparities in shoulder height reported in various studies.<sup>17,24</sup> Our evaluation of shoulder balance levels revealed that Group A had better outcomes than Group B. Previous studies have indicated that loss of thoracic curve correction can lead to shoulder imbalance; however, our findings show improved results compared with earlier reports.<sup>25,26</sup>

Higher instrumentation levels have been identified as a potential cause of postjunctional kyphosis.<sup>27</sup> In our study, Group B exhibited lower PJA than Group A, yet neither group reported any postjunctional kyphosis, likely due to the intraoperative preservation of the T8 to T10 spinal process and also the use of postoperative spine braces for at least 6 months. It could further help to limit proximal junctional kyphosis.

The clinical outcomes measured by the SRS-22 questionnaire indicated significant differences in mental health and satisfaction between the 2 groups, highlighting the importance of body image for patients after surgery, with Group A achieving better results. One limitation of this study is its retrospective nature. Nonetheless, it represents the first comprehensive investigation of a large population utilizing short and extended-fusion en-bloc DVR to correct AIS Lenke 5C.

## CONCLUSION

The extension of the upper instrumented vertebrae in Group A significantly enhances the correction of the compensatory thoracic curve and rib hump leveling. This approach also promotes better posture by improving shoulder balance in patients with AIS Lenke 5C when compared with the short instrumentation in Group B. Additionally, coronal and sagittal balance significantly improved at the last follow-up visit.

## REFERENCES

1. Geck MJ, Rinella A, Hawthorne D, et al. Comparison of surgical treatment in Lenke 5C adolescent idiopathic scoliosis: anterior dual rod versus posterior pedicle fixation surgery. *Spine (Phila Pa 1986)*. 2009;34(18):1942–1951. doi:10.1097/BRS.0b013e3181a3c777
2. Oba H, Takahashi J, Kobayashi S, et al. Upper instrumented vertebra to the right of the lowest instrumented vertebra as a predictor of an increase in the main thoracic curve after selective posterior fusion for the thoracolumbar/lumbar curve in Lenke type 5C adolescent idiopathic scoliosis: multicenter study on the relationship between fusion area and surgical outcome. *J Neurosurg Spine*. 2019;31(6):857–864. doi:10.3171/2019.5.SPINE181469
3. Urbanski W, Wolanczyk MJ, Jurasz W, et al. The impact of direct vertebral rotation (DVR) on radiographic outcome in surgical correction of idiopathic scoliosis. *Arch Orthop Trauma Surg*. 2017;137(7):879–885. doi:10.1007/s00402-017-2700-4
4. Mattila M, Jalanko T, Helenius I. *En Bloc*. 2013;38(18):1576–1583. doi:10.1097/BRS.0b013e31829a6d37
5. Seki S, Kawaguchi Y, Nakano M, Makino H, Mine H, Kimura T. Rod rotation and differential rod contouring followed by direct vertebral rotation for treatment of adolescent idiopathic scoliosis: effect on thoracic and thoracolumbar or lumbar curves assessed with intraoperative computed tomography. *Spine J*. 2016;16(3):365–371. doi:10.1016/j.spinee.2015.11.032
6. Hwang SW, Dubaz OM, Ames R, Rothkrug A, Kimball JS, Samdani AF. The impact of direct vertebral body derotation on the lumbar prominence in Lenke type 5C curves. *SPI*. 2012;17(4):308–313. doi:10.3171/2012.7.SPINE12273
7. Wang Z, Shen Y, Wu Y, et al. Anterior selective lumbar fusion saving more distal fusion segments compared with posterior approach in the treatment of adolescent idiopathic scoliosis with Lenke type 5: a cohort study with more than 8 -year follow-up. *Orthop Surg*. 2021;13(8):2327–2334. doi:10.1111/os.13117
8. Li J, Zhao Z, Tseng C, Zhu Z, Qiu Y, Liu Z. Selective fusion in Lenke 5 adolescent idiopathic scoliosis. *World Neurosurg*. 2018;118:e784–e791. doi:10.1016/j.wneu.2018.07.052
9. Nambiar M, Yang Y, Liew S, Turner PL, Torode IP. Single-versus dual-rod anterior instrumentation of thoracolumbar curves in adolescent idiopathic scoliosis. *Eur Spine J*. 2016;25(10):3249–3255. doi:10.1007/s00586-015-4360-9
10. Okubo T, Yagi M, Suzuki S, et al. Does selective posterior correction and fusion surgery influence cervical sagittal alignment in patient with Lenke type 5 adolescent idiopathic scoliosis?—A 5-year follow-up retrospective cohort study. *Spine (Phila Pa 1986)*. 2021;46(18):E976–E984. doi:10.1097/BRS.0000000000003967
11. Lee CS, Hwang CJ, Lee DH, Cho JH. Does fusion to T2 compared with T3/T4 lead to improved shoulder balance in adolescent idiopathic scoliosis with a double thoracic curve? *J Pediatr Orthop B*. 2019;28(1):32–39. doi:10.1097/BPB.0000000000000520
12. Sanders AE, Baumann R, Brown H, Johnston CE, Lenke LG, Sink E. Selective anterior fusion of thoracolumbar/lumbar curves in adolescents: when can the associated thoracic curve be left unfused? *Spine (Phila Pa 1976)*. 2003;28(7):706–713. doi:10.1097/01.BRS.0000051925.88443.85
13. Okada E, Watanabe K, Pang L, et al. Posterior correction and fusion surgery using pedicle-screw constructs for Lenke type 5c adolescent idiopathic scoliosis. *Spine (Phila Pa 1986)*. 2015;40(1):25–30. doi:10.1097/BRS.0000000000000652



14. do Rosário JLP. Photographic analysis of human posture: a literature review. *J Bodyw Mov Ther.* 2014;18(1):56–61. doi:10.1016/j.jbmt.2013.05.008
15. Banno T, Yamato Y, Hasegawa T, et al. Impact of pelvic obliquity on coronal alignment in patients with adolescent idiopathic scoliosis. *Spine Deform.* 2020;8(6):1269–1278. doi:10.1007/s43390-020-00145-x
16. Alluri RK, Sheikh B, Elysee JC, et al. Shoulder balance in adult spinal deformity patients undergoing selective lumbar fusion. *Spine (Phila Pa 1986).* 2022;47(9):E385–E389. doi:10.1097/BRS.0000000000004255
17. Kuklo TR, Lenke LG, Graham EJ, et al. Clinical, and patient assessment of shoulder balance following fusion versus nonfusion of the proximal thoracic curve. *Adolescent Idiopathic Scoliosis.* 2020;27(18):2013–2020. doi:10.1097/01.BRS.0000024162.02138.F9
18. Yang JH, Suh SW, Chang DG. Rib regeneration morphology after thoracoplasty in adolescent idiopathic scoliosis. *Spine (Phila Pa 1986).* 2020;45(3):177–183. doi:10.1097/BRS.0000000000003219
19. Chen K, Chen Y, Shao J, et al. Long-term follow-up of posterior selective thoracolumbar/lumbar fusion in patients with Lenke 5C adolescent idiopathic scoliosis: an analysis of 10-year outcomes. *Global Spine J.* 2022;12(5):840–850. doi:10.1177/2192568220965566
20. Ohrt-Nissen S, Cheung PWH, Kawasaki S, Shigematsu H, Cheung JPY. Curve overcorrection predicts coronal imbalance in selective thoracic fusion in adolescent idiopathic scoliosis. *Global Spine J.* 2024;14(3):856–861. doi:10.1177/21925682221124526
21. Ogura Y, Okada E, Fujii T, et al. Midterm surgical outcomes of a short fusion strategy for adolescent idiopathic scoliosis with Lenke 5C curve. *Spine J.* 2020;20(3):361–368. doi:10.1016/j.spinee.2019.09.010
22. Qiu Y, Qiu X, Ma W, et al. How well does radiological measurements correlate with cosmetic indices in adolescent idiopathic scoliosis with Lenke 5, 6 curve types? *Spine (Phila Pa 1986).* 2010;35(18):E882–E888. doi:10.1097/BRS.0b013e3181d6fdd7
23. Urbanski W, Markowski P, Zaluski R, Kokaveshi A, Morawiec P. Direct vertebral rotation (DVR) does not improve clinical and radiological results compared to differential rod contouring (DRC) in patients treated surgically for idiopathic scoliosis. *J Clin Med.* 2023;12(12):4091. doi:10.3390/jcm12124091
24. Liu Z, Hu Z-S, Qiu Y, et al. Role of clavicle chest cage angle difference in predicting postoperative shoulder balance in Lenke 5C adolescent idiopathic scoliosis patients after selective posterior fusion. *Orthop Surg.* 2017;9(1):86–90. doi:10.1111/os.12305
25. Hong J-Y, Suh S-W, Modi HN, Yang J-H, Park S-Y. Analysis of factors that affect shoulder balance after correction surgery in scoliosis: a global analysis of all the curvature types. *Eur Spine J.* 2013;22(6):1273–1285. doi:10.1007/s00586-013-2697-5
26. Yaszay B, Bastrom TP, Newton PO, Harms Study Group. Should shoulder balance determine proximal fusion levels in patients with Lenke 5 curves? *Spine Deform.* 2013;1(6):447–451. doi:10.1016/j.jsdpd.2013.08.003
27. Zhou Q, Hu B, Yang X, et al. Proximal junctional kyphosis in Lenke 5 AIS patients: the important factor of pelvic incidence. *BMC Musculoskelet Disord.* 2021;22(1):185. doi:10.1186/s12891-021-04052-8

**Funding:** The authors received no financial support for the research, authorship, and/or publication of this article.

**Declaration of Conflicting Interests:** The authors have no conflicts of interest to declare.

**Disclosures:** The authors have no disclosures.

**Author Contributions:** E.A. was responsible for the concept and design of the overall study. Data were retrieved and assembled by E.A. and Z.H.Q. All authors contributed to the writing and final approval of the manuscript.

**Ethical Statement:** The ethical committee for Xiangya Hospital Central South University approved the study, and informed consent was obtained from all patients and/or legal guardian(s). All methods were performed per our hospital's relevant guidelines and regulations.

**Corresponding Author:** HongQi Zhang, Department of Spinal Surgery and Orthopaedics, Xiangya Hospital Central South University, Changsha, Xiangya Road 87, 410008, Hunan Province, China; zhq9996@163.com; Chaofeng Guo; 343942471@qq.com

Published 16 January 2025

Copyright © 2025 ISASS. The IJSS is an open access journal following the Creative Commons Licensing Agreement CC BY-NC-ND. To learn more or order reprints, visit <http://ijssurgery.com>.