INTERNATIONAL JOURNAL of SPINE SURGERY

Navigation-assisted fluoroscopy in minimally invasive direct lateral interbody fusion: a cadaveric study

Jonathan E. Webb, Gilad J. Regev, Steven R. Garfin and Choll W. Kim

Int J Spine Surg 2010, 4 (4) 115-121
doi: https://doi.org/10.1016/j.esas.2010.09.002
http://ijssurgery.com/content/4/4/115

This information is current as of April 19, 2024.

Email Alerts Receive free email-alerts when new articles cite this article. Sign up at:
http://ijssurgery.com/alerts

The International Journal of Spine Surgery
2397 Waterbury Circle, Suite 1,
Aurora, IL 60504, Phone: +1-630-375-1432
© 2010 ISASS. All Rights Reserved.

INTERNATIONAL SOCIETY for the ADVANCEMENT of SPINE SURGERY

Downloaded from http://ijssurgery.com/ by guest on April 19, 2024

Available online at www.sciencedirect.com
ScienceDirect
SAS Journal 4 (2010) 115–121
SAS Journal
www.sasjournal.com

MIS

Navigation-assisted fluoroscopy in minimally invasive direct lateral interbody fusion: a cadaveric study

Jonathan E. Webb, MD [a], Gilad J. Regev, MD [a], Steven R. Garfin, MD [a], Choll W. Kim, MD, PhD [a,b,*]

[a] *University of California, San Diego, San Diego, CA*
[b] *Spine Institute of San Diego at Alvarado Hospital, San Diego, CA*

Abstract

Background: Minimally invasive surgery (MIS) is dependent on intraoperative fluoroscopic imaging for visualization, which significantly increases exposure to radiation. Navigation-assisted fluoroscopy (NAV) can potentially decrease radiation exposure and improve the operating room environment by reducing the need for real-time fluoroscopy. The direct lateral interbody fusion (DLIF) procedure is a technique for MIS intervertebral lumbar and thoracic interbody fusions. This study assesses the use of navigation for the DLIF procedure in comparison to standard fluoroscopy (FLUORO), as well as the accuracy of the NAV MIS DLIF procedure.

Methods: Three fresh whole-body cadavers underwent multiple DLIF procedures at the T10-L5 levels via either NAV or FLUORO. Radiation exposure and surgical times were recorded and compared between groups. An additional cadaver was used to evaluate the accuracy of the NAV system for the DLIF procedure by measuring the deviation error as the surgeon worked further from the anterior superior iliac spine tracker.

Results: Approach, discectomy, and total fluoroscopy times for FLUORO were longer than NAV ($P < .05$). In contrast, the setup time was longer in NAV ($P = .005$). Cage insertion and total operating times were similar for both. Radiation exposure to the surgeon for NAV was significantly less than FLUORO ($P < .05$). Accuracy of the NAV system was within 1 mm for L2-5.

Conclusion: Navigation for the DLIF procedure is feasible. Accuracy for this procedure over the most common levels (L2-5) is likely sufficient for safe clinical application. Although initial setup times were longer with NAV, simultaneous anteroposterior and lateral imaging with the NAV system resulted in overall surgery times similar to FLUORO. Navigation minimizes fluoroscopic radiation exposure.

Clinical significance: Navigation for the DLIF procedure is accurate and decreases radiation exposure without increasing the overall surgical time.

© 2010 SAS - The International Society for the Advancement of Spine Surgery. Published by Elsevier Inc. All rights reserved.

Keywords: Navigation; Direct lateral interbody fusion; Accuracy; Minimally invasive spine surgery

Minimally invasive surgery (MIS) techniques for the spine have been developed with the goal of minimizing soft-tissue trauma associated with spinal surgery.[1] The direct lateral interbody fusion (DLIF) technique is a relatively new MIS technique that uses a lateral, retroperitoneal approach for anterior interbody fusion and deformity correction.[2] However, as with many MIS techniques, the smaller incisions used for the DLIF procedure limit direct visualization of the surgical field, thereby requiring increased dependence on intraoperative fluoroscopic guidance during the procedure.[3] Frequent use of fluoroscopy during the procedure results in increased radiation exposure to the patient and surgical team. Reliance on cumbersome protective gear and frequent repositioning of the C-arm to obtain multiplanar images further interferes with and obstructs the surgical field.[3,4] Because of these issues with the C-arm and radiation exposure, there is renewed interest in the use of navigation-assisted fluoroscopy (NAV) to decrease the use of intraoperative fluoroscopy.[5–8] NAV systems use fixed-reference frame markers on the patient and specialized surgical instruments that are simultaneously captured and tracked by an intraoperative camera attached to a navigation computer. The computer overlays the posi-

Partially funded by the National Institutes of Health Summer Research Training Grant (T35 HL07491).

* Corresponding author: Choll W. Kim, MD, PhD, Spine Institute of San Diego, Center for Minimally Invasive Spine Surgery at Alvarado Hospital, 6719 Alvarado Rd, Ste 308, San Diego, CA 92120; Phone: 619-265-7912; Fax: 619-265-7922.
E-mail address: chollkim@smiss.org

1935-9810 © 2010 SAS - The International Society for the Advancement of Spine Surgery. Published by Elsevier Inc. All rights reserved.
doi:10.1016/j.esas.2010.09.002

Downloaded from http://ijssurgery.com/ by guest on April 19, 2024

tion of the instruments onto a set of fluoroscopic images obtained at the beginning of the procedure. This enables the surgeon to observe real-time instrument location during the procedure.

The use of NAV technology can minimize the use of real-time intraoperative fluoroscopy, thereby decreasing radiation exposure to the surgical team.[7] By use of fluoroscopic images that are taken at the beginning of the surgery, navigation also minimizes the encroachment of the C-arm into the surgical field.

The introduction of any new surgical technique is often accompanied by concerns from surgeons that may limit wide use. A recent survey study conducted by our group suggests that concerns from surgeons about NAV include the increased operative time, cost, lack of necessity, unreliable accuracy, and intraoperative problems.[9] The purpose of this study is to assess the effectiveness and accuracy of NAV when used during the DLIF procedure.

Materials and methods

Study design

Unilateral DLIF procedures (Medtronic Spine, Memphis, Tennessee) were performed on 3 cadaveric specimens. Procedures were done via either intraoperative NAV or standard fluoroscopy (FLUORO) techniques. Just prior to each level of each cadaver, the type of intraoperative guidance to be used was randomly selected and divided into either the NAV group or FLUORO group. The surgeon was notified at the time of randomization whether navigation or fluoroscopy was to be used by a research assistant. After each procedure, final C-arm images were obtained to confirm satisfactory implant position and spinal alignment. An NAV system (StealthStation Treon; Medtronic Navigation, Louisville, Colorado) was used for all NAV procedures (as described later). The StealthStation equipment was set up and run by trained research personnel and Medtronic representatives, exactly as it would be during an actual patient surgery. All DLIF procedures were performed by a single surgeon who had approximately 1 year of experience with NAV with the DLIF technique. Specific operative steps were timed by a separate observer. Each specimen was positioned and draped only once, so recorded setup times do not include these steps. Setup time for both groups started with image library acquisition, including locating the disk center, and ended at the time of the lateral skin incision. For NAV, setup time also included insertion of a patient reference tracker in the anterior superior iliac spine (ASIS), registration of NAV instruments, and manipulation of the C-arm. The NAV patient reference tracker was inserted once into each specimen. Three values were obtained for NAV tracker pin insertion, and the mean time was used to determine the length of all NAV group setup times.

Exposure and approach times were recorded and were defined as beginning with the lateral skin incision and ending with the insertion of the last of the cephalad and caudal endplate dilator bone screws. Discectomy time began with initial annulus incision and ended at initiation of cage insertion. Cage insertion time was recorded from beginning of cage insertion to verification of alignment by fluoroscopy. Total operating time was defined as initial image library obtainment to removal of DLIF retractors. The total fluoroscopy time was determined automatically by the internal timer of the C-arm. Radiation exposure was evaluated by use of radiation-detection badges worn by the surgeon anteriorly and exterior to the lead protective thyroid shield. Separate radiation badges were worn for each single-level DLIF procedure. Control radiation badges were placed both inside and outside of the operating room.

NAV MIS DLIF technique (NAV)

All specimens were thawed and positioned on a radiolucent table in the left lateral decubitus position, with the greater trochanter located at the table's bend. Specimens were fixed to the table with tape, and the table was mechanically bent at the hip to improve access to the lumbar spine by moving the superior iliac spine (Fig. 1). The ASIS was palpated and a 0.5-cm incision made for insertion of the navigation (NAV) tracker pin. A standard OEC 9800 C-arm (GE Healthcare Technologies, Waukesha, Wisconsin) was fitted with a navigation tracker to allow image capture by the StealthStation Treon navigation computer (Medtronic Navigation). The C-arm was used to obtain true anteroposterior (AP) and lateral images of a specific level while the surgeon was distant from the machine. The images were uploaded to the NAV system, and all surgical instruments were registered. Image library acquisition was accomplished for each level in which navigation was used. The C-arm was then removed from the surgical field for the remainder of the procedure. The disk center was used as the surgical target to plan the skin incision (Fig. 2). A 2.5-cm longitudinal incision was made through the skin at each level in which the DLIF procedure was accomplished, with subsequent blunt dissection by use of Mayo scissors through the lateral abdominal wall. The retroperitoneal space was entered by finger dissection. The lateral aspect of the transverse process was palpated and the psoas muscle gently cleared of intervening tissue. A navigated initial dilator was then inserted through the psoas muscle to the disk center. A long guidewire was passed through the cannulated portion of the navigated dilator and was inserted approximately 2 cm into the disk.

The approach to the T10-L1 levels was intrathoracic. Imaging was used in an analogous fashion to identify the optimum skin incision site. Dissection was carried down through the intercostal space and the lung parenchyma displaced by finger dissection followed by insertion of the dilators. Similar to the technique at the caudal levels, the dilators were passed along the posterior chest wall (in the lumbar spine, the posterior abdominal wall) and thereafter centered on the target disk space. This allowed the dilator to pass along the diaphragmatic sulcus and displace the dia-

Downloaded from http://ijssurgery.com/ by guest on April 19, 2024

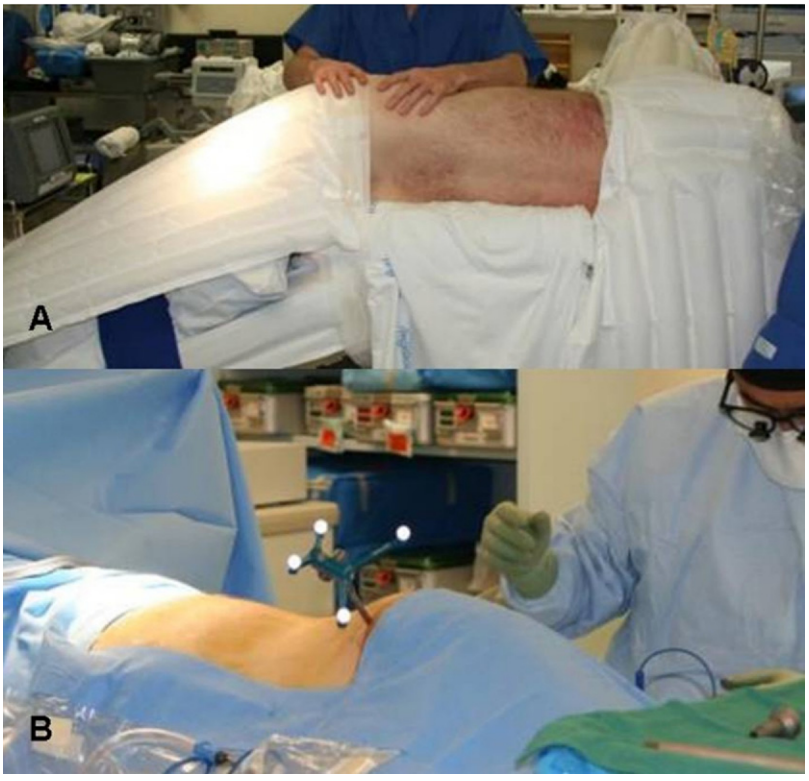

Fig. 1. NAV DLIF setup. Specimens were oriented in the left lateral decubitus position with the surgical table bent to provide great access to the lumbar spine (A). A navigation tracker pin is placed in the anterior superior iliac spine for optical navigation by the StealthStation Treon (B).

phragm anteriorly. At T12-L1, the crus of the diaphragm covers the disk space. Once the retractor was positioned, the retractor blade bone pin was inserted into T12. Electrocautery was used to incise the crus, which was then swept under the caudal retractor blade by use of endoscopic peanut elevators. The L1 retractor bone pin was then inserted.

The navigated dilator was removed, and a series of tubular dilators were placed over the guidewire to dilate through the psoas muscle before introduction of the tubular retractor. The tubular retractor was inserted over the largest tubular dilator via a twisting motion. A table-mounted holding arm was attached and tightened to hold the retractor in the desired position. The dilators were removed, and 1 retractor bone screw was inserted into the superior endplate of the inferior vertebra. The retractor was opened by direct vision until sufficient disk visualization was obtained, with the surgeon being alert to the presence of any nerves in the field. A second retractor bone screw was inserted into the inferior endplate of the superior vertebra. Finally, any remaining psoas muscle or tissue was cleared by suction in a gentle sweeping motion.

After the placement of the tubular retractor, the lateral disk annulus was exposed and incised with an annulotomy

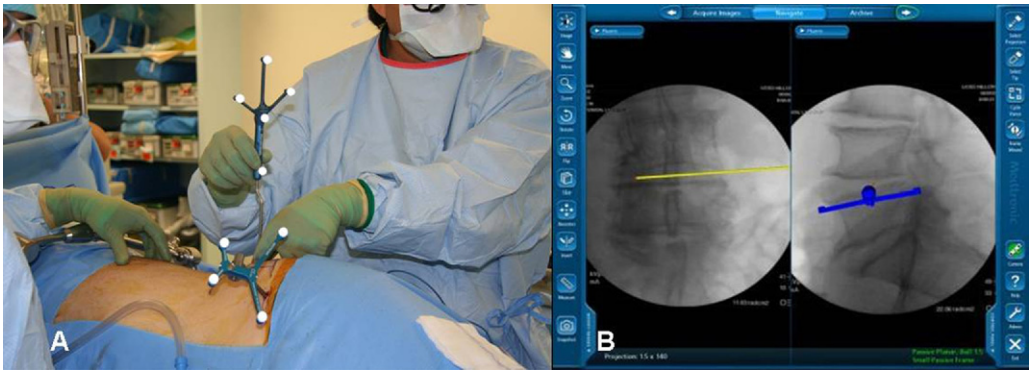

Fig. 2. Surgeon's intraoperative use and perspective of navigation system. The surgeon plans the skin incision with the NAV Pointer (A) by simultaneously visualizing the disk center in real time with the navigation computer's virtual instrument overlay over the previously obtained anterior/posterior and lateral images (B).

Downloaded from http://ijssurgery.com/ by guest on April 19, 2024

knife. A subtotal discectomy was performed. Disk debridement was accomplished by use of a rotating shaver and disk removed with pituitary rongeurs and curettes. Once adequate discectomy had been achieved, the contralateral annulus was released with a long Cobb elevator. After contralateral annulus release, endplates were decorticated, and the disk space was dilated with smooth metal sizers to determine the necessary cage height for adequate correction. Cage length selection was made ensuring adequate span of the apophyseal ring by use of the NAV Pointer by adding length to the pointer tip with the software. The surgeon then inserted the intervertebral cage, keeping the inserter instrument perfectly upright, ensuring proper alignment and orientation of the cage. Both the discectomy and placement of the graft were done solely via navigation guidance. At the end of the procedure, the C-arm was reintroduced and fluoroscopic images were taken to verify graft position. The procedure ended with slow removal of the tubular retractor. A final set of fluoroscopic images was then obtained.

MIS DLIF technique (FLUORO)

For the FLUORO group, setup was similar to the NAV group with a few exceptions. Setup for this group did not include placement of a reference tracker. A set of new fluoroscopic images were taken to locate the disk by use of the C-arm at the beginning of each level. Surgical approach, positioning of the retractors, discectomy, and insertion of the intervertebral cage were analogous to NAV by use of multiple lateral and under-the-table AP fluoroscopic images for instrument guidance. Therefore the C-arm remained in the surgical field throughout the procedure.

NAV accuracy

A fourth specimen was used to evaluate the accuracy of the NAV system. All procedures were conducted by the same technique as previously described for NAV DLIF. Image library acquisition was done for each level, and instruments were reregistered at each level as well. Four 4.77-mm-diameter cannulated screws were placed in the L2-5 vertebral bodies. Accuracy data were collected at 4 stages of the NAV MIS DLIF procedure: after retractor deployment, after Cobb release of the contralateral annulus, after cage sizing, and after cage insertion. The surgeon exposed the screw head, and the tip of the NAV Pointer was placed in the center of the screw head, at which time a virtual image was taken of the NAV Pointer tip location by the navigation computer. This protocol was repeated 3 times at each designated stage of the procedure, with the surgeon removing the pointer from the field and repositioning the probe in the same known position. StealthStation images were saved each time the pointer was returned to the field for each level, and these images were then used for deviation measurements.

The deviation distance of each navigation computer image was then measured (Fig. 3). Anterior-posterior (via lateral fluoroscopy images), medial-lateral (via anterior-posterior images), and cephalad-caudad (via lateral fluoroscopy images) deviation of the NAV Pointer tip from the center of the screw head was measured by Photoshop software (Adobe, Inc., San Jose, California). Deviation distance was determined by use of an image standard ratio of the known screw shaft width in millimeters to the width of the screw in the image in pixels. The image deviation distance in pixels was then multiplied by this standard ratio to determine the deviation distance in millimeters. All deviation distances at each level, at each stage in the procedure, and in all 3-dimensional planes were then averaged and reported as a single average deviation value for a specific procedure level.

Statistical methods

All statistical comparisons were made by use of the Student t test. Significance was set at $P < .05$.

Results

There were 21 unilateral DLIF procedures performed on 3 cadaveric specimens from T10-11 to L4-5: 11 in the NAV group and 10 in the FLUORO group (Table 1). Comparisons between NAV and FLUORO for the DLIF procedure show statistically significant differences for setup, approach, discectomy, and total fluoroscopy times (Fig. 4).

Our results show that mean approach times for the FLUORO group were significantly longer than approach times for NAV (19.61 ± 2.52 minutes vs 15.91 ± 4.08 minutes, $P = .024$). Likewise, when comparisons were made between discectomy times for the 2 groups, significantly more time was required for discectomy with FLUORO than for NAV (8.43 ± 1.99 minutes vs 5.98 ± 1.88 minutes, $P = .009$). In contrast, the setup time required for NAV was significantly longer than the setup time for FLUORO (5.81 ± 2.65 minutes vs 3.01 ± 0.84 minutes, $P = .005$). When mean cage insertion and total operating times were compared between groups, no statistically significant differences were obtained.

Fluoroscopy time used for FLUORO, as determined by the internal timer on the C-arm, was nearly twice as long as with NAV (43.7 ± 16.6 seconds vs 24.0 ± 10.8 seconds per level, $P = .004$). Radiation exposure for NAV was nearly undetectable (0.82 ± 0.6 mrem per level), unlike exposures seen for FLUORO (4.80 ± 3.08 mrem per level) ($P = .0005$).

Accuracy data were recorded from a separate specimen at 4 stages of each NAV DLIF procedure, and overall mean values were determined per level from L4-5 to L1-2 (Fig. 5). Accuracy results were as follows: L4-5, 0.78 ± 0.33 mm; L3-4, 0.97 ± 0.12 mm; L2-3, 0.86 ± 0.08 mm; and L1-2, 1.38 ± 0.44 mm.

Downloaded from http://ijssurgery.com/ by guest on April 19, 2024

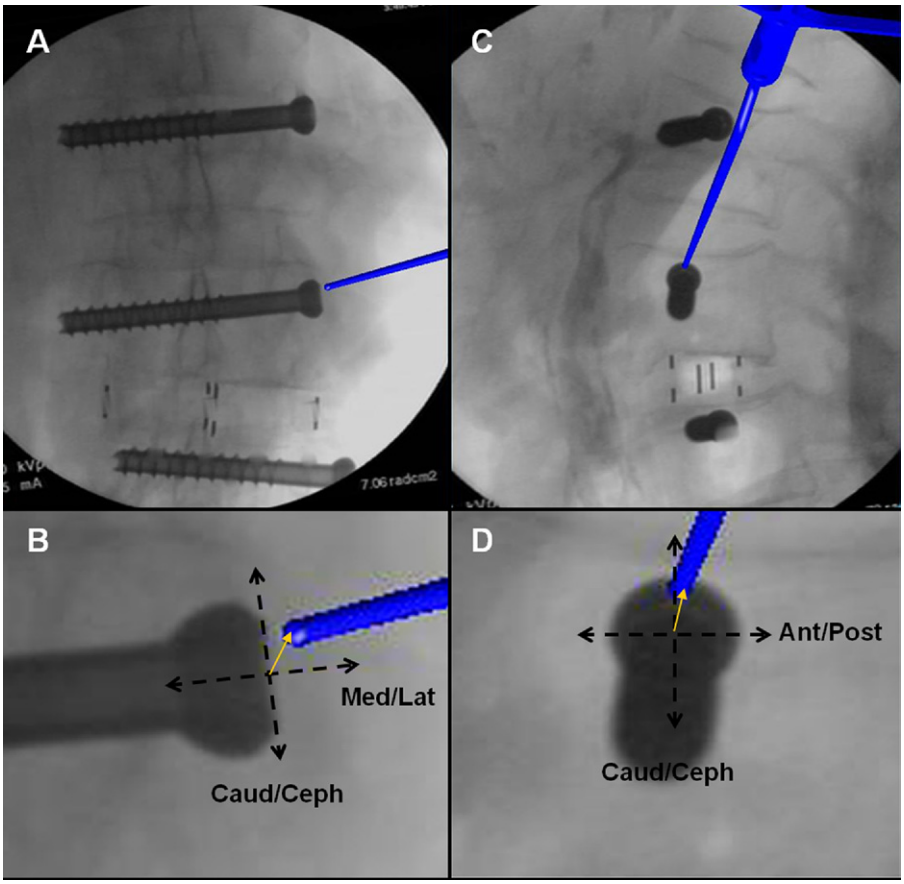

Fig. 3. Accuracy determination by use of navigation images. Accuracy measurements were made from intraoperative navigation images (A, C). Deviation distances in 3 dimensions were determined by measuring the NAV Pointer tip deviation from the center of a screw head previously inserted into each vertebral body (B, D).

Discussion

The DLIF technique is a recently developed spinal fusion procedure using MIS techniques. The purpose of this study was to evaluate the effectiveness and accuracy of NAV for the DLIF procedure.

Our results show that use of NAV for the MIS DLIF procedure is feasible. The data indicate that although initial setup time is longer for NAV MIS DLIF, the total operating times were not significantly different between the groups because of the shorter approach and discectomy times for the NAV group. The simultaneous AP and lateral imaging provided by NAV is the likely factor that makes the approach, guidewire insertion, and discectomy times shorter than FLUORO. In addition, with the C-arm removed from the surgical field for most of a navigation-assisted procedure, the surgeon can more easily maneuver about the sur-

Table 1
Spinal level in NAV and FLUORO groups

Spinal level	NAV group	FLUORO group
T10-11	3	0
T11-12	1	2
T12-L1	2	1
L1-2	1	2
L2-3	3	0
L3-4	1	2
L4-5	0	3
Total	11	10

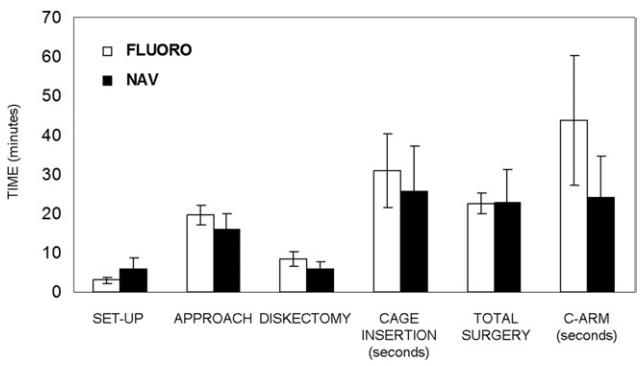

Fig. 4. Comparison of surgical times. Various surgical step times for both the FLUORO group and the NAV group were compared. The FLUORO group had significantly longer approach, discectomy, and C-arm usage times, whereas the NAV group had a significantly longer setup time ($P < .05$). Cage insertion times and total surgical times were not significantly different between the 2 groups.

Downloaded from http://ijssurgery.com/ by guest on April 19, 2024

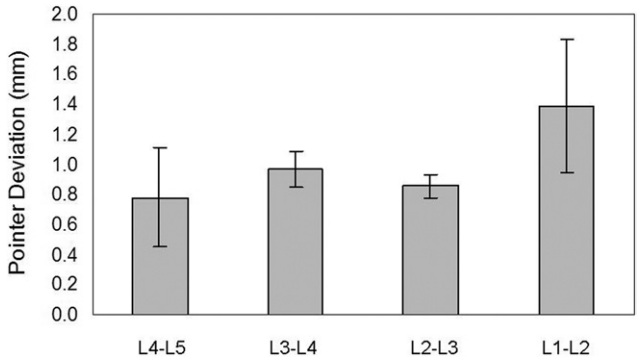

Fig. 5. Accuracy of navigation-assisted DLIF procedure, showing mean 3-dimensional intraoperative NAV Pointer deviation distances for NAV DLIF procedure. Navigation is accurate within 1 mm for the common DLIF levels of L2-5. A slight decrease in accuracy is seen as the NAV Pointer moves further from the NAV tracker pin in the ASIS.

gical field. Navigation-assisted procedures do, however, require proper setup of the navigation system, which includes insertion of the navigation tracker pin and registration of the surgical instruments. These extra steps lead to longer setup times for NAV. Overall, however, this does not significantly change the total operating times compared with FLUORO.

Accuracy data show that NAV MIS DLIF is accurate to less than 1 mm over the most commonly indicated levels for the DLIF procedure (L2-5). Although the error at L1-2 is significant (1.38 ± 0.44 mm), it was relatively similar to the internal system error reported by the StealthStation Treon; that level was 1.3 mm. The accuracy data show that as the NAV Pointer progresses away from the ASIS NAV tracker pin, there is a slight increase in the positional error between the navigation virtual image and the radiographic image. This minor error increase is expected as the navigation instruments move further from the fixed tracker pin. However, our study shows that the error seen for the most common DLIF levels of L2-5 is acceptable, at less than 1 mm. Another interesting issue that arises when measuring distances on radiographic films is the concept of parallax. In our study, to minimize parallax, the surgical target site was centered for each level and a new image library was obtained at the beginning of each level. Along these lines, the NAV Pointer tip, from which 3-dimensional distances were measured, was an electronic overlay made by the StealthStation computer, thus minimizing image perspective issues.

It is important to note that this study analyzed the accuracy of the NAV MIS DLIF technique in a single specimen at only 4 lumbar levels. New images were obtained after cage insertion at each level to account for changes in disk space height due to cage insertion. In addition, as a surgeon corrects deformities from caudal to cephalad, movement of the spine due to cage insertion may, theoretically, alter the accuracy of the navigation system.

Minimally invasive spine surgery relies heavily on fluoroscopy for guidance and instrument placement for each procedure. This reliance exposes the surgeon and surgical team to ionizing radiation. Likewise, previous studies have shown that radiation exposure from spinal procedures is much greater than exposure for surgery of the extremities because of differences in tissue mass. Spinal images require significantly more energy to penetrate tissues and thus lead to greater generation of ionizing radiation.[4,10–12] Thus efforts to limit radiation exposure during spinal procedures remain paramount. According to the Nuclear Regulatory Commission, the yearly exposure limits to the whole body, eyes, and hand are 5,000, 15,000, and 50,000 mrem, respectively. On the basis of our cadaveric data, each level leads to 4.8 mrem of exposure. This coincides with 1,042 levels per year for maximum whole-body exposure. Taking into account that a significant portion of the surgeries would involve more than a single level, as well as the likelihood that in the actual clinical setting, more imaging would be used, the maximum exposure limit could be reached by an active spine surgeon. With navigation-assisted MIS techniques, this radiation exposure can be dramatically decreased. During NAV DLIF, the C-arm is used at the beginning of the procedure to obtain an image library and is not used again until the procedure is complete. During this time, the surgical team steps away from the C-arm. By eliminating radiation exposure, the surgeon and surgical team can avoid the use of cumbersome protective lead gear.

This study shows that navigation technology is a useful tool for use with the MIS DLIF technique. However, it is important to note that this study only used a single surgeon who was experienced in MIS procedures and the use of navigation technologies. Therefore time data from this study may not represent surgical times for all surgeons with a variety of experience with these techniques. Likewise, the surgeon in this study was familiar with interpreting real-time simultaneous AP and lateral images produced by the navigation system. Surgeons not familiar with mentally interpreting navigation images into the reality of the surgical field may require more time to complete each MIS DLIF procedure.

Another key limitation of this study is that neurophysiologic monitoring cannot be used in the cadaveric specimen. In the actual clinical setting, readjustment of the initial dilator must be performed, especially at L4-5, despite an optimal position on fluoroscopy. The need to make changes to the position of the initial dilator solely because of triggering of the neuromonitoring system would add more time to the approach. Finally, our statistical analyses used the Student *t* test to compare 2 groups. Given the number of parameters and their interdependence, other statistical methods may be used that may alter the statistical significance of the study.

Although the use of navigation technology for MIS of the spine is promising, surgeon perceptions about the use of spinal navigation have recently been studied and interestingly show that the majority of those queried are concerned about the increased operative time and cost, lack of necessity, unreliable accuracy, and intraoperative problems with

Downloaded from http://ijssurgery.com/ by guest on April 19, 2024

navigation technology.[9] However, navigation technology has been widely used in the fields of neurosurgery, orthopaedic surgery, and otolaryngology dating back to the 1970s, with a large growth in technology development in the 1990s.[13] Numerous studies have noted that although navigation-assisted technologies require longer setup and learning curves, the reproducibility and accuracy of the surgical procedure improve with the use of navigation.[3,5,14–16] The intraoperative accuracy of image-guided fluoroscopy for pedicle screw placement has been described.[17–19] Likewise, a previous study of navigation-assisted MIS transforaminal lumbar interbody fusion (TLIF) conducted by our group[6] and a study conducted by Sasso and Garrido[20] note that navigation-assisted MIS techniques for spinal fusion do not increase total surgical time.

However, widespread adoption of spinal navigation technologies will likely require that the technology become more user-friendly, more reliable, more cost-effective, and less prone to intraoperative malfunction. The added costs of new navigation technology in overall health care delivery must be further analyzed. Such analyses will likely have a variable impact based on differences specific to each practice setting. DeLucia et al[21] have previously described the fundamental difficulties with image-guided MIS procedures. Their conclusions emphasized the need for surgeon practice and familiarity with navigation systems to improve their "mental model of the surgical environment." To provide more practice to surgeons, navigation-assisted MIS training must be available to those who are interested. Further studies that evaluate the clinical efficacy, success, and limitations of NAV for the DLIF technique are currently being conducted by our group and will further illuminate its importance as a new, effective minimally invasive technique for spinal fusion.

Conclusion

MIS of the spine is a promising area of clinical practice that has the potential to provide improved outcomes for patients. However, these techniques pose new challenges. With decreased visualization of the surgical field, the surgeon must rely more on an intraoperative C-arm to visualize key anatomic landmarks. With increased C-arm use, there is increased exposure to ionizing radiation. This study has shown that spinal navigation provides an alternative means of visualizing the surgical anatomy while offering the surgeon a more safe and ergonomically friendly environment in which to operate. The NAV MIS DLIF technique is a promising method of performing minimally invasive lumbar interbody fusions using spinal navigation.

References

1. Fessler RG. Minimally invasive spine surgery. *Neurosurgery* 2002; 51(Suppl):Siii–iv.
2. Ozgur BM, Aryan HE, Pimenta L, Taylor WR. Extreme lateral interbody fusion (XLIF): a novel surgical technique for anterior lumbar interbody fusion. *Spine J* 2006;6:435–43.
3. Holly LT, Foley KT. Intraoperative spinal navigation. *Spine* 2003; 28(Suppl):S54–61.
4. Rampersaud YR, Foley KT, Shen AC, Williams S, Solomito M. Radiation exposure to the spine surgeon during fluoroscopically assisted pedicle screw insertion. *Spine* 2000;25:2637–45.
5. Assaker R, Reyns N, Vinchon M, Demondion X, Louis E. Transpedicular screw placement: image-guided versus lateral-view fluoroscopy: in vitro simulation. *Spine* 2001;26:2160–4.
6. Kim CW, Lee YP, Taylor W, Oygar A, Kim WK. Use of navigation-assisted fluoroscopy to decrease radiation exposure during minimally invasive spine surgery. *Spine J* 2008;8:584–90.
7. Mirza SK, Wiggins GC, Kuntz C, et al. Accuracy of thoracic vertebral body screw placement using standard fluoroscopy, fluoroscopic image guidance, and computed tomographic image guidance: a cadaver study. *Spine* 2003;28:402–13.
8. Vaccaro AR, Yuan PS, Smith HE, Hott J, Sasso R, Papadopoulos S. An evaluation of image-guided technologies in the placement of anterior thoracic vertebral body screws in spinal trauma: a cadaver study. *J Spinal Cord Med* 2005;28:308–13.
9. Choo AD, Regev G, Garfin SR, Kim CW. Surgeons' perceptions of spinal navigation: analysis of key factors affecting the lack of adoption of spinal navigation technology. *SAS J* 2008;4:189–94.
10. Theocharopoulos N, Damilakis J, Perisinakis K, Papadokostakis G, Hadjipavlou A, Gourtsoyiannis N. Occupational gonadal and embryo/fetal doses from fluoroscopically assisted surgical treatments of spinal disorders. *Spine* 2004;29:2573–80.
11. Theocharopoulos N, Perisinakis K, Damilakis J, Papadokostakis G, Hadjipavlou A, Gourtsoyiannis N. Occupational exposure from common fluoroscopic projections used in orthopaedic surgery. *J Bone Joint Surg Am* 2003;85:1698–703.
12. Theocharopoulos N, Damilakis J, Perisinakis K, Papadokostakis G, Hadjipavlou A, Gourtsoyiannis N. Fluoroscopically assisted surgical treatments of spinal disorders: conceptus radiation doses and risks. *Spine* 2006;31:239–44.
13. Amiot LP, Poulin F. Computed tomography-based navigation for hip, knee, and spine surgery. *Clin Orthop Relat Res* 2004:77–86.
14. Amiot LP, Lang K, Putzier M, Zippel H, Labelle H. Comparative results between conventional and computer-assisted pedicle screw installation in the thoracic, lumbar, and sacral spine. *Spine* 2000;25: 606–14.
15. Fu TS, Chen LH, Wong CB, et al. Computer-assisted fluoroscopic navigation of pedicle screw insertion: an in vitro feasibility study. *Acta Orthop Scand* 2004;75:730–5.
16. Smith HE, Vaccaro AR, Yuan PS, Papadopoulos S, Sasso R. The use of computerized image guidance in lumbar disk arthroplasty. *J Spinal Disord Tech* 2006;19:22–7.
17. Foley KT, Smith MM. Image-guided spine surgery. *Neurosurg Clin North Am* 1996;7:171–86.
18. Merloz P, Tonetti J, Pillet L. Pedicle screw placement using image-guided techniques. *Clin Orthop* 1998;354:39–48.
19. Quiñones-Hinojosa A, Kolen R, Jun P, Rosenberg WS, Weinstein PR. Accuracy over space and time of computer-assisted fluoroscopic navigation in the lumbar spine *in vivo*. *J Spinal Disord Tech* 2006;19: 109–13.
20. Sasso RC, Garrido BJ. Computer-assisted spinal navigation versus serial radiography and operative time for posterior spinal fusion at L5-S1. *J Spinal Disord Tech* 2007;20:118–22.
21. DeLucia PR, Mather RD, Griswold JA, Mitra S. Toward the improvement of image-guided interventions for minimally invasive surgery: three factors that affect performance. *Hum Factors* 2006;48:23–38.

Downloaded from http://ijssurgery.com/ by guest on April 19, 2024