

Endoscopic transforaminal decompression, interbody fusion, and percutaneous pedicle screw implantation of the lumbar spine: A case series report

Said G. Osman

Int J Spine Surg 2012, 6 () 157-166
doi: <https://doi.org/10.1016/j.ijsp.2012.04.001>
<https://www.ijssurgery.com/content/6/157>

This information is current as of May 17, 2025.

Email Alerts Receive free email-alerts when new articles cite this article. Sign up at:
<http://ijssurgery.com/alerts>



Endoscopic transforaminal decompression, interbody fusion, and percutaneous pedicle screw implantation of the lumbar spine: A case series report

Said G. Osman, MD, FAAOS, FRCS Ed(ortho) *

American Spine Center, Frederick, MD

Abstract

Background: On the basis of the experiences gained from conventional open spinal procedures, a long list of desirable objectives have emerged with the evolution of the lesser invasive spinal procedures. At the top of that list is the desire to minimize the trauma of surgery. The rest of the objectives, which include reductions of operating time, surgical blood loss, hospital stay, postoperative narcotic medication, convalescence, complication rates, and escalating health care costs, as well as the desire of elderly patients to continue rigorous physical activities, largely depend on the ability to minimize the trauma of surgery. The purpose of this study was to investigate the feasibility of the least invasive lumbar decompression, interbody fusion and percutaneous pedicle screw implantation, to minimize surgical trauma without compromising the quality of the treatment outcome, as well as to minimize risk of complications.

Methods: In this case series, 60 patients with diagnoses of degenerative disc disease, degenerative motion segments with stenosis, and spondylolisthesis, in whom nonoperative treatments failed, were treated with endoscopic transforaminal decompression and interbody fusion by 1 surgeon in 2 centers. The outcome measures were as follows: operating time, intraoperative blood loss, hospital stay, Visual Analogue Scale (VAS) scores for back and leg pain, scores on the Roland-Morris Disability Questionnaire, and postoperative imaging studies. A consecutive series of patients who met the treatment criteria completed VAS forms and Roland-Morris questionnaires preoperatively. Surgical procedures included arthroscopic decompression of the foramina and the discs; endplate preparation and implantation of allograft bone chips and bone morphogenetic protein 2 on absorbable collagen sponge into the disc space; and percutaneous implantation of pedicle screws. Postoperatively, the patients again completed the VAS forms and Roland-Morris questionnaires. Their charts were reviewed for office notes, operative notes, hospital stay, medications, and imaging studies. The latest X-ray and computed tomography scan films were reviewed and analyzed. Patients were followed up for a minimum of 6 months. The literature was reviewed for comparison of outcomes.

Results: Sixty patients met the inclusion criteria. The mean age was 52.8 years. The duration of illness averaged 5 years. Follow-up ranged from 6 to 25 months, with a mean of 12 months. Preoperative diagnoses included degenerative disc disease, degenerative motion segments with stenosis, and spondylolisthesis. The mean time in the operating room was 2 hours 54 minutes. Estimated blood loss averaged 57.6 mL. The duration of the hospital stay averaged 2.6 days. Preoperative back pain and leg pain were significantly reduced ($P < .005$). Forty-seven imaging studies obtained at the last visit, including X-ray and computed tomography scans, showed solid fusion in 28 patients (59.6%), stable fixation in 17 (36.2%), and osteolysis around the pedicle screws in 2 (4.2%). All patients had improvement of motor function, whereas 2 patients complained of residual numbness. In addition, 8 patients (13%) complained of residual discomfort on extension of the lumbar spine. Two patients had pedicle screw-related complications requiring surgery. A review of the literature showed that endoscopic transforaminal decompression and interbody fusion performed better than open transforaminal lumbar interbody fusion/posterior lumbar interbody fusion, minimally invasive transforaminal lumbar interbody fusion, and extreme lateral lumbar interbody fusion, with regard to most parameters studied.

Conclusions: The endoscopic transforaminal lumbar decompression, interbody fusion, and percutaneous pedicle screw instrumentation consistently produced satisfactory results in all demographics. It performed better than the alternative procedures for most parameters studied.

© 2012 ISASS - International Society for the Advancement of Spine Surgery. Published by Elsevier Inc. All rights reserved.

Keywords: ETDIF; Arthroscopic; Posterolateral; Interbody; Percutaneous; BMP-2

* Corresponding author: Said G. Osman, MD, FAAOS, FRCS Ed(ortho), American Spine Center, 1050 Key Pkwy, Frederick, MD 21702; Tel: 240-629-3939; Fax: 240-715-9670.

E-mail address: gotoaila@gmail.com

Open surgical procedures of the lumbar spine, though addressing the pathology adequately, may—depending on the complexity of the condition and the magnitude of the procedures—lead to complications that can cause disability in patients.^{1–4} Besides complications, major

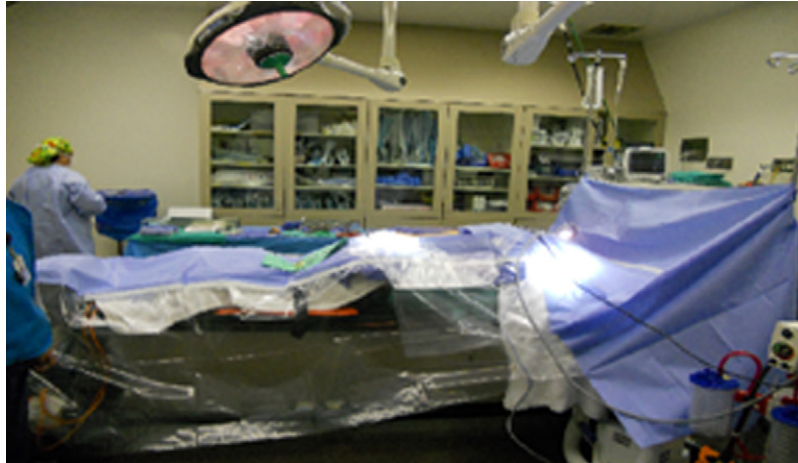


Fig. 1. Patient prone on open frame, transparent drape is used to maintain visual control of foot pedals, and lateral position of fluoroscope.

dissections of the spine may lead to prolonged duration under anesthesia, large quantities of blood loss requiring transfusion, prolonged hospital stay, long duration of narcotic pain medication, protracted rehabilitation programs, incomplete recovery because of damage to the paraspinal muscles,^{5,6} failure to return to a patient's prior occupation, and increased cost to the individual and society. Given the unsustainable escalation of health care costs, the impact of surgical trauma on outcome, the increasing demand by patients for the shortest postoperative downtime, the desire of elderly patients to continue vigorous physical activities, and the growing numbers of elderly patients with spinal problems in the community, it is reasonable to explore the feasibility of the least invasive methods to remove the disease while preserving the normal anatomy. The various less invasive procedures, such as percutaneous pedicle screw implantation, mini-transforaminal lumbar interbody fusion, extreme lateral lumbar interbody fusion (XLIF), AxiaLIF (pre-sacral approach), and other similar procedures, attempt to achieve these goals, with variable successes. Although these procedures, to variable extents, reduce surgical trauma, operating time, blood loss, hospital stay, recovery time, and costs, they all suffer characteristic limitations in their

abilities in addressing diseases at different levels of the spine. This necessitates a combination of approaches to address different pathologic processes at different spinal levels. Examples include the use of AxiaLIF being limited to L4-5 and L5-S1; limitation of XLIF caudal to L4-5 (because of the neural anatomy and the iliac wing obstructing lateral access to the spine) and cephalad to levels L2-3 (because of the rib cage obstructing access); and the difficulty of using the minimally invasive spine surgery (MIS) transforaminal lumbar interbody fusion (TLIF) at multiple levels. Furthermore, the anatomic structures traversed to establish access channels to the spine pose different challenges with potentially serious consequences. Examples include injury to the bowel in the presacral access to the lumbosacral junction,⁷⁻⁹ potential injury to the lumbar plexus with the XLIF approach,¹⁰⁻¹³ and potential intraspinal complications with MIS TLIF similar to those of open surgery.^{11,12,14}

Although a number of spinal procedures fall under the umbrella name of "minimally invasive spine surgery," it is obvious from the foregoing data that each has a unique set of potential complications that can be devastating for the patient. Hence all MIS procedures are not the same, and it

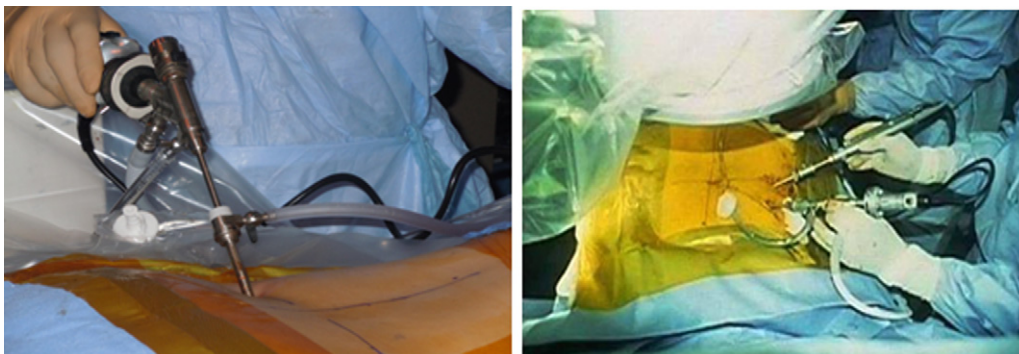

Fig. 2. Uniportal, and biportal transforaminal approaches to lumbar spine.

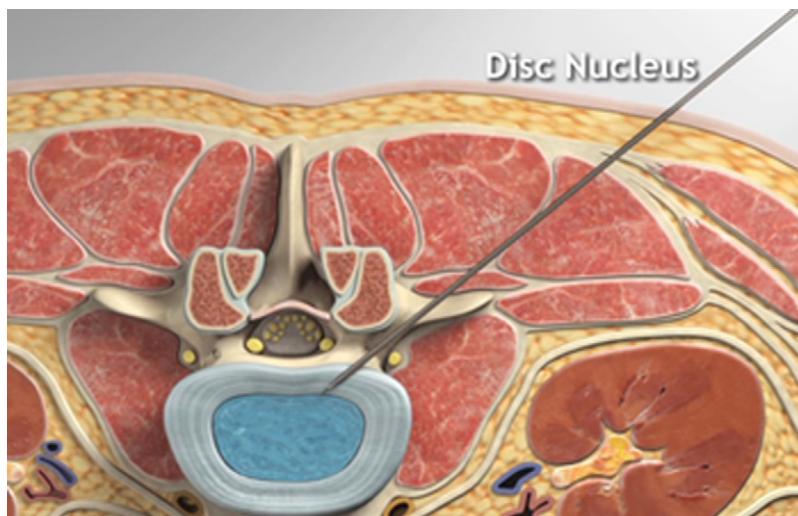


Fig. 3. Illustration of the path of posterolateral transforaminal instrumentation of the lumbar disc. Note the traversing and exiting nerves, seen end-on.

may be time to consider redefining and grading them based on some of these factors.

Methods

Consecutive patients who met the treatment criteria completed Visual Analogue Scale (VAS) forms and Roland-Morris questionnaires preoperatively. All patients were placed under endotracheal anesthesia; a Foley catheter was passed under sterile conditions; electrodes were attached for intraoperative transcranial electrical stimulation-induced motor-evoked potentials (MEPs) and elec-

tromyography (EMG) monitoring; and sequential compression devices were applied for intraoperative deep venous thrombosis prophylaxis. The patients were all placed in the prone position on an open-frame operating table throughout surgery (Fig. 1).

A transparent surgical drape was used to enable the surgeon to visually supervise repositioning of the C-arm for lateral projection to avoid injury to the patient and for the sake of foot-pedal visibility. A unilateral uniportal, unilateral biportal, or bilateral arthroscopic approach was used depending on the pathology, with the bilateral approach being the most frequently used for this series (Fig. 2). For




Fig. 4. Demonstration of sequence of transforaminal instrumentation of lumbar disc for endoscopy. Instrumentation begins with long spine needle, followed by guide-wire, obturator, and cannula, in that order. The middle of the lower row of photographs shows percutaneous removal of the disc nucleus, seen on the last of the photographs.




Fig. 5. Expandable reamer in un-expanded and expanded state. Note the distal end of the reamer cannula is threaded so that it locks into the endplates, thus preventing deep penetration and backing out of the reamer.

neuro-monitoring, the team—consisting of a technician (in the operating room) and a neurophysiologist (remote), working in concert with the operating team (surgical and anesthetic)—routinely used the combination of transcranial electrical stimulation-induced MEPs and EMG to monitor myogenic responses to surgery. No muscle relaxants were used during anesthesia to minimize interference with electrical recordings. Needles or a combination of needles and surface electrodes were used, with needles being used consistently for transcranial electrodes.

The procedure started with disc instrumentation if the disc height was greater than 50% of normal and with percutaneous pedicle screw instrumentation and distraction if the disc was collapsed to less than 50% of its normal height. Disc instrumentation started with insertion of an 18-gauge, 6.5-inch spinal needle, at the mid-interpedicular site, on both anteroposterior and lateral fluoroscopic projections. EMG may be monitored by attaching the electrode clip to the spinal needle, as the needle is advanced into the disc. Needle stimulation was performed in situations where the disc was markedly collapsed, narrowing the Kambin triangle.

Where the disc height was more than 50% of normal, MEPs, transmuscular EMG, and endoscopic visualization were used to monitor the disc instrumentation procedure.

During the phase of percutaneous pedicle screw implantation, a sharp trocar and cannula were inserted under direct fluoroscopic control or under the control of a navigation system. A guidewire was introduced through the needle after the removal of the stylet. The guidewire was then stimulated, and EMG recording was made. The needle was then removed, leaving the guidewire in the vertebra. A cannulated tap was used to tap the pedicle canal over the guidewire. The tap and the pedicle screw were sequentially stimulated to determine whether there was a breach of the pedicle wall. Readings between 10 and 20 milliamps were accepted.

Access to the posterolateral disc was established through the triangular working zone, as described by Kambin¹⁵ (Fig. 3). Portal sites and angles of instrumentation were selected as described by Osman and Marsolais.¹⁶

Steps to establish an access channel to the disc started with intradiscal instrumentation with the spinal needle and ended with the appropriately sized cannula docked into the disc, and the disc nucleus was excised by use of various instruments, including grasping forceps and shavers (Fig. 4). In the situation where there was more than 50% collapse of the disc height with narrowing of the triangular working space (Kambin triangle), percutaneous pedicle screw instrumentation was performed be-




Fig. 6. The photograph on the left shows expandable disc reamer in place. The middle image shows expanded reamer in the disc space. The picture on the right shows bilateral, bi-portal approach with the arthroscope (on the left) visualizing endplate preparation with expandable reamer in the contralateral portal.

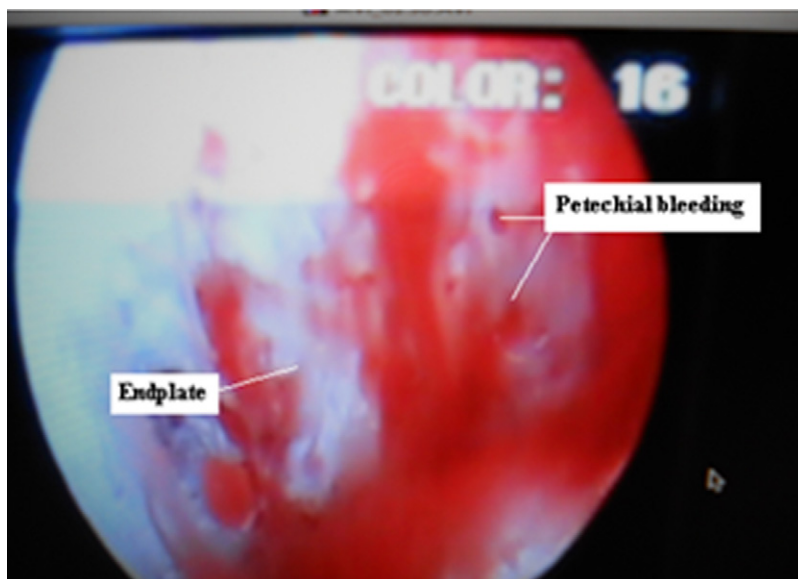


Fig. 7. Arthroscopic visualization of the prepared endplate. Note the petechial bleeding and the shiny subchondral bone which has not been breached during the reaming.

fore disc instrumentation. Distraction of the motion segment was carried out through the pedicle screws and locked in the distracted position, to open up the triangular working space.

Endplate preparation was performed with an expandable reamer through the smallest-diameter cannula to fit snugly between the endplates. The cannula was threaded at its distal end to engage the endplates, thereby reducing the risk of backing out or penetrating deeper into the disc space (Fig. 5).

The reamer was expanded within the disc space and rotated anteriorly and posteriorly in the plane of the disc space, to excise the fibrocartilage. Reaming was performed under fluoroscopic and arthroscopic guidance. The latter ensured the adequacy of endplate preparation (Fig. 6).

At the completion of the endplate preparation, arthroscopic visualization should reveal the subchondral bone, as well as petechial bleeding from the bone (Fig. 7).

Recombinant human bone morphogenetic protein 2 (rhBMP-2), at a concentration of 1.5 mg/mL, was placed on absorbable collagen sponge (ACS) for 15 minutes before implantation. A mean of 6 mg of rhBMP-2 was used per level fused. The ACS with rhBMP-2 was cut into 3 equal portions, and 2 portions were placed anteriorly in the disc space through the 2 access cannulas, 1 on each side. The third portion was further cut into small strips and mixed with 10 to 15 cubic centimeters of allograft bone chips. The mixture was packed into the disc space, behind the ACS containing rhBMP-2, by use of bilateral portals (Fig. 8).

Postoperatively, the patients completed the VAS forms and Roland-Morris questionnaires at the last follow-up. The patients' charts were reviewed for operative notes, hospital stay, medications, and imaging studies. The latest X-ray (including anteroposterior, lateral, and flexion/extension views) and computed tomography scan films were reviewed and analyzed. Patients were followed up for a minimum of 6 months.

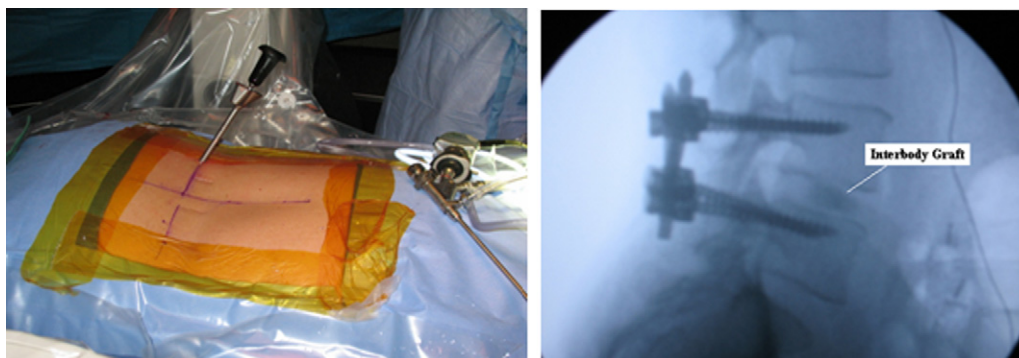
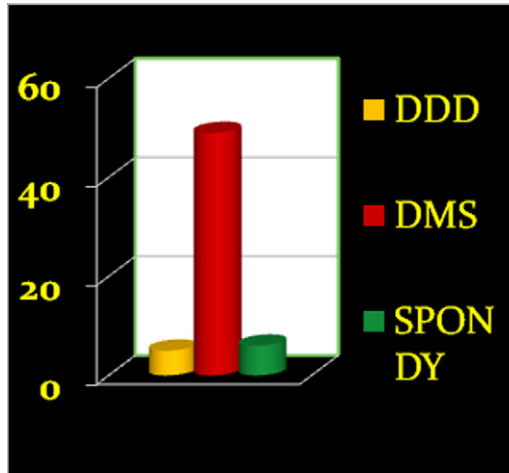


Fig. 8. The photograph illustrates the insertion of the graft in the intervertebral space, and the lateral fluoroscopic view shows interbody graft in place.



DDD = degenerative disc disease; DMS = degenerative motion-segment; Spondy = spondylolisthesis

Fig. 9. Illustrates the diagnoses in this series: DDD = degenerative disc disease; DMS = degenerative motion-segment; and Spondylolisthesis.

Results

In total, 60 patients (30 men and 30 women) met the inclusion criteria. Clinical data including office notes, operative notes, X-ray reports, and laboratory reports were available on all patients. Only 13 patients completed the Roland-Morris questionnaire at the last follow-up. Images were available for this study for 47 patients (78%). All the procedures were performed with patients in the prone position, and none needed conversion to an open approach or another MIS approach. All levels of the lumbar spine from the thoracolumbar junction to the lumbosacral junction were accessible through the described posterolateral approach, and no transiliac arthroscopic access to the lumbosacral junction was necessary in this series. The mean age was 52.8 years (range, 26–85 years). Of the patients, 57% were aged older than

50 years and 20% were aged older than 70 years. The duration of illness ranged from 2 months to 32 years and averaged 5 years. All patients complained of both back pain and leg pain of variable severity. Follow-up ranged from 6 to 25 months, with a mean of 12 months. Preoperative diagnoses included degenerative disc disease (8.3%), degenerative motion segments with stenosis (81.7%), and spondylolisthesis (10%) (Fig. 9).

The number of levels fused were as follows: 1 in 22 patients (36.7%), 2 in 28 patients (46.6%), 3 in 7 patients (11.7%), 4 in 1 patient (1.7%), and 5 in 2 patients (3.3%) (Fig. 10). The mean time in the operating room was 2 hours 54 minutes (range, 1 hour 57 minutes–4 hours 11 minutes). The operating room time increased with the number of levels fused (Fig. 11). Estimated blood loss averaged 57.6 mL (range, 30–100 mL). The blood loss increased with the number of levels fused (Fig. 12).

The pedicle screw systems used were as follow: Denali/Serengeti (K2M, Leesburg, Virginia) in 19 patients; Pathfinder (Zimmer, Warsaw, Indiana) in 18; Sextant

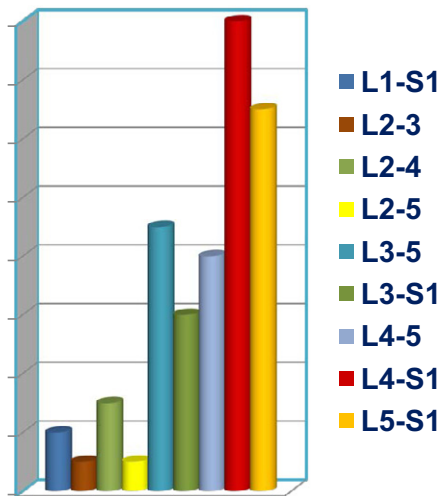


Fig. 10. Illustrates the frequency of motion-segments treated.

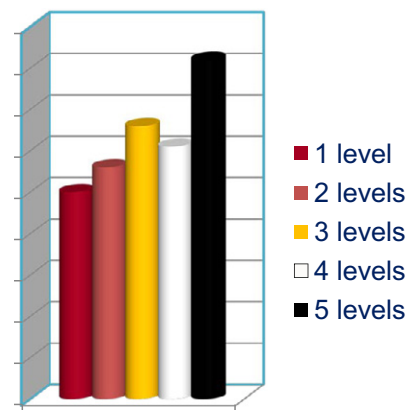


Fig. 11. Illustrates operating time according to levels fused.

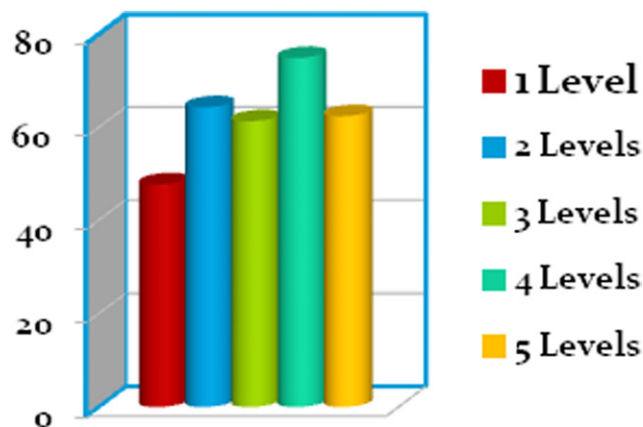


Fig. 12. Illustrates estimated blood loss according to levels fused.

(Medtronic, Memphis, Tennessee) in 17; and SpheRx (Nuvasive, San Diego, California) in 6. The length of hospital stay averaged 2.6 days (range, 1–12 days). The length of hospital stay increased with the number of levels fused. The preoperative back pain score averaged 7.5 (range, 0–10) on the VAS, and postoperative pain averaged 2 (range, 0–8) at the last follow-up. A paired *t* test was used for statistical analysis, and the difference between preoperative and postoperative back pain scores was significant ($P < .005$). The preoperative leg pain score averaged 7.0 (range, 0–10), and postoperative pain averaged 1.7 (range, 0–5) at the last follow-up ($P < .005$) (Fig. 13).

There were 9 patients who had 10 prior lumbar surgical procedures: 6 had 1-level decompressions (1 had a reoperation), 2 had 2-level decompressions, and 1 had an L5-S1 fusion. Their symptomatic relief and length of hospital stay were equal to or better than those of primary surgery cases (Fig. 14).

The disability score on the Roland-Morris Disability Questionnaire, available for 13 patients, averaged 21.2 preoperatively and 17.5 (range, 3–22) postoperatively. Forty-seven imaging studies were available for this study, including X-ray and

computed tomography scans; they showed solid fusion in 28 patients (59.6%), stable fixation in 17 (36.2%), and osteolysis around the pedicle screws in 2 (4.2%) (Fig. 15). The evolution of fusion was well demonstrated on the sequential follow-up radiographic studies (Fig. 16).

All patients had improvement of motor function, whereas 2 patients complained of residual numbness. In addition, 8 patients (13%) complained of residual discomfort on extension of the lumbar spine. In 1 patient (1.6%), medial penetration of an S1 screw occurred with S1 nerve root irritation, which required revision during the same admission. Pain developed in 1 patient because of loose pedicle screws, and removal of hardware was required. Both patients had a satisfactory outcome after the second operation.

Discussion

Compared with other surgical disciplines, including sports medicine in orthopedics, MIS spine surgery is still in its infancy. Several factors have combined to facilitate the paradigm shift from open to MIS spine surgery. These include, but are not limited to, the desire to minimize complications associated with extensive open procedures; the desire to restore function while preserving normal anatomy; the desire to minimize hospitalization and facilitate an early return to a productive occupation; and the desire for elderly patients to return to active pre-morbid status as early as possible. Currently, the driving force for change is the need to reign in the cost of medical care.

As we transition from open to less traumatic procedures, the term “minimally invasive spine surgery” has gained common use. At this time, in the lumbar spine, there are a number of procedures that fall under the umbrella name of minimally invasive spine surgery; these include MIS TLIF, XLIF, AxiaLIF (presacral approach to the lumbosacral junction), interspinous instrumentation, and facet fusion techniques. All these procedures, though sharing the label of MIS, have different attributes in terms of disruption of the normal anatomic structures; collateral damage to the struc-

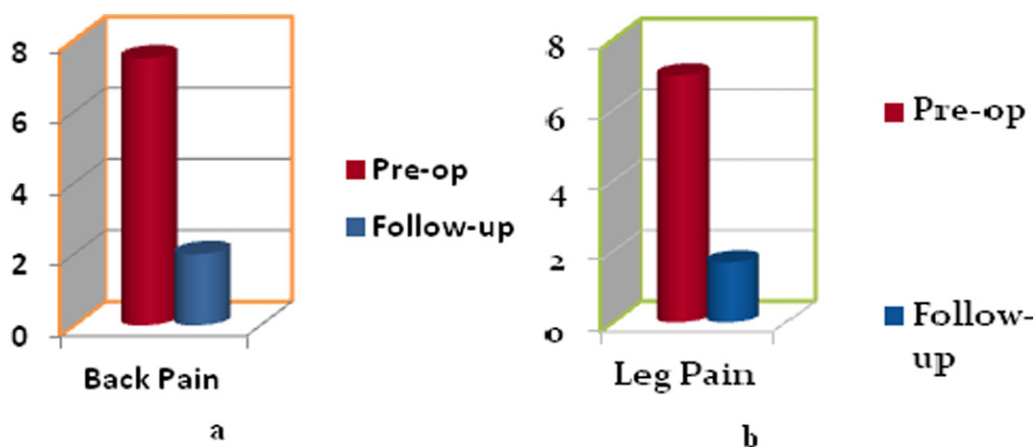


Fig. 13. a. Pre- and post-operative back pain; b. pre- and post-operative leg pain.
Downloaded from <https://www.ijssurgery.com/> by guest on May 17, 2025

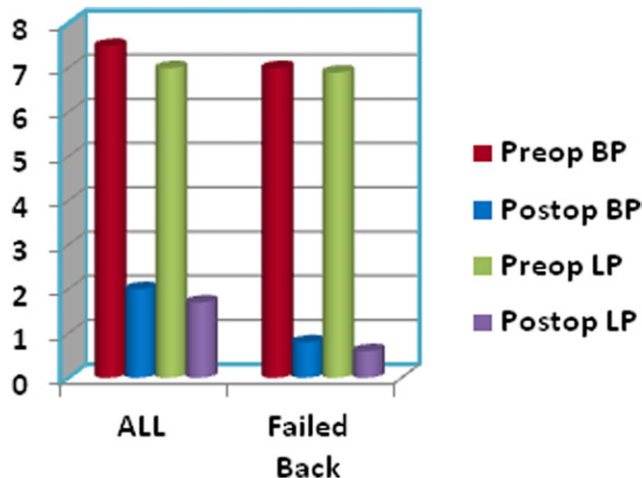


Fig. 14. Graph compares outcomes of all cases undergoing fusion versus those who had prior spine surgery.

tures in the neighborhood; accessibility to the different levels of the spine; the patient's self-image; and the stress of procedures on the operating team. Hence it is reasonable at this time to consider redefining and grading the MIS techniques based on these and other observations.

In their cadaveric study of a posterolateral arthroscopic approach to the lumbar and thoracic spine, Osman and Marsolais¹⁶ described approaches and parameters for safe instrumentation of the discs and foramina from T3 to S1. Later, they described an endoscopic transiliac approach to the L5-S1 disc and foramen to access the deep-seated L5-S1 level.¹⁷ Lessons learned from these studies have helped the author of this article to perform the least invasive procedures through the posterolateral approach from T4 to the sacrum. AxialIF provides presacral access that is currently limited to L4-5 and L5-S1,¹⁸ and although the number of occurrences is statistically small, serious bowel injuries requiring major interventions have been reported, due to the perforation of the rectum.⁷⁻⁹ XLIF is currently being performed by an increasing number of surgeons, and success rates as compared with open procedures are good. Notably, operating room time, length of hospital stay, and recovery time are much shorter and blood loss is much less than in open surgery cases, and functional restoration is better.¹⁹ The shortcomings of XLIF are the inability to access the L5-S1 disc and the risk of injury to the lumbosacral plexus at L4-5. Furthermore, access to the spine at L2-3 and cephalad is limited by the downward-sloping ribs and may require entry into the retropleural space in the thoracic motion segments. A common but often minor complication involves injury to the lumbosacral plexus in the belly of the psoas major with motor and sensory changes, weakness of hip flexion, and injury to other retroperitoneal structures, including the kidney.¹⁰⁻¹³ MIS TLIF is a difficult procedure requiring excision of the facet joint and, hence, is slow and is associated with moderate blood loss, thus limiting its use to 1 or 2 levels. Furthermore, intraspinal and intraforaminal

complications are comparable to those of open procedures.^{11,12,14} These features make it unsuitable for multi-level decompression, fusion, and instrumentation.

Endoscopic transforaminal decompression and interbody fusion (ETDIF) avoids the natural cavities, including the spinal, peritoneal, and pleural cavities. It also avoids entry into the psoas major, thereby avoiding injury to the resident lumbar plexus. The retropleural and retroperitoneal spaces are also avoided, minimizing the risk of injury to the viscera. The parameters studied showed a short operating room time, minimal blood loss, short length of hospital stay, satisfactory clinical outcome, and minimal complication rate. Most importantly, for multilevel decompression, interbody fusions, and pedicle screw instrumentation, ETDIF may be used for motion segments extending from T3 to the sacrum without changing the surgical technique or repositioning of the patient. Several reports on the trans-psoas approach describe postoperative weakness of hip flexion and neural deficits of variable severity affecting the lower extremities.^{7,10,18-20}

The essential features described in this article include routine use of a neuro-monitor; use of a transparent surgical drape so that the surgeon can see and operate foot pedals while operating the fluoroscopy machine in the lateral projection; and use of expandable reamers so that the instrument can be inserted in an unexpanded state through a small-diameter cannula and expanded within the disc to an appropriate dimension to scrape the fibrocartilage off the subchondral bone. The latter minimizes pressure on the soft tissue, including the nerve roots in the neighborhood of the cannula, while expansion of the access channel against the neighboring soft tissues—which is necessary with the XLIF, MIS TLIF, and posterior endoscopic approaches to the spine, to facilitate insertion of the appropriately sized instruments and implants into the disc space—is avoided. The use of arthroscopic visualization during the endplate prepara-

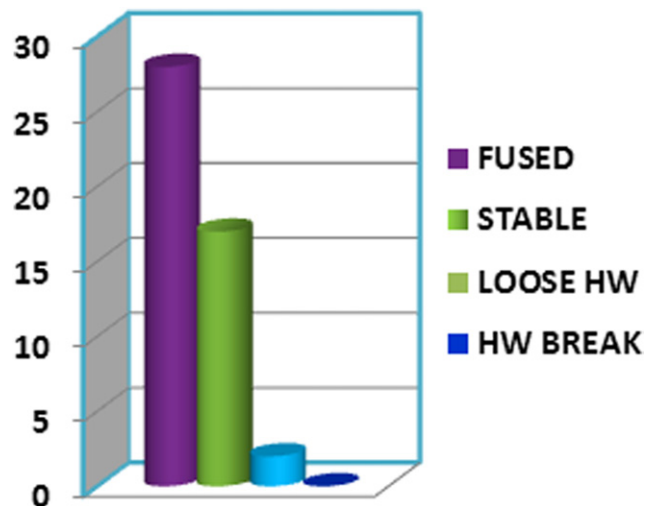
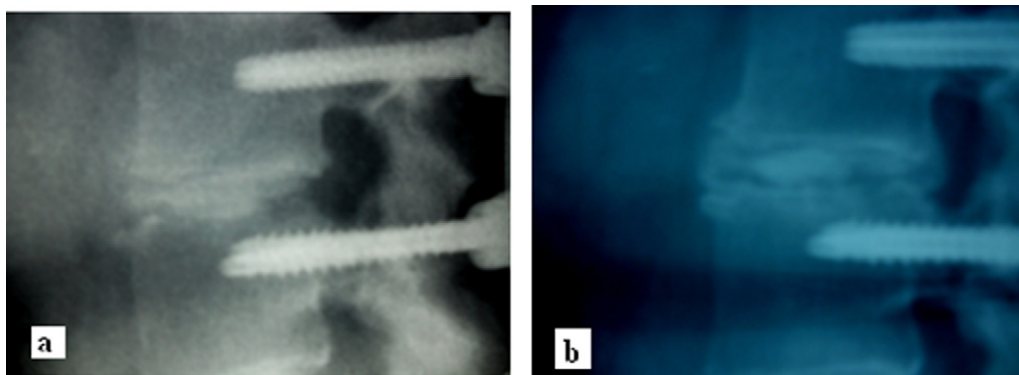


Fig. 15. Radiographic results following lumbar fusion.



a = 3 months post-op; b = 6 months post-op.

Fig. 16. Lateral views of a fused segment at 3 months and 6 months post-operatively.

tion confirms the adequacy of the preparation visually, rather than relying on palpation with instruments. The main uncertainty of this procedure has been the containment of the graft material. The author currently uses Optimesh (Spineology, St Paul, Minnesota) for this purpose.

ETDIF is a natural evolution of the arthroscopic microdiscectomy procedure. Several authors, over the last 2 decades, have published their experiences with the posterolateral arthroscopic approach, and the results have been largely satisfactory.^{21–23} The author has used this approach for nearly 2 decades and, with the application of the knowledge gained from the cadaveric studies referenced earlier, has not had any serious neurologic or other complications over the years. Unfortunately, although the steps for disc instrumentation are fairly simple and straightforward, the limited triangular operating space over the posterolateral disc bordered by the traversing and exiting nerve roots and, hence, the possibility of neural injury, has led to a low level of enthusiasm for this approach by spine surgeons until now. However, with the use of better teaching tools, technological improvements, and above all, a commitment to properly educate surgeons by those who have the expertise, it is expected that more surgeons will take an interest in learning and applying this very versatile approach.

Conclusion

The least invasive (arthroscopic) lumbar decompression, interbody fusion (with bone morphogenetic protein 2 and allograft bone chips), and percutaneous pedicle screw instrumentation consistently produced satisfactory results in all demographics. Anesthesia time is predictably and consistently short, blood loss is consistently negligible, and none of the patients required blood transfusion. The hospital stay is brief for most healthy patients irrespective of age. The results of this study show how drastically the surgery-related morbidity, as well as the economics thereof, can be reduced. The outcomes relat-

ing to patients in the group aged 71 to 90 years are particularly encouraging, given that the population is aging, yet with the desire to continue with physical activities generally enjoyed by younger generations. A prospective randomized controlled trial is required to test the validity of the results of this case series. Such a study should also look at the duration of rehabilitation, return to premorbid occupation, cost of treatment, and complications, in addition to the previously mentioned data.

References

1. Deyo RA, Ciol MA, Cherkin DC, Loeser JD, Bigos SJ. Lumbar spinal fusion. A cohort study of complications, reoperations, and resource use in the Medicare population. *Spine* 1993;18:1463–70.
2. Baker JK, Reardon PR, Reardon MJ, Heggeness MH. Vascular injury in anterior lumbar surgery. *Spine* 1993;18:2227–30.
3. Rihn JA, Patel R, Makda J, et al. Complications associated with single-level transforaminal lumbar interbody fusion. *Spine J* 2009;9:623–9.
4. Scaduto AA, Gamradt SC, Yu WD, Huang J, Delamarter RB, Wang JC. Perioperative complications of threaded cylindrical lumbar interbody fusion devices: Anterior versus posterior approach. *J Spinal Disord Tech* 2003;16:502–7.
5. Kawaguchi Y, Matsui H, Tsuji H. Back muscle injury after posterior lumbar spine surgery. Part 1: Histologic and histochemical analyses in rats. *Spine* 1994;19:2590–7.
6. Kawaguchi Y, Matsui H, Tsuji H. Back muscle injury after posterior lumbar spine surgery. Part 2: Histologic and histochemical analyses in humans. *Spine* 1994;19:2598–602.
7. Ozgur BM, Agarwal V, Nail E, et al. Two-year clinical and radiographic success of minimally invasive lateral transpsoas approach for the treatment of degenerative lumbar conditions. *SAS J* 2010;4:41–6.
8. Rogers WB, Cox CS, Gerber EJ. Minimally invasive treatment (XLIF) of adjacent segment disease after prior lumbar fusions. *Internet J Minim Invasive Spinal Technol* 2010;3.
9. Anand N, Rosemann R, Khalsa B, Baron EM. Mid-term and long-term clinical and functional outcomes of minimally invasive correction and fusion for adults with scoliosis. *Neurosurg Focus* 2010;28:E6.
10. Dakwar E, Cardona RF, Smith DA, et al. Early outcomes and safety of minimally invasive, lateral retroperitoneal transpsoas approach for the adult degenerative scoliosis. *Neurosurg Focus* 2010;28:E8.
11. Villavicencio AT, Burneikiene S, Roeca CM, Nelson EL, Mason A. Minimally invasive versus open transforaminal lumbar interbody fusion. *Surg Neurol Int* 2010;1:12.

12. Wang J, Zhou Y, Zhang ZF, Li CQ, Zheng WJ, Liu J. Comparison of one-level minimally invasive and open transforaminal lumbar interbody fusion in degenerative and isthmic spondylolisthesis grades 1 and 2. *Eur Spine J* 2010;19:1780–4.
13. Schizas C, Tzinieris N, Tsiridis E, Kosmopoulos V. Minimally invasive versus open transforaminal lumbar interbody fusion; evaluating initial experience. *Int Orthop* 2009;33:1693–8.
14. Dhall SS, Wang MY, Mummaneni PV. Clinical and radiographic comparison of mini-open transforaminal lumbar interbody fusion with open transforaminal lumbar interbody fusion in 42 patients with long-term follow-up. *J Neurosurg Spine* 2008;9:560–5.
15. Kambin P. Arthroscopic microdiscectomy. *Arthroscopy* 1992;8:287–95.
16. Osman SG, Marsolais EB. Posterolateral arthroscopic discectomies of the thoracic and lumbar spine. *Clin Orthop Relat Res* 1994:122–9.
17. Osman SG, Marsolais EB. Endoscopic transiliac approach to L5-S1 disc and foramen. A cadaver study. *Spine* 1997;22:1259–63.
18. Oliviera L, Marchi L, Coutinho E, et al. The use rh-BMP2 in stand alone extreme lateral interbody fusion (X-LIF): Clinical and radiological results after 24 months follow-up. *World Spinal Column J* 2010;1:19–25.
19. Deluzio KJ, Lucio JC, Rogers WB. Value and cost in less invasive spinal fusion surgery: Lessons learned from a community hospital. *SAS J* 2010;4:37–40.
20. Knight RQ, Schwaegler P, Hanscom D, Roh J. Direct lateral lumbar interbody fusion for degenerative conditions: Early complication profile. *J Spinal Disord Tech* 2009;22:34–7.
21. Yeung AT, Yeung CA. Minimally invasive techniques for the management of lumbar disc herniation. *Orthop Clin North Am* 2007;38:363–72.
22. Hovorka I, Damotte A, Arcamone H, Argenson C, Boileau P. Lumbar videodiscectomy. Results in a prospective consecutive series [in French]. *Rev Chir Orthop Reparatrice Appar Mot* 2004;90:312–8.
23. Hermantin FU, Petters T, Quartararo L, et al. A prospective, randomized study comparing the results of open discectomy with those of video-assisted arthroscopic microdiscectomy. *J Bone Joint Surg Am* 1999;81:958–65.