

Does Clinical Photography Influence Satisfaction With Surgery in Adult Patients Operated on for Spinal Deformity?

Alejandro Gomez-Rice, Cristina Madrid, Enrique Izquierdo, Fernando Marco-Martínez, Jesús A.F. Tresguerres and Felisa Sanchez-Mariscal

Int J Spine Surg published online 29 December 2020
<https://www.ijssurgery.com/content/early/2020/12/17/7155>

This information is current as of May 17, 2025.

Email Alerts Receive free email-alerts when new articles cite this article. Sign up at:
<http://ijssurgery.com/alerts>

Does Clinical Photography Influence Satisfaction With Surgery in Adult Patients Operated on for Spinal Deformity?

ALEJANDRO GOMEZ-RICE,^{1,2} CRISTINA MADRID,³ ENRIQUE IZQUIERDO,³ FERNANDO MARCO-MARTÍNEZ,^{2,4,5} JESÚS A.F. TRESGUERRES,⁶ FELISA SANCHEZ-MARISCAL⁷

¹Hospital Universitario Ramon y Cajal, Madrid, Spain, ²Complutense University of Madrid, Madrid, Spain, ³Hospital Universitario de Getafe, ⁴Hospital Clínico San Carlos, Madrid, Spain, ⁵Department of Surgery, School of Medicine, Complutense University of Madrid, Madrid, Spain, ⁶Department of Physiology, School of Medicine, Complutense University of Madrid, Madrid, Spain, ⁷Hospital Universitario Rey Juan Carlos, Madrid, Spain

ABSTRACT

Background: Recently published data suggest that showing patients operated on for adolescent idiopathic scoliosis or kyphosis their preoperative and postoperative photographs may enhance their satisfaction and self-image as measured by Scoliosis Research Society Health-Related Quality of Life Questionnaire (SRS-22) scores. No data exist for adult spinal deformity (ASD) surgery. The aim of this study is to determine the effect on patient postoperative satisfaction and self-image of showing adult deformity patients their preoperative and postoperative whole body photographs.

Methods: This was a nonconcurrent prospective study. Patients operated on for ASD with a minimum 2-year postoperative follow-up who had preoperative full-body photographs taken by a professional photographer were included. Two follow-up visits were arranged 7 days apart. In the first visit, patients completed the SRS-22 questionnaire, and full-body standing photographs were taken. In the second visit, patients were asked to complete again questions 4, 6, 10, 14, 19 (self-image), 21, and 22 (satisfaction) of the SRS-22 after seeing their preoperative and postoperative full-body photographs.

Results: Thirty patients (28 female) were included. The median age at surgery was 50 years (26–76). The median follow-up was 51 months (24–120). SRS-22 results at first visit were: activity 2.79 ± 0.75 ; self-image 2.71 ± 0.82 ; pain 2.53 ± 1.10 ; mental health 3.08 ± 0.77 ; satisfaction 3.46 ± 1.20 ; global 2.74 ± 0.72 . SRS-22 results at second visit were: self-image 2.9 ± 0.75 ; satisfaction 4.02 ± 0.97 . After seeing the preoperative and final follow-up photographs, patients experienced an improvement in SRS-22 self-image ($P = .000$) and satisfaction domains ($P = .011$).

Conclusions: In patients operated on for ASD, showing preoperative and postoperative photographs improves patient satisfaction with surgery and self-image.

Level of Evidence: 3.

Clinical Relevance: Our results could be a starting point for introducing full-body clinical photographs as a routine clinical tool in adult deformity patients undergoing surgery.

Other & Special Categories

Keywords: adult spinal deformity, quality of life, patient satisfaction, SRS-22, clinical photography

BACKGROUND

Delivering patient-centered care is an important component of a high-quality health care system.¹ Patient satisfaction after spinal surgery is currently being used as a proxy for quality of care, caregiver performance, and process measures for hospitals.^{2,3} Bearing this in mind, identification of factors that may influence patient satisfaction is important.

Previously conducted studies have shown that adolescents operated for scoliosis⁴ and kyphosis⁵ improved their satisfaction as measured by Scoliosis Research Society Health-Related Quality of Life Questionnaire (SRS-22) scores after showing them

preoperative and postoperative full-spine photographs. The influence of clinical photography in patient satisfaction after adult deformity surgery has not been previously reported.

Although it was designed for patients with adolescent idiopathic scoliosis, the SRS-22 is now widely used as an outcome instrument in patients with adult spinal deformity (ASD),^{2,6–8} and it has proven an excellent 7-day test-retest reliability.⁹

The SRS-22 self-image domain has proven to have a strong correlation with patient satisfaction for adult scoliosis surgery.² The purpose of this study is to determine the effect on patient postoperative satisfaction and self-image of showing adult

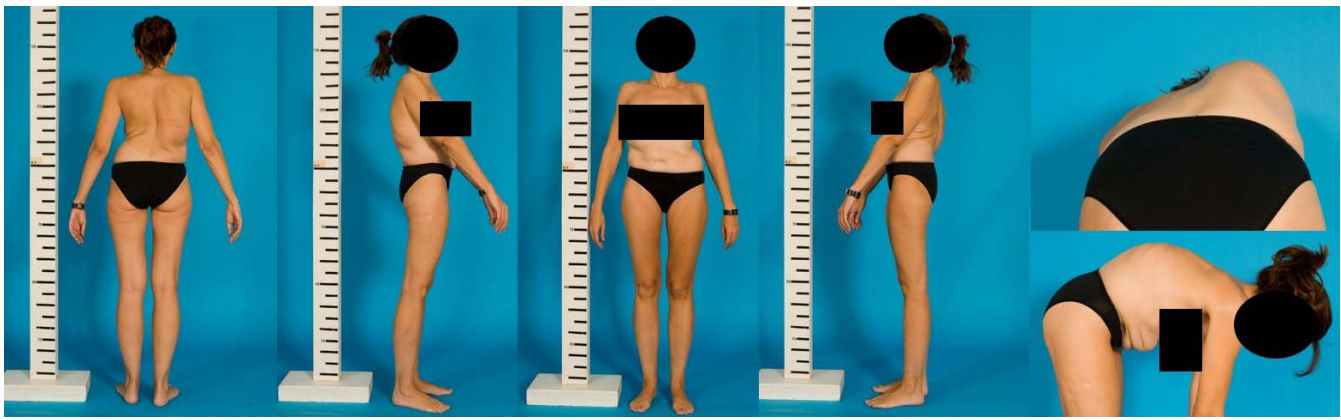

Figure 1. Preoperative photographs of an adult idiopathic scoliosis patient.

deformity patients their preoperative and postoperative whole-body photographs.

METHODS

Study Design

This is a single-center single-surgeon nonconcurrent prospective study approved by the Institutional Research Ethics Committee. Written informed consent was obtained from all patients after they were provided with a detailed information sheet. The null hypothesis is that satisfaction and self-image in patients operated on for adult deformity are not affected by showing patients their preoperative and postoperative full-body photographs.

Subject Inclusion

Inclusion criteria were as follows: age at surgery older than 25 years, having professional clinical photographs taken before surgery, minimum 2-year follow-up after surgery, and having undergone 5 or more levels of fusion for idiopathic or degenerative scoliosis with main Cobb angle greater than 40° , sagittal and/or coronal imbalance greater than 5 cm, T3–T12 kyphosis greater than 80° , and thoracolumbar kyphosis greater than 20° .

Exclusion criteria: tumors or neuromuscular, congenital, or traumatic deformity. Patients with a longer than 10-year follow-up were excluded in order to avoid that the natural aesthetic changes associated with aging could bias self-image assessment.

Out of 130 patients operated on for adult deformity between January 2007 and December 2016, 39 met our inclusion criteria. Two patients were deceased, 2 patients could not be contacted, and 4 patients lived far away and could not

participate for logistic reasons. One patient refused to participate in our study. Thirty patients were finally included. Demographic data and patient's characteristics are summarized in Table 1.

Data Collection

Two outpatient visits were arranged 7 days apart. Data were collected by 2 researchers not involved in patient treatment. In the first visit, informed consent granting permission to use the photographs for this study was obtained from all individual participants included in the study. Subjects completed the SRS-22 questionnaire, and full-body standing photographs were taken by a professional clinical photographer. All photographs—preoperative and postoperative—were taken by the same professional clinical photographer using similar camera settings and lighting in the same room and at the same distance.

Subjects were asked to stand relaxed during the photographic sessions. Photographs were taken from anterior, posterior, and lateral views in both the upright and the forward-bending positions (Figure 1).

In the second visit, patients were shown their preoperative and final follow-up photographs (Figure 2). After seeing the clinical photographs, they were asked again to answer questions 4, 6, 10, 14, 19 (self-image), 21, and 22 (satisfaction) of the SRS-22 questionnaire.

Statistical Methods

The collected data were analyzed using IBM SPSS Statistics 23 for Windows. Descriptive statistics are presented as mean, median, standard deviation, and range. A paired Wilcoxon test was

Table 1. Patient characteristics.

Patient	Age at Surgery, y	Sex	Diagnosis	Surgery	Follow-Up, mo
1	49	Female	IS + Sag. Imb.	L2 PSO; multilevel SPO; T2–iliac fusion	26
2	51	Female	IS + Sag. Imb. + PJK; previous Harrington rod surgery	Multilevel SPO; T2–S1 fusion	27
3	29	Female	IS	T2–L2 fusion	27
4	41	Female	IS + Sag. Imb.	Multilevel SPO; T10–iliac fusion	29
5	66	Female	IS + LSS	T10–iliac fusion	30
6	62	Female	IS + CCSI; previous Harrington rod surgery	L3 asymmetric PSO; T7–iliac fusion	53
7	68	Female	DS + Cor. Imb. + FB	Multilevel SPO; T12–iliac fusion	25
8	62	Female	IS + TLK	T12 VCR; multilevel SPO T2–iliac fusion	35
9	63	Female	DS + degenerative FB	Multilevel SPO; L2–iliac fusion	49
10	33	Female	IS	T3–L4 fusion	51
11	33	Female	IS	Double approach; anterior T4–T9 discectomy; multilevel SPO; T1–L3 fusion through a posterior approach	51
12	73	Female	CCSI + FB	L4 PSO; T8–iliac fusion	50
13	70	Female	Sag. Imb. + FB	L4 PSO; multilevel SPO; T4–iliac fusion	43
14	42	Female	IS + Sag. Imb. + LSS; previous Harrington rod surgery	Multilevel PSO; T12–iliac fusion	58
15	57	Female	IS + FB + Sag. Imb.; previous double-approach surgery	L4 PSO; T2–iliac fusion	94
16	61	Female	Thoracic hyperkyphosis + Sag. Imb.	Multilevel SPO; C5–L4 fusion	68
17	70	Male	Sag. Imb. + FB; previous lumbar fusion	L4 PSO; T10–iliac fusion	24
18	55	Female	Sag. Imb. + FB + LSS; previous lumbar fusion	L4 PSO; T8–iliac fusion	45
19	38	Female	Thoracic hyperkyphosis	Double approach; T7–T10 anterior discectomy and fusion; C5–L3 fusion through a posterior approach	70
20	41	Female	IS	Double approach; T10–L3 anterior discectomy and fusion; T6–L5 fusion through a posterior approach	118
21	48	Female	Thoracic hyperkyphosis	Multilevel SPO; D2–L3 fusion	120
22	26	Female	IS	Multilevel SPO; costoplasty; T2–L4 fusion	119
23	51	Female	IS	Double approach; D11–L4 anterior discectomy and fusion; D10–L4 fusion through posterior approach	118
24	48	Male	Thoracic hyperkyphosis	Multilevel SPO; D2–L3 fusion	42
25	67	Female	DS	Multilevel SPO; T10–L5 fusion	87
26	76	Female	FB + Sag. Imb.	L4 PSO; T10–iliac fusion	39
27	44	Female	IS + FB	Double approach; T10–L2 anterior discectomy and fusion; T10–L5 fusion through posterior approach	93
28	42	Female	IS + FB + Sag. Imb.; previous Harrington rod surgery	L4 PSO; multilevel SPO; T4–S1 fusion	92
29	47	Female	IS + Sag. Imb.	Double approach; D11–L4 anterior discectomy and fusion; T2–S1 fusion through posterior approach	120
30	48	Female	IS + CCSI; previous Harrington rod surgery	Multilevel SPO; T1–iliac fusion	87

Abbreviations: IS, idiopathic scoliosis; Sag. Imb., sagittal imbalance >5 cm; PJK, proximal junctional kyphosis; LSS, lumbar spinal stenosis; CCSI, combined coronal and sagittal imbalance; DS, degenerative scoliosis; Cor. Imb., coronal imbalance >5 cm; FB, flat back; TLK, thoracolumbar kyphosis; PSO, pedicle subtraction osteotomy; SPO, Smith-Petersen osteotomy; VCR, vertebral column resection.

performed to compare prephotography and post-photography SRS-22 results. A *P* value of <0.05 was considered statistically significant.

RESULTS

Thirty patients were included in this study. Twenty-eight female and 2 male subjects were recruited. Median age at surgery was 50 years (range 26–76). Median postoperative follow-up was 51 months (range 24–120). The median number of fused levels was 13 (range 5–18). Six patients were treated by combined anterior and posterior ap-

proach (double approach), while 24 patients were treated by a posterior-only approach.

Eighteen patients were operated on for idiopathic scoliosis, 3 for degenerative scoliosis with a coronal Cobb angle greater than 30°, and 4 patients for thoracic hyperkyphosis. Twelve patients presented with a sagittal imbalance greater than 5 cm, 1 patient with a coronal imbalance greater than 5 cm, and 3 patients with a combined sagittal and coronal imbalance (Table 1). Twenty-two patients underwent primary surgery, while 8 patients had been submitted to previous surgery. Five patients had a

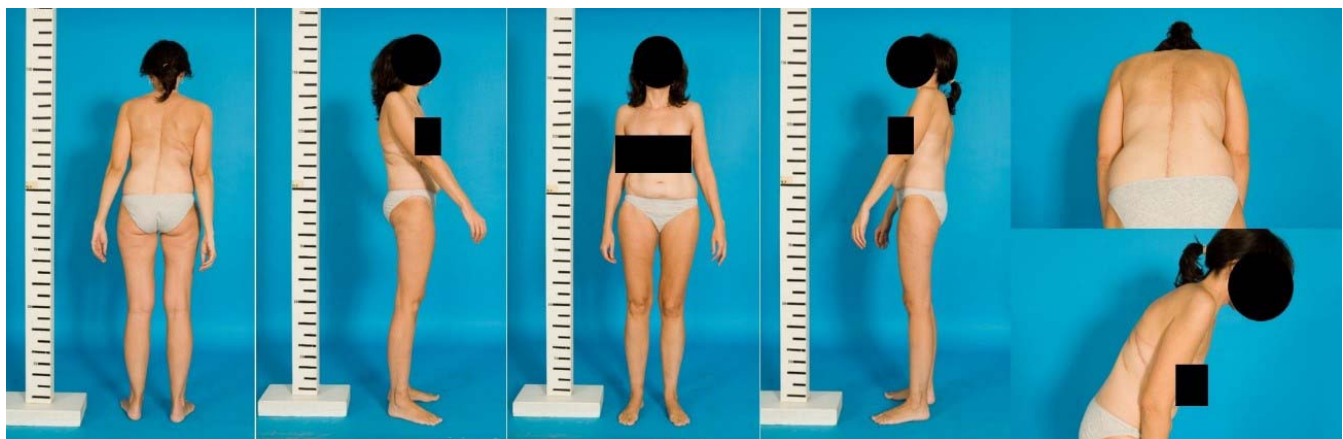

Figure 2. Final follow-up photographs of an adult idiopathic scoliosis patient (same patient as Figure 1).

multilevel fusion mass following a Harrington rod surgery, 1 patient had a history of a previous double approach for deformity surgery, and 2 patients had undergone prior lumbar fusion.

At first visit, before the photographs were taken, SRS-22 scores were as follows: activity 2.79 ± 0.75 ; self-image 2.71 ± 0.82 ; pain 2.53 ± 1.10 ; mental health 3.08 ± 0.77 ; satisfaction 3.46 ± 1.20 ; global 2.74 ± 0.72 . At second visit, after showing patients their preoperative and final follow-up full-body photographs, SRS-22 scores were as follows: self-image 2.9 ± 0.75 ; satisfaction 4.02 ± 0.97 .

A statistically significant improvement was found in both self-image ($P = .000$) and satisfaction ($P = .011$) after showing patients their preoperative and final follow-up full-body photographs (Table 2). The null hypothesis was rejected.

DISCUSSION

Patient-reported outcome questionnaires have become the standard measure for treatment effectiveness after ASD surgery.^{10,11} The SRS-22 questionnaire has been validated in an adult deformity population^{12,13} and is one of the most widely used health-related quality-of-life instruments in adult deformity patients.^{6-8,14-18}

Table 2. Comparison of Scoliosis Research Society Health-Related Quality of Life Questionnaire (SRS-22) satisfaction and self-image domains before and after showing patients their preoperative and final follow-up photographs.

	Prephotography		Postphotography		P
	Mean \pm SD	Min-Max	Mean \pm SD	Min-Max	
SRS-22 satisfaction	3.46 \pm 1.20	1-5	4.02 \pm 0.97	1-5	.011
SRS-22 self-image	2.71 \pm 0.82	1-4.6	2.9 \pm 0.75	2-5	.000

Abbreviations: Min, minimum; Max, maximum.

Although it is unclear if patient satisfaction is associated with the extent of improvement in surgical outcome measures after spinal surgery,⁹ there is no doubt that the use of patient satisfaction metrics represents an important movement toward patient-centered care.^{2,3} However, determinants of patient satisfaction in ASD surgery have proven to be complex.¹⁹

We are unaware of any study that has previously examined if the use of clinical photography may have an influence in patient satisfaction after ASD surgery.

Only 2 prior studies^{4,5} have examined the effects of clinical photography in clinical results after spinal deformity surgery. In 2015, Albayarak et al⁴ compared the SRS-22 scores in 2 groups of 30 patients operated on for adolescent idiopathic scoliosis. Patients in group 1 were shown the preoperative and most recent follow-up photographs, while patients in group 2 were not shown their photographs. They found a statistically significant difference between the groups for question 10 (self-image), 18 (function), and 21 (satisfaction). No significant difference was found between the 2 groups in the SRS-22 domains. One year later,⁵ the same study group conducted a similar study in a population of 40 hyperkyphotic subjects with a mean age of 19 years. They proved that showing patients their preoperative and postoperative photographs improved postoperative patient satisfaction as measured by SRS-22R scores. This second study employed a different methodology using the same patients as the control group. We decided to adopt this approach for our study since we are under the impression that many confounding

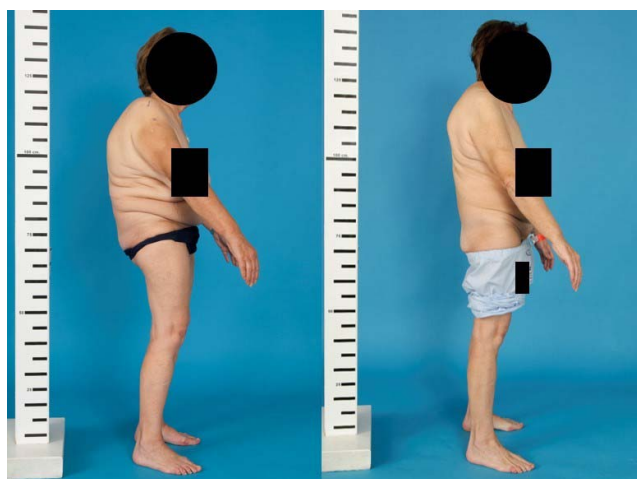


Figure 3. Preoperative and postoperative right-side upright position clinical photographs of a patient operated on for thoracolumbar kyphosis. Patient preoperative picture shows pelvic retroversion and knee flexion as compensatory mechanisms. Final follow-up photograph shows reversal of compensatory mechanisms.

factors can be avoided using the same patients as the control group.²⁰

It should be noted that, contrary to our study, none of these 2 studies used a standardized identical photographic technique including the same equipment, lighting, and background. Another methodological difference that merits comment is that none of these 2 papers used full-body clinical photographs. ASD patients assume many different compensatory postures, including a retroverted pelvis, extended hips, flexed knees, and ankle dorsiflexion.^{21,22} Although in some patients a full-spine photograph may be sufficient to evaluate aesthetic changes after surgery, full-body photographs provide a better appreciation of the entire musculoskeletal system's participation in ASD compensation (Figure 3). Recent efforts to describe compensation in response to malalignment using the pelvis and lower limbs have demonstrated success using full-body stereoradiographic imaging (EOS imaging).^{22,23} Analogously, we used full-body photographs in our study since they allow clinicians and patients to better assess changes in compensatory mechanisms following surgery²¹ (Figure 3).

The main limitation of the present study is the small sample size; however, this is a limitation shared with the 2 previous studies evaluating the influence of clinical photography in patient satisfaction following spinal deformity surgery.^{4,5} Like the vast majority of studies on ASD surgery^{2,6–8,11,12,16–21} our study included patients with deformity caused by different etiological factors. Due to

the heterogeneity in clinical settings, any potential change found in SRS-22 activity, pain, and mental health domains after showing patients their photographs could be difficult to interpret. For this reason, we decided to focus our study on patient satisfaction, bearing in mind that the SRS-22 self-image domain has a strong correlation with patient satisfaction following ASD surgery.² Although our patients experienced improvement in the SRS self-image domain that barely reached a minimal clinically important difference calculated by standard error of measurement,¹⁷ a statistically significant improvement in SRS satisfaction was found. Unfortunately, the present study lacked longitudinal data that would allow us to be sure whether the improvement in patient satisfaction after seeing their photographs will be temporary or long lasting.

Despite these limitations, we provide the first evidence that patient satisfaction and self-image may improve after ASD surgery by the use of clinical photography. This could be an important starting point for introducing full-body clinical photographs as a routine clinical tool in adult deformity patients undergoing surgery.

ACKNOWLEDGMENTS

The authors wish to acknowledge Jose Dominguez Pallas, clinical photographer, for his involvement. This study was approved by the Institutional Research Ethics Committee.

REFERENCES

1. Tsai TC, Orav EJ, Jha AK. Patient satisfaction and quality of surgical care in US hospitals. *Ann Surg*. 2015;261(1):2–8.
2. Gum JL, Bridwell KH, Lenke LG, Bumpass DB, Sugrue PA, Karikari IO, Carreon LY. SRS22R appearance domain correlates most with patient satisfaction after adult deformity surgery to the sacrum at 5-year follow-up. *Spine (Phila Pa 1976)*. 2015;40(16):1297–1302.
3. Truumees E. Appropriate use of satisfaction scores in spine care. *Spine J*. 2013;13(9):1013–1016.
4. Albayrak A, Buyuk AF, Ucpunar H, Balioglu MB, Kargin D, Kaygusuz MA. Pre- and postoperative photographs and surgical outcomes in patients with Lenke type 1 adolescent idiopathic scoliosis. *Spine (Phila Pa 1976)*. 2015;40(7):469–474.
5. Albayrak A, Balioglu MB, Misir A, et al. Preoperative and postoperative photographs and surgical outcomes of patients with kyphosis. *Spine (Phila Pa 1976)*. 2016;41(19):E1185–E1190.
6. Mannion AF, Elfering A, Bago J, et al. Factor analysis of the SRS-22 outcome assessment instrument in patients with adult spinal deformity. *Eur Spine J*. 2018;27(3):685–699.
7. Yoshida G, Boissiere L, Larrieu D, et al. Advantages and

disadvantages of adult spinal deformity surgery and its impact on health-related quality of life. *Spine (Phila Pa 1976)*. 2017;42(6):411–441.

8. Scheer JK, Mundis GM, Klineberg E, et al. Recovery following adult spinal deformity surgery: the effect of complications and reoperation in 149 patients with 2-year follow-up. *Eur Spine J*. 2016;25(8):2612–2621.

9. Bago J, Climent JM, Ey A, Perez-Grueso FJ, Izquierdo E. The Spanish version of the SRS-22 patient questionnaire for idiopathic scoliosis: transcultural adaptation and reliability analysis. *Spine (Phila Pa 1976)*. 2004;29(15):1676–1680.

10. Godil SS, Parker SL, Zuckerman SL, et al. Determining the quality and effectiveness of surgical spine care: patient satisfaction is not a valid proxy. *Spine J*. 2013;13(9):1006–1012.

11. Glassman SD, Schwab F, Bridwell KH, Shaffrey C, Horton W, Hu S. Do 1-year outcomes predict 2-year outcomes for adult deformity surgery? *Spine J*. 2009;9(4):317–322.

12. Bridwell KH, Cats-Baril W, Harrast J, et al. The validity of the SRS-22 instrument in an adult spinal deformity population compared with the Oswestry and SF-12: a study of response distribution, concurrent validity, internal consistency, and reliability. *Spine (Phila Pa 1976)*. 2005;30(4):455–461.

13. Berven S, Deviren V, Demir-Deviren S, Hu SS, Bradford DS. Studies in the modified Scoliosis Research Society Outcomes Instrument in adults: validation, reliability, and discriminatory capacity. *Spine (Phila Pa 1976)*. 2003;28(18):2164–2169.

14. Sánchez-Mariscal F, Gomez-Rice A, Rodríguez-López T, et al. Preoperative and postoperative sagittal plane analysis in adult idiopathic scoliosis in patients older than 40 years of age. *Spine J*. 2017;17(1):56–61.

15. Sánchez-Mariscal F, Gomez-Rice A, Izquierdo E, Pizones J, Zúñiga L, Alvarez-González P. Correlation of radiographic and functional measurements in patients who underwent primary scoliosis surgery in adult age. *Spine (Phila Pa 1976)*. 2012;37(7):592–598.

16. Núñez-Pereira S, Vila-Casademunt A, Domingo-Sabat M, et al. Impact of early unanticipated revision surgery on health-related quality of life after adult spinal deformity surgery. *Spine J*. 2018;18(6):926–934.

17. Crawford CH III, Glassman SD, Bridwell KH, Berven SH, Carreon LY. The minimum clinically important difference

in SRS-22R total score, appearance, activity and pain domains after surgical treatment of adult spinal deformity. *Spine (Phila Pa 1976)*. 2015;40(6):377–381.

18. Crawford CH III, Glassman SD, Bridwell KH, Carreon LY. The substantial clinical benefit threshold for SRS-22R domains after surgical treatment of adult spinal deformity. *Spine Deform*. 2016;4(5):373–377.

19. Hamilton DK, Kong C, Hiratzka J, et al. Patient satisfaction after adult spinal deformity surgery does not strongly correlate with health-related quality of life scores, radiographic parameters, or occurrence of complications. *Spine (Phila Pa 1976)*. 2017;42(10):764–769.

20. Gliner JA, Morgan GA, Harmon RJ. Single-factor repeated-measures designs: analysis and interpretation. *J Am Acad Child Adolesc Psychiatry*. 2002;41(8):1014–1016.

21. Lamartina C, Berjano P. Classification of sagittal imbalance based on spinal alignment and compensatory mechanisms. *Eur Spine J*. 2014;23(6):1177–1189.

22. Jalai CM, Cruz DL, Diebo BG, et al. Full-body analysis of age-adjusted alignment in adult spinal deformity patients and lower-limb compensation. *Spine (Phila Pa 1976)*. 2017;42(9):653–661.

23. Jalai CM, Diebo BG, Cruz DL, et al. The impact of obesity on compensatory mechanisms in response to progressive sagittal malalignment. *Spine J*. 2017;17(5):681–688.

Disclosures and COI: The authors state no conflict interest in relation to this study.

Corresponding Author: Alejandro Gomez-Rice, Hospital Ramon y Cajal, M-607, km. 9.100, 28034, Madrid, Spain. Phone: (+3491368000); Email: alexgomezrice@hotmail.com.

Published 0 Month 2021

This manuscript is generously published free of charge by ISASS, the International Society for the Advancement of Spine Surgery. Copyright © 2021 ISASS. To see more or order reprints or permissions, see <http://ijssurgery.com>.