

Bone Morphogenetic Protein in Anterior Lumbar Interbody Fusions: A Propensity-Matched Medicare Outcome Analysis

Syed I. Khalid, Ravi S. Nunna, Rachyl M. Shanker, Kyle B. Thomson, Rown Parola, Owoicho Adogwa and Ankit I. Mehta

Int J Spine Surg published online 14 June 2022
<https://www.ijssurgery.com/content/early/2022/06/14/8301>

This information is current as of May 17, 2025.

Email Alerts Receive free email-alerts when new articles cite this article. Sign up at:
<http://ijssurgery.com/alerts>

Bone Morphogenetic Protein in Anterior Lumbar Interbody Fusions: A Propensity-Matched Medicare Outcome Analysis

SYED I. KHALID, MD^{1,2}; RAVI S. NUNNA, MD¹; RACHYL M. SHANKER, MD³; KYLE B. THOMSON, BS³; ROWN PAROLA, MS¹; OWOICHO ADOGWA, MD, MPH⁴; AND ANKIT I. MEHTA, MD¹

¹Department of Neurosurgery, University of Illinois at Chicago, Chicago, IL, USA; ²Surgery, Rush University Medical Center, Chicago, IL, USA; ³Chicago Medical School, North Chicago, IL, USA; ⁴Department of Neurosurgery, University of Texas Southwestern Medical Center, Dallas, TX, USA

ABSTRACT

Background: Bone morphogenetic protein (BMP) is a costly agent commonly used in spine surgery. Its effectiveness and complication profile have never been studied in a large, propensity-matched population following its approval by the Food and Drug Administration for use in single-level anterior lumbar interbody fusion (ALIF) surgeries.

Objective: To investigate the rate of symptomatic pseudarthrosis or need for revision surgery after single-level stand-alone ALIFs with and without the use of BMP.

Methods: Medicare Standard Analytic files derived from Medicare parts A and B were used to identify adult patients who underwent single-level ALIF procedures with and without use of BMP between 2004 and 2014. Patients were propensity matched based on their age, gender, and history of diabetes mellitus, hypertension, chronic kidney disease, body mass index greater than 30 kg/m², smoking, rheumatoid arthritis, and osteoporosis. Sensitivity analysis using adjusted multivariate logistic regression models was also performed. The primary outcomes were the rates of symptomatic pseudarthrosis or need for revision surgery.

Results: The propensity-matched population analyzed in this study contained 22,380 patients undergoing single-level ALIF (8971 [40.6%] with BMP and 13,139 [59.4%] without BMP). Both patient groups were balanced at baseline. The rate of symptomatic pseudarthrosis in the propensity-matched analysis was higher in the BMP group (1.9% vs 1.4%, $P < 0.05$). BMP use during single-level ALIFs was associated with 44% increased odds of developing pseudarthrosis (OR 1.44, 95% CI 1.16–1.76). However, there was no statistically significant difference in the rate of revision surgery between groups (3.7% vs 3.5%, $P = 0.49$).

Conclusions: BMP use in single-level ALIFs may be associated with increased risk of symptomatic pseudarthrosis. Large prospective pragmatic trials are needed to corroborate our findings.

Level of Evidence: 3.

Lumbar Spine

Keywords: bone morphogenetic protein, complication, postoperative, fusion, lumbar, pseudarthrosis

INTRODUCTION

Arthrodesis is one of the most common approaches in the treatment of degenerative, infectious, traumatic, developmental, and neoplastic disorders of the spine. The failure of these interventions occurs, in part, due to nonunion or pseudarthrosis, which in turn results in symptomatic pain, deformity, spinal cord compression, or hardware failure.^{1,2} Efforts to reduce the rate of pseudarthrosis have been multifaceted, including implantable electrical stimulation devices, magnetic fields, and pulsed ultrasounds.^{3–5} Additionally, the use of substrates between vertebrae to create more permissive environments for fusion has been a common approach.^{6–11} Traditionally, autologous grafts, most commonly from the iliac crest, have been used;

however, these types of grafts prolong surgery times, increase morbidity, and are specifically associated with hematoma, infection, fracture, and postoperative graft site pain.^{12–17} To reduce these mostly harvest-related complications, bone graft substitutes such as bone marrow aspirate, ceramics, mesenchymal stem cells, demineralized bone matrixes, and human recombinant bone morphogenetic protein (BMP) have been investigated as alternatives to iliac crest bone grafts (ICBGs).^{18–23} In 2002, the approval of recombinant BMP-2, a human cellular growth factor involved in the regulation of bone induction, maintenance, and repair, by the Food and Drug Administration (FDA) for use in single-level anterior lumbar interbody fusion (ALIF) was spurred by early studies demonstrating equivalent

or improved fusion rates with no associated major complications. Despite its cost of \$3500 to \$5500, this approval demonstrated efficacy, and its favorable side effect profile led to use in up to 48% of all ALIFs performed nationally, including off-label use in many spine surgeries.^{6,8–11,24–29} Despite early research demonstrating BMP as a promising alternative to ICBG, several subsequent studies reported conflicting results, suggesting a range of efficacy spanning from inferior to equivalent rates of fusion when compared with ICBG. Other studies have demonstrated significant complications associated with BMP use, including bone resorption or remodeling, retrograde ejaculation, ectopic bone formation, hematoma, and seroma.^{30–41} To this end, we have undertaken a review of all of the cases in which BMP was used for the initially FDA-approved indication—single-level ALIFs—and compared outcomes to patients in which BMP was not used to determine the potential risks and benefits that might be associated with BMP use in Medicare beneficiaries.

METHODS

Data Collection

Medicare Standard Analytic files containing all inpatient and outpatient facility records billed to Medicare derived from Medicare parts A and B, which cover 51 million patients, from January 2004 to December 2014 were retrospectively analyzed. Patients undergoing single-level ALIF were identified based on International Statistical Classification of Diseases, 9th edition (ICD-9), diagnosis codes, ICD-9 procedure codes, and current procedural terminology (CPT) codes.

Patients undergoing ALIF were identified by querying the database for coincidence of the following CPT codes or ICD-9 Procedure Coding System codes: (1) CPT-22558 (anterior interbody fusion, lumbar) or ICD-9–81.06 (lumbar and lumbosacral fusion of the anterior column, anterior technique) and (2) CPT-22851 (application of intrabody device). Only patients undergoing single-level fusions were included in the study. Likewise, patients who received BMP were identified by the concurrent coding indicating its use, CPT-8452 (Figure 1).

Comorbidities

Demographic data for aggregate records included sex and age. ICD-9-CM diagnosis codes were used to identify comorbidities as previously described and

listed in Supplemental Table 1. Comorbidities were noted as follows: body mass index (BMI) greater than 30 kg/m², diabetes mellitus, chronic kidney disease, hypertension, rheumatoid arthritis, osteoporosis, and smoking status.

Complications

Postoperative outcomes of pseudarthrosis and revision surgery were assessed at ≤2 years following surgery. ICD-9-CM codes used to identify these outcomes are listed in Supplemental Table 2.

Statistical Analysis

Descriptive statistics were calculated for age, sex, comorbidities, and postoperative outcomes. Sensitivity analysis using adjusted multivariate logistic regression models was performed to assess factors that may be independently associated with pseudarthrosis and revision following ALIF. Patients undergoing single-level ALIFs with and without BMP were matched with the use of propensity score matching based on age, gender, and history of diabetes mellitus, hypertension, chronic kidney disease, BMI greater than 30 kg/m², smoking, rheumatoid arthritis, and osteoporosis, as previously described.^{42–43}

χ^2 tests were calculated to compare demographic data and comorbidities in each cohort. Odds ratios were calculated to compare pseudarthrosis and revision surgery based on BMP use. The data were analyzed using *R* statistical software (version 3.6.0, 2019, R Foundation, Vienna, Austria).

RESULTS

Descriptive Characteristics

Between January 2004 and December 2014, 22,380 Medicare beneficiaries between the ages of 65 and 84 years with benefit enrollment for at least 2 years underwent single-level ALIFs (Figure 1). The descriptive characteristics and outcomes of the total population are summarized in Supplemental Tables 3 and 4. The propensity-matched population analyzed in this study contained 22,110 patients split into 8971 (40.6%) patients undergoing single-level ALIF with BMP and 13,139 (59.4%) patients undergoing single-level ALIF without the use of BMP. The demographic distribution and postoperative complication rates are summarized in Table 1. The majority of patients undergoing ALIFs with and without BMP were women ($n = 5733$, 63.9% and $n = 8370$, 63.7%, respectively). The

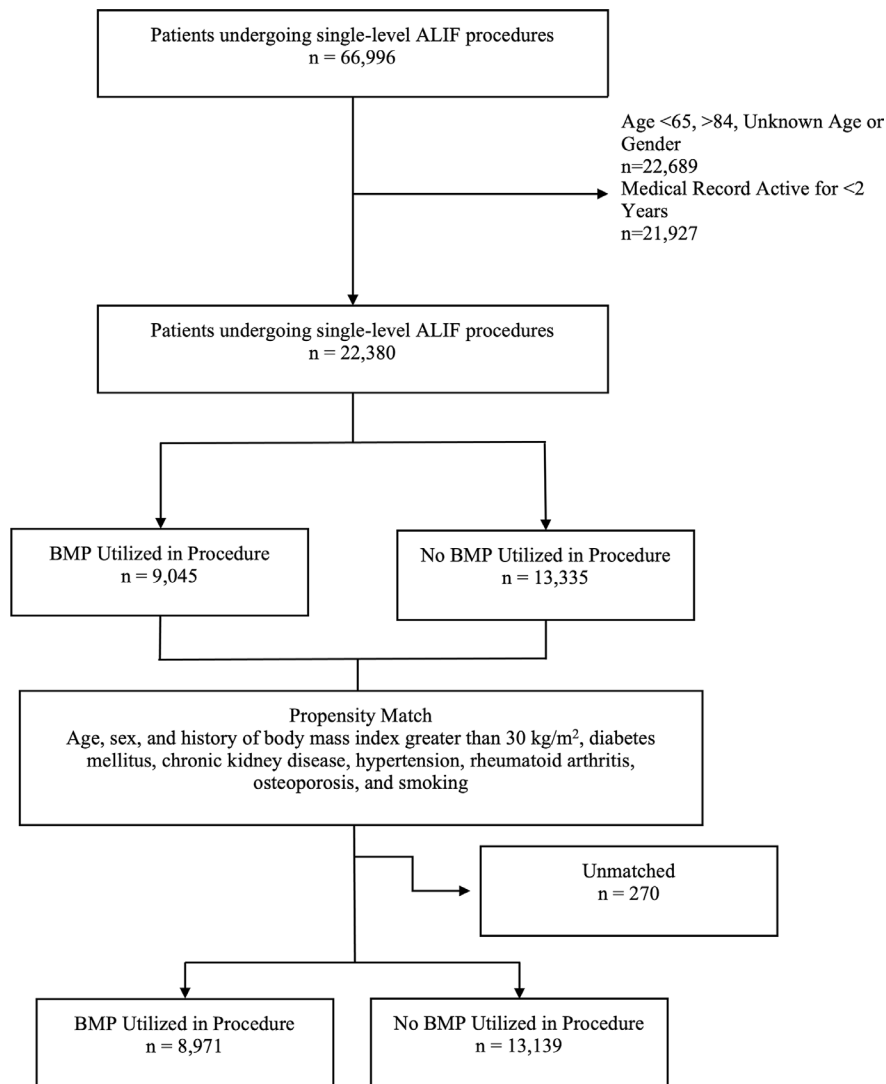


Figure 1. Patient selection flow chart. ALIF, anterior lumbar interbody fusion; BMP, bone morphogenetic protein.

ages of patients in the BMP and no BMP groups were as follows: 3920 (43.7%) and 5388 (41.0%) between 65 and 69 years, 2766 (30.8%) and 4133 (31.5%) between 70 and 74 years, 1658 (18.5%) and 2536 (19.3%) between 75 and 79 years, and 627 (7.0%) and 1082 (8.2%) between 80 and 84 years, respectively.

The rates of BMI >30 (5.2% vs 5.4%, $P = 0.52$), chronic kidney disease (3.8% vs 4.0%, $P = 0.46$), rheumatoid arthritis (3.1% vs 2.8%, $P = 0.24$), osteoporosis (9.1% vs 8.6%, $P = 0.26$), and smoking status (9.5% vs 9.9%, $P = 0.30$) did not differ significantly between patients who underwent single-level ALIFs with and without BMP. Although the rates of diabetes mellitus (19.2% vs 21.4%, $P < 0.05$) and hypertension (51.3% vs 53.1%, $P < 0.05$) were found to be statically different, these differences were not likely of significant clinical importance (Table 1).

Postoperative Outcomes

Although patients undergoing single-level ALIFs with BMP had statistically higher rates of pseudarthrosis (1.9% vs 1.4%, $P < 0.05$) and this difference trended toward statistical significance (log rank $P < 0.001$), the rates of revision surgery (3.7% vs 3.5%, $P = 0.49$) were not significantly different and did not trend toward statistical significance (log rank $P = 0.5$) (Table 1 and Figure 2).

The odds of developing pseudarthrosis (OR 1.44, 95% CI 1.16–1.76) were significantly higher among the BMP cohort. The odds of requiring revision surgery did not significantly differ between cohorts (OR 1.06, 95% CI 0.91–1.22) (Table 2). These effects were confirmed using multivariable regression testing (Supplemental Table S5).

Table 1. Propensity-matched characteristics of patients undergoing single-level anterior lumbar interbody fusion surgeries.

Parameters	Total, n = 22,110	BMP Utilized in Procedure, n = 8971	No BMP Utilized in Procedure, n = 13,139	P Value
Age, n (%)				<0.05
65–69	9308 (42.1)	3920 (43.7)	5388 (41.0)	
70–74	6899 (31.2)	2766 (30.8)	4133 (31.5)	
75–79	4194 (19.0)	1658 (18.5)	2536 (19.3)	
80–84	1709 (7.7)	627 (7.0)	1082 (8.2)	
Sex, n (%)				0.77
Male	8007 (36.2)	3238 (36.1)	4769 (36.3)	
Female	14,103 (63.8)	5733 (63.9)	8370 (63.7)	
Comorbidities, n (%)				
Body mass index >30 kg/m ²	1183 (5.4)	469 (5.2)	714 (5.4)	0.52
Diabetes mellitus	4540 (20.5)	1725 (19.2)	2815 (21.4)	<0.05
Chronic kidney disease	865 (3.9)	340 (3.8)	525 (4.0)	0.46
Hypertension	11,575 (52.4)	4601 (51.3)	6974 (53.1)	<0.05
Rheumatoid arthritis	651 (2.9)	279 (3.1)	372 (2.8)	0.24
Osteoporosis	1947 (8.8)	814 (9.1)	1133 (8.6)	0.26
Smoking	2159 (9.8)	853 (9.5)	1306 (9.9)	0.30
Postoperative complications, n (%)				
Pseudarthrosis	352 (1.6)	174 (1.9)	178 (1.4)	<0.05
Revision surgery	789 (3.6)	330 (3.7)	459 (3.5)	0.49

Abbreviation: BMP, bone morphogenetic protein.

DISCUSSION

A retrospective analysis of a propensity-matched group of 22,110 patients undergoing ALIFs with and without BMP was performed. Patients who received BMP during their procedures had an overall significantly greater tendency for pseudarthrosis; however, they were found to not have a significant difference in their rate of revision surgery at up to 2 years following surgery.

Early studies of BMP use in ALIF and other approaches for lumbar fusion demonstrated greater fusion rates coupled with more favorable side effect profiles; however, some more recent studies have demonstrated no differences in fusion rates.^{1,6,7,9–11,28,32–37,44–55} In a systematic review of 4

prospective randomized control trials of patients undergoing single-level ALIF procedures with and without BMP, Galimberti et al’s analysis of 589 patients found a significant improvement in the rates of fusion in procedures using BMP compared with those without BMP at 2 years (OR 7.08, 95% CI 1.54–32.67, *P* = 0.01).^{7,8,10,39,46} Similarly, a meta-analysis of 19 prospective randomized control trials by Zhang et al of 1852 patients who received single-level ALIF with BMP or with ICBG found significantly increased fusion rates (relative risk [RR] 1.13, 95% CI 1.05–1.23, *P* = 0.001); however, they also found no difference in success of the clinical outcomes (RR 1.04, 95% CI 0.95–1.13, *P* = 0.38).⁵⁶ Conversely, Manzur et al conducted

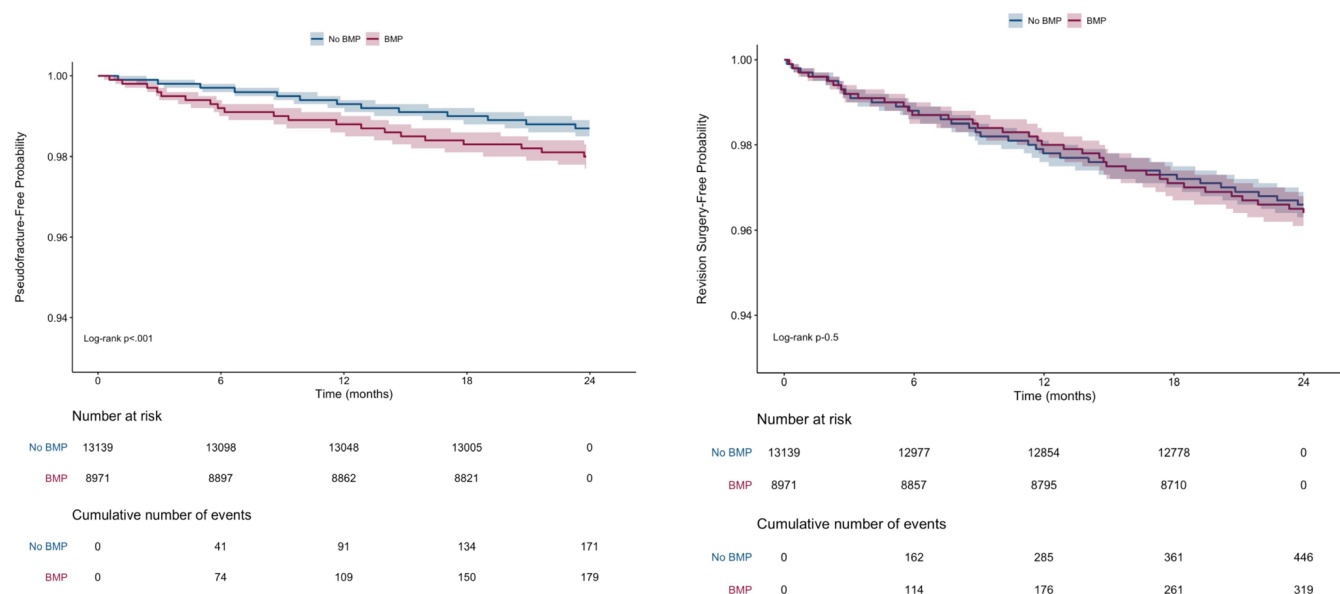


Figure 2. Kaplan-Meier plot for pseudarthrosis and revision surgery occurring within 2 y postoperatively. BMP, bone morphogenetic protein.

Table 2. Propensity-matched odds of complications among bone morphogenetic protein treatment cohort who underwent single-level anterior lumbar interbody fusion surgeries compared with the control cohort.

Postoperative Complications	OR (95% CI)
Pseudarthrosis	1.44 (1.16–1.76)
Revision surgery	1.06 (0.91–1.22)

a systematic review of 55 randomized and nonrandomized prospective, retrospective, and randomized control trials that reported fusion rates of single and multilevel ALIF with or without BMP and autograft vs allograft; this study found no significant difference in the pooled rates of fusion between the 3991 patients who underwent surgeries with and without BMP (94.4% vs 84.8%, $P = 0.106$).⁵⁵ Likewise, a meta-analysis of 5 Medtronic-sponsored randomized control trials by Fu et al whose analysis included 416 patients undergoing single-level ALIF with BMP vs ICBG found no difference in the odds of fusion (OR 1.05, 95% CI 0.88–1.124, $P > 0.05$).³⁶

Studies and case reports have found specific complications associated with BMP in ALIF such as radiculitis, heterotopic ossification, osteolysis, subsidence, soft tissue swelling, local inflammation, sterile cyst formation, and retrograde ejaculation. These adverse events were entirely unreported in the original 5 industry-funded studies promoting the safety and efficacy of BMP in ALIF; however, more recent literature has consistently demonstrated these complications are specific to or exacerbated with BMP use.^{49,57–67} The present study, which to the knowledge of the authors is the largest study on the topic, demonstrates a 1.44-fold increase in the odds of pseudarthrosis with the use of BMP. In addition, the rate of revision surgery was similar with and without the use of BMP, with no trend toward statistical significance (3.7% vs 3.5%, $P = 0.49$). The significant findings of our study may be attributable to the increased capture of adverse events by longitudinal administrative databases compared with clinical trials. These results add to the existing literature demonstrating a lower than previously described efficacy and significant side effect profile.

Global Impact of BMP's Approval for Use in Spine Surgery

Initial data demonstrating the safety and efficacy of the use of BMP in ALIF procedures have spurred its increased use in many off-label indications. Some of these indications, though initially, have demonstrated some promise.^{6–9,11,26,28,44,54,60,68,69} Adverse events, like those that lead to the FDA to release a warning against BMP's use in anterior cervical discectomy and fusion procedures, have warned against its use in some contexts.⁷⁰ Furthermore, its off-label

use in the lumbar spine in posterior, lateral, and oblique approaches and for multiple-level procedures has been controversial in the literature due to varying reports of its safety and efficacy in these contexts.^{6–11,27,34,35,44,50,55,56,71–74}

Finally, taking the recently mounting evidence of lower than previously demonstrated efficacy, significant side effect profile, and significant costs associated with the use of BMP, its use should be more thoroughly evaluated not only in off-label uses in spine surgery but also in its approved use in ALIF surgeries.^{35,75,76}

Limitations

There exist a number of limitations that should be considered in interpreting the results of our investigation. The administrative data found in this study were generated for financial and administrative use rather than clinical research purposes and therefore may vary in detail and accuracy. The application of ICD-9 codes may be subjective as they rely on an interpretation of physician records by the medical reviewer entering the codes and subject to changing coding practices. Notably, there is also no way to assess how pseudarthrosis was specifically diagnosed in our cohort. In order to assess the true rate of pseudarthrosis, a radiologic review would be necessary but is unable to be conducted on the database used. Moreover, we are unable to discern the exact indication, dose, and location of placement in regard to BMP. Of note, the appropriate indication and dose have been poorly specified historically, and dosing regimens may have varied throughout the study period as more literature has been published on adverse effects.^{30,36,37,40} Furthermore, we are unable to discern whether recombinant human bone morphogenetic protein-2 (hBMP-2) or osteogenic protein-1 (OP-1, also termed BMP-7) was used. These administrative data also do not provide qualifiable details on the severity of disease states (eg, spinal alignment), provide patient-reported outcome scores, or allow for standardization of treatment protocols or surgeon technique or expertise (eg, implant type and material), which may mask certain confounding factors. Finally, the use of propensity score matching is by no means a substitute for a prospective trial. While we sought to control demographic factors and comorbidities to the best of our abilities, the groups did vary significantly in regard to malnutrition (8.4% vs 7.9%, $P = 0.03$) and Elixhauser Comorbidity Index (6.86 vs 6.79, $P = 0.046$). These differences were not determined to be clinically significant. While these aforementioned limitations should be carefully considered, we believe the results of our investigation add to the current body of literature pertaining to the use of BMP and pose interesting further areas of research that may be investigated through prospective trials.

CONCLUSIONS

BMP use in single-level ALIFs may be associated with increased risk of symptomatic pseudarthrosis, and no improvement in the rate of need for revision surgery. In addition, its great cost may further depreciate its utility. Large prospective pragmatic trials are needed to corroborate our findings.

REFERENCES

1. Rajae SS, Bae HW, Kanim LEA, Delamarter RB. Spinal fusion in the United States: analysis of trends from 1998 to 2008. *Spine (Phila Pa 1976)*. 2012;37(1):67–76. doi:10.1097/BRS.0b013e31820cccfb
2. de OO, Martins SPR, de LW, Gomes MM. The use of bone morphogenetic proteins (BMP) and pseudarthrosis, a literature review. *Rev Bras Ortop*. 2017;52(2):124–140. doi:10.1016/j.rboe.2016.03.005
3. Kucharzyk DW. A controlled prospective outcome study of implantable electrical stimulation with spinal instrumentation in a high-risk spinal fusion population. *Spine (Phila Pa 1976)*. 1999;24(5):465–468. doi:10.1097/00007632-199903010-00012
4. Linovitz RJ, Pathria M, Bernhardt M, et al. Combined magnetic fields accelerate and increase spine fusion: a double-blind, randomized, placebo controlled study. *Spine (Phila Pa 1976)*. 2002;27(13):1383–1389. doi:10.1097/00007632-200207010-00002
5. Cook SD, Salkeld SL, Msenull, Patron LP, Ryaby JP, Whitecloud TS. Low-intensity pulsed ultrasound improves spinal fusion. *Spine J*. 2001;1(4):246–254. doi:10.1016/s1529-9430(01)00086-9
6. Boden SD, Kang J, Sandhu H, Heller JG. Use of recombinant human bone morphogenetic protein-2 to achieve posterolateral lumbar spine fusion in humans: a prospective, randomized clinical pilot trial: 2002 Volvo Award in clinical studies. *Spine (Phila Pa 1976)*. 2002;27(23):2662–2673. doi:10.1097/00007632-200212010-00005
7. Boden SD, Zdeblick TA, Sandhu HS, Heim SE. The use of rhBMP-2 in interbody fusion cages. Definitive evidence of osteoinduction in humans: A preliminary report. *Spine (Phila Pa 1976)*. 2000;25(3):376–381. doi:10.1097/00007632-200002010-00020
8. Burkus JK, Gornet MF, Dickman CA, Zdeblick TA. Anterior lumbar interbody fusion using rhBMP-2 with tapered interbody cages. *J Spinal Disord Tech*. 2002;15(5):337–349. doi:10.1097/00024720-200210000-00001
9. Burkus JK, Transfeldt EE, Kitchel SH, Watkins RG, Balderston RA. Clinical and radiographic outcomes of anterior lumbar interbody fusion using recombinant human bone morphogenetic protein-2. *Spine (Phila Pa 1976)*. 2002;27(21):2396–2408. doi:10.1097/00007632-200211010-00015
10. Burkus JK, Sandhu HS, Gornet MF, Longley MC. Use of rhBMP-2 in combination with structural cortical allografts: clinical and radiographic outcomes in anterior lumbar spinal surgery. *J Bone Joint Surg Am*. 2005;87(6):1205–1212. doi:10.2106/JBJS.D.02532
11. Dawson E, Bae HW, Burkus JK, Stambough JL, Glassman SD. Recombinant human bone morphogenetic protein-2 on an absorbable collagen sponge with an osteoconductive bulking agent in posterolateral arthrodesis with instrumentation. A prospective randomized trial. *J Bone Joint Surg Am*. 2009;91(7):1604–1613. doi:10.2106/JBJS.G.01157
12. Sasso RC, LeHuec JC, Shaffrey C, Spine Interbody Research Group. Iliac crest bone graft donor site pain after anterior lumbar interbody fusion: a prospective patient satisfaction outcome assessment. *J Spinal Disord Tech*. 2005;18 Suppl:S77–81. doi:10.1097/01.bsd.0000112045.36255.83
13. Robertson PA, Wray AC. Natural history of posterior iliac crest bone graft donation for spinal surgery: a prospective analysis of morbidity. *Spine (Phila Pa 1976)*. 2001;26(13):1473–1476. doi:10.1097/00007632-200107010-00018
14. Boden SD. Overview of the biology of lumbar spine fusion and principles for selecting a bone graft substitute. *Spine (Phila Pa 1976)*. 2002;27(16 Suppl 1):S26–31. doi:10.1097/00007632-200208151-00007
15. Arrington ED, Smith WJ, Chambers HG, Bucknell AL, Davino NA. Complications of iliac crest bone graft harvesting. *Clinical Orthopaedics & Related Research*. 1996;329:300–309. doi:10.1097/00003086-199608000-00037
16. Banwart JC, Asher MA, Hassanein RS. Iliac crest bone graft harvest donor site morbidity. A statistical evaluation. *Spine (Phila Pa 1976)*. 1995;20(9):1055–1060. doi:10.1097/00007632-199505000-00012
17. Laurie SW, Kaban LB, Mulliken JB, Murray JE. Donor-site morbidity after harvesting rib and iliac bone. *Plast Reconstr Surg*. 1984;73(6):933–938. doi:10.1097/00006534-198406000-00014
18. Hsu WK, Nickoli MS, Wang JC, et al. Improving the clinical evidence of bone graft substitute technology in lumbar spine surgery. *Global Spine J*. 2012;2(4):239–248. doi:10.1055/s-0032-1315454
19. HS A, Lynch K, Toth J. Prospective comparison of autograft vs. allograft for adult posterolateral lumbar spine fusion: differences among freeze-dried, frozen, and mixed grafts. *J Spinal Disord*. 1995;8(2):131–135.
20. Gan Y, Dai K, Zhang P, Tang T, Zhu Z, Lu J. The clinical use of enriched bone marrow stem cells combined with porous beta-tricalcium phosphate in posterior spinal fusion. *Biomaterials*. 2008;29(29):3973–3982. doi:10.1016/j.biomaterials.2008.06.026
21. Korovessis P, Koureas G, Zacharatos S, Papazisis Z, Lambiris E. Correlative radiological, self-assessment and clinical analysis of evolution in instrumented dorsal and lateral fusion for degenerative lumbar spine disease. Autograft versus coralline hydroxyapatite. *Eur Spine J*. 2005;14(7):630–638. doi:10.1007/s00586-004-0855-5
22. Moro-Barrero L, Acebal-Cortina G, Suárez-Suárez M, Pérez-Redondo J, Murcia-Mazón A, López-Muñiz A. Radiographic analysis of fusion mass using fresh autologous bone marrow with ceramic composites as an alternative to autologous bone graft. *J Spinal Disord Tech*. 2007;20(6):409–415. doi:10.1097/bsd.0b013e-318030ca1e
23. Vaccaro AR, Stubbs HA, Block JE. Demineralized bone matrix composite grafting for posterolateral spinal fusion. *Orthopedics*. 2007;30(7):567–570. doi:10.3928/01477447-20070701-06
24. Herno A, Airaksinen O, Saari T, Sihvonen T. Surgical results of lumbar spinal stenosis. A comparison of patients with or without previous back surgery. *Spine (Phila Pa 1976)*. 1995;20(8):964–969. doi:10.1097/00007632-199504150-00015
25. Polly D, Ackerman S, Shaffrey C, et al. An economic analysis of bone morphogenetic protein. *Spine J*. 2002;2(5):120. doi:10.1016/S1529-9430(02)00381-9
26. Baskin DS, Ryan P, Sonntag V, Westmark R, Widmayer MA. A prospective, randomized, controlled cervical fusion study using recombinant human bone morphogenetic protein-2 with the CORNERSTONE-SR allograft ring and the ATLANTIS anterior

- cervical plate. *Spine (Phila Pa 1976)*. 2003;28(12):1219–1224. doi:10.1097/01.BRS.0000065486.22141.CA
27. Dimar JR, Glassman SD, Burkus JK, Pryor PW, Hardacker JW, Carreon LY. Clinical and radiographic analysis of an optimized rhBMP-2 formulation as an autograft replacement in posterolateral lumbar spine arthrodesis. *J Bone Joint Surg Am*. 2009;91(6):1377–1386. doi:10.2106/JBJS.H.00200
28. Dimar JR, Glassman SD, Burkus KJ, Carreon LY. Clinical outcomes and fusion success at 2 years of single-level instrumented posterolateral fusions with recombinant human bone morphogenetic protein-2/compression resistant matrix versus iliac crest bone graft. *Spine (Phila Pa 1976)*. 2006;31(22):2534–2539. doi:10.1097/01.brs.0000240715.78657.81
29. Ong KL, Villarraga ML, Lau E, Carreon LY, Kurtz SM, Glassman SD. Off-label use of bone morphogenetic proteins in the United States using administrative data. *Spine (Phila Pa 1976)*. 2010;35(19):1794–1800. doi:10.1097/BRS.0b013e3181ecf6e4
30. Benglis D, Wang MY, Levi AD. A comprehensive review of the safety profile of bone morphogenetic protein in spine surgery. *Neurosurgery*. 2008;62(5 Suppl 2):S423–31. doi:10.1227/01.neu.0000326030.24220.d8
31. Lao L, Cohen JR, Buser Z, et al. Trends analysis of rhBMP2 utilization in single-level anterior lumbar interbody fusion in the United States. *Global Spine J*. 2018;8(2):137–141. doi:10.1177/2192568217701119
32. Guppy KH, Harris J, Chen J, Paxton EW, Alvarez J, Bernbeck J. Reoperation rates for symptomatic nonunions in posterior cervical (subaxial) fusions with and without bone morphogenetic protein in a cohort of 1158 patients. *J Neurosurg Spine*. 2016;24(4):556–564. doi:10.3171/2015.7.SPINE15353
33. Guppy KH, Harris J, Chen J, Paxton EW, Bernbeck JA. Reoperation rates for symptomatic nonunions in posterior cervicothoracic fusions with and without bone morphogenetic protein in a cohort of 450 patients. *J Neurosurg Spine*. 2016;25(3):309–317. doi:10.3171/2016.1.SPINE151330
34. Guppy KH, Paxton EW, Harris J, Alvarez J, Bernbeck J. Does bone morphogenetic protein change the operative nonunion rates in spine fusions? *Spine (Phila Pa 1976)*. 2014;39(22):1831–1839. doi:10.1097/BRS.0000000000000534
35. Esmail N, Buser Z, Cohen JR, et al. Postoperative complications associated with rhBMP2 use in posterior/posterolateral lumbar fusion. *Global Spine J*. 2018;8(2):142–148. doi:10.1177/2192568217698141
36. Fu R, Selph S, McDonagh M, et al. Effectiveness and harms of recombinant human bone morphogenetic protein-2 in spine fusion: a systematic review and meta-analysis. *Ann Intern Med*. 2013;158(12):890–902. doi:10.7326/0003-4819-158-12-201306180-00006
37. Simmonds MC, Brown JVE, Heirs MK, et al. Safety and effectiveness of recombinant human bone morphogenetic protein-2 for spinal fusion: a meta-analysis of individual-participant data. *Ann Intern Med*. 2013;158(12):877–889. doi:10.7326/0003-4819-158-12-201306180-00005
38. Mariscal G, Nuñez JH, Barrios C, Domenech-Fernández P. A meta-analysis of bone morphogenetic protein-2 versus iliac crest bone graft for the posterolateral fusion of the lumbar spine. *J Bone Miner Metab*. 2020;38(1):54–62. doi:10.1007/s00774-019-01025-9
39. Galimberti F, Lubelski D, Healy AT, et al. A systematic review of lumbar fusion rates with and without the use of rhBMP-2. *Spine (Phila Pa 1976)*. 2015;40(14):1132–1139. doi:10.1097/BRS.0000000000000971
40. Carragee EJ, Mitsunaga KA, Hurwitz EL, Scuderi GJ. Retrograde ejaculation after anterior lumbar interbody fusion using rhBMP-2: a cohort controlled study. *Spine J*. 2011;11(6):511–516. doi:10.1016/j.spinee.2011.02.013
41. Comer GC, Smith MW, Hurwitz EL, Mitsunaga KA, Kessler R, Carragee EJ. Retrograde ejaculation after anterior lumbar interbody fusion with and without bone morphogenetic protein-2 augmentation: a 10-year cohort controlled study. *Spine J*. 2012;12(10):881–890. doi:10.1016/j.spinee.2012.09.040
42. Khalid SI, Carlton A, Wu R, Kelly R, Peta A, Adogwa O. Outpatient and inpatient readmission rates of 1- and 2-level anterior cervical discectomy and fusion surgeries. *World Neurosurg*. 2019;126:e1475–e1481. doi:10.1016/j.wneu.2019.03.124
43. DE H, Imai K, King G, MatchIt SEA. Nonparametric pre-processing for parametric causal inference. *J Stat Softw*. 2011;42(8). doi:10.18637/jss.v042.i08
44. Haid RW, Branch CL, Alexander JT, Burkus JK. Posterior lumbar interbody fusion using recombinant human bone morphogenetic protein type 2 with cylindrical interbody cages. *Spine J*. 2004;4(5):527–538. doi:10.1016/j.spinee.2004.03.025
45. Singh K, Smucker JD, Gill S, Boden SD. Use of recombinant human bone morphogenetic protein-2 as an adjunct in posterolateral lumbar spine fusion: A prospective CT-scan analysis at one and two years. *J Spinal Disord Tech*. 2006;19(6):416–423. doi:10.1097/00024720-200608000-00008
46. Slosar PJ, Josey R, Reynolds J. Accelerating lumbar fusions by combining rhBMP-2 with allograft bone: a prospective analysis of interbody fusion rates and clinical outcomes. *Spine J*. 2007;7(3):301–307. doi:10.1016/j.spinee.2006.10.015
47. Dhall SS, Wang MY, Mummaneni PV. Clinical and radiographic comparison of mini-open transforaminal lumbar interbody fusion with open transforaminal lumbar interbody fusion in 42 patients with long-term follow-up. *J Neurosurg Spine*. 2008;9(6):560–565. doi:10.3171/SPI.2008.9.08142
48. Mummaneni PV, Pan J, Haid RW, Rodts GE. Contribution of recombinant human bone morphogenetic protein—2 to the rapid creation of interbody fusion when used in transforaminal lumbar interbody fusion: a preliminary report. *Journal of Neurosurgery*. 2004;1(1):19–23. doi:10.3171/spi.2004.1.1.0019
49. Rihn JA, Patel R, Makda J, et al. Complications associated with single-level transforaminal lumbar interbody fusion. *Spine J*. 2009;9(8):623–629. doi:10.1016/j.spinee.2009.04.004
50. Glassman SD, Carreon LY, Djurasovic M, et al. RhBMP-2 versus iliac crest bone graft for lumbar spine fusion: a randomized, controlled trial in patients over sixty years of age. *Spine (Phila Pa 1976)*. 2008;33(26):2843–2849. doi:10.1097/BRS.0b013e318190705d
51. Katayama Y, Matsuyama Y, Yoshihara H, et al. Clinical and radiographic outcomes of posterolateral lumbar spine fusion in humans using recombinant human bone morphogenetic protein-2: an average five-year follow-up study. *Int Orthop*. 2009;33(4):1061–1067. doi:10.1007/s00264-008-0600-5
52. Cho JH, Lee JH, Yeom JS, et al. Efficacy of Escherichia coli-derived recombinant human bone morphogenetic protein-2 in posterolateral lumbar fusion: an open, active-controlled, randomized, multicenter trial. *Spine J*. 2017;17(12):1866–1874. doi:10.1016/j.spinee.2017.06.023
53. Hurlbert RJ, Alexander D, Bailey S, et al. rhBMP-2 for posterolateral instrumented lumbar fusion: a multicenter prospective randomized controlled trial. *Spine (Phila Pa 1976)*. 2013;38(25):2139–2148. doi:10.1097/BRS.0000000000000007

54. Glassman SD, Dimar JR, Burkus K, et al. The efficacy of rhBMP-2 for posterolateral lumbar fusion in smokers. *Spine (Phila Pa 1976)*. 2007;32(15):1693–1698. doi:10.1097/BRS.0b013e318074c366
55. Manzur M, Virk SS, Jivanelli B, et al. The rate of fusion for stand-alone anterior lumbar interbody fusion: A systematic review. *Spine J*. 2019;19(7):1294–1301. doi:10.1016/j.spinee.2019.03.001
56. Zhang H, Wang F, Ding L, et al. A meta analysis of lumbar spinal fusion surgery using bone morphogenetic proteins and autologous iliac crest bone graft. *PLoS ONE*. 2014;9(6). doi:10.1371/journal.pone.0097049
57. Carragee EJ, Hurwitz EL, Weiner BK. A critical review of recombinant human bone morphogenetic protein-2 trials in spinal surgery: emerging safety concerns and lessons learned. *Spine J*. 2011;11(6):471–491. doi:10.1016/j.spinee.2011.04.023
58. Makanji HS, Bhalla A, Bono CM. BMP-2 with anterior lumbar interbody fusion: clinical usage and recent controversies. *Seminars in Spine Surgery*. 2016;28(4):233–238. doi:10.1053/j.semss.2016.08.006
59. Helgeson MD, Lehman RA, Patzkowski JC, Dmitriev AE, Rosner MK, Mack AW. Adjacent vertebral body osteolysis with bone morphogenetic protein use in transforaminal lumbar interbody fusion. *Spine J*. 2011;11(6):507–510. doi:10.1016/j.spinee.2011.01.017
60. Burkus JK, Heim SE, Gornet MF, Zdeblick TA. Is infuse bone graft superior to autograft bone? An integrated analysis of clinical trials using the LT-CAGE lumbar tapered fusion device. *Journal of Spinal Disorders & Techniques*. 2003;16(2):113–122. doi:10.1097/00024720-200304000-00001
61. Carragee EJ, Ghanayem AJ, Weiner BK, Rothman DJ, Bono CM. A challenge to integrity in spine publications: years of living dangerously with the promotion of bone growth factors. *Spine J*. 2011;11(6):463–468. doi:10.1016/j.spinee.2011.06.001
62. Carragee EJ, Bono CM, Scuderi GJ. Pseudomorbidity in iliac crest bone graft harvesting: the rise of rhBMP-2 in short-segment posterior lumbar fusion. *Spine J*. 2009;9(11):873–879. doi:10.1016/j.spinee.2009.09.001
63. Knox JB, Dai JM, Orchowski J. Osteolysis in transforaminal lumbar interbody fusion with bone morphogenetic protein-2. *Spine (Phila Pa 1976)*. 2011;36(8):672–676. doi:10.1097/BRS.0b013e3181e030e0
64. Mroz TE, Wang JC, Hashimoto R, Norvell DC. Complications related to osteobiologics use in spine surgery: a systematic review. *Spine (Phila Pa 1976)*. 2010;35(9 Suppl):S86–104. doi:10.1097/BRS.0b013e3181d81ef2
65. Perri B, Cooper M, Laurysen C, Anand N. Adverse swelling associated with use of rh-BMP-2 in anterior cervical discectomy and fusion: a case study. *Spine J*. 2007;7(2):235–239. doi:10.1016/j.spinee.2006.04.010
66. Vaidya R, Weir R, Sethi A, Meisterling S, Hakeos W, Wybo CD. Interbody fusion with allograft and rhBMP-2 leads to consistent fusion but early subsidence. *J Bone Joint Surg Br*. 2007;89(3):342–345. doi:10.1302/0301-620X.89B3.18270
67. Williams BJ, Smith JS, Fu KMG, et al. Does bone morphogenetic protein increase the incidence of perioperative complications in spinal fusion? A comparison of 55,862 cases of spinal fusion with and without bone morphogenetic protein. *Spine (Phila Pa 1976)*. 2011;36(20):1685–1691. doi:10.1097/BRS.0b013e318216d825
68. Boakye M, Mummaneni PV, Garrett M, Rodts G, Haid R. Anterior cervical discectomy and fusion involving a polyetheretherketone spacer and bone morphogenetic protein. *J Neurosurg Spine*. 2005;2(5):521–525. doi:10.3171/spi.2005.2.5.0521
69. Burkus JK, Sandhu HS, Gornet MF, Longley MC. Use of rhBMP-2 in combination with structural cortical allografts: clinical and radiographic outcomes in anterior lumbar spinal surgery. *J Bone Joint Surg Am*. 2005;87(6):1205–1212. doi:10.2106/JBJS.D.02532
70. Food and Drug Administration. FDA Public Health Notification: Life-threatening complications associated with recombinant human bone morphogenetic protein in cervical spine fusion. 2008.
71. Andersen T, Christensen FB, Laursen M, Høy K, Hansen ES, Bünger C. Smoking as a predictor of negative outcome in lumbar spinal fusion. *Spine (Phila Pa 1976)*. 2001;26(23):2623–2628. doi:10.1097/00007632-200112010-00018
72. Hindoyan K, Tilan J, Buser Z, et al. A retrospective analysis of complications associated with bone morphogenetic protein 2 in anterior lumbar interbody fusion. *Global Spine J*. 2017;7(2):148–153. doi:10.1177/2192568217694010
73. Cahill KS, Chi JH, Day A, Claus EB. Prevalence, complications, and hospital charges associated with use of bone-morphogenetic proteins in spinal fusion procedures. *JAMA*. 2009;302(1):58–66. doi:10.1001/jama.2009.956
74. Laurie AL, Chen Y, Chou R, Fu R. Meta-analysis of the impact of patient characteristics on estimates of effectiveness and harms of recombinant human bone morphogenetic protein-2 in lumbar spinal fusion. *SPINE (Phila Pa 1976)*. 2016;41(18):E1115–E1123. doi:10.1097/BRS.0000000000001580
75. Dagostino PR, Whitmore RG, Smith GA, Maltenfort MG, Ratliff JK. Impact of bone morphogenetic proteins on frequency of revision surgery, use of autograft bone, and total hospital charges in surgery for lumbar degenerative disease: review of the Nationwide Inpatient Sample from 2002 to 2008. *Spine J*. 2014;14(1):20–30. doi:10.1016/j.spinee.2012.10.035
76. Singh K, Nandyala SV, Marquez-Lara A, Fineberg SJ. Epidemiological trends in the utilization of bone morphogenetic protein in spinal fusions from 2002 to 2011. *Spine (Phila Pa 1976)*. 2014;39(6):491–496. doi:10.1097/BRS.0000000000000167

Funding: The authors received no financial support for the research, authorship, and/or publication of this article.

Declaration of Conflicting Interests: The authors report no conflicts of interest in this work.

IRB Approval: The present study was deepend to be exempt from institutional review board review by our institution

Corresponding Author: Syed I. Khalid, University of Illinois at Chicago, Chicago, IL, USA; syed.khalid@me.com

Published 10 May 2022

This manuscript is generously published free of charge by ISASS, the International Society for the Advancement of Spine Surgery. Copyright © 2022 ISASS. To see more or order reprints or permissions, see <http://ijssurgery.com>.