

C1-C2 Facet Joint Penetration by C2 Pedicle Screws: Influence of Local Anatomy, Bone Mineral Density, and Screw Length

Alexander Rosinski, Cristian Balcescu, Ian Singleton, Ashish Mittal, Khalid Odeh, Victor Ungurean, Jeremi Leasure and Dimitriy Kondrashov

Int J Spine Surg published online 22 November 2022
<https://www.ijssurgery.com/content/early/2022/11/20/8386>

This information is current as of May 10, 2025.

Email Alerts Receive free email-alerts when new articles cite this article. Sign up at:
<http://ijssurgery.com/alerts>

C1-C2 Facet Joint Penetration by C2 Pedicle Screws: Influence of Local Anatomy, Bone Mineral Density, and Screw Length

ALEXANDER ROSINSKI, MS, MD¹; CRISTIAN BALCESCU, MD¹; IAN SINGLETON, MD¹; ASHISH MITTAL, MD¹; KHALID ODEH, MD¹; VICTOR UNGUREAN²; JEREMI LEASURE, MSE²; AND DIMITRIY KONDRASHOV, MD^{1,3}

¹St. Mary's Medical Center, San Francisco Orthopaedic Residency Program, San Francisco, CA, USA; ²The Taylor Collaboration, San Francisco, CA, USA; ³San Francisco Spine Surgeons, San Francisco, CA, USA

ABSTRACT

Background: A challenge of C2 pedicle screw placement is to avoid penetration into the C1-C2 facet joint, as this may alter normal biomechanics and accelerate joint degeneration. Our objective was to clarify how local anatomy and surgical technique may relate to C2 pedicle screw penetration into the C1-C2 facet joint.

Methods: C2 pedicle screws were inserted using a fluoroscopically assisted freehand technique. Independent fellowship-trained spine surgeons blindly reviewed intraoperative fluoroscopic and postoperative computed tomography (CT) images for evidence of facet joint penetration (FJP). C2 pedicle morphometry, the sagittal angle of the facet joint, axial and sagittal pedicle screw angles, and screw length were measured on the relevant CT images.

Results: A total of 34 patients fulfilled the study criteria, and a total of 68 C2 pedicle screws were placed. Eight screws (16%) penetrated the C1-C2 facet joint. The mean sagittal angle of the C1-C2 facet joint was significantly lower in the FJP group compared with the non-FJP group. The mean sagittal angle of the screws was significantly higher in the FJP group compared with the non-FJP group. The mean screw length was significantly greater for screws causing FJP compared with the non-FJP group. The mean axial screw angle was significantly lower in the FJP group compared with the non-FJP group. Pedicle width, length, height, and transverse angle were not significantly associated with FJP. Independent reviewers were able to identify FJP on intraoperative fluoroscopic imaging in 2 out of 8 cases.

Conclusion: Lower sagittal angle of the facet joint, higher sagittal angle of the pedicle screw, and screw length >24 mm are associated with higher risk of C1-C2 FJP. When placing C2 pedicle screws under these conditions, caution should be taken to avoid FJP.

Clinical Relevance: Several anatomical and technical factors may increase the risk of C1-C2 FJP during placement of C2 pedicle screws using a fluoroscopically assisted freehand technique, underscoring the importance of preoperative planning and limiting screw length.

Level of Evidence: 3.

Cervical Spine

Keywords: C2 pedicle screws, cervical spine surgery, facet penetration, cervical fusion

INTRODUCTION

The need to obtain fixation at the C2 vertebral level can result from traumatic, inflammatory, neoplastic, congenital, iatrogenic, or degenerative disorders. Options for C2 fixation include pedicle, pars, transarticular (Magerl), and translaminar screws as well as spinous process wiring. While the precise indications for each type of fixation are complex and dependent on a given patient's vascular and osseous anatomy, length of construct, amount of correction, and surgeon's experience, pedicle screws are often preferred and may provide a superior biomechanical fixation.¹ C2 transarticular screw placement is not anatomically feasible in up to 10% to 23% of patients due to variations

in vertebral artery anatomy or a large vertebral artery groove (high-riding or aberrant vertebral artery). Translaminar screws require intact posterior elements, adequate laminar thickness, and a stable anterior spinal column.²⁻⁴ Furthermore, clinical studies have reported lower rates of pseudarthrosis and hardware failure in patients treated with C1 lateral mass and C2 pedicle screws (Harms technique) compared with those treated with pars and translaminar screw constructs.⁵⁻⁸

The instrumentation of the C2 pedicle is particularly challenging due to the vascular, neurological, and osseous anatomy of the segment. The vertebral artery typically lies immediately lateral and inferior to the pedicle as it makes a right angle turn within the lateral mass of C2.⁵ The anatomical variants of the vertebral

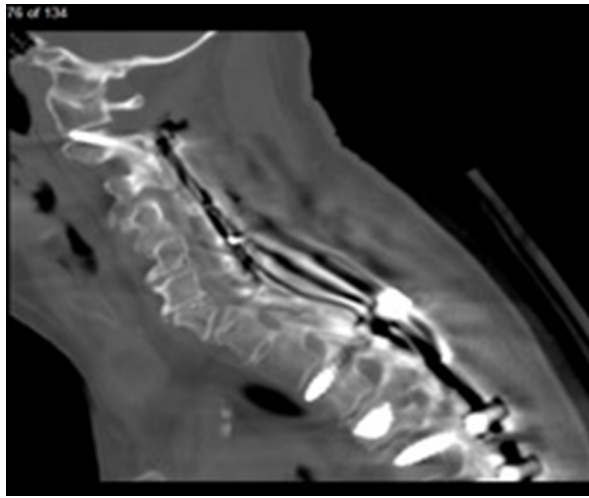


Figure 1. Sagittal computed tomography image of C1-C2 facet joint penetration.

artery are relatively common, especially in patients with congenital skeletal anomalies such as os odontoideum.^{9,10} Narrow pedicle width and a high-riding vertebral artery may complicate screw placement in up to 23% and 31% of patients, respectively.¹¹⁻¹⁴ Another challenge of C2 pedicle screw placement is to avoid penetration into the C1-C2 facet joint, unless C1-2 fusion is desired, as this may alter normal biomechanics and accelerate joint degeneration at the C1-C2 motion segment (Figure 1).¹⁵⁻¹⁷ Direct facet joint violation, instability, and C1-C2 kyphosis may also result in painful motion postoperatively.¹⁸⁻²⁰ For example, facet joint penetration (FJP) of lateral mass screws during cervical laminoplasty, a motion preserving technique of cervical decompression, has been associated with significantly increased rates of axial neck pain and stiffness.^{17,21,22} The reported incidence of C1-C2 FJP during freehand placement of C2 pedicle screws ranges from 4% to 20%.²³⁻²⁵ To the authors' knowledge, however, no previous study has investigated the anatomical and technical risk factors associated with C2 pedicle screw FJP.

The purpose of the present study was to clarify how penetration of C2 pedicle screw into the C1-C2 facet joint is related to the C2 pedicle morphometry, the sagittal angle of the C1-C2 facet joint, sagittal and axial pedicle screw insertion angles, bone mineral density of C2, and screw length. We postulated that more vertically oriented C1-C2 facet joints, softer bone, and longer pedicle screws may predispose to inadvertent C1-C2 FJP. In addition, we report on the incidence of FJP undetected on intraoperative fluoroscopic imaging and subsequently confirmed on postoperative computed tomography (CT).

METHODS

An institutional review board approval was obtained prior to the initiation of the study. The institutional review board had granted a waiver of informed consent for this study. A retrospective radiographic review was conducted on all patients who underwent a posterior cervical fixation with C2 pedicle screws at a single tertiary care urban teaching hospital from 1 January 2010 to 1 April 2022 and had intraoperative fluoroscopy and postoperative CT imaging available for evaluation. Exclusion criteria included a lack of postoperative CT images of the cervical spine. Pediatric patients were not included in the study.

Surgical Technique

C2 pedicle screws were inserted using the freehand technique with fluoroscopic confirmation. First, general endotracheal anesthesia was achieved, and intraoperative somatosensory-evoked potential monitoring was initiated to detect any changes during the procedure. A wine cork or radiolucent bite block was placed to help visualize the C2 pedicles on the intraoperative fluoroscopic open mouth view (Figure 2). A Mayfield head clamp was applied with 60 lbs/inch of torque. The patient was placed in reverse Trendelenburg position on a Jackson or ProAxis table with the patient's arms at their sides. A posterior midline approach to the cervical spine was then performed. The C1-C2 interlaminar window was exposed and the vascular plexus of epidural sinusoids packed with Floseal hemostatic matrix (Baxter) and Cottonoid patties. A straight freer or Penfield 2 elevator was used to palpate the cephalad and medial aspect of the C2 pedicle and guide the placement of the starting hole. A small burr (typically 1.7 mm) was then used to make a unicortical pilot hole. A cervical pedicle awl was used to cannulate the C2 pedicle to a depth of approximately 10 mm. The tip was angled facing medially away from the vertebral artery. At the same time, an assistant held a freer or Penfield 2 elevator against the medial aspect of the C2 pedicle to help guide the angulation of the awl in the axial and sagittal planes. At this point, a lateral view and an open mouth fluoroscopic views were obtained. On the open mouth view, we ensured that the tip of the awl started to enter the outline of the C2 pedicle. The lateral view was used to check the cephalad angulation of the awl within the pedicle. The awl was advanced to approximately 20 to 24 mm in depth. If unable to advance, the trajectory was changed, and the awl was rotated outside of the pedicle tract 180°. If the awl continued to



Figure 2. A wine cork placed in the mouth to help visualize the C2 pedicles on the intraoperative open mouth view.

be unable to advance, but on lateral view the trajectory appeared correct, a shorter screw was used. The open mouth view was then rechecked to ensure that there was no violation of the C1-C2 facet, and the lateral view was rechecked to ensure that the awl was parallel to the axis of the pedicle. The inside of the pedicle was then palpated with a balltip probe to ensure no breaches in the pedicle wall and a solid bottom. The pedicle was under-tapped in softer bone or tapped line to line in stronger bone. The balltip probe was again used to feel the inside of the pedicle. The pedicle screw was then advanced. If unable to advance past 14 to 16 mm despite adjustments in trajectory, a shorter pedicle or a pars screw was placed. If possible, bilateral instrumentation was performed simultaneously to save time on the above steps.

Independent reviewers blindly reviewed the intraoperative fluoroscopic images for evidence of FJP. Presence or absence of FJP on CT imaging was evaluated according to a modified classification described by Gertzbein and Robbins. Grade 0 screws are positioned entirely within bone. Grade 1 screws had a breach of the pedicle with less than 50% of the diameter of the screw entering the cortex. Grade 2 screws had greater than 50% of the screw diameter entering the cortex.^{26,27} The Gertzbein and Robbins grades were independently reviewed by a fellowship-trained spine surgeon as well as senior residents to determine inter- and intrarater reliability.

Morphometric Measurements

C2 pedicle morphometry including pedicle width, length, height, and transverse angle was measured using preoperative CT images. The sagittal angle of the facet joint, axial and sagittal pedicle screw angles, and screw length were measured using postoperative CT images. The sagittal angle of the C1-C2 facet joint and sagittal screw angle were measured relative to the inferior endplate of C2 on CT images to reduce the effects of head position and/or variations in cervical lordosis (Figure 3).^{28,29} The axial angle of each pedicle screw was measured relative to the vertebral midline on axial CT images to account for the presence of any vertebral rotation (Figure 4). The bone mineral density of the C2 vertebral body was assessed using preoperative CT images. Hounsfield units obtained from CT images of the lumbar spine have been previously shown to correlate with dual-energy x-ray absorptiometry *T* scores.³⁰ CT measurements less than 100 Hounsfield units correlate with osteopenia or *T* scores less than -1.0.

Statistical Methods

A 2-tailed unpaired *t* test was used to evaluate any differences between the non-FJP and FJP groups. The cutoff point for significance was defined as $P < 0.05$. Inter- and intrarater reliability were obtained by using Kappa statistical analysis. All analyses were performed using JMP version 15.0 (SAS Institute, Cary, NC).

RESULTS

Out of the 53 patients who had bilateral C2 screws placed during the study period, 34 patients met the inclusion criteria, with a total of 68 C2 pedicle screws placed. The remainder of the patients had incomplete imaging and were excluded from the study. Seventeen patients were diagnosed with cervical spondylotic

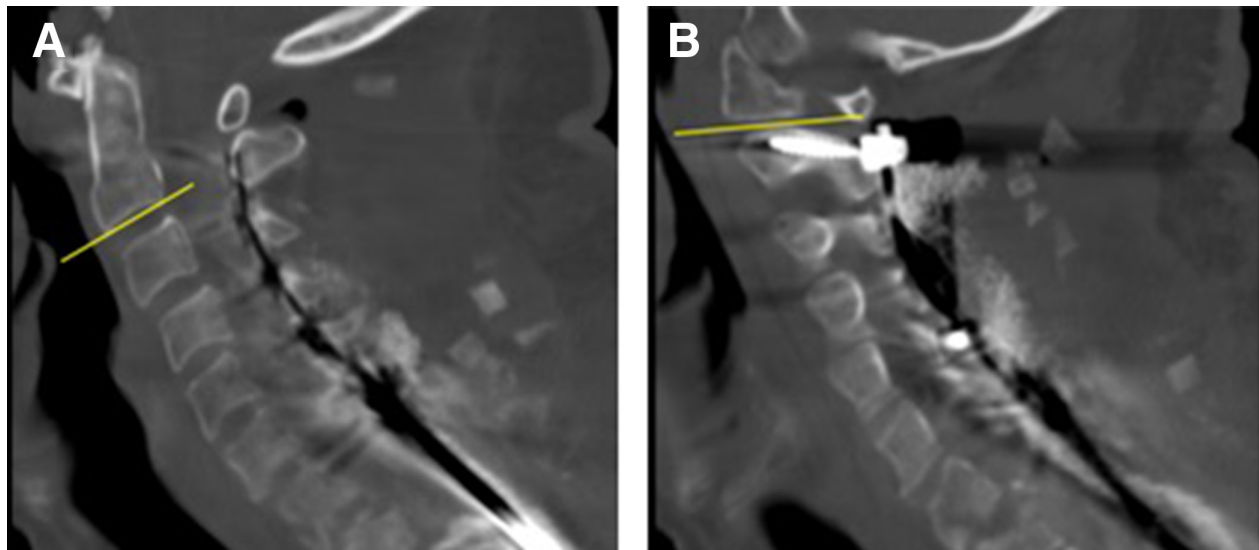


Figure 3. Measurement of the sagittal angle of the C1-C2 facet joint. The inferior endplate of C2 represents the reference line (A). A second line approximates the slope of the C1-C2 facet joint (B). The sagittal screw angles were measured using a similar method.

myelopathy, 7 with cervical fractures, 6 with metastatic tumors, 3 with cervical kyphosis requiring a pedicle subtraction osteotomy, and 1 with ossification of the posterior longitudinal ligament.

The average age was 66 years in the non-FJP group and 68 years in the FJP group ($P = 0.60$). There were no neurophysiologic alerts or vertebral artery injuries during the C2 screw placement. Eight screws (14%) penetrated the C1-C2 facet joint. There were 5 Grade 1 and 3 Grade 2 facet joint violations. The Kappa coefficients for inter- and intrarater reliability of the Gertzbein and Robbins grades were 0.87 and 0.93, respectively. The mean sagittal angle of the C1-C2 facet joint was significantly lower in the penetrated (FJP) group compared with the non-penetrated (non-FJP) group (Table 1, Figure 5). The mean sagittal angle of the screws was

significantly higher in the FJP group compared with the non-FJP group (Table 1, Figure 6). The mean axial screw angle was significantly lower in the FJP group compared with the non-FJP group (Table 1). The mean screw length was significantly higher for FJP screws compared with the non-FJP screws (Table 1, Figure 7). The mean bone mineral density of the C2 vertebral body was lower in the FJP group compared with the non-FJP group, but this finding did not reach statistical significance ($P = 0.06$). Pedicle width, length, height, and transverse angle were not significantly associated with FJP (Table 2). Independent reviewers were able to identify FJP on intraoperative fluoroscopic imaging in 2 out of 8 cases (Figure 8). None of the C2 pedicle screws required revision at the latest follow-up (mean 12 months). None of the patients required a cephalad extension of the fusion.

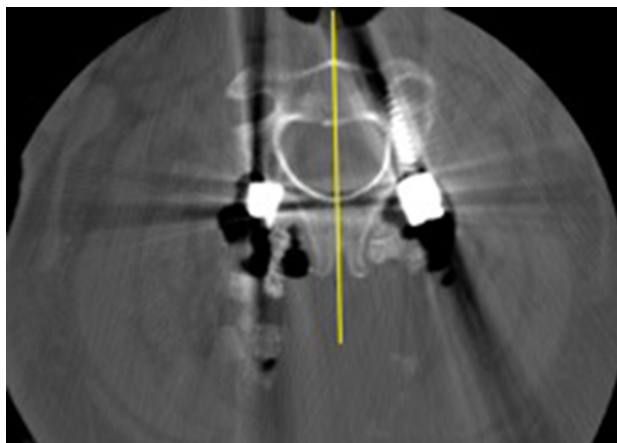


Figure 4. The axial angle of each pedicle screw was measured relative to a line bisecting the C2 vertebra and aligned with the spinous processes to account for any vertebral rotation.

DISCUSSION

Our findings demonstrate that lower sagittal angle of the facet joint, higher sagittal angle of the pedicle screw, lower axial angle of the pedicle screw, and longer screw length are associated with a higher risk of C1-C2 FJP. The mean bone mineral density of the C2 vertebral body was lower in the FJP group compared with the non-FJP group, but this finding did not reach statistical significance. Pedicle width, length, height, and transverse angle were not significantly associated with FJP. Careful surgical technique is necessary to avoid FJP when placing C2 pedicle screws under these conditions. Meticulous exposure of the C2 lamina, pars, and C1-C2 interlaminar window as well as palpation and/or direct

Table 1. Comparison of postoperative CT measurements between patients with and without FJP.

Postoperative CT Measurement	Non-FJP Screw Placement (<i>n</i> = 60)	FJP Screw Placement (<i>n</i> = 8)	<i>P</i> Value
Sagittal angle of the C1-C2 facet joint	20.8° ± 5.5°	13.9° ± 4.4°	<0.01
Sagittal angle of the C2 pedicle screw	50.1° ± 6.1°	55.5° ± 6.4°	0.02
Axial angle of the C2 pedicle screw	17.9° ± 7.7°	13.8° ± 3.4°	0.02
C2 pedicle screw length, mm	23.5 ± 4.3	28.4 ± 3.9	<0.01
Bone mineral density of C2, Hounsfield units	397 ± 134	305 ± 72	0.06

Abbreviations: CT, computed tomography; FJP, facet joint penetration.

Note: Data represented as mean ± SD.

visualization of the medial wall of the C2 pedicles is crucial to determine the starting point for the C2 pedicle screw and its trajectory. These findings are concordant with our initial hypothesis that more vertically oriented C1-C2 facet joints and longer pedicle screws may predispose to inadvertent C1-C2 FJP, although we also predicted softer bone would predispose to FJP as well.

The results of our study suggest that FJPs may not be apparent on intraoperative fluoroscopic imaging. Similarly, Yoem et al reported in a study of 39 C2 pedicle screws that none of their 8 vertebral artery groove violations was detectable on intraoperative fluoroscopy or postoperative plain radiographs.³¹ Some authors have suggested that 3-dimensional navigation improves pedicle screw accuracy compared with freehand techniques.³² However, few studies have directly compared the 2 techniques in the cervical spine.^{33,34} In a retrospective review of 426 C2 pars and pedicle screws, Hlubek et al reported that freehand placement was more accurate than CT-based navigation (acceptable placement

was 94% vs 82%, respectively; *P* = 0.02).³⁵ In their study, the incidence of vertebral artery injury and other complications did not differ between the techniques.

The Gertzbein and Robbins classification has been used in several studies of pedicle screw accuracy in the cervical spine.^{19,33} Prior studies suggested that FJP contributes to facet degeneration and development of axial symptoms. Most breaches (63%) in our study were Gertzbein and Robbins Grade 1 with less than 50% of the screw diameter entering the joint. A minimal radiographic breach may not represent a true cortical breach due to metal-related artifact on CT imaging.²⁵ Even if present, breaches less than 25% to 50% of the screw diameter represent less than 1 mm of screw length beyond the margin of the cortex.^{23,25}

Despite FJP, at the time of this study no patient from this sample with or without FJP had required a revision surgery for symptomatic adjacent segment disease (ASD) or removal of hardware. The mean follow-up for patients with FJP in our study of approximately 1

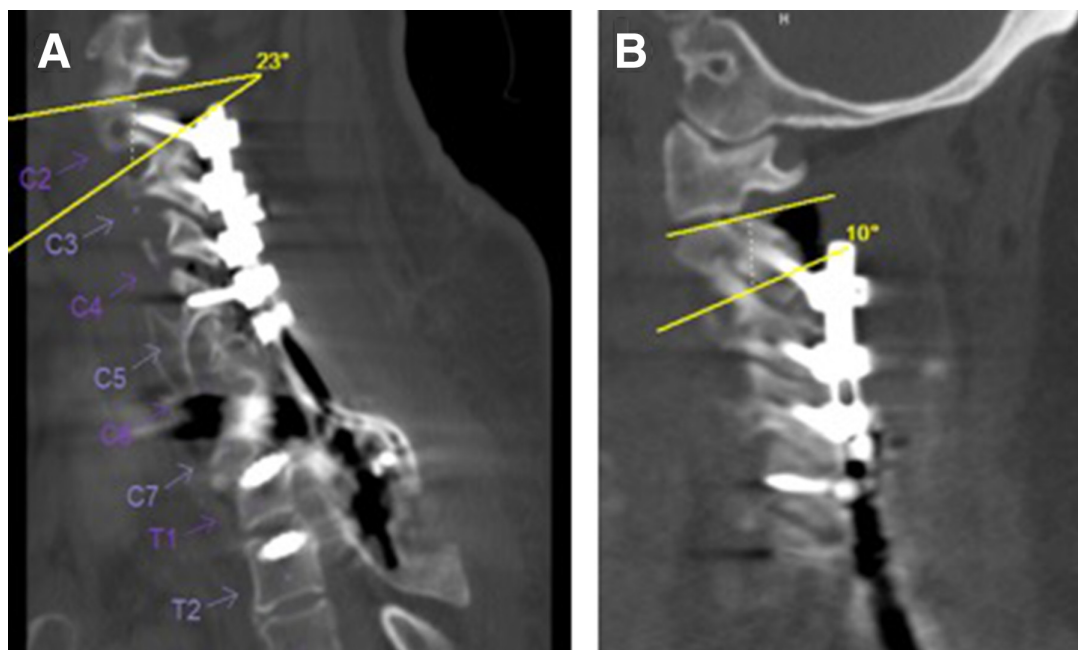


Figure 5. Computed tomography images demonstrating a lower sagittal facet joint angle in the facet joint penetration (FJP) group (B) compared with the non-FJP group (A).

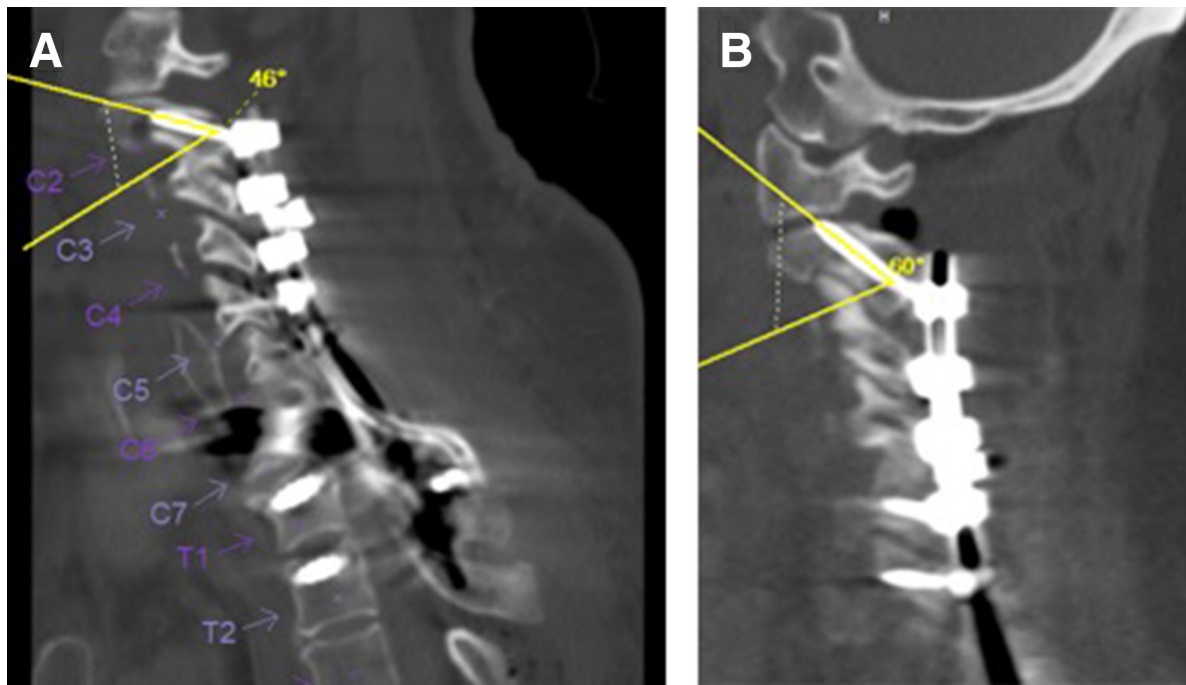


Figure 6. Computed tomography images demonstrating a higher sagittal screw angle in the facet joint penetration (FJP) group (B) compared with the non-FJP group (A).

year is likely sufficient to address the early radiographic sequelae of facet joint violation such as early arthritis or progressive erosion into C1. It is likely inadequate for symptomatic or operative ASD, especially considering our sample size. We assume there will possibly be some rate of symptomatic or operative ASD at C1-C2 that will

present in the future. Although ASD is a leading cause of revision surgery following anterior cervical discectomy and fusion as well as posterior cervical fusion, it is still somewhat unclear whether ASD primarily results from age-related progression of the underlying disease or adjacent segment biomechanical changes related to

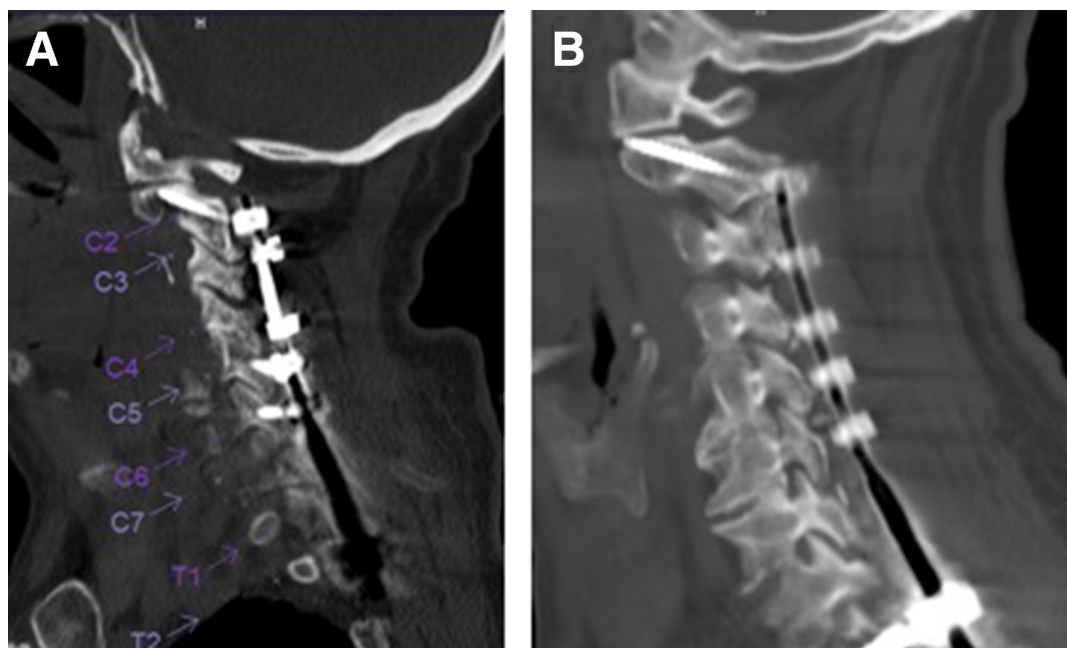


Figure 7. Computed tomography images demonstrating increased screw length in the facet joint penetration (FJP) group (B, 38 mm) compared with the non-FJP group (A, 26 mm). Both patients had similar sagittal facet joint angles, sagittal screw angles, and axial screw angles (19° vs 21°, 51° vs 53°, and 20° vs 21°, respectively).

Table 2. Comparison of C2 pedicle morphometry between patients with and without FJP.

Computed Tomography Measurement	Non-FJP Screw Placement (n = 60)	FJP Screw Placement (n = 8)	P Value
Width, mm	7.5 ± 2.1	7.4 ± 1.1	0.88
Length, mm	32.2 ± 2.9	31.7 ± 1.3	0.59
Height, mm	7.7 ± 1.4	7.4 ± 1.1	0.48
Transverse angle	43.0° ± 3.4°	42.3° ± 2.5°	0.55

Abbreviation: FJP, facet joint penetration.

Note: All data are represented as mean ± SD.

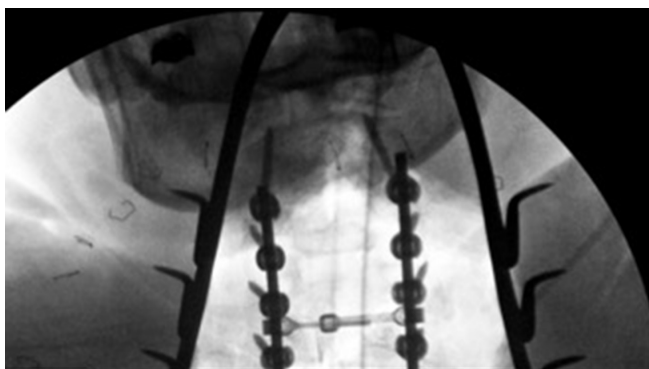
the fusion.^{36–40} Clinically, patients may present with new pain, new symptomatic spinal stenosis, or new sagittal or coronal imbalance.⁴¹

FJP may lead to altered loading of the facet joint and contribute to eventual facet joint and adjacent segment degeneration.¹⁶ However, relatively few studies have investigated clinical outcomes related to FJP in the cervical spine.^{19,21,27} In a retrospective study of 52 freehand C2 pedicle screws, Punyarat et al reported 2 superior breaches, 1 of which occurred close to the C2 nerve and may have caused occipital neuralgia.²³ The authors state that the patient's symptoms resolved completely with removal of the pedicle screw. In a retrospective study of 40 freehand C2 pedicle screws placed in 24 patients, Pham et al reported 4 FJPs but no clinical sequelae at 6 months of follow-up.²⁴ Other clinical studies have reported an association between FJP of lateral mass screws during cervical laminoplasty and axial pain and stiffness.^{17,42} Pham et al also noted that “the majority of breaches occurred superiorly as a result of screw length choice and not as a result of error in exposure or anatomical trajectory.”²⁴ This is in line with the results of our study, which did not find a significant association between pedicle width, length, height, and transverse angle and FJP. In a study of 170 C2 pedicle screws, Alosch et al found that a pedicle isthmus diameter less than 6 mm was associated with a nearly 2-fold

increased risk of cortical breach; however, any cortical breach was included in their analysis, not only FJP.⁴³ Bydon et al analyzed over 300 freehand C2 pedicle screws and found no association between screw length and medial or lateral breach.⁴⁴ However, the authors did not include superior cortical violations in their analysis.

The freehand fluoroscopic technique if performed correctly is effective in the placement of C2 pedicle screws. Using the fluoroscopically assisted freehand technique, we were able to place pedicle screws in every patient in whom we had planned preoperatively to perform pedicle screw fixation. The preoperative plan for cephalad extent of the fusion was never altered because of inability to place C2 fixation. The operating room equipment necessary for this technique includes Mayfield head clamp, wine cork or radiolucent bite block, and radiolucent table. The wine cork or radiolucent bite block placed in the mouth is critical in obtaining the open mouth to visualize the C2 pedicle outline for the starting screw position. An inability to obtain a perfect open mouth view due to smaller or tighter jaw opening or metallic dental work producing interference with the beam can present a significant challenge. The FJP detailed in this study occurred early in the inclusion period, prior to the authors becoming aware that fluoroscopy is not always sufficient to detect intraoperative FJP. The subsequent steps the authors undertook included rigorous following of the previously detailed protocol. In addition, although typically the screw length is determined intraoperatively, we generally limited screw length to 24 mm or less to limit FJP. These steps significantly limited FJP during subsequent operations.

Limitations of the study include the lack of clinical assessments of C1-C2 degeneration over time. Future studies should compare patient-reported outcomes and rates of C1-C2 degenerative disease in patients with and without FJP. In addition, none of the C2 pedicle screws in our study required revision at the latest follow-up; therefore, future studies are necessary to investigate the clinical significance, if any, of facet joint violations in the cervical spine. Furthermore, a larger sample size may have been sufficiently powered to detect statistically significant differences in bone mineral density between FJP and non-FJP groups. Osteoporotic patients may require increased cortical purchase and longer C2 screws to achieve adequate fixation, thus confounding the association between bone mineral density and FJP. Also, a larger sample size may allow for comparisons between patients with lower Grade 1 and higher Grade 2 facet joint violations. Additionally, this study was

**Figure 8.** Intraoperative fluoroscopic open mouth view demonstrating C1-C2 facet joint penetration.

limited to the freehand technique, and navigation and robotics were not included. The higher sagittal angle of the pedicle screw was found to be associated with a higher risk of FJP; however, navigation or robotics may be able to decrease the sagittal screw angle by allowing for a higher starting point than the freehand technique.

Adjacent segment degeneration is a common sequelae of cervical spine arthrodesis and results in recurrent symptoms, patient pain and disability, as well as possible revision surgery to extend the surgical construct. Violation of the unfused facet joints above the cervical fusion construct will result in damage to the articular cartilage of the facet, possibly causing facet arthrosis and progressive degeneration. The C2 vertebra has a unique bony anatomy and close proximity to vital structures such as vertebral arteries and the spinal cord that makes C2 instrumentation quite challenging. With the ever-increasing number and invasiveness of complex cervical posterior reconstruction, C2 pedicle screw placement is becoming more common. This would potentially increase the number of patients with inadvertent violation of the unfused C1-C2 facet joint, setting off a cascade of ASD, possible proximal junctional kyphosis, suboccipital pain, and limited cervical rotation. Thus, any potential guidance on how to avoid the violation of the C1-C2 facet joint by instrumentation is of great importance.

CONCLUSION

Several anatomical and technical factors may increase the risk of C1-C2 FJP during placement of C2 pedicle screws using a fluoroscopically assisted freehand technique, including a lower sagittal facet angle, higher sagittal screw angle, lower axial screw angle, and screw length >24 mm. Intraoperative fluoroscopy is not always adequate to avoid C1-C2 FJP, underscoring the importance of preoperative planning and limiting screw length. None of the C2 pedicle screws in our study required revision at the latest follow-up.

REFERENCES

1. Du JY, Aichmair A, Kueper J, Wright T, Lebl DR. Biomechanical analysis of screw constructs for atlantoaxial fixation in cadavers: a systematic review and meta-analysis. *J Neurosurg Spine*. 2015;22(2):151–161. doi:10.3171/2014.10.SPINE13805
2. Paramore CG, Dickman CA, Sonntag VKH. The anatomical suitability of the C1-2 complex for transarticular screw fixation. *J Neurosurg*. 1996;85(2):221–224. doi:10.3171/jns.1996.85.2.0221
3. Mandel IM, Kambach BJ, Petersilge CA, Johnstone B, Yoo JU. Morphologic considerations of C2 isthmus dimensions for the placement of transarticular screws. *Spine (Phila Pa 1976)*. 2000;25(12):1542–1547. doi:10.1097/00007632-200006150-00014
4. Humke T, Grob D, Dvorak J, Messikommer A. Translaminar screw fixation of the lumbar and lumbosacral spine. A 5-year follow-up. *Spine (Phila Pa 1976)*. 1998;23(10):1180–1184. doi:10.1097/00007632-199805150-00021
5. Elliott RE, Tanweer O, Boah A, Smith ML, Frempong-Boadu A. Comparison of safety and stability of C-2 pars and pedicle screws for atlantoaxial fusion: meta-analysis and review of the literature. *J Neurosurg Spine*. 2012;17(6):577–593. doi:10.3171/2012.9.SPINE111021
6. Parker SL, McGirt MJ, Garcés-Ambrossi GL, et al. Translaminar versus pedicle screw fixation of C2: comparison of surgical morbidity and accuracy of 313 consecutive screws. *Neurosurgery*. 2009;64(5 Suppl 2):343–348. doi:10.1227/01.NEU.0000338955.36649.4F
7. Wang MY. Cervical crossing laminar screws: early clinical results and complications. *Neurosurgery*. 2007;61(5 Suppl 2):311–315. doi:10.1227/01.neu.0000303987.49870.7b
8. Wright NM. Posterior C2 fixation using bilateral, crossing C2 laminar screws: case series and technical note. *J Spinal Disord Tech*. 2004;17(2):158–162. doi:10.1097/00024720-200404000-00014
9. Yamazaki M, Okawa A, Furuya T, et al. Anomalous vertebral arteries in the extra- and intraosseous regions of the craniovertebral junction visualized by 3-dimensional computed tomographic angiography: analysis of 100 consecutive surgical cases and review of the literature. *Spine (Phila Pa 1976)*. 2012;37(22):E1389–E1397. doi:10.1097/BRS.0b013e31826a0c9f
10. Moon BJ, Choi KH, Shin DA, et al. Anatomical variations of vertebral artery and C2 isthmus in atlanto-axial fusion: consecutive surgical 100 cases. *J Clin Neurosci*. 2018;53:147–152. doi:10.1016/j.jocn.2018.04.058
11. Wajanavisit W, Lertudomphonwanit T, Fuangfa P, Chanplakorn P, Kraiwattanapong C, Jaovisidha S. Prevalence of high-riding vertebral artery and morphometry of C2 pedicles using a novel computed tomography reconstruction technique. *Asian Spine J*. 2016;10(6):1141–1148. doi:10.4184/asj.2016.10.6.1141
12. Wakao N, Takeuchi M, Nishimura M, et al. Vertebral artery variations and osseous anomaly at the C1-2 level diagnosed by 3D CT angiography in normal subjects. *Neuroradiology*. 2014;56(10):843–849. doi:10.1007/s00234-014-1399-y
13. Yeom JS, Buchowski JM, Kim H-J, Chang B-S, Lee C-K, Riew KD. Risk of vertebral artery injury: comparison between C1-C2 transarticular and C2 pedicle screws. *Spine J*. 2013;13(7):775–785. doi:10.1016/j.spinee.2013.04.005
14. Wang J, Xia H, Ying Q, et al. An anatomic consideration of C2 vertebrae artery groove variation for individual screw implantation in axis. *Eur Spine J*. 2013;22(7):1547–1552. doi:10.1007/s00586-013-2779-4
15. Chung KJ, Suh SW, Swapnil K, Yang JH, Song HR. Facet joint violation during pedicle screw insertion: a cadaveric study of the adult lumbosacral spine comparing the two pedicle screw insertion techniques. *Int Orthop*. 2007;31(5):653–656. doi:10.1007/s00264-006-0249-x
16. Kim H-J, Chun H-J, Kang K-T, et al. The biomechanical effect of pedicle screws' insertion angle and position on the superior adjacent segment in 1 segment lumbar fusion. *Spine (Phila Pa 1976)*. 2012;37(19):1637–1644. doi:10.1097/BRS.0b013e31823f2115
17. Chen H, Li H, Deng Y, et al. Optimal area of lateral mass mini-screws implanted in plated cervical laminoplasty: a

radiography anatomy study. *Eur Spine J*. 2017;26(4):1140–1148. doi:10.1007/s00586-016-4785-9

18. Yoshida M, Tamaki T, Kawakami M, et al. Does reconstruction of posterior ligamentous complex with extensor musculature decrease axial symptoms after cervical laminoplasty? *Spine (Phila Pa 1976)*. 2002;27(13):1414–1418. doi:10.1097/00007632-200207010-00008

19. Tannous O, Jazini E, Weir TB, et al. Facet joint violation during percutaneous pedicle screw placement: a comparison of two techniques. *Spine (Phila Pa 1976)*. 2017;42(15):1189–1194. doi:10.1097/BRS.0000000000002001

20. Levin JM, Alentado VJ, Healy AT, Steinmetz MP, Benzell EC, Mroz TE. Superior segment facet joint violation during instrumented lumbar fusion is associated with higher reoperation rates and diminished improvement in quality of life. *Clin Spine Surg*. 2018;31(1):E36–E41. doi:10.1097/BSD.0000000000000566

21. Chen Z, Zhao J, Xu H, Liu A, Yuan J, Wang C. Technical factors related to the incidence of adjacent superior segment facet joint violation after transpedicular instrumentation in the lumbar spine. *Eur Spine J*. 2008;17(11):1476–1480. doi:10.1007/s00586-008-0776-9

22. Chen ZD, Wu J, CW L, Zeng WR, Huang ZZ, Lin B. C1-C2 pedicle screw fixation for pediatric atlantoaxial dislocation: initial results and long-term follow-up. *J Pediatr Orthop*. 2017.

23. Punyarat P, Buchowski JM, Klawson BT, Peters C, Lertudomphonwanit T, Riew KD. Freehand technique for C2 pedicle and pars screw placement: is it safe? *Spine J*. 2018;18(7):1197–1203. doi:10.1016/j.spinee.2017.11.010

24. Pham MH, Bakhsheshian J, Reid PC, Buchanan IA, Fredrickson VL, Liu JC. Evaluation of C2 pedicle screw placement via the freehand technique by neurosurgical trainees. *J Neurosurg Spine*. 2018;29(3):235–240. doi:10.3171/2018.1.SPINE17875

25. Sciubba DM, Noggle JC, Vellimana AK, et al. Radiographic and clinical evaluation of free-hand placement of C-2 pedicle screws. Clinical article. *J Neurosurg Spine*. 2009;11(1):15–22. doi:10.3171/2009.3.SPINE08166

26. Gertzbein SD, Robbins SE. Accuracy of pedicular screw placement in vivo. *Spine (Phila Pa 1976)*. 1990;15(1):11–14. doi:10.1097/00007632-199001000-00004

27. Matsukawa K, Kato T, Yato Y, et al. Incidence and risk factors of adjacent cranial facet joint violation following pedicle screw insertion using cortical bone trajectory technique. *Spine (Phila Pa 1976)*. 2016;41(14):E851–E856. doi:10.1097/BRS.0000000000001459

28. Takao T, Kubota K, Maeda T, et al. A radiographic evaluation of facet sagittal angle in cervical spinal cord injury without major fracture or dislocation. *Spinal Cord*. 2017;55(5):515–517. doi:10.1038/sc.2016.172

29. Pesenti S, Lafage R, Lafage V, Panuel M, Blondel B, Jouve JL. Cervical facet orientation varies with age in children: an MRI study. *J Bone Joint Surg Am*. 2018;100(9):e57. doi:10.2106/JBJS.17.00979

30. Schreiber JJ, Anderson PA, Rosas HG, Buchholz AL, Au AG. Hounsfield units for assessing bone mineral density and strength: a tool for osteoporosis management. *J Bone Joint Surg Am*. 2011;93(11):1057–1063. doi:10.2106/JBJS.J.00160

31. Yeom JS, Buchowski JM, Park KW, Chang BS, Lee CK, Riew KD. Undetected vertebral artery groove and foramen violations during C1 lateral mass and C2 pedicle screw placement. *Spine (Phila Pa 1976)*. 2008;33(25):E942–E949. doi:10.1097/BRS.0b013e3181870441

32. Mason A, Paulsen R, Babuska JM, et al. The accuracy of pedicle screw placement using intraoperative image guidance systems. *J Neurosurg Spine*. 2014;20(2):196–203. doi:10.3171/2013.11.SPINE13413

33. Bredow J, Oppermann J, Kraus B, et al. The accuracy of 3D fluoroscopy-navigated screw insertion in the upper and subaxial cervical spine. *Eur Spine J*. 2015;24(12):2967–2976. doi:10.1007/s00586-015-3974-2

34. Uehara M, Takahashi J, Ikegami S, et al. Screw perforation features in 129 consecutive patients performed computer-guided cervical pedicle screw insertion. *Eur Spine J*. 2014;23(10):2189–2195. doi:10.1007/s00586-014-3502-9

35. Hlubek RJ, Bohl MA, Cole TS, et al. Safety and accuracy of freehand versus navigated C2 pars or pedicle screw placement. *Spine J*. 2018;18(8):1374–1381. doi:10.1016/j.spinee.2017.12.003

36. Alhashash M, Shousha M, Boehm H. Adjacent segment disease after cervical spine fusion: evaluation of a 70 patient long-term follow-up. *Spine (Phila Pa 1976)*. 2018;43(9):605–609. doi:10.1097/BRS.0000000000002377

37. Cho SK, Riew KD. Adjacent segment disease following cervical spine surgery. *J Am Acad Orthop Surg*. 2013;21(1):3–11. doi:10.5435/JAAOS-21-01-3

38. van Eck CF, Regan C, Donaldson WF, Kang JD, Lee JY. The revision rate and occurrence of adjacent segment disease after anterior cervical discectomy and fusion: a study of 672 consecutive patients. *Spine (Phila Pa 1976)*. 2014;39(26):2143–2147. doi:10.1097/BRS.0000000000000636

39. Lee JC, Lee SH, Peters C, Riew KD. Risk-factor analysis of adjacent-segment pathology requiring surgery following anterior, posterior, fusion, and nonfusion cervical spine operations: survivorship analysis of 1358 patients. *J Bone Joint Surg Am*. 2014;96(21):1761–1767. doi:10.2106/JBJS.M.01482

40. Hilibrand AS, Carlson GD, Palumbo MA, Jones PK, Bohlman HH. Radiculopathy and myelopathy at segments adjacent to the site of a previous anterior cervical arthrodesis. *J Bone Joint Surg Am*. 1999;81(4):519–528. doi:10.2106/00004623-199904000-00009

41. Cheh G, Bridwell KH, Lenke LG, et al. Adjacent segment disease following lumbar/thoracolumbar fusion with pedicle screw instrumentation: a minimum 5-year follow-up. *Spine (Phila Pa 1976)*. 2007;32(20):2253–2257. doi:10.1097/BRS.0b013e31814b2d8e

42. Sakaura H, Hosono N, Mukai Y, Fujii R, Iwasaki M, Yoshikawa H. Persistent local pain after posterior spine surgery for thoracic lesions. *J Spinal Disord Tech*. 2007;20(3):226–228. doi:10.1097/01.bsd.0000211275.81862.91

43. Alosch H, Parker SL, McGirt MJ, et al. Preoperative radiographic factors and surgeon experience are associated with cortical breach of C2 pedicle screws. *J Spinal Disord Tech*. 2010;23(1):9–14. doi:10.1097/BSD.0b013e318194e746

44. Bydon M, Mathios D, Macki M, et al. Accuracy of C2 pedicle screw placement using the anatomic freehand technique. *Clin Neurol Neurosurg*. 2014;125:24–27. doi:10.1016/j.clineuro.2014.07.017

Funding: This work was funded entirely by internal, institutional research funds. No external funding was received for this study.

Declaration of Conflicting Interests: The authors declare that the study was performed in the

absence of any commercial or financial relationships that could be considered a potential conflict of interest.

Disclosures: Dimitriy Kondrashov reports grants or contracts, royalties or licenses, consulting fees, and support for attending meetings and/or travel from Spineart and consulting fees from SI-Bone. The remaining authors have no disclosures.

IRB Approval: Our institution's institutional review board approved this study and granted a waiver of informed consent.

Corresponding Author: Dimitriy Kondrashov, St. Mary's Medical Center, San Francisco Orthopaedic Residency Program, 450 Stanyan St, San Francisco, CA 94117, USA; sfspine@gmail.com

This manuscript is generously published free of charge by ISASS, the International Society for the Advancement of Spine Surgery. Copyright © 2022 ISASS. To see more or order reprints or permissions, see <http://ijssurgery.com>.