

Influence of Preoperative T1-Slope and Cervical Sagittal Vertical Axis on Postoperative Cervical Sagittal Alignment Following Posterior Cervical Laminoplasty

Ninad Bhat, Shane Burch, Bobby Tay, Sigurd H. Berven, Vedat Deviren and Alekos A. Theologis

Int J Spine Surg published online 8 March 2023
<https://www.ijssurgery.com/content/early/2022/12/29/8415>

This information is current as of May 17, 2025.

Email Alerts Receive free email-alerts when new articles cite this article. Sign up at:
<http://ijssurgery.com/alerts>

Influence of Preoperative T1-Slope and Cervical Sagittal Vertical Axis on Postoperative Cervical Sagittal Alignment Following Posterior Cervical Laminoplasty

NINAD BHAT, BS¹; SHANE BURCH, MD¹; BOBBY TAY, MD¹; SIGURD H. BERVEN, MD¹; VEDAT DEVIREN, MD¹; AND ALEKOS A. THEOLOGIS, MD¹

¹Department of Orthopaedic Surgery, University of California - San Francisco (UCSF), San Francisco, CA, USA

ABSTRACT

Background: Assess correlation between preoperative cervical sagittal alignment (T1 slope [T1S] and C2-C7 cervical sagittal vertical axis [cSVA]) and postoperative cervical sagittal balance after posterior cervical laminoplasty.

Methods: Consecutive patients who underwent laminoplasty at a single institution with >6 weeks postoperative follow-up were divided into 4 groups based on preoperative cSVA and T1S (Group 1: cSVA <4 cm/T1S <20°; Group 2: cSVA ≥4 cm/T1S ≥20°; Group 3: cSVA <4 cm/T1S ≥20°; Group 4: cSVA <4 cm/T1S <20°). Radiographic analyses were conducted at 3 timepoints, and changes in cSVA, C2-C7 cervical lordosis (CL), and T1S -CL were compared.

Results: A total of 214 patients met inclusion criteria (28 patients had cSVA <4 cm/T1S <20° [Group 1]; 47 patients had cSVA ≥4 cm/T1S ≥20° [Group 2]; 139 patients had cSVA <4 cm/T1S ≥20° [Group 3]). No patients had cSVA ≥4 cm/T1S <20° (Group 4). Patients either had a C4-C6 (60.7%) or C3-C6 (39.3%) laminoplasty. Mean follow-up was 1.6 ± 1.32 years. For all patients, mean cSVA increased 6 mm postoperatively. cSVA significantly increased postoperatively for both groups with a preoperative cSVA <4 cm (ie, Groups 1 and 3 [$P < 0.01$]). For all patients, mean CL decreased 2° postoperatively. Groups 1 and 2 had significant differences in preoperative CL but nonsignificant differences at 6 weeks ($P = 0.41$) and last follow-up ($P = 0.06$).

Conclusion: Cervical laminoplasty resulted in a mean decrease in CL. Patients with high preoperative T1S, irrespective of cSVA, were at risk of loss of CL postoperatively. While patients with low preoperative T1S and cSVA <4 cm experienced a decrease in global sagittal cervical alignment, CL was not jeopardized.

Clinical Relevance: The results of this study may facilitate preoperative planning for patients undergoing posterior cervical laminoplasty.

Level of Evidence: 3.

Cervical Spine

Keywords: cervical laminoplasty, sagittal alignment, cervical lordosis, T1 slope, SVA

INTRODUCTION

Posterior cervical laminoplasty is a common surgical technique to address cervical spinal cord compression secondary to cervical spondylosis and ossification of the posterior longitudinal ligament. Its use is typically reserved for patients with minimal neck pain, multi-level pathology, and preserved cervical lordosis (CL).^{1,2} As loss of CL after posterior cervical laminoplasty may jeopardize clinical outcomes,³ a comprehensive understanding of risk factors for loss of cervical sagittal alignment after the operation is important. While several risk factors for the loss of CL after posterior cervical laminoplasty have been identified,³⁻⁵ the relationship between preoperative cervical alignment and postoperative cervical alignment in patients undergoing cervical laminoplasty has not been fully explored. As

such, the goal of this investigation is to assess changes in cervical alignment after cervical laminoplasty based on preoperative cervical alignment, particularly severity of cervical sagittal vertical axis (cSVA) and T1 slope (T1S).

METHODS

Patient Cohort

After Institutional Review Board approval at our institution, consecutive patients who underwent posterior cervical laminoplasty between January 2008 and September 2018 were identified. Patients included for analysis were those with no prior cervical spine surgery, complete radiographic data, and minimum 6-week follow-up.

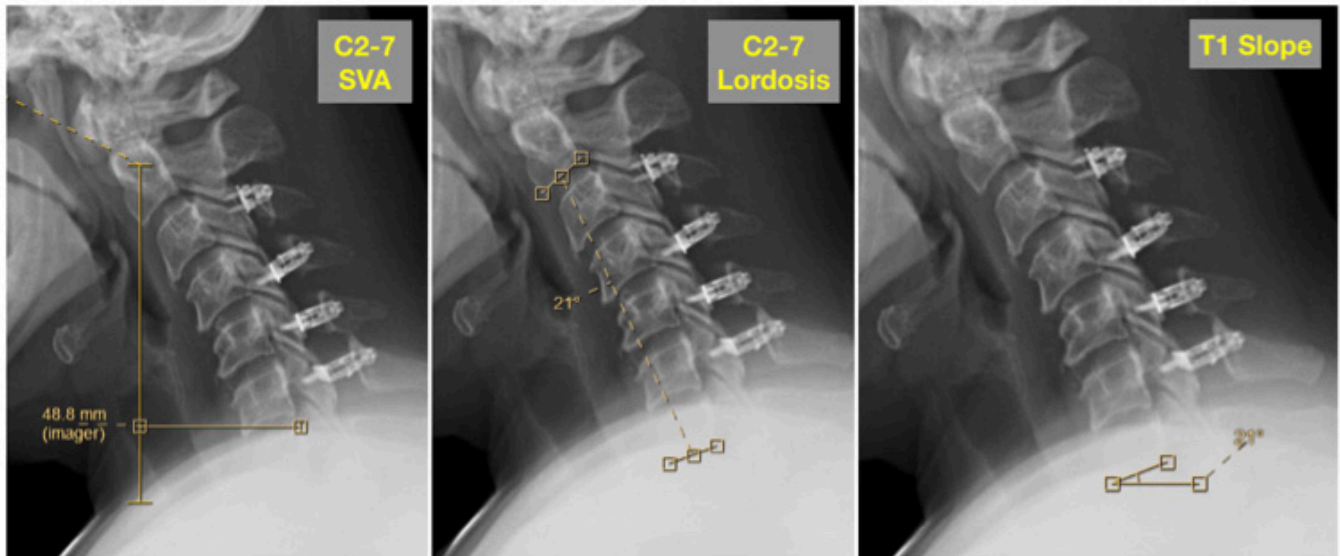


Figure. Representative cervical alignment radiographic parameters. SVA, sagittal vertical axis.

Radiographic Analysis

Radiographic analysis was performed on lateral radiographs of the cervical spine taken in the neutral position at 3 timepoints: preoperative, 6-week follow-up, and last follow-up. The following 3 sagittal alignment parameters were measured for each patient at each timepoint (Figure):

1. C2-C7 sagittal vertebral angle
2. C2-C7 lordosis by Cobb's method
3. T1S

Differences between the C2-C7 Cobb and T1S were calculated for each patient at each timepoint by subtracting the T1S from C2-C7 lordosis.

Patients were divided into the following 4 groups based on the degree of the cSVA and T1S:

1. SVA <40 mm, T1S <20°
2. SVA ≥40 mm, T1S ≥20°
3. SVA <40 mm, T1S ≥20°
4. SVA >40 mm, T1S ≤20°

Statistical Analysis

Means and SDs were calculated for each radiographic parameter at each time point for the different cohort of patients. Using Microsoft Excel, paired *t* tests and analysis of variance tests were used to compare changes in radiographic parameter. A *P* value <0.05 was used for statistical significance.

RESULTS

A total of 341 patients underwent posterior cervical laminoplasty in the time frame studied. Of these 341 patients, 214 patients met inclusion criteria (134 men, 80 women; mean age 63.5 ± 12.0 years, range 20–86 years). There were 28 patients who had cSVA <4 cm/T1S <20° (Group 1). Forty-seven patients had cSVA ≥4 cm/T1S ≥20° (Group 2), and 139 patients had cSVA <4 cm/T1S ≥20° (Group 3). No patients had cSVA ≥4 cm/T1S <20° (Group 4). Mean follow-up was 1.6 ± 1.32 years (range 0.3–10.8 years). All patients underwent multilevel laminoplasty, with the most common levels treated being C4-C6 (60.7%) and C3-C6 (39.3%).

Data for preoperative and postoperative cervical alignment for the entire cohort and for the 3 subgroups are presented in the Table. For the entire cohort, average cSVA was <4 cm. When comparing groups, it was found that there were significant differences between all groups at each timepoint for cSVA. After the operations, average cSVA significantly increased for the entire cohort (average increase of 6.2 mm between preoperative and last postoperative measurements). For Group 1 (cSVA <4 cm/T1S <20°), there was a significant increase in cSVA after the operation (2.0 cm preoperative to 2.6 cm at latest follow-up). Similarly, there was a significant increase in cSVA (2.7 cm preoperative to 3.4 cm at latest follow-up) for Group 3 (cSVA <4 cm/T1S ≥20°). For Group 2 (cSVA ≥4 cm/T1S ≥20°), there were no significant changes in cSVA after the operation.

The average preoperative C2-C7 CL for the entire group was 16°. After the operation, average CL

Table. Patient subgroups based on cervical SVA and T1S.

Variables	All Patients (n = 214)	SVA <4 cm, T1 <20° (n = 28)	SVA ≥4 cm T1 ≥20° (n = 47)	SVA <4 cm T1 ≥20° (n = 139)	P
Age, y, mean ± SD (min-max)	63.5 ± 11.9 (20–86)	58.5 ± 14.9 (20–79)	64.8 ± 10.8 (40–84)	64.1 ± 11.5 (30–86)	>0.05
Gender					
Men	134	12	38	84	>0.05
Women	80	16	9	55	
Follow-up, y, mean ± SD (min-max)	1.6 ± 1.3 (0.3–10.8)	1.76 ± 1.5 (0.3–6.7)	1.7 ± 1.2 (0.4–5.4)	1.6 ± 1.3 (0.3–0.8)	>0.05
SVA					
Preoperative	31.4 ± 13.9	20.2 ± 9.4	51.1 ± 9.0	27.0 ± 8.6	<0.01
6-wk PO	39.4 ± 16.0	27.4 ± 11.0	57.1 ± 17.3	36.4 ± 11.4	<0.01
Last PO	37.6 ± 15.5	26.1 ± 10.9	55.1 ± 16.4	34.0 ± 12.8	<0.01
P	<0.01	0.01	0.26	<0.01	
C2-C7 lordosis					
Preoperative	16.4 ± 11.5	7.9 ± 5.2	16.2 ± 11.1	18.2 ± 11.9	<0.01
6-wk PO	12.1 ± 9.6	11.6 ± 11.3	13.8 ± 9.6	11.7 ± 9.2	>0.05
Last PO	14.5 ± 10.7	10.4 ± 7.9	14.4 ± 10.0	15.3 ± 11.3	>0.05
P	<0.01	0.12	0.12	<0.01	
T1S					
Preoperative	31.2 ± 11.3	14.4 ± 5.3	39.4 ± 9.6	31.8 ± 9.0	<0.01
6-wk PO	28.1 ± 11.7	16.5 ± 7.9	34.7 ± 10.4	28.7 ± 10.8	<0.01
Last PO	30.3 ± 10.8	17.5 ± 7.1	37.1 ± 10.0	30.6 ± 9.3	<0.01
P	0.19	0.23	0.11	0.08	
T1-(C2-C7 lordosis)					
Preoperative	14.8 ± 10.3	6.5 ± 7.7	22.2 ± 8.1	13.7 ± 9.6	<0.01
6-wk PO	16.0 ± 12.5	4.7 ± 13.3	20.9 ± 11.6	17.0 ± 11.0	<0.01
Last PO	15.9 ± 12.4	7.1 ± 9.1	22.7 ± 11.6	15.9 ± 12.4	<0.01
P	0.57	0.11	0.75	0.14	

Abbreviations: PO, postoperative; SVA, sagittal vertical axis; T1S, T1 slope.

decreased (average decrease of 1.9° between preoperative and last postoperative measurements). When comparing groups, it was found that there were no differences in preoperative CL between Groups 2 and 3 (patients with T1S ≥20°). Group 1 (cSVA <4 cm/T1S <20°) had a significantly greater preoperative CL compared with Group 2 (cSVA ≥4 cm/T1S ≥20°), but nonsignificant differences at 6 weeks ($P = 0.41$) and last follow-up ($P = 0.06$). Compared with preoperative, Group 1 (cSVA <4 cm/T1S <20°) showed a mean increase in CL of 2°, and patients with T1S ≥20° (Groups 2 and 3) showed a mean decrease of 2° and 3°, respectively, at latest follow-up.

DISCUSSION

Posterior cervical laminoplasty is a common surgical technique utilized to decompress the cervical spinal cord with the goal to improve neurologic function and reduce pain.^{6,7} As postoperative CL has been shown to be correlated with postsurgical neck pain and disability,³ the goal of this investigation was to assess the influence of preoperative cervical alignment, particularly severity of cSVA and T1S, on postoperative cervical sagittal alignment. This study had 2 major findings: (1) patients with high preoperative T1S, irrespective of cSVA, were at risk of loss of CL

postoperatively; and (2) patients with low preoperative T1S and cSVA <4 cm experienced a decrease in global sagittal cervical alignment without jeopardizing CL. These results are in concordance with and also add a unique dimension to the current literature on sagittal alignment following posterior cervical laminoplasty.

Changes in the sagittal profile following cervical posterior laminoplasty have been an area of great interest and investigation.⁸ As loss of sagittal cervical alignment is purported to jeopardize clinical outcomes, several studies have attempted to assess preoperative factors that predict the loss of CL following posterior cervical laminoplasty. Historically, the leading theories regarding loss of CL after laminoplasty centered around magnitude of CL. For example, Suk et al identified 3 preoperative risk factors that predicted postoperative kyphosis: (1) preoperative neutral position lordotic angle <10°, (2) preoperative diagnosis of cervical spondylotic myelopathy, and (3) a preoperative kyphotic angle during flexion that is greater than the extension lordotic angle.⁴ However, within this model, effects on changes on CL were mixed, likely due to the fact that other parameters of cervical sagittal alignment, including cSVA and T1S, were not considered.

More recently, the importance of cSVA and T1S on cervical alignment following laminoplasty has gained greater appreciation. For example, in an investigation of 174 patients without preoperative kyphotic alignment, Sakai et al found that an SVA measurement >4.2 cm measured from the center of gravity of the head to C7 and advanced age (>75 years) were predictors of postoperative kyphotic alignment following laminoplasty.⁹ In a retrospective review of 49 patients who underwent open door laminoplasty, Lee et al noted that laminoplasty has a high probability of resulting in loss of CL, and that the T1S was significantly associated with change in the postoperative Cobb angle.¹⁰ Specifically, it was reported that patients with higher T1Ss demonstrated loss of CL postoperatively.¹⁰ Miyazaki et al and Kim et al also demonstrated that loss of CL after laminoplasty is significantly correlated with preoperative T1S.^{11,12} Our findings corroborate these results, as we found that patients with high T1Ss ($>20^\circ$), irrespective of the global sagittal cervical alignment (cSVA), demonstrate significant decreases in CL and cSVA postoperatively compared with patients with low T1Ss.

In contrast to the patients with high T1Ss, patients in our study with low T1Ss demonstrated an improvement, albeit slight, in CL after the operation. While the low T1S patients had a significant increase in cSVA, the average cSVA remained <4 cm. This highlights the notion that the preservation and improvement of CL after laminoplasty are most likely related to alignment of the thoracolumbar spine (ie, thoracic kyphosis), as manifested in the T1S.

Our study's findings should be considered in the context of its limitations. Notably, there is heterogeneity in the study population with regard to age at the time of surgery and follow-up time. However, as all patients had 6-week postoperative radiographs, and that changes in the radiographic alignment parameters between 6 weeks and last follow-up are not significantly different, heterogeneity in latest follow-up likely does not influence the results. Other limitations include variations in levels of laminoplasty performed and by whom. Last, while the absence of clinical outcomes may be considered a limitation, the goal of this study was to purely assess radiographic changes in sagittal alignment after laminoplasty based on variations in preoperative sagittal alignment.

CONCLUSION

We anticipate that the results of this study will assist in the preoperative planning and counseling of

patients for whom posterior cervical laminoplasty is considered.

REFERENCES

- Hirabayashi K, Watanabe K, Wakano K, Suzuki N, Satomi K, Ishii Y. Expansive open-door laminoplasty for cervical spinal stenotic myelopathy. *Spine (Phila Pa 1976)*. 1983;8(7):693–699. doi:10.1097/00007632-198310000-00003
- Seichi A, Takeshita K, Ohishi I, et al. Long-term results of double-door laminoplasty for cervical stenotic myelopathy. *Spine (Phila Pa 1976)*. 2001;26(5):479–487. doi:10.1097/00007632-200103010-00010
- Lau D, Winkler EA, Than KD, Chou D, Mummaneni PV. Laminoplasty versus laminectomy with posterior spinal fusion for multilevel cervical spondylotic myelopathy: influence of cervical alignment on outcomes. *J Neurosurg Spine*. 2017;27(5):508–517. doi:10.3171/2017.4.SPINE16831
- Suk K-S, Kim K-T, Lee J-H, Lee S-H, Lim Y-J, Kim J-S. Sagittal alignment of the cervical spine after the laminoplasty. *Spine*. 2007;32(23):E656–E660. doi:10.1097/BRS.0b013e318158c573
- Ratliff JK, Cooper PR. Cervical laminoplasty: a critical review. *J Neurosurg*. 2003;98(3 Suppl):230–238. doi:10.3171/spi.2003.98.3.0230
- Kurokawa R, Kim P. Cervical laminoplasty: the history and the future. *Neurol Med Chir (Tokyo)*. 2015;55(7):529–539. doi:10.2176/nmc.ra.2014-0387
- Naderi S, Benzel EC, Baldwin NG. Cervical spondylotic myelopathy: surgical decision making. *Neurosurg Focus*. 1996;1(6):e1. doi:10.3171/foc.1996.1.6.1
- Lee CK, Shin DA, Yi S, et al. Correlation between cervical spine sagittal alignment and clinical outcome after cervical laminoplasty for ossification of the posterior longitudinal ligament. *J Neurosurg Spine*. 2016;24(1):100–107. doi:10.3171/2015.4.SPINE141004
- Sakai K, Yoshii T, Hirai T, et al. Cervical sagittal imbalance is a predictor of kyphotic deformity after laminoplasty in cervical spondylotic myelopathy patients without preoperative kyphotic alignment. *Spine (Phila Pa 1976)*. 2016;41(4):299–305. doi:10.1097/BRS.0000000000001206
- Lee JS, Son DW, Lee SH, Kim DH, Lee SW, Song GS. The predictable factors of the postoperative kyphotic change of sagittal alignment of the cervical spine after the laminoplasty. *J Korean Neurosurg Soc*. 2017;60(5):577–583. doi:10.3340/jkns.2017.0505.007
- Miyazaki M, Ishihara T, Notani N, Kanazaki S, Tsumura H. Relationship of T1 slope with loss of lordosis and surgical outcomes after laminoplasty for cervical ossification of the posterior longitudinal ligament. *Clin Neurol Neurosurg*. 2018;164:19–24. doi:10.1016/j.clineuro.2017.11.007
- Kim B, Yoon DH, Ha Y, et al. Relationship between T1 slope and loss of lordosis after laminoplasty in patients with cervical ossification of the posterior longitudinal ligament. *Spine J*. 2016;16(2):219–225. doi:10.1016/j.spinee.2015.10.042

Funding: The authors received no financial support for the research, authorship, and/or publication of this article.

Declaration of Conflicting Interests: The authors report no conflicts of interest in this work.

Disclosures: Ninad Bhat has nothing to disclose. Shane Burch discloses consulting fees from Medtronic, Nuvasive, and Zimmer/Biomet. Bobby Tay discloses grants or contracts from Nuvasive and Omega and consulting fees from DePuy/Synthes, Stryker, and Zimmer-Biomet. Sigurd H. Berven discloses grants or contracts from NSF, NIH, Nuvasive, and Omega (all payments paid to institution); royalties or licenses from Medtronic and Stryker; consulting fees from Medtronic, Stryker, Integrity, Medicea, and Innovasis; and stock or stock options from Providence and Green Sun. Vedat Deviren discloses grants or contracts from Nuvasive and Omegas (payments made to institution); royalties or licenses from Nuvasive and Alphatec; and consulting fees from Nuvasive, Alphatec, Seaspine, Medicea, and Zimmer-Biomet. Alekos Theologis discloses grants or contracts from NSF and NIH (all paid to institution); royalties or licenses from Alphatec; consulting fees

from Alphatec, Surgalign, DePuy Spine, Icotec, Carbofix, Ulrich Medical USA, and Restor3D; participation on an advisory board for Ulrich Medical USA and Restor3D; and stock or stock options from Carbofix and Restor3D.

Corresponding Author: Alekos A. Theologis, Department of Orthopedic Surgery, University of California - San Francisco (UCSF), 500 Parnassus Ave, MUW 318, San Francisco, CA 94315, USA; alekos.theologis@ucsf.edu

This manuscript is generously published free of charge by ISASS, the International Society for the Advancement of Spine Surgery. Copyright © 2022 ISASS. To see more or order reprints or permissions, see <http://ijssurgery.com>.