

## Are Sandwich Vertebrae Prone to Refracture After Percutaneous Vertebroplasty or Kyphoplasty? A Meta-Analysis

Xue-Yang Liu, Min Feng, Xiang-Long Zhang, Tao Zou, Zhi Huang, Jian-Dong Yang and Hui-Hui Sun

*Int J Spine Surg* published online 27 February 2024  
<https://www.ijssurgery.com/content/early/2024/02/23/8577>

This information is current as of May 4, 2025.

---

**Email Alerts** Receive free email-alerts when new articles cite this article. Sign up at:  
<http://ijssurgery.com/alerts>

# Are Sandwich Vertebrae Prone to Refracture After Percutaneous Vertebroplasty or Kyphoplasty? A Meta-Analysis

XUE-YANG LIU, BS<sup>1\*</sup>; MIN FENG, BS<sup>2\*</sup>; XIANG-LONG ZHANG, BS<sup>1</sup>; TAO ZOU, BS<sup>1</sup>; ZHI HUANG, BS<sup>1</sup>;  
JIAN-DONG YANG, PhD<sup>1</sup>; AND HUI-HUI SUN, MD<sup>1</sup>

<sup>1</sup>Department of Orthopedics, Clinical Medical College of Yangzhou University, Yangzhou, Jiangsu, China; <sup>2</sup>Day treatment ward, Clinical Medical College of Yangzhou University, Yangzhou, Jiangsu, China

\*Xue-Yang Liu and Min Feng contributed equally to the work.

## ABSTRACT

**Background:** The formation of sandwiched vertebrae (SDVs) after percutaneous vertebroplasty (PVP) or percutaneous kyphoplasty (PKP) has become a common phenomenon. Whether SDVs are more likely to fracture is still controversial. Therefore, we conducted a meta-analysis to provide medical evidence for whether SDVs are more prone to refracture than non-SDVs (NSDVs) after PVP or PKP.

**Methods:** This study was conducted in accordance with the criteria of the Preferred Reporting Items for Systematic Reviews and Meta-Analyses. Several databases, including PubMed, Embase, Medline databases, China National Knowledge Infrastructure, Wanfang, and Weipu, were thoroughly searched for relevant studies included from any point up until June 2022. Statistical analyses were performed using Revman 5.4.

**Results:** A total of 4052 individuals from 9 studies were enrolled. Overall, patients with SDV presented more risk to have refracture than patients with NSDV (OR = 1.57,  $P = 0.04$ ). The incidences of refracture were comparable between the 2 cohorts in studies with a follow-up time less than 3 years (OR = 1.28,  $P = 0.49$ ). However, patients with SDV were more prone to have refracture than patients with NSDV in studies with a follow-up time longer than 3 years (OR = 1.92,  $P = 0.009$ ). Moreover, patients with SDV were more likely to have refracture than patients with NSDV in studies that involved both PVP and PKP (OR = 1.62,  $P = 0.002$ ). In addition, age, low bone density, and postoperative kyphosis angle of sandwich fracture segments  $>10^\circ$  were independent factors to predict refracture.

**Conclusions:** Patients with SDV were more likely to have refracture after PVP or PKP, especially when the follow-up time was longer than 3 years.

**Level of Evidence:** 3.

Minimally Invasive Surgery

Keywords: sandwiched vertebrae, refracture, PVP, PKP, meta-analysis

## INTRODUCTION

The number of patients with new osteoporotic fractures was estimated to be 178 million in 2019, representing an increase of 33.4% since 1990 and still increasing every year.<sup>1</sup> Osteoporosis is characterized by the decrease of bone mass and destruction of bone tissue structure, leading to susceptibility to fragility fracture.<sup>2,3</sup> Vertebral fractures relating to osteoporosis are osteoporotic vertebral compression fractures (OVCFs), which often result in acute pain in the low back, spinal deformity in kyphosis, potential but rare neurological deficits,<sup>4</sup> and reduced quality of life for patients.

In the past, conservative treatment was recommended for OVCFs, considering age and surgical risk.<sup>5</sup> However, subsequent studies have shown that patients often die of multiple complications during conservative treatment, such

as deep vein thrombosis and pneumonia.<sup>6</sup> With the development and improvement of percutaneous vertebroplasty (PVP) and percutaneous kyphoplasty (PKP), early surgical intervention has gradually become the first choice of treatment.<sup>5</sup> However, these procedures raise questions regarding whether the sandwich vertebrae (SDVs; an unfractured vertebra located between 2 cemented vertebrae) are more likely to fracture. Since the upper and lower vertebrae have been hardened, potential biomechanical changes around SDV may cause it to be prone to fracture. Several studies have investigated the incidence of SDV fracture in comparison with other refracture conditions, but inconsistent outcomes were reported.<sup>7,8</sup> Thus, we aimed to conduct a meta-analysis on this aspect by analyzing domestic and foreign clinical studies and discuss whether prophylactic sandwich vertebral augmentation is needed.

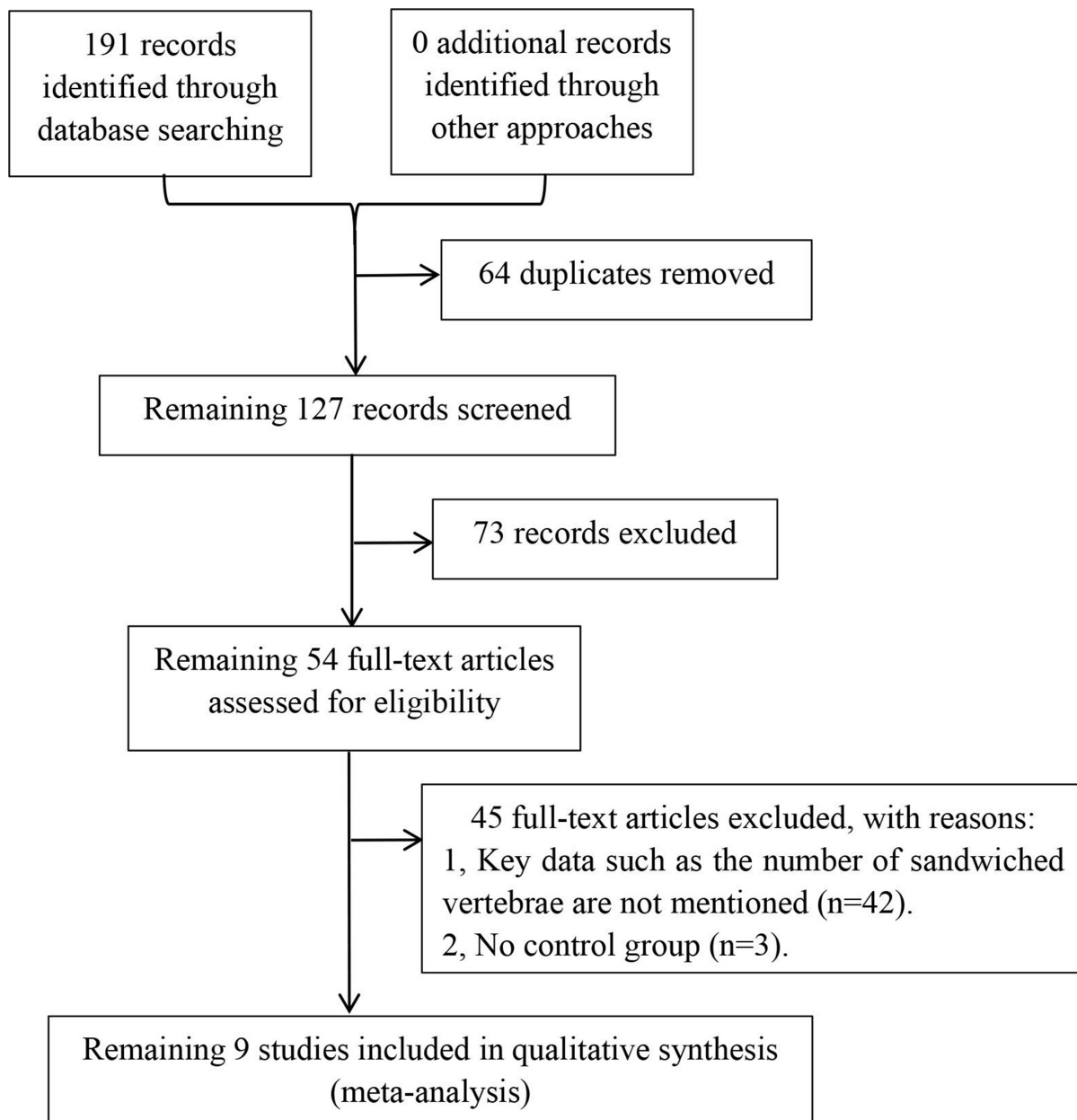


Figure 1. Flowchart of study selection process.

## METHODS

### Search Strategy

This study was conducted in accordance with the criteria of the Preferred Reporting Items for Systematic Reviews and Meta-Analyses.<sup>9</sup> Several databases, including PubMed, Embase, Medline databases, China National Knowledge Infrastructure, Wanfang, and Weipu, were thoroughly searched for relevant studies from the establishment time of these databases until June 2022. Specific Medical Subject Headings terms and keywords, including “sandwich vertebra,” “sandwich vertebrae,” “sandwich vertebral bodies,” “sandwich vertebral fracture,” “vertebral

compression fractures,” “fracture,” and “refracture,” were used in various combinations to search relevant articles. Eligible studies were limited to English and Chinese. References of key articles were screened for additional potentially relevant articles. The search strategy is shown in Figure 1.

### Inclusion Criteria

Studies were included if they included patients with SDV and NSDV (controls) for comparison; if interventions were manual therapy techniques (PVP or PKP); if outcomes were fractures of SDV and NSDV; if they

reported the rate of occurrence of fractures (as the number of “events”) among SDV patients compared with NSDV subjects; and if the SDVs were formed after PVP or PKP (definition: a well-preserved vertebral body between 2 cement-augmented vertebrae).<sup>10</sup>

### Exclusion Criteria

Duplicate studies were excluded. Studies in which pathological fractures were caused by tumor or hyperparathyroidism were also excluded. Additionally, studies with incomplete data or no control group were excluded.

### Data Extraction

A standard data extraction form was used by 2 reviewers to independently extract information and checked by other reviewers for accuracy. Essential information was extracted, including the first author, publication year, number of patients, age, and follow-up duration. Discrepancies were resolved by a consensus among the study team.

### Quality Assessment

We finally used the Quality Assessment of Diagnostic Accuracy Studies (QUADAS)-2 quality assessment modified by Zhong to assess the quality of enrolled studies.<sup>11</sup>

### Statistical Analysis

RevMan5.4 software was used to statistically analyze the data of the included studies. Standardized mean difference was used to express the effect index of continuous variable data. The effect index of count data was expressed as the odds ratio. Each effect index was expressed with a 95% confidence interval. Heterogeneity was assessed using the Q-test and quantified with the  $I^2$  index. If  $I^2 \leq 50\%$ , the fixed effects model was used for analysis. Otherwise, the random effect model

was used. If heterogeneity could not be ruled out, subgroup analysis was performed to determine the source of heterogeneity.

## RESULTS

### Study Characteristics

Nine studies were included in the meta-analysis, including 5 retrospective studies, 1 case-control study, and 3 cohort studies.<sup>7,8,12–18</sup> A summary of included studies is provided in Table 1. The publication year ranged from 2007 to 2022, study sizes ranged from 55 to 1321 participants, and mean ages ranged from 67.8 to 77.8 years.

### Quality Assessment Result

The studies were evaluated using the QUADAS-2 quality assessment. All of the studies were of high quality (Table 2). The funnel plot shows that the publication bias was minimal in the included studies (Figure 2).

## META-ANALYSIS RESULTS

Random effects model was used for overall analysis of the 9 studies due to high heterogeneity ( $I^2 = 56\%$ ), and the results showed that the patients with SDV presented more risk to have refracture than patients with NSDV (OR = 1.57,  $P = 0.04$ ; Figure 3). Besides, subgroup analysis was further performed according to the follow-up duration, and we revealed that the incidences of refracture were comparable between the 2 cohorts in studies with a follow-up time less than 3 years ( $I^2 = 58\%$ , OR = 1.28,  $P = 0.49$ ; Figure 4). However, patients with SDV were more prone to refracture than patients with NSDV in studies with a follow-up time longer than 3 years ( $I^2 = 57\%$ , OR = 1.92,  $P = 0.009$ ; Figure 4). Moreover, we performed another subgroup analysis according to surgical methods used in each study: PVP alone, PKP alone, and PVP and

**Table 1.** Characteristics of studies examining the difference of refracture between sandwich vertebra and nonsandwich vertebra.

Study	Study Type	Participants, <i>n</i>	Mean Age, y	Gender, Male/Female	Mean Follow-Up, mo
Bo et al (2022) <sup>7</sup>	Retrospective	225	73.8 (62.8–84.7)	79/146	28.55 (15.6–41.5)
Han et al (2018) <sup>8</sup>	Retrospective	132	76.6 (68.4–84.8)	15/117	15.9 (6.2–24.62)
Chiu et al (2020) <sup>12</sup>	Retrospective	1321	77.8 (70.1–85.5)	NM	39.6 (24.0–61.0)
Hierholzer et al (2008) <sup>13</sup>	Retrospective	316	73.0 (-)	257/59	8.0 (6.0–56.0)
Jiang et al (2017) <sup>14</sup>	Case-control	111	68.0 (46.0–90.0)	17/94	26.3 (17.6–35.0)
Liu et al (2021) <sup>15</sup>	Retrospective	1228	73.9 (53.0–89.0)	27/88	39.4 (12.6–71.6)
Pitton et al (2007) <sup>16</sup>	Prospective	191	70.7 (61.0–80.4)	61/130	19.7 (7.0–32.4)
Zeng et al (2018) <sup>17</sup>	Prospective	349	60.0 (-)	NM	40.0 (12.0–60.0)
Zhang et al (2021) <sup>18</sup>	Retrospective	179	74.4 (62.8–85.5)	NM	21.5 (15.7–27.2)

Abbreviation: NM, not mentioned.

**Table 2.** QUADAS-2 quality assessment result of the included studies.

Study	Was a Consecutive or Random Sample of Patients Enrolled?	Did the Study Avoid Inappropriate Exclusions?	Was the Method of Imaging Tests Described?	Were All Patients Tested With MRI or CT?
Bo et al (2022) <sup>7</sup>	Consecutive	Yes	Yes	Yes
Han et al (2018) <sup>8</sup>	Consecutive	Yes	Yes	Yes
Chiu et al (2020) <sup>12</sup>	Consecutive	Yes	Yes	Yes
Hierholzer et al (2008) <sup>13</sup>	Consecutive	Yes	Yes	Yes
Jiang et al (2017) <sup>14</sup>	Consecutive	Yes	Yes	Yes
Liu et al (2021) <sup>15</sup>	Consecutive	Yes	Yes	Yes
Pitton et al (2007) <sup>16</sup>	Consecutive	Yes	Yes	Yes
Zeng et al (2018) <sup>17</sup>	Consecutive	Yes	Yes	Yes
Zhang et al (2021) <sup>18</sup>	Consecutive	Yes	Yes	Yes

Abbreviations: CT, computed tomography; MRI, magnetic resonance imaging.

PKP. Among the studies that involved both PVP and PKP, no heterogeneity was detected ( $I^2 = 0\%$ ), and patients with SDV were more likely to have refracture than patients with NSDV only in these studies (OR = 1.62,  $P = 0.002$ ; Figure 5). In addition, some studies pointed out that age, bone density, and postoperative kyphosis of sandwich fracture segments were independent risk factors that affected postoperative sandwich vertebral refracture.<sup>10,12,16</sup> Low bone density and postoperative kyphosis angle of sandwich fracture segments  $>10^\circ$  were the most important factors.

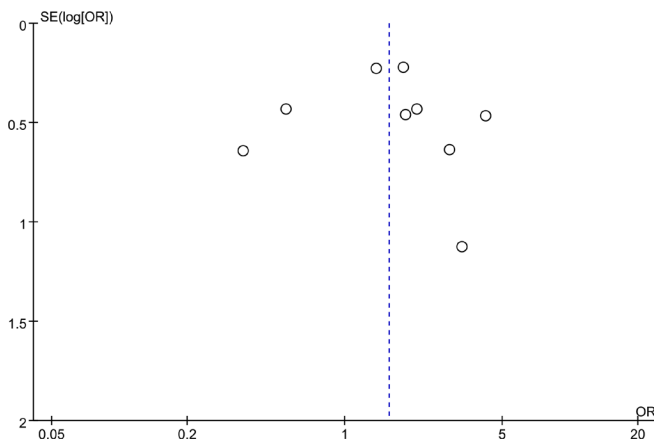
## DISCUSSION

OVFC is a very common orthopedic disorder. In the past, conservative treatment was preferred due to limited surgical approaches. However, many patients suffer from various complications, such as unrelieved pain, kyphosis, hypostatic pneumonia caused by bed rest, and even death caused by deep vein thrombosis. Therefore, the progress of minimally invasive surgical methods, PVP or PKP, is now preferred.<sup>19</sup> PVP and PKP were associated with less trauma, fast recovery, wide age applicability, and early

ambulation to avoid bed-related complications. Importantly, although PVP and PKP have some disadvantages, such as bone cement leakage, postoperative vertebral height loss, and vascular and nerve injuries, very few severe complications were reported.<sup>20</sup>

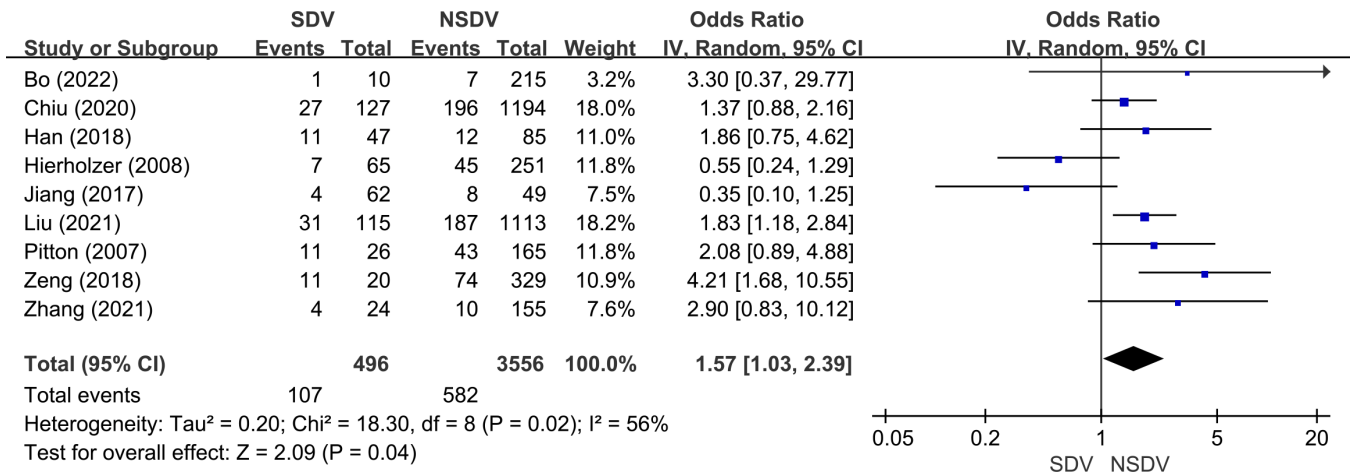
SDVs formed after PVP or PKP are a common and special condition. It was believed that after percutaneous vertebral augmentation, the stiffness and hardness of the cemented vertebral body were increased, and the stress distribution was shifted to the adjacent vertebral body, especially to the sandwiched vertebral body.<sup>21,22</sup> Han and Jang reported that the SDV was more likely to fracture due to the double load,<sup>8</sup> which is consistent with the conclusion of this article, and some other researchers had the same conclusion.<sup>15,17,18</sup> However, some other scholars established the corresponding percutaneous vertebral augmentation model and analyzed it by finite element method. They found that the maximum stress, deformation, and stiffness of the SDVs did not change significantly in the patients undergoing PVP or PKP,<sup>23</sup> which means SDVs are not easy to fracture. In addition, Jiang et al found that the probability of vertebral fracture in the SDV group was not significantly higher than that in NSDV group.<sup>14</sup> Many other studies comparing SDVs with ordinary adjacent vertebrae reached the same conclusion.<sup>7,12-14,16</sup>

Due to these inconsistent outcomes on whether SDVs are prone to refracture, we performed this meta-analysis and found that the overall incidence of refracture in patients with SDV was significantly higher than that in patients with NSDV. Subgroup analysis further revealed that patients with SDV in the studies involved with both PVP and PKP were more likely to experience fracture. However, the incidence of refracture between the 2 cohorts in studies that involved only PVP or PKP was comparable, and we believe that different sample sizes in the 3 subgroups were the potential reason. This finding also indicated that more studies with a large sample size were further required to confirm our results.



**Figure 2.** Funnel plot of included studies regarding the difference of refracture between sandwich vertebra and nonsandwich vertebra.



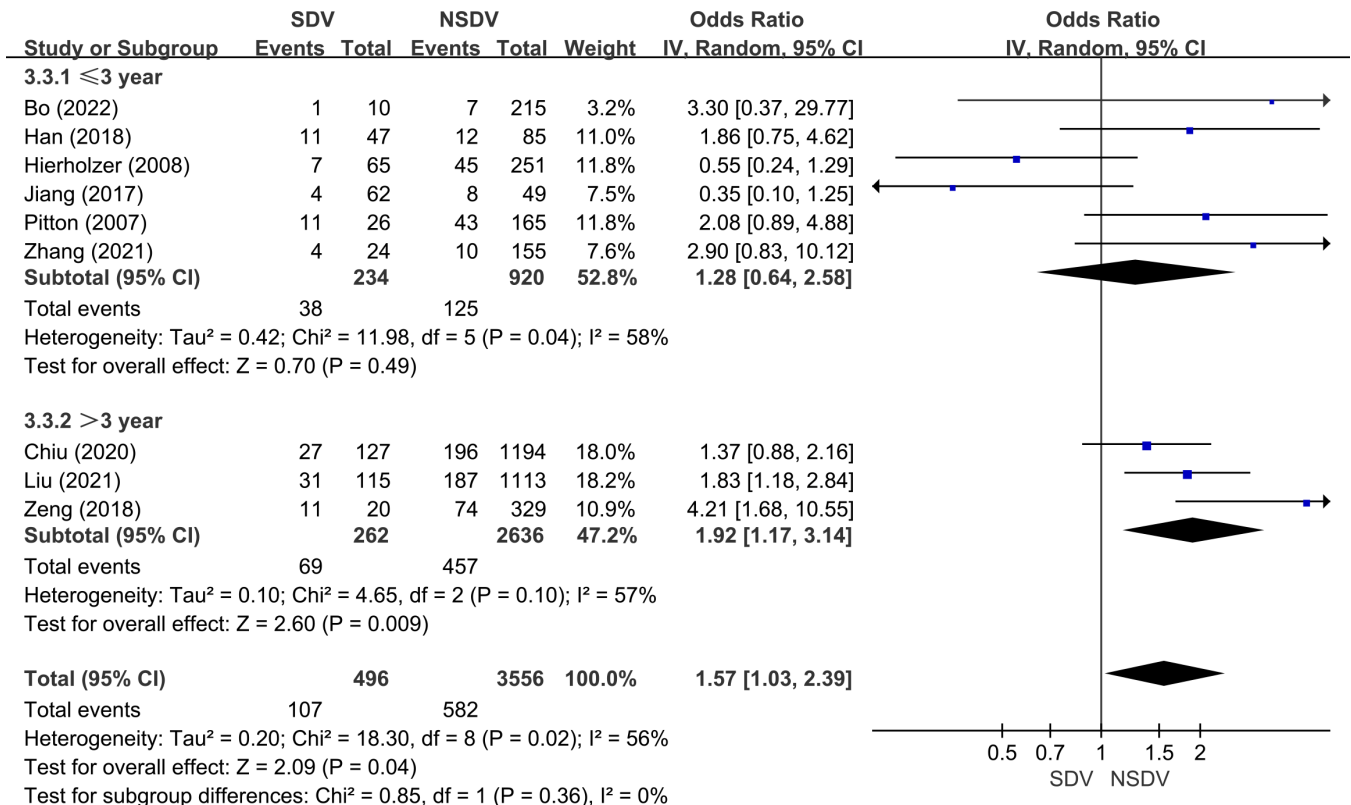


**Figure 3.** Forest plot of included studies that examined the difference of refracture between sandwich vertebra and nonsandwich vertebra. Abbreviations: SDV, sandwich vertebrae; NSDV, nonsandwich vertebrae.

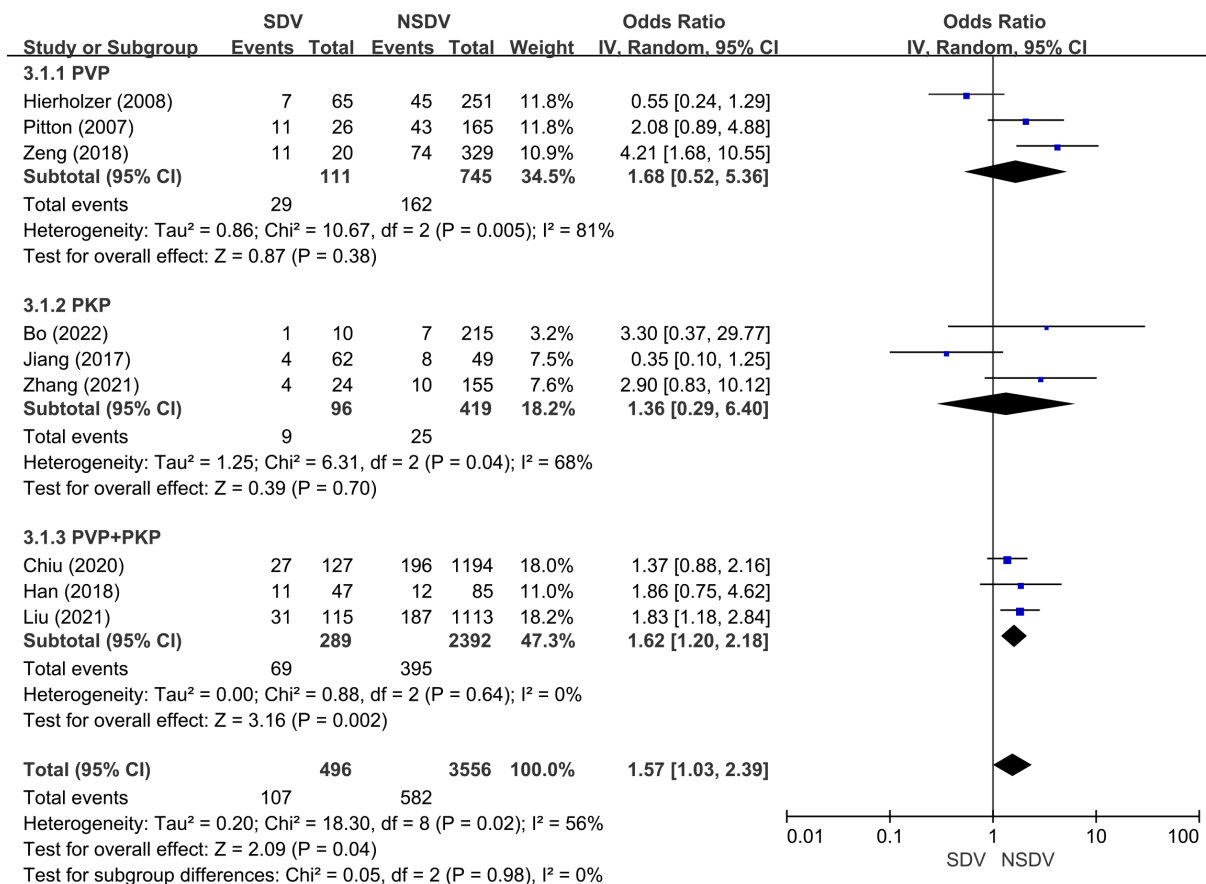
In addition, considering that different follow-up durations may have impact on refracture incidence, the enrolled studies were further divided into 2 subgroups according to follow-up time, and we found that SDV was more likely to fracture compared with NSDV in studies with a follow-up longer than 3 years. Liu et al reported that 85% of SDV was fracture-free during 5-year follow-up.<sup>15</sup> However, this article did not measure bone mineral density and did not

mention the status of postoperative antiosteoporosis treatment, which may affect the accuracy of the result.

Identifying the predictors to refracture after PVP and PKP is really important. Wei reported that the patients with T-scores  $\leq -3.5$  SD and postoperative kyphosis angles  $\geq 10^\circ$  were more likely to have refracture.<sup>24</sup> Chiu et al found that gender was the factor associated with sandwich vertebral fracture, and men were susceptible to fragility fracture.<sup>12</sup>



**Figure 4.** Forest plot of included studies that perform subgroup analysis according to the follow-up duration. Abbreviations: SDV, sandwich vertebrae; NSDV, nonsandwich vertebrae.



**Figure 5.** Forest plot of included studies that perform subgroup analysis according to the operative methods. Abbreviations: SDV, sandwich vertebrae; NSDV, nonsandwich vertebrae.

We believe that this is due to the fact that men normally undertake more physical labor in society. Meanwhile, the compliance of men is worse than that of women, due to the fact that they do not strictly follow basic treatments such as antiosteoporosis after surgery. Besides, some other researchers found that age, bone density, and location in the thoracolumbar segment were independent risk factors that affected postoperative SDV refracture.<sup>10,16</sup> Even the same conclusion has been reached at the level of adjacent and distant vertebrae.<sup>18,25</sup> They divided patients into the group of T10 to L2 junction and other junctions and compared the incidence of sandwich vertebral fractures between the 2 groups. They proved that T10 to L2 levels were associated with a significantly higher incidence of sandwich vertebral fracture. We think that this is mainly because thoracolumbar is the stress concentration area of the spine. Low bone density and postoperative kyphosis angle of sandwich fracture segments  $>10^\circ$  were the key points.

For prophylactic surgery, Li et al divided patients into observation group (treated with the small-dose bone cement prophylactic strengthening of SDV) and control group (treated without SDV strengthening) and found that

the small-dose bone cement prophylactic strengthening of SDV can reduce the risk of postoperative fracture.<sup>26</sup> Jia et al divided patients with SDV into a preventive group and patients with NSDV into a nonpreventive group, and they reported that the fracture rate in the nonpreventive group was 21.6, whereas no new fractures were detected in the prevention group.<sup>27</sup> Some researchers also found that prophylactic cement injection into nonfracture vertebrae may prevent new compression fractures after vertebroplasty for osteoporotic patients.<sup>28</sup> However, Liu et al reported that sandwich vertebral refracture risk increases with the number of augmented vertebrae, and prophylactic augmentation of every SDV may be unnecessary.<sup>29</sup>

### Limitations

There were several limitations to the study. First, this meta-analysis mainly included retrospective studies, while high-quality randomized controlled trials were currently lacking. Second, the studies about SDVs are still rare until now, and the quality of the literature is relatively low. Third, the follow-up time is short in some studies, and none of the included studies were followed up more than

5 years. Fourth, some articles did not mention postoperative antiosteoporosis, which may affect the accuracy of the final conclusions. Therefore, more clinical studies are still required to prove it.<sup>5</sup>

## CONCLUSION

Patients with SDV were more likely to have refracture after PVP or PKP, especially when the follow-up time was longer than 3 years.

## REFERENCES

1. Wu A-M, Bisignano C, James SL. Global, regional, and national burden of bone fractures in 204 countries and territories, 1990-2019: a systematic analysis from the global burden of disease study 2019. *Lancet Healthy Longev*. 2021;2(9):e580–e592. doi:10.1016/S2666-7568(21)00172-0
2. Bijlsma AY, Meskers CGM, Westendorp RGJ, Maier AB. Chronology of age-related disease definitions: osteoporosis and sarcopenia. *Ageing Res Rev*. 2012;11(2):320–324. doi:10.1016/j.arr.2012.01.001
3. Kutsal FY, Ergin Ergani GO. Vertebral compression fractures: still an unpredictable aspect of osteoporosis. *Turk J Med Sci*. 2021;51(2):393–399. doi:10.3906/sag-2005-315
4. Prost S, Pesenti S, Fuentes S, Tropiano P, Blondel B. Treatment of osteoporotic vertebral fractures. *Orthop Traumatol Surg Res*. 2021;107(1S):102779. doi:10.1016/j.otsr.2020.102779
5. Shi G, Li P-C, Zhang S-H, Gao Y-Z, Wei X-C. Percutaneous kyphoplasty for the treatment of senior patient with acute and chronic osteoporotic vertebral compression fractures [Progress on treatment of osteoporotic vertebral compression fracture]. *Zhong-guo Gu Shang*. 2013;26(10):820–823.
6. Brower RG. Consequences of bed rest. *Crit Care Med*. 2009;37(10 Suppl):S422–S428. doi:10.1097/CCM.0b013e-3181b6e30a
7. Yang B, Zhao Y, Zhao Y. Is the incidence of sandwich vertebral fracture higher than that of ordinary adjacent vertebral fracture after PKP. *Medicine*. 2022;101(27):e29900. doi:10.1097/MD.00000000000029900
8. Han S, Jang IT. Analysis of adjacent fractures after two-level percutaneous vertebroplasty: is the intervening vertebral body prone to re-fracture. *Asian Spine J*. 2018;12(3):524–532. doi:10.4184/asj.2018.12.3.524
9. Liberati A, Altman DG, Tetzlaff J, et al. The PRISMA statement for reporting systematic reviews and meta-analyses of studies that evaluate healthcare interventions: explanation and elaboration. *BMJ*. 2009;339:b2700. doi:10.1136/bmj.b2700
10. Yang J. Risk factors of re-fracture of the sandwich vertebrae after vertebral body augmentation for spinal osteoporotic sandwich fractures. *J Trauma Surg*. 2020;22(6):433–437. doi:10.3969/j.issn.1009-4237.2020.06.007
11. Jiang H. Incidence of spontaneous resorption of lumbar disc herniation: a meta-analysis. *Pain Physician*. 2018;20(1):E45–E52. doi:10.36076/ppj.2017.1.E45
12. Chiu P-Y, Kao F-C, Hsieh M-K, et al. A retrospective analysis in 1347 patients undergoing cement augmentation for osteoporotic vertebral compression fracture: is the sandwich vertebra at a higher risk of further fracture?. *Neurosurgery*. 2021;88(2):342–348. doi:10.1093/neuros/nyaa435
13. Hierholzer J, Fuchs H, Westphalen K, Baumann C, Slosch C, Schulz R. Incidence of symptomatic vertebral fractures in patients after percutaneous vertebroplasty. *Cardiovasc Intervent Radiol*. 2008;31(6):1178–1183. doi:10.1007/s00270-008-9376-7
14. Jiang J, Xiao B, Yajun L, et al. Relationship of cement augmentation on sandwiched osteoporosis vertebral compression fracture and adjacent vertebral re-fracture. *J Clin Orthop Res*. 2017;2(4). doi:10.19548/j.2096-269x.2017.04.009
15. Liu J, Tang J, Chen G, et al. Comparison of refracture risk between sandwich vertebrae and ordinary adjacent vertebrae. *Chinese J Restor Reconstr Surg*. 2021;35(9):1161–1166. doi:10.7507/1002-1892.202104060
16. Pitton MB, Herber S, Bletz C, et al. CT-guided vertebroplasty in osteoporotic vertebral fractures: incidence of secondary fractures and impact of intradiscal cement leakages during follow-up. *Eur Radiol*. 2008;18(1):43–50. doi:10.1007/s00330-007-0694-y
17. Zheng-Xing Z. *Subsequent Vertebral Compression Fractures after Vertebroplasty Compared with Conservative Treatment A Comparative Study*. [Master]. Guangdong Medical University; 2018. <https://d.wanfangdata.com.cn/thesis/ChJUaGVzaXNOZXdTmJAYmJAMDESCUQwMTYwNjc4NhoIZWgybmpyY24>.
18. Zhang Y, Sun Z, Yin P, Zhu S, Hai Y, Su Q. Do sandwich vertebral bodies increase the risk of post-augmentation fractures? A retrospective cohort study. *Arch Osteoporos*. 2021;16(1):180. doi:10.1007/s11657-021-00922-9
19. Zhang J, He X, Fan Y, Du J, Hao D. Risk factors for conservative treatment failure in acute osteoporotic vertebral compression fractures (Ovcfs). *Arch Osteoporos*. 2019;14(1):24. doi:10.1007/s11657-019-0563-8
20. Long Y, Yi W, Yang D. Advances in vertebral augmentation systems for osteoporotic vertebral compression fractures. *Pain Res Manag*. 2020;2020:3947368. doi:10.1155/2020/3947368
21. Fribourg D, Tang C, Sra P, Delamarter R, Bae H. Incidence of subsequent vertebral fracture after kyphoplasty. *Spine*. 2004;29(20):2270–2276. doi:10.1097/01.brs.0000142469.41565.2a
22. Kim MH, Lee AS, Min SH, Yoon SH. Risk factors of new compression fractures in adjacent vertebrae after percutaneous vertebroplasty. *Asian Spine J*. 2011;5(3):180–187. doi:10.4184/asj.2011.5.3.180
23. Baroud G, Nemes J, Heini P, Steffen T. Load shift of the intervertebral disc after a vertebroplasty: a finite-element study. *Eur Spine J*. 2003;12(4):421–426. doi:10.1007/s00586-002-0512-9
24. Wei J. Risk factors of central vertebral refracture after sandwich type osteoporotic vertebral compression fracture. *Modern Practical Medicine*. 2020;32(3). doi:10.3969/j.issn.1671-0800.2020.03.023
25. Dai C, Liang G, Zhang Y, Dong Y, Zhou X. Risk factors of vertebral re-fracture after PVP or PKP for osteoporotic vertebral compression fractures, especially in eastern Asia: a systematic review and meta-analysis. *J Orthop Surg Res*. 2022;17(1):161. doi:10.1186/s13018-022-03038-z
26. Li X, She L, Fan J, et al. Clinical analysis of small-dose bone cement prophylactic strengthening of sandwich vertebra in the treatment of "sandwich" osteoporotic vertebral compression fracture. *J Bengbu Med Coll*. 2021;10. doi:10.13898/j.cnki.issn.1000-2200.2021.10.028



27. Jia P, Tang H, Chen H, et al. Prophylactic vertebroplasty procedure applied with a resorbable bone cement can decrease the fracture risk of sandwich vertebrae: long-term evaluation of clinical outcomes. *Regen Biomater*. 2017;4(1):47–53. doi:10.1093/rb/rbw037
28. Kobayashi N, Numaguchi Y, Fuwa S, et al. Prophylactic vertebroplasty: cement injection into non-fractured vertebral bodies during percutaneous vertebroplasty. *Acad Radiol*. 2009;16(2):136–143. doi:10.1016/j.acra.2008.05.005
29. Liu J, Tang J, Gu Z, Zhang Y, Yu S, Liu H. Fracture-free probability and predictors of new symptomatic fractures in sandwich, ordinary-adjacent, and non-adjacent vertebrae: a vertebra-specific survival analysis. *J Neurointerv Surg*. 2021;13(11):1058–1062. doi:10.1136/neurintsurg-2020-016985

**Funding:** This study was funded by the Natural Science Foundation of Jiangsu Province (BK20230294), Natural Science Foundation of Yangzhou City (SZR2023000040), the Lvyang Jinfeng Talent Project of Yangzhou City (LYJF00027), and Jiangsu Innovative and Entrepreneurial Talent Programme (JSS-CBS20211597).

**Declaration of Conflicting Interests:** The authors declare that no conflict of interest exists.

**Ethical Statement:** This study was a retrospective assessment of the public data, so the approval of the institutional review committee is not required.

**Corresponding Author:** Jian-Dong Yang and Hui-Hui Sun, Department of Orthopedics, Clinical Medical College of Yangzhou University, Yangzhou, Jiangsu, China; yangjiandong69@sohu.com, sunhuihui5566@163.com

This manuscript is generously published free of charge by ISASS, the International Society for the Advancement of Spine Surgery. Copyright © 2024 ISASS. To see more or order reprints or permissions, see <http://ijssurgery.com>.