

Can Dynamic Spinal Stabilization Be an Alternative to Fusion Surgery in Adult Spinal Deformity Cases?

Ali Fahir Ozer, Mehmet Yigit Akgun, Ege Anil Ucar, Mehdi Hekimoglu, Ahmet Tulgar Basak, Caner Gunerbuyuk, Sureyya Toklu, Tunc Oktenoglu, Mehdi Sasani, Turgut Akgul and Ozkan Ates

Int J Spine Surg published online 1 April 2024
<https://www.ijssurgery.com/content/early/2024/04/01/8588>

This information is current as of May 9, 2025.

Email Alerts Receive free email-alerts when new articles cite this article. Sign up at:
<http://ijssurgery.com/alerts>

Can Dynamic Spinal Stabilization Be an Alternative to Fusion Surgery in Adult Spinal Deformity Cases?

ALI FAHIR OZER, MD^{1,2,3}; MEHMET YIGIT AKGUN, MD^{1,2}; EGE ANIL UCAR, MD⁴; MEHDI HEKIMOGLU, MD⁵; AHMET TULGAR BASAK, MD⁵; CANER GUNERBUYUK, MD²; SUREYYA TOKLU, MD⁶; TUNC OKTENOGU, MD^{1,2}; MEHDI SASANI, MD^{1,2}; TURGUT AKGUL, MD²; AND OZKAN ATEŞ, MD^{1,2}

¹Department of Neurosurgery, Koc University Hospital, Istanbul, Turkey; ²Spine Center, Koc University Hospital, Istanbul, Turkey; ³Bioengineering and Orthopaedic Surgery Colleges of Engineering and Medicine, University of Toledo, Toledo, OH, USA; ⁴Faculty of Medicine, Koc University, Istanbul, Turkey; ⁵Department of Neurosurgery, American Hospital, Istanbul, Turkey; ⁶Department of Neurosurgery, Erzurum Bolge Research and Education Hospital, Erzurum, Turkey

ABSTRACT

Background: Rigid stabilization and fusion surgery are widely used for the correction of spinal sagittal and coronal imbalance (SCI). However, instrument failure, pseudoarthrosis, and adjacent segment disease are frequent complications of rigid stabilization and fusion surgery in elderly patients. In this study, we present the results of dynamic stabilization and 2-stage dynamic stabilization surgery for the treatment of spinal SCI. The advantages and disadvantages are discussed, especially as an alternative to fusion surgery.

Methods: In our study, spinal, sagittal, and coronal deformities were corrected with dynamic stabilization performed in a single session in patients with good bone quality (without osteopenia and osteoporosis), while 2-stage surgery was performed in patients with poor bone quality (first stage: percutaneous placement of screws; second stage: placement of dynamic rods and correction of spinal SCI 4–6 months after the first stage). One-stage dynamic spinal instrumentation was applied to 20 of 25 patients with spinal SCI, and 2-stage dynamic spinal instrumentation was applied to the remaining 5 patients.

Results: Spinal SCI was corrected with these stabilization systems. At 2-year follow-up, no significant loss was observed in the instrumentation system, while no significant loss of correction was observed in sagittal and coronal deformities.

Conclusion: In adult patients with spinal SCI, single or 2-stage dynamic stabilization is a viable alternative to fusion surgery due to the very low rate of instrument failure.

Clinical Relevance: This study questions the use of dynamic stabilization systems for the treatment of adult degenerative deformities.

Level of Evidence: 4.

Lumbar Spine

Keywords: spinal, deformity, dynamic, stabilization, imbalance

INTRODUCTION

Instrumentation and fusion surgery are the only indisputable methods for all kinds of deformity surgery. However, sagittal and coronal imbalance (SCI) is quite common in individuals older than 65 years. These patients, who typically have comorbidities, account for 32% to 68% of the population¹ and are at risk of serious complications. Indeed, complication rates in adult deformity surgery range from 13% to 41%. Advanced age, smoking, and osteoporosis are known risk factors for perioperative complications.^{2–7}

Revision surgery in a patient with complications can cause even more serious problems. Therefore, patients who are not willing to undergo surgery in the early stages are liable to develop fixed deformities over time, which can significantly impact surgical success.

The frequency of use of dynamic systems in deformity surgery has increased over the past decade. Since bone growth is not complete in idiopathic adolescent scoliosis, the aim is to provide asymmetrical growth by using dynamic systems from both the posterior and anterior approaches. Correction of the deformity was considered and successful results were published by Crawford and Lenke for the first time in 2010.^{8–13}

Dynamic systems have been successfully used in a single motion segment and for the treatment of degenerated spine adjacent to the fusion.^{14–18} Moreover, dynamic stabilization has been successfully used in multilevel instability and degenerative scoliosis surgery.^{19–21}

Screw loosening and pseudoarthrosis due to poor bone quality are the most serious problems in elderly patients who have undergone fusion

and instrumentation as part of deformity surgery. Dynamic stabilization and/or 2-stage spinal stabilization surgery have been reported as a solution to instrument failure and pseudoarthrosis, which are important complications of spinal fusion surgery.^{22–24} In the present study, we share our experience of using dynamic system for the treatment of spinal SCI in adults.

MATERIALS AND METHODS

Patient Selection Criteria

The medical records of 25 patients who were operated on using dynamic systems for SCI and had at least 2 years of clinical follow-up were retrospectively analyzed. Patients with mobile deformities were selected as ideal candidates for dynamic stabilization surgery. In patients with kyphotic deformity, the posture in which the patient can stand upright without support and the forward-leaning posture of the spine after walking or standing were evaluated using standing lateral radiographs of the spine. While this method of obtaining spine x-ray images may be subject to criticism, it was chosen because patients with kyphotic deformities initially stand in an upright posture but may start to lean forward after a while and complain of low back pain.

The scoliotic deformity was evaluated with anteroposterior lying and standing radiographs, as well as lateral bending view radiographs. This method can help confirm the mobile deformity. All spinal radiographs were obtained in this way.

Considering the etiology of the patients, the deformities of the spine in our cohort developed as a result of the degenerative process. All patients underwent dual-energy x-ray absorptiometry, magnetic resonance imaging (MRI), and computed tomography (CT). The presence of scoliosis, kyphosis, and kyphoscoliosis was investigated in each patient, and preoperative values were noted. Patients with at least 2 years of follow-up were included in the study.

Surgical Technique

Two-stage surgery was preferred for patients with osteoporosis (T score: below -2.5) detected by bone density measurement, and single-stage surgery was preferred for patients with T score above -2.5 . Two-stage surgery was preceded by 6-month treatment for osteoporosis.

Two-stage surgery was performed in 5 of 25 patients. In the first stage, spinal anesthesia was administered to 3 elderly patients while general anesthesia was administered to the rest. In the first surgery, screws were

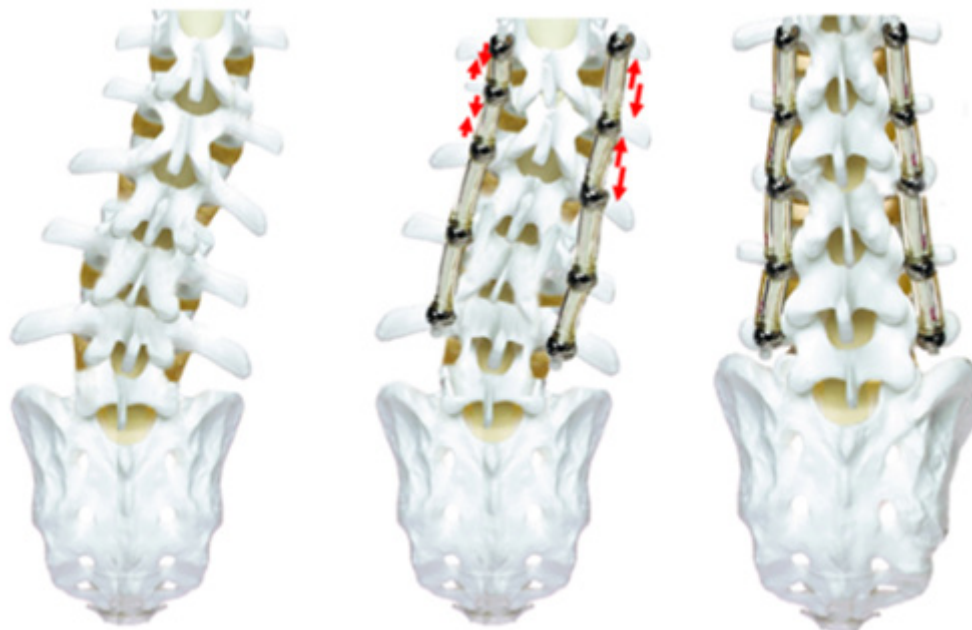


Figure 1. If the Dynesys system is used, the residual deformity is corrected by cutting the spacers shorter than normal and providing greater torque than normal in the concave part of the deformity.




Figure 2. When Orthrus and Peek rods are used, compressing the concave side and locking the rod to the screw in this manner is sufficient to provide additional improvement.

inserted by the Wiltse method, either by opening the skin from the midline and making small incisions over the fascia or by the minimally invasive percutaneous method using neuronavigation. The second surgery of the patients was planned 4 months after the first surgery. After confirming the osteointegration of the screws with the control CT images, decompression was made to the required levels and the rods were placed. In single-stage surgeries, screwing, rod insertion, and, where necessary, decompression were performed in the same session, and the Wiltse technique was used for stabilization.

In patients with scoliotic deformity, since the deformity is partially corrected in the supine position, if the Dynesys system is used, the remaining deformity is corrected as much as possible by cutting the spacers shorter than normal and providing greater torque than normal in the concave part of the deformity (Figure 1).

When Orthrus and Peek rods are used, compressing the concave side and locking the rod to the screw in this manner is sufficient to provide additional improvement

(Figure 2). Dynamic stabilization was performed with 2 different systems in this cohort. The Dynesys system was used in 19 patients, and the Orthrus system was used in 6 patients.

In kyphotic deformities, normal sagittal balance is achieved by positioning the table in the second stage, accompanied by fluoroscopy, and the rods are placed at this stage. In this way, the impaired sagittal balance is restored to normal (Figure 3).

Because many patients have both deformities concomitantly, both procedures are performed at the same time.

In patients who have neurologic findings preoperatively due to foraminal or main canal stenosis or disc herniation, decompression can be performed at the first surgery, and only unilateral or sometimes bilateral temporary short rods can be placed on these segments to loosen only the screws that concern these segments (Figure 4). Since cortical bone is formed around the loosened screw when the screw is changed in the second surgery with a larger screw, the screw clings to the more stable bone, greatly reducing the possibility of loosening. Patients are evaluated with CT after an average of 16 to 20 weeks to determine the osteointegration of screws. If osteointegration is completed, then rods are placed and screws are connected to each other (Figure 5).

Osteoporosis Treatment

In patients with T score below -2.5 , calcium 1×1 (400 mg) and vitamin D3 20,000 units/week were prescribed for 6 months.

Clinical and Radiological Follow-Up

Scoliotic Cobb angle, thoracic kyphosis angle, sagittal vertical axis (SVA), and pelvic parameters were measured together with the radiologic imaging of patients. Moreover, degenerative changes in the

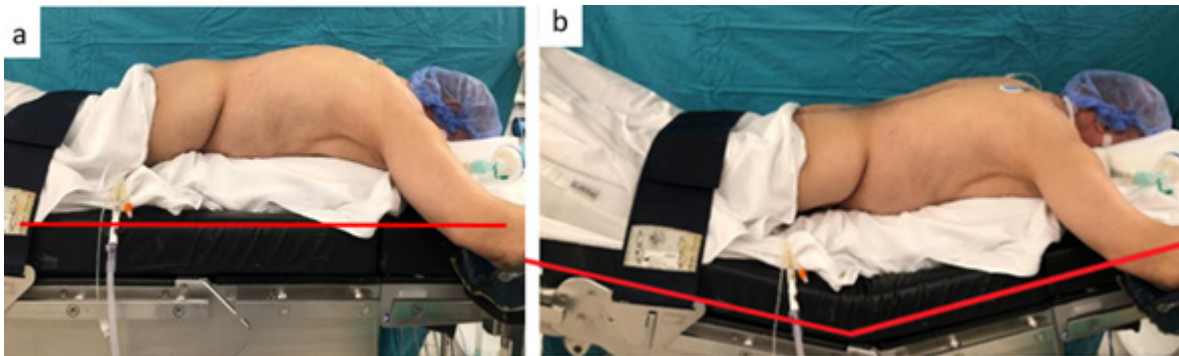


Figure 3. In kyphotic deformities, in the second stage, (A) the table is positioned under the scope, (B) normal sagittal balance is achieved, and the rods are placed.

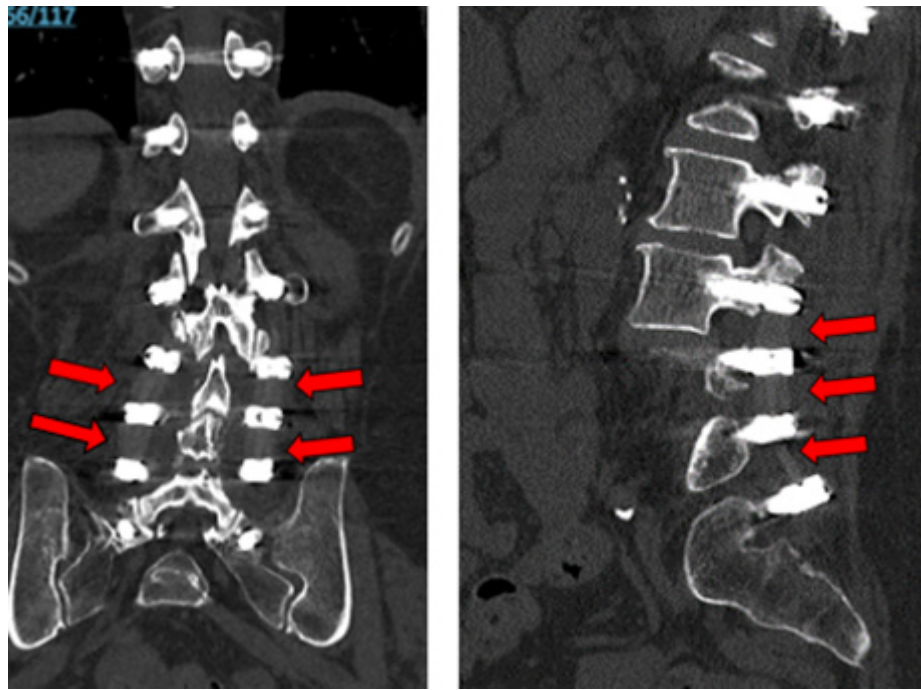


Figure 4. In patients undergoing 2-stage surgery, temporary rods can be placed in the segments that were decompressed in the first stage. In this case, the risk of screw loosening in the relevant segments increases.

spine were evaluated with radiologic parameters. Spinal stenosis grades were detailed using Schizas and Lee classification systems, and disc degeneration grades were detailed using Pfirrmann classification system. All patients were evaluated using visual analog scale (VAS) and Oswestry Disability Index (ODI) scores in the preoperative period, in the early postoperative period, and at the 6-, 12-, and 24-month postoperative follow-up.

Statistical Analysis

Statistical analyses were performed using SPSS version 22 (SPSS Inc., Chicago, IL, USA). Categorical variables were presented as frequency (%) and continuous variables were presented as mean \pm standard deviation (SD). The normality of continuous variables was assessed using the Kolmogorov-Smirnov test. For repeated and 2 measurements, the paired samples *t* test was used. ANOVA was used for >2 measurements. The level of statistical significance was set at $P < 0.05$ for all analyses.

RESULTS

A total of 25 patients (17 [68%] women and 8 [32%] men; mean age: 62.9 ± 10.8 [range: 41–79] years) were included in the study. The Dynesys system was used in

19 (76%) patients, and the Orthrus system was used in 6 (24%) patients (Tables 1 and 2).

The clinical outcomes at the 6-month, 12-month, and 24-month clinical follow-up are presented in Table 3. There was a significant difference in VAS and ODI scores between measurements ($P < 0.001$). This difference was due to the difference between all times, except for the difference between 12-month and 24-month postoperative values (Table 4).

The preoperative and postoperative radiological findings are presented in Table 3. Scoliotic and kyphotic deformity recovery rates are provided in Table 5.

Notably, the scoliotic Cobb angle exhibited a substantial and statistically significant reduction at the third month postoperatively (11.29 ± 7.06 , $P = 0.001$), indicative of effective corrective measures. However, the subsequent follow-up periods (at 6, 12, and 24 months) did not demonstrate further statistically significant changes, suggesting a plateau in improvement. A similar trend was observed in the thoracic kyphosis angle, with a significant decrease at the third month (23.48 ± 9.61 , $P = 0.013$) but with subsequent stabilization. The SVA also displayed a significant reduction at the third month (52.78 ± 49.37 , $P = 0.047$) but remained relatively constant thereafter. Importantly, it is noteworthy that from the third month onward, there was a loss of correlation in the scoliotic Cobb angle, thoracic kyphosis angle, and SVA values, with no statistical significance observed (Table 5).

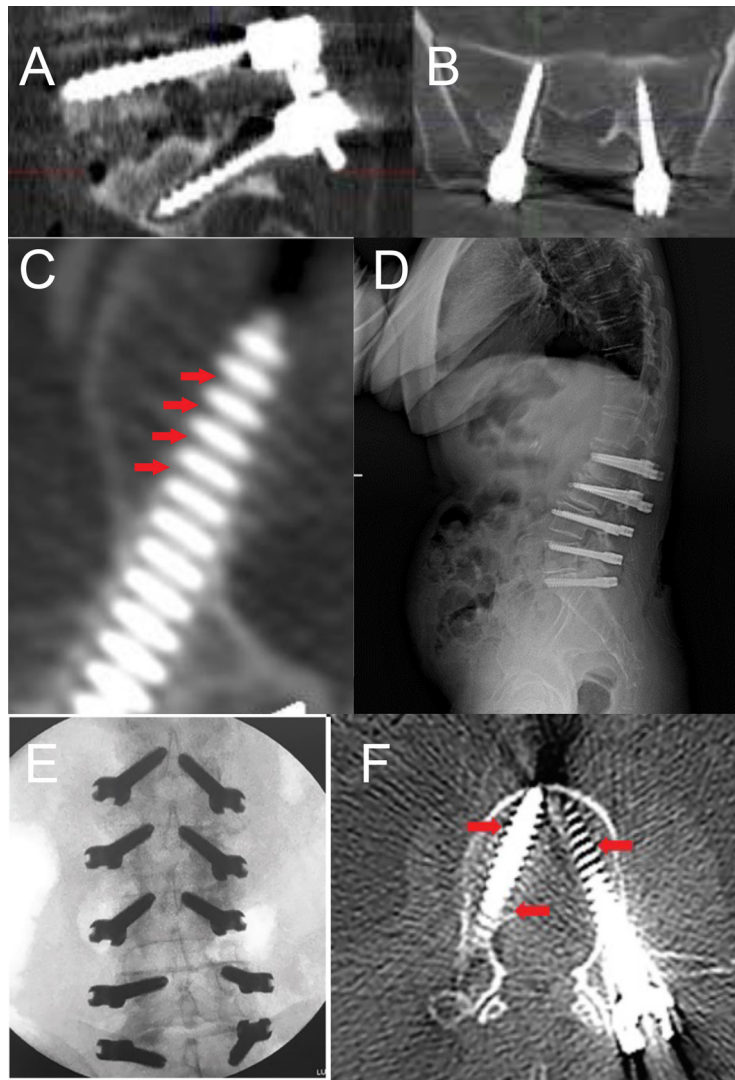


Figure 5. Patients are evaluated with computed tomography (CT) after an average of 16–20 weeks for the determination of osteointegration of screws. If osteointegration is completed, then rods are placed and screws are connected to each other. (A) Sagittal and (B) coronal CT image of patients showing screw loosening after traditional surgery with rigid stabilization. (C) Axial CT image of the patient showing successful osteointegration after the first stage of 2-stage surgery. (D) Lateral x-ray image of the patient after the second stage stabilization surgery by Dynesys system. (E) Intraoperative coronal fluoroscopy image and (F) CT image of the patient showing osteointegration after the first stage of 2-stage surgery. Red arrows indicate areas of connection between bone and screws.

In one female patient, adequate improvement in kyphotic deformity could not be achieved, whereas in 1 patient, communication could not be established due to patient dissatisfaction. The outcomes for this patient were considered unsuccessful. However, very satisfactory results were obtained in the remaining 23 patients.

Except for subcutaneous hematoma and superficial tissue infection, no serious complications were encountered in this cohort. Screw loosening without clinical significance was detected in 2 patients. In addition, none of the cases required revision surgery secondary to screw malposition, adjacent segment disease, or screw loosening.

Some cases in this series are illustrated in Figures 6–10.

DISCUSSION

With advancing age, the development of deformities such as kyphosis and scoliosis is common. In cases of kyphotic deformity, the patient typically states that he/she begins forward bending after walking for a long distance. Low back pain is the predominant complaint in scoliotic deformity. Neurological findings are mostly in the form of nerve root irritation and may allow the patient to continue with his daily life.

During the examination, lying and standing radiographs can clearly demonstrate whether the deformity is mobile or not. The key mistake during this evaluation is to follow the patient because he can manage his coronal or sagittal balance.

Table 1. Details of the system used, patient age and gender, number of levels operated, Schizas and Lee grades of spinal stenosis, Pfirrmann grade of intervertebral disc degeneration, number of stages of surgery, and preoperative T scores.

Patient Number	System	Age, y	Gender	Level	Schizas Grade	Lee Grade	Pfirrmann Grade	Stage	Preop T Score
1	Dynesys	48	F	T12-S1	B	1	4	2	-2.5
2	Dynesys	65	F	T10-S1	C	2	4	2	-2.5
3	Dynesys	51	M	L2-Iliac	B	1	3	1	-1.5
4	Dynesys	63	F	T9-L5	D	3	5	1	-1.5
5	Dynesys	47	M	T12-Iliac	B	1	4	1	-1.5
6	Dynesys	54	F	L3-Iliac	A3	0	4	1	-1.5
7	Dynesys	41	F	L2-Iliac	C	2	3	1	-1
8	Dynesys	77	F	T12-L5	D	3	5	1	-1.5
9	Dynesys	65	F	T10-Iliac	D	3	5	1	-2.5
10	Dynesys	79	F	L2-Iliac	A2	0	4	1	-2.5
11	Dynesys	66	F	L2-S1	B	1	4	2	-2.5
12	Dynesys	68	F	T10-S1	C	2	4	1	-2.5
13	Dynesys	44	M	L2-Iliac	A3	0	2	1	-1
14	Dynesys	68	F	T10-Iliac	D	3	4	1	-1.5
15	Dynesys	69	F	T6-S1	D	3	4	2	-2.5
16	Dynesys	61	M	L1-S1	D	3	5	1	-1.5
17	Dynesys	72	M	T12-Iliac	A2	0	4	1	-2.5
18	Dynesys	78	F	L1-S1	B	1	4	1	-1
19	Dynesys	67	M	T10-Iliac	B	1	5	2	-2.5
20	Orthrus	68	F	T12-S1	C	2	5	1	-1.5
21	Orthrus	61	F	T11-S1	A3	0	3	1	-1.5
22	Orthrus	77	F	L2-Iliac	B	1	4	1	-1.5
23	Orthrus	65	M	L2-S1	D	3	4	1	-1.5
24	Orthrus	52	M	T11-L5	C	2	4	1	-1
25	Orthrus	67	M	L1-S1	D	3	4	1	-1.5

Abbreviations: F, female; M, male; Preop, preoperative.

In the classical approach, the indications for surgical treatment of adult deformity are lack of response to nonoperative treatment, presence of disability, pain, and neurological symptoms, and progression of deformity.^{25–28} Although fusion surgery is the most preferred surgical method, it is associated with a high risk of morbidity and mortality.

Spinal deformity can be defined as spinal curvature or alignment that exceeds the normal range.²⁶ Adult spinal deformity (ASD) can include any or a combination of spinal deformities affecting the axial, coronal, and sagittal planes. Scoliosis is defined as a lateral spinal curvature of >10° resulting in concomitant rotational deformity in the axial plane and loss of kyphosis or lordosis in the sagittal plane. The prevalence of scoliosis is increasing owing to progressive population aging.

ASD is caused by age-related degenerative changes. Degenerative bone and soft tissue changes cause radiculopathy or instability through spinal stenosis, thus inducing

spondylolisthesis or rotatory subluxation or oligolisthesis.²⁹ The first degenerative process is the loss of function of the intervertebral discs, characterized by reduced disc height, loss of water and proteoglycan content in the disc, and increased enzyme degradation. Subsequently, pathological changes in the vertebral and facet joints increase the load on the anterior part of the vertebral joints and cause arthritic changes in the posterior elements leading to bone remodeling and instability.^{29–31}

ASD can be summarized as loss of sagittal balance manifested by loss of lordosis in the lumbar spine, forward bending of the trunk, and retroversion of the pelvis. Decreased lumbar lordosis (LL) can be caused by a variety of factors, including degenerative changes, scoliosis, and iatrogenic factors. Loss of LL tilts the body forward, causing an increase in pelvic incidence (PI)/LL mismatch and SVA.^{30–32}

Patients with sagittal imbalance use some of the following compensatory mechanisms to maintain an upright posture: backward tilt of the head and neck to maintain a straight gaze, straightening of the thoracic spine to reduce kyphosis, simultaneous pelvic retroversion, and knee flexion.^{30–33}

In patients with ASD, surgery focuses more on correcting sagittal imbalance than scoliosis because sagittal imbalance causes greater pain and disability. Coronal imbalance can also lead to back pain and dysfunction; however, it is more commonly associated

Table 2. Demographic characteristics of patients and type of dynamic system.

Characteristic	n (%)
Age, y, mean ± SD	62.92 ± 10.80
Gender	
Female	17 (68.0)
Male	8 (32.0)
System	
Dynesys	19 (76.0)
Orthrus	6 (24.0)

Table 3. Patient VAS and ODI scores at preoperative and postoperative time points.

Patient number	VAS				ODI			
	Preop	6-mo Postop	12-mo Postop	24-mo Postop	Preop	6-mo Postop	12-mo Postop	24-mo Postop
1	7	3	1	1	72	26	6	8
2	7	3	1	0	66	26	16	10
3	6	2	0	0	56	28	12	8
4	7	3	2	0	66	36	16	16
5	8	1	1	1	58	16	10	10
6	7	2	0	2	72	18	12	8
7	7	3	0	1	74	26	8	6
8	5	4	2	0	72	24	26	8
9	6	4	4	4	68	56	58	52
10	8	1	1	0	68	18	8	8
11	6	3	2	1	66	16	8	12
12	7	2	0	1	72	26	8	6
13	8	2	1	2	76	28	2	2
14	7	2	2	1	62	32	6	8
15	8	2	1	1	76	32	8	2
16	6	4	1	2	76	36	4	4
17	7	3	1	1	58	26	2	20
18	7	2	0	2	76	26	6	8
19	8	1	0	1	72	28	8	2
20	7	2	1	1	58	26	8	6
21	6	1	1	0	62	26	4	4
22	7	3	1	1	58	36	4	2
23	7	1	1	0	60	16	12	18
24	6	3	2	1	72	30	2	2
25	7	2	0	0	72	16	12	8
Mean	6.88	2.36	1.04	0.96	67.52	26.96	10.64	9.52

Abbreviations: ODI, Oswestry Disability Index; Postop, postoperative; Preop, preoperative; VAS, visual analog scale.

with aesthetics.³⁴ Nevertheless, the ideal approach for ASD is to consider both sagittal and coronal parameters during the surgical treatment. In our opinion, the most appropriate time for the patient is when the coronal deformity is corrected while lying down and the sagittal deformity is corrected by using their lumbar paravertebral muscles. Dynamic stabilization of the patient in the initial stage will avert the need for risky and painful surgeries in the future. Two-stage surgery is very important for these patients in terms of clinical outcomes.³⁵

Delayed intervention can cause exhaustion of the compensatory mechanisms leading to the development of fixed deformity. The aim is to stop the process before the development of fixed sagittal imbalance. Initiation of both kyphotic and scoliotic deformities indicates that the process has begun. In these patients, when the scoliotic or kyphotic deformity is in the mobile stage, it is critical to intervene before it reaches abnormal dimensions.

An ideal dynamic system normalizes the load distribution passing through the vertebral bodies in the functional

unit where the neutral zone is disturbed.^{36–38} Biomechanical studies have shown that in a model with anterior interbody support, placement of a dynamic rod on the rigid screw reduces the stress on the screw against loading, normalizing the load transfer in the spine.^{39–43} In one study, the use of dynamic screws and rigid rods was found to stabilize an impaired neutral zone close to the rigid system.⁴⁴ In another biomechanical study, mobile screws were found to have developed less stress on fewer screws while stabilizing the neutral zone compared to rigid screws.⁴⁵ In biomechanical studies using dynamic screw and dynamic rod, the impaired neutral zone was stabilized close to normal and the stress on the screw was lesser compared to rigid screw.^{46,47} When any of the screw or rod systems are used as a dynamic system, it reduces the stress formation on the screw. However, despite all the advantages, there is a possibility of screw loosening, even in systems where both the dynamic screw and the rod are used at the same time.⁴⁸

The biggest criticism of fusion surgery is instrument failure and pseudoarthrosis.^{23,24} Age-related

Table 4. Variation of patients' VAS and ODI scores over time.

Outcome Measure	Preoperative, mean \pm SD	Postoperative, mean \pm SD			<i>P</i> ^a
		6-mo	12-mo	24-mo	
VAS	6.88 \pm 0.78	2.36 \pm 0.95	1.04 \pm 0.93	0.96 \pm 0.93	<0.001
ODI	67.52 \pm 6.74	26.96 \pm 8.68	10.64 \pm 11.21	9.52 \pm 10.07	<0.001

Abbreviations: ODI, Oswestry Disability Index; VAS, visual analog scale.

^aRepeated measure analysis of variance was applied.

Table 5. Postoperative change in the radiological values of the patients.

Outcome Measure	Preoperative, mean \pm SD	Postoperative, mean \pm SD			
		3-mo	6-mo	12-mo	24-mo
Scoliotic Cobb angle	19.23 \pm 7.68	11.29 \pm 7.06 ($P = 0.001$)	12.16 \pm 8.11	12.57 \pm 7.67	12.51 \pm 9.21
Thoracic kyphosis angle	27.36 \pm 11.40	23.48 \pm 9.61 ($P = 0.013$)	25.11 \pm 9.62	25.26 \pm 10.88	25.44 \pm 10.45
SVA (mm)	75.84 \pm 63.56	52.78 \pm 49.37 ($P = 0.047$)	56.17 \pm 46.95	58.46 \pm 51.39	58.74 \pm 53.87
PI	52.76 \pm 15.64	50.80 \pm 12.74 ($P = 0.442$)			
PT	22.68 \pm 12.76	26.08 \pm 8.51 ($P = 0.159$)			
SS	30.04 \pm 7.75	24.80 \pm 8.98 ($P = 0.008$)			

Abbreviations: PI, pelvic incidence; PT, pelvic tilt; SS, sacral slope; SVA, sagittal vertical axis.

*Paired samples *t* test was applied.

deterioration of bone quality is a key pathological factor, especially in ASD. In addition, poor bone quality is also a very important factor contributing to pseudoarthrosis in fusion surgery. Development of such a complication necessitates revision surgery that is more severe than the initial surgery.^{49–52}

One- or two-stage dynamic stabilization and fusion surgery have been shown to overcome the frequently encountered problems of instrument failure and pseudoarthrosis.^{23,24} In our study, instrument

failure was not observed after long segment 1- or 2-stage dynamic stabilization in adult patients with SCI. Coronal and sagittal imbalance was successfully corrected with 1- or 2-stage dynamic stabilization, but no significant loss of correction was observed at 6-month radiologic follow-up.

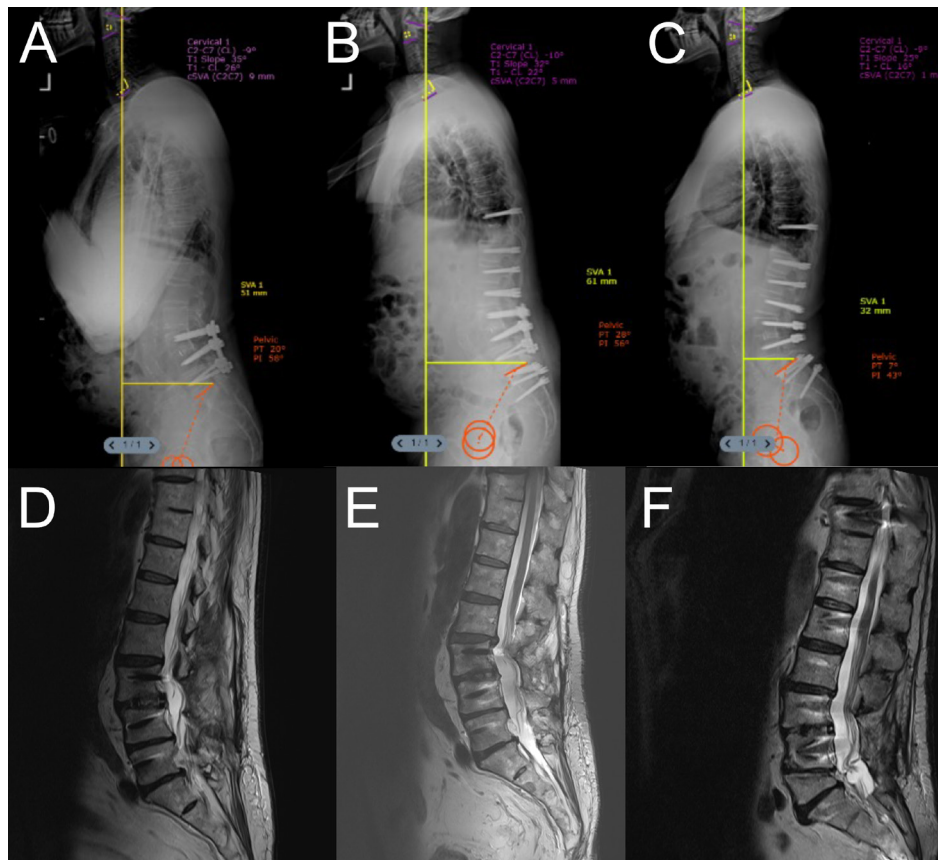


Figure 6. Patient who previously underwent L3-L4 interbody fusion and L3-L4-L5 stabilization due to spondylolisthesis presented with worsening kyphosis and difficulty looking forward. (A) Preoperative standing lateral x-ray image, (B) first stage postoperative standing lateral x-ray image, (C) second stage postoperative standing lateral x-ray image, (D) sagittal magnetic resonance image (MRI) after initial L3-L4-L5 stabilization, (E) preoperative sagittal MRI showing proximal junctional kyphosis and Pfirrmann grade 4 intervertebral disc degeneration, and (F) second stage postoperative sagittal MRI. The Dynesis system was used for dynamic stabilization. Two-stage surgery was performed because the patient was osteoporotic (T score = -2.5 preop, -1.5 before the second stage). The patient showed significant improvement in both spinopelvic parameters and clinical findings after surgery.

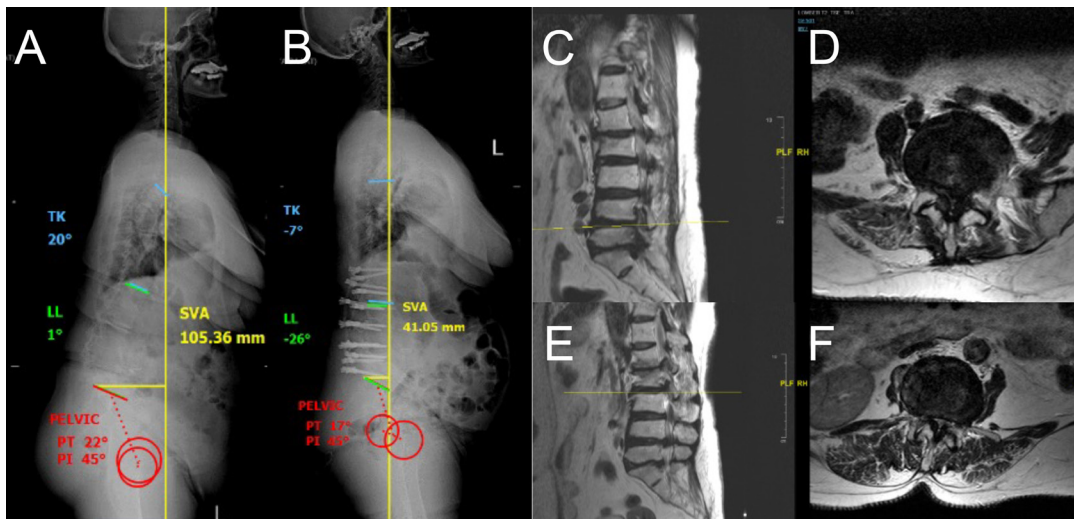


Figure 7. Radiological images of a patient with neurological claudication and walking difficulties. Decompression and dynamic stabilization with the Orthrus system were performed. (A) Preoperative standing lateral x-ray image and (B) Postoperative standing lateral x-ray image showing sagittal imbalance and related pelvic parameters. (C and E) Preoperative sagittal magnetic resonance images and (D and F) preoperative axial magnetic resonance imaging (MRI), showing Schizas grade D and Lee grade 3 spinal stenosis. The patient showed significant increase in walking distance without difficulty.

Limitations

The results section demonstrates 2-year follow-up and concludes that there was no case that required revision surgery secondary to screw malposition, adjacent segment disease or screw loosening. While this is admirable, the relatively short follow-up means that no meaningful conclusion can be drawn. Conducting prospective studies with a larger cohort with longer follow-up durations would enhance the

generalizability of the results and provide a more comprehensive understanding of effectiveness of dynamic stabilization over time. Moreover, patients in this cohort were not categorized by the severity of the deformity; hence, mild and severe cases are analyzed at the same time. Further studies are needed to determine which patient groups of adult spine deformity are better suited for dynamic stabilization.

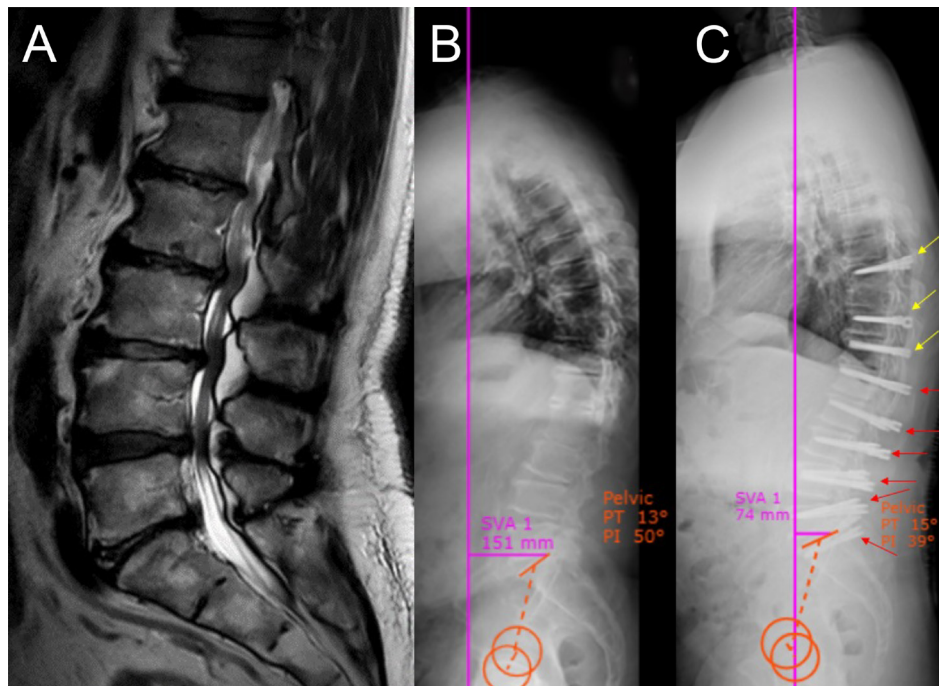


Figure 8. Radiological images of a patient with lower back pain and walking difficulties. Decompression and dynamic stabilization with Dynesys system were performed. (A) Preoperative sagittal magnetic resonance image showing Pfirrmann grade 4 degenerative intervertebral disc changes. (B) Preoperative lateral x-ray image showing sagittal imbalance and pelvic parameters. (C) Postoperative lateral x-ray image showing improved sagittal balance.

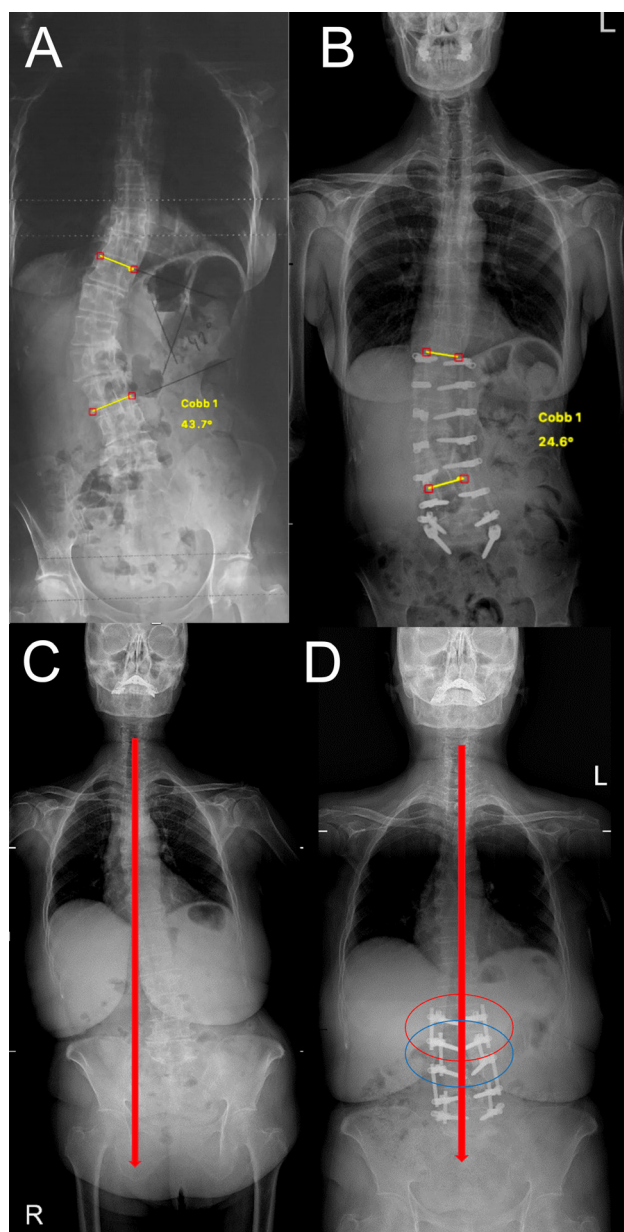


Figure 9. Radiological images of 2 different patients with severe lower back pain and walking difficulties showing decompensated coronal imbalance. Both of the patients were decompressed and dynamically stabilized with Orthrus system. (A and C) Preoperative and (B and D) postoperative anteroposterior x-ray images showing significant improvement in coronal balance of the patients.

CONCLUSION

Successful results were obtained in 1- or 2-stage surgeries with the dynamic system. This method can be preferred because it is easier to perform compared to fusion and rigid instrumentation surgery. From this perspective, it can also be used in mobile adolescent idiopathic scoliosis surgery. However, longer-term clinical studies are required to obtain more definitive evidence.

REFERENCES

1. Kebaish KM, Neubauer PR, Voros GD, Khoshnevisan MA, Skolasky RL. Scoliosis in adults aged forty years and older: prevalence and relationship to age, race, and gender; spine. *Spine*. 2011;36(9):731–736. doi:10.1097/BRS.0b013e3181e9f120
2. Glassman SD, Hamill CL, Bridwell KH, Schwab FJ, Dimar JR, Lowe TG. The impact of perioperative complications on clinical outcome in adult deformity surgery. *Spine*. 2007;32(24):2764–2770. doi:10.1097/BRS.0b013e31815a7644
3. Núñez-Pereira S, Vila-Casademunt A, Domingo-Sabat M, et al. Impact of early unanticipated revision surgery on health-related quality of life after adult spinal deformity surgery. *Spine J*. 2018;18(6):926–934. doi:10.1016/j.spinee.2017.09.017
4. Veeravagu A, Li A, Swinney C, et al. Predicting complication risk in spine surgery: a prospective analysis of a novel risk assessment tool. *J Neurosurg Spine*. 2017;27(1):81–91. doi:10.3171/2016.12.SPINE16969
5. Yoshida G, Hasegawa T, Yamato Y, et al. Predicting perioperative complications in adult spinal deformity surgery using a simple sliding scale. *Spine*. 2018;43(8):562–570. doi:10.1097/BRS.0000000000002411
6. Elsamadicy AA, Adogwa O, Ongele M, et al. Preoperative hemoglobin level is associated with increased health care use after elective spinal fusion (≥ 3 levels) in elderly male patients with spine deformity. *World Neurosurg*. 2018;112:e348–e354. doi:10.1016/j.wneu.2018.01.046
7. Dinizo M, Dolgalev I, Passias PG, Errico TJ, Raman T. Complications after adult spinal deformity surgeries: all are not created equal. *Int J Spine Surg*. 2021;15(1):137–143. doi:10.14444/8018
8. Crawford CH, Lenke LG. Growth modulation by means of anterior tethering resulting in progressive correction of juvenile idiopathic scoliosis: a case report. *J Bone Joint Surg Am*. 2010;92(1):202–209. doi:10.2106/JBJS.H.01728
9. Raitio A, Syvänen J, Helenius I. Vertebral body tethering: indications, surgical technique, and a systematic review of published results. *J Clin Med*. 2022;11(9):2576. doi:10.3390/jcm11092576
10. Betz RR, Ranade A, Samdani AF, et al. Vertebral body stapling: a fusionless treatment option for a growing child with moderate idiopathic scoliosis. *Spine*. 2010;35(2):169–176. doi:10.1097/BRS.0b013e3181c6dfff5
11. Newton PO. Spinal growth tethering: indications and limits. *Ann Transl Med*. 2020;8(2):27. doi:10.21037/atm.2019.12.159
12. Samdani AF, Ames RJ, Kimball JS, et al. Anterior vertebral body tethering for idiopathic scoliosis: two-year results. *Spine*. 2014;39(20):1688–1693. doi:10.1097/BRS.0000000000000472
13. Floman Y, El-Hawary R, Lonner BS, Betz RR, Arnin U. Vertebral growth modulation by posterior dynamic deformity correction device in skeletally immature patients with moderate adolescent idiopathic scoliosis. *Spine Deform*. 2021;9(1):149–153. doi:10.1007/s43390-020-00189-z
14. Ozer AF, Oktenoglu T, Egemen E, et al. Lumbar single-level dynamic stabilization with semi-rigid and full dynamic systems: a retrospective clinical and radiological analysis of 71 patients. *Clin Orthop Surg*. 2017;9(3):310–316. doi:10.4055/cios.2017.9.3.310
15. Meyer B, Thomé C, Vajkoczy P, et al. Lumbar dynamic pedicle-based stabilization versus fusion in degenerative disease: a multicenter, double-blind, prospective, randomized controlled trial. *J Neurosurg Spine*. 2022;37(4):1–10. doi:10.3171/2022.2.SPINE21525

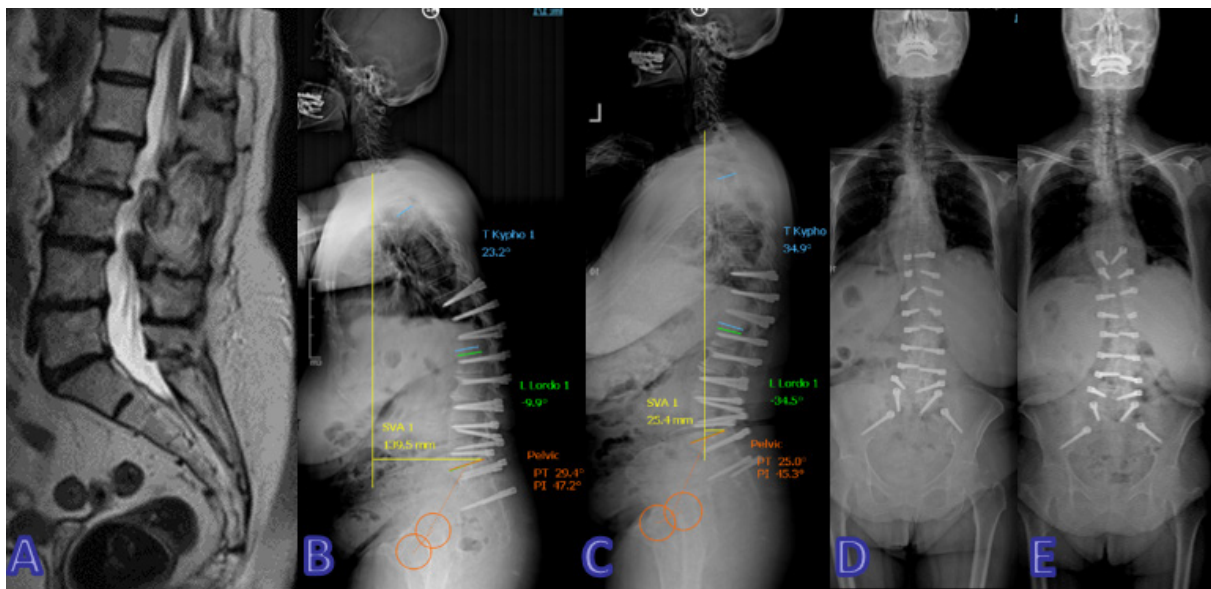


Figure 10. Two-stage surgery: A 69-year-old woman, who underwent an operation for L4-5 stenosis 10 years ago, developed low back pain during the process and started to lean forward gradually. (A) Preoperative magnetic resonance image (MRI); (B) lateral x-ray image after the first stage, before placement of the rods; (C) lateral x-ray image after placement of the rods; (D) antero-posterior x-ray image after the first stage, before placement of the rods; (E) antero-posterior x-ray image after placement of the rods. The patient showed significant improvement in both spinopelvic parameters and clinical findings after surgery.

16. Sengupta DK. Dynamic stabilization devices in the treatment of low back pain. *Neurol India*. 2005;53(4):466–474. doi:10.4103/0028-3886.22614
17. Zhang Y, Zhang Z-C, Li F, et al. Long-term outcome of dynesys dynamic stabilization for lumbar spinal stenosis. *Chin Med J*. 2018;131(21):2537–2543. doi:10.4103/0366-6999.244107
18. Esaltato D. Is pedicle screw dynamic stabilisation a possible management of lumbar diseases with a low-grade instability. *AJBSR*. 2021;12(1):622–626. doi:10.34297/AJBSR.2021.12.001707
19. Di Silvestre M, Lolli F, Bakaloudis G, Parisini P. Dynamic stabilization for degenerative lumbar scoliosis in elderly patients. *Spine*. 2010;35(2):227–234. doi:10.1097/BRS.0b013e3181bd3be6
20. Di Silvestre M, Lolli F, Bakaloudis G. Degenerative lumbar scoliosis in elderly patients: dynamic stabilization without fusion versus posterior instrumented fusion. *Spine J*. 2014;14(1):1–10. doi:10.1016/j.spinee.2012.10.023
21. Di Silvestre M, Lolli F, Greggi T, Vommaro F, Baioni A. Adult's degenerative scoliosis: midterm results of dynamic stabilization without fusion in elderly patients—is it effective?. *Adv Orthop*. 2013;2013:365059. doi:10.1155/2013/365059
22. Özer AF, Başak AT, Özbek MA, et al. Lumbar dynamic stabilization with 2-stage surgery: early results. *Int J Spine Surg*. 2022;16(4):8306:638–645. doi:10.14444/8306
23. Jaeger A, Giber D, Bastard C, et al. Risk factors of instrumentation failure and pseudarthrosis after stand-alone L5-S1 anterior lumbar interbody fusion: a retrospective cohort study. *J Neurosurg Spine*. 2019;31(3):338–346. doi:10.3171/2019.3.SPINE181476
24. Khalifé M, Charles Y-P, Riouallon G, et al. French society of spinal surgery. lumbar scoliosis and stenosis: what outcomes for which treatment? Analysis of three surgical techniques in 154 patients with minimum two-year follow-up. *Orthopaedics & Traumatology: Surgery & Research*. 2023;103632. doi:10.1016/j.otsr.2023.103632
25. Smith JS, Shaffrey CI, Bess S, et al. Recent and emerging advances in spinal deformity. *Neurosurgery*. 2017;80(3S):S70–S85. doi:10.1093/neuros/nyw048
26. Youssef JA, Orndorff DO, Patty CA, et al. Current status of adult spinal deformity. *Global Spine J*. 2013;3(1):51–62. doi:10.1055/s-0032-1326950
27. Sengupta D. Adult spinal deformity. In: Rao R, Smuck M, eds. *Orthopaedic Knowledge Update: Spine*. 4th ed. Rosemont, IL: American Academy of Orthopaedic Surgeons; 2012:349–367.
28. Silva FE, Lenke LG. Adult degenerative scoliosis: evaluation and management. *Neurosurg Focus*. 2010;28(3):E1. doi:10.3171/2010.1.FOCUS09271
29. Diebo BG, Shah NV, Boachie-Adjei O, et al. Adult spinal deformity. *Lancet*. 2019;394(10193):160–172. doi:10.1016/S0140-6736(19)31125-0
30. Kanter AS, Bradford DS, Okonkwo DO, Rengachary SS, Mummaneni PV. Thoracolumbar spinal deformity: part I. A historical passage to 1990: historical vignette. *J Neurosurg Spine*. 2009;11(6):631–639. doi:10.3171/2009.3.SPINE08336
31. Lam FC, Kanter AS, Okonkwo DO, Ogilvie JW, Mummaneni PV. Thoracolumbar spinal deformity: part II. developments from 1990 to today: historical vignette. *J Neurosurg Spine*. 2009;11(6):640–650. doi:10.3171/2009.3.SPINE08337
32. Sparrey CJ, Bailey JF, Safaei M, et al. Etiology of lumbar lordosis and its pathophysiology: a review of the evolution of lumbar lordosis, and the mechanics and biology of lumbar degeneration. *Neurosurg Focus*. 2014;36(5):E1. doi:10.3171/2014.1.FOCUS13551
33. Iyer S, Sheha E, Fu MC, et al. Sagittal spinal alignment in adult spinal deformity: an overview of current concepts and a critical analysis review. *JBJS Rev*. 2018;6(5):e2. doi:10.2106/JBJS.RVW.17.00117
34. Bao H, Zhu F, Liu Z, et al. Coronal curvature and spinal imbalance in degenerative lumbar scoliosis: disc degeneration is associated. *Spine*. 2014;39(24):E1441–E1447. doi:10.1097/BRS.0000000000000603
35. Özer AF, Başak AT, Özbek MA, et al. Lumbar dynamic stabilization with 2-stage surgery: early results. *Int J Spine Surg*. 2022;16(4):8306:638–645. doi:10.14444/8306

36. Kummer B. Biomechanische Aspekte der Instabilität der Wirbelsäule. In: *FuchsGA (Hrsg) Die Instabile Wirbelsäule*. Stuttgart New York: Georg Thieme; 1991:8–14.
37. Bergmark A. Stability of the lumbar spine. a study in mechanical engineering. *Acta Orthop Scand Suppl*. 1989;230:1–54. doi:10.3109/17453678909154177
38. Goel VK, Gilbertson LG. Basic science of spinal instrumentation. *Clin Orthop Relat Res*. 1997;335(335):10–31.
39. Biedermann L. Biomechanics of pedicle fixation as related to implant design. In: *Presented at the American-European Meeting on Pedicle Fixation of the Spine and Other Advanced Techniques*. Munich, Germany; 1994.
40. Niosi CA, Zhu QA, Wilson DC, Keynan O, Wilson DR, Oxland TR. Biomechanical characterization of the three-dimensional kinematic behavior of the dynesys dynamic stabilization system: an in vitro study. *Eur Spine J*. 2006;15(6):913–922. doi:10.1007/s00586-005-0948-9
41. Barrey C, Freitas E, Perrin G. Pedicle screw-based dynamic stabilization devices in the lumbar spine: biomechanical concepts, technologies, classification, and clinical results. *Advanced Concepts in Lumbar Degenerative Disk Disease*. 2016.
42. Freudiger S, Dubois G, Lorrain M. Dynamic neutralization of the lumbar spine confirmed on a new lumbar spine simulator in vitro. *Arch Orthop Trauma Surg*. 1999;119(3–4):127–132. doi:10.1007/s004020050375
43. Sengupta DK, Bucklen B, McAfee PC, Nichols J, Angara R, Khalil S. The comprehensive biomechanics and load-sharing of semirigid PEEK and semirigid posterior dynamic stabilization systems. *Adv Orthop*. 2013;2013:745610. doi:10.1155/2013/745610
44. Bozkuş H, Senoğlu M, Baek S, et al. Dynamic lumbar pedicle screw-rod stabilization: in vitro biomechanical comparison with standard rigid pedicle screw-rod stabilization. *J Neurosurg Spine*. 2010;12(2):183–189. doi:10.3171/2009.9.SPINE0951
45. Liu C, Kamara A, Yan Y. Investigation into the biomechanics of lumbar spine micro-dynamic pedicle screw. *BMC Musculoskelet Disord*. 2018;19(1):231. doi:10.1186/s12891-018-2132-5
46. Erbulut DU, Kiapour A, Oktenoglu T, Ozer AF, Goel VK. A computational biomechanical investigation of posterior dynamic instrumentation: combination of dynamic rod and hinged (dynamic) screw. *J Biomech Eng*. 2014;136(5):051007. doi:10.1115/1.4027060
47. Oktenoglu T, Erbulut DU, Kiapour A, et al. Pedicle screw-based posterior dynamic stabilization of the lumbar spine: in vitro cadaver investigation and a finite element study. *Comput Methods Biomech Biomed Engin*. 2015;18(11):1252–1261. doi:10.1080/10255842.2014.890187
48. Özer AF, Aydın AL, Hekimoğlu M, et al. Should iliac wing screws be included in long segment dynamic stabilization? *Cureus*. 2021;13(2):e13543. doi:10.7759/cureus.13543
49. Pham MH, Mehta VA, Patel NN, et al. Complications associated with the dynesys dynamic stabilization system: a comprehensive review of the literature. *Neurosurg Focus*. 2016;40(1):E2. doi:10.3171/2015.10.FOCUS15432
50. Kim YJ, Bridwell KH, Lenke LG, Cho K-J, Edwards CC, Rinella AS. Pseudarthrosis in adult spinal deformity following multisegmental instrumentation and arthrodesis. *J Bone Joint Surg Am*. 2006;88(4):721–728. doi:10.2106/JBJS.E.00550
51. Kim YJM, Bridwell KHM, Lenke LGM, Rhim SM, Cheh GM. Pseudarthrosis in long adult spinal deformity instrumentation and fusion to the sacrum: prevalence and risk factor analysis of 144 cases. *Spine*. 2006;31(20):2329–2336. doi:10.1097/01.brs.0000238968.82799.d9
52. Bhagat S, Vozar V, Lutchman L, Crawford RJ, Rai AS. Morbidity and mortality in adult spinal deformity surgery: Norwich spinal unit experience. *Eur Spine J*. 2013;22 Suppl 1(Suppl 1):S42–S46. doi:10.1007/s00586-012-2627-y

Funding: This research did not receive any specific grant from funding agencies in the public, commercial, or not-for-profit sectors.

Declaration of Conflicting Interests: None declared.

Corresponding Author: Ali Fahir Ozer, Department of Neurosurgery, Topkapı, Koç Üniversitesi Hastanesi, Cd. No:4, 34010 Zeytinburnu/Istanbul, Turkey; alifahirozer@gmail.com

This manuscript is generously published free of charge by ISASS, the International Society for the Advancement of Spine Surgery. Copyright © 2024 ISASS. To see more or order reprints or permissions, see <http://ijssurgery.com>.