

# Evaluating Treatment Strategies for Spinal Lesions in Multiple Myeloma: A Review of the Literature

MANAN SUNIL PATEL, BA,<sup>1</sup> ALEXANDER GHASEM, MD,<sup>2</sup> DYLAN N. GREIF, BA,<sup>1</sup> SAMUEL R. HUNTLEY, BSC,<sup>1</sup> SHEILA A. CONWAY, MD,<sup>2</sup> MOTASEM AL MAAIEH, MD<sup>2</sup>

<sup>1</sup>University of Miami Miller School of Medicine, Miami, Florida, <sup>2</sup>University of Miami, Department of Orthopedic Surgery, Miami, Florida

## ABSTRACT

**Background:** Vertebral disease is a major cause of morbidity in 70% of patients diagnosed with multiple myeloma (MM). Associated osteolytic lesions and vertebral fractures are well documented in causing debilitating pain, functional restrictions, spinal deformity, and cord compression. Currently, treatment modalities for refractory MM spinal pain include systemic therapy, radiotherapy, cementoplasty (vertebroplasty/kyphoplasty), and radio frequency ablation. Our objectives were to report on the efficacy of existing treatments for MM patients with refractory spinal pain, to determine if a standardized treatment algorithm has been described, and to set the foundation upon which future prospective studies can be designed.

**Methods:** A systematic search of the PubMed database was performed for studies relevant to the treatment of vertebral disease in MM patients. A multitude of search terms in various combinations were used, including but not limited to: “vertebroplasty,” “kyphoplasty,” “radiation,” “multiple myeloma,” “radiotherapy,” and “radiosurgery.”

**Results:** Our preliminary search resulted in 219 articles, which subsequently resulted in 19 papers following abstract, title, full-text, and bibliography review. These papers were then grouped by treatment modality: radiotherapy, cementoplasty, or combination therapy. Significant pain and functional score improvement across all treatment modalities was found in the majority of the literature. While complications of treatment occurred, few were noted to be clinically significant.

**Conclusions:** Treatment options—radiotherapy and/or cementoplasty—for vertebral lesions and pathologic fractures in MM patients demonstrate significant radiographic and clinical improvement. However, there is no consensus in the literature as to the optimal treatment modality as a result of a limited number of studies reporting head-to-head comparisons. One study did find significantly improved pain and functional scores with preserved vertebral height in favor of kyphoplasty over radiotherapy. When not contraindicated, we advocate for some form of cementoplasty. Further prospective studies are required before implementation of a standardized treatment protocol.

**Level of Evidence:** 5.

Minimally Invasive Surgery

Keywords: multiple myeloma, kyphoplasty, vertebroplasty, cementoplasty, radiosurgery, radiation, combination therapy, radio frequency ablation, pathologic fracture, vertebral height, radiotherapy

## INTRODUCTION

Cytokine-induced osteoclastic bone resorption is reported in 70–100% of multiple myeloma (MM) patients,<sup>1</sup> resulting in back pain, vertebral fractures (55–70% of MM patients), and neurological deficits from spinal cord or nerve root impingement (up to 30% of MM patients).<sup>2–5</sup>

Although an incurable disease with an age-adjusted incidence of 6 per 100 000 annually and a 45% 5-year survival rate,<sup>2,6</sup> MM prognosis has improved with the introduction of high-dose chemotherapy alongside autologous hematopoietic support,<sup>7–10</sup> new biologically targeted agents, and the use of zoledronic acid.<sup>11</sup> As patients with MM

are living longer, painful complications from osteolytic bone lesions are becoming an increasingly impactful and prevalent clinical concern on their quality of life.

The general treatment for back pain in MM patients has been analgesics, bed rest, back braces, and pharmacologic agents that antagonize bone resorption (ie, bisphosphonates).<sup>12</sup> Radiotherapy or surgery is employed in cases with vertebral lesions, spinal cord compression, impending fractures, or treatment-resistant back pain.<sup>13</sup> This paper reviews the literature for 4 minimally invasive treatment modalities: stereotactic radiosurgery (SR), percutaneous vertebroplasty (PV), kyphoplasty (KP), and a

Table 1. Characteristics of studies included.

Study	Type of Study (Level of Evidence)	Procedure Performed	Number of Patients in Study (n)	Age (y)/Sex of Patients	Vertebra or Bones Treated
Jin et al <sup>21</sup>	Prospective study (2)	SR	24	61.5 (42–92) (median)/13 M (54.2%), 11 F (45.8%)	Cervical (n = 3), thoracic (n = 21), lumbar (n = 7)
Miller et al <sup>20</sup>	Retrospective study (3)	SR	38	59 (37–87) (median)/22 M (37%), 27 F (63%)	Cervical (n = 4), thoracic (n = 37), lumbar (n = 12), sacral (n = 3)
Lecouvet et al <sup>23</sup>	Prospective study (2)	SR	12	56 (mean)/8 M (67%), 4 F (33%)	Lumbar (n = 3), thoracic (n = 9)
Masala et al <sup>25</sup>	Retrospective study (3)	PV	64	71.4 ± 9.6 (mean)/34 M (52%), 30 F (48%)	Thoracic (n = 93), lumbar (n = 105)
Masala et al <sup>26</sup>	Prospective study (2)	Percutaneous osteoplasty	39	64 (48–88) (median)/17 M (44%), 22 F (56%)	Femur (n = 10), humerus (n = 7), pelvic bone (n = 15), pubis (n = 2), tibia (n = 5)
Nas et al <sup>27</sup>	Retrospective study (3)	PV	41	60.63 ± 11.24 (39–84) (mean)/24 M (58.5%), 17 F (41.5%)	Thoracic (n = 86), lumbar (n = 80)
Chen et al <sup>28</sup>	Retrospective study (3)	PV	24	67 (54–81) (mean)/4 M (17%), 20 F (83%)	Thoracic (n = 24), lumbar (n = 12)
Anselmetti et al <sup>1</sup>	Prospective study (2)	PV	106	70.1 (35–92) (mean)/56 M (53%), 50 F (47%)	C2–S1; 528 vertebra treated
McDonald et al <sup>29</sup>	Retrospective study (3)	PV	67	66.2 (mean)/37 M (55%), 30 F (45%)	Thoracic and lumbar spine; 114 vertebra treated
Simony et al <sup>30</sup>	Retrospective study (3)	PV	17	62.6 (46–76) (mean)/11 M (61%), 7 F (39%)	T6–S2; 64 vertebra treated
Ramos et al <sup>31</sup>	Prospective study (2)	PV	12	66 (54–80) (mean)/9 M (75%), 3 F (25%)	T9–L4; T11 (n = 3), T12 (n = 3), L1 (n = 2), L2 (n = 4)
Diamond et al <sup>32</sup>	Retrospective study (3)	PV	7	69 (58–78) (mean)/3 M (43%), 4 F (57%)	14 vertebra treated
Thang et al <sup>33</sup>	Retrospective study (3)	PV	28	65 (40–89) (median)/17 M (61%), 11 F (39%)	Dorsal vertebrae (n = 57), lumbar vertebrae (n = 59), sacrum (n = 1), others (pelvis) (n = 1)
Bartolozzi et al <sup>24</sup>	Prospective study (2)	PV and KP	14	54 (49–72) (median)/10 M (71%), 4 F (29%)	T6–S1; KP (n = 10), PV (n = 9)
Dudney et al <sup>18</sup>	Prospective study (2)	KP	18	63.5 (48–79) (mean)/NA	T6–L5; T11 (n = 9), T12 (n = 7), L1 (n = 8), L2 (n = 7)
Trumm et al <sup>36</sup>	Retrospective study (3)	PV; 6 patients underwent additional RFA prior (Group A)	39	65 ± 7 (mean)/22 M (56%), 17 F (44%)	Cervical (n = 3), thoracic (n = 32), lumbar (n = 27), sacral vertebrae (n = 5)
Orgera, 2013	Randomized control trial (1)	PV + RFA (Group A), PV alone (Group B)	36	67.4 (51–82) (mean)/10 M (28%), 26 F (72%)	Thoracic (n = 19), lumbar (n = 31)
Audat et al <sup>12</sup>	Prospective study (2)	Conventional therapy (Group 1), PV/KP + conventional therapy (Group 2)	27	Group 1: 58.15 (39–78) (mean)/9 M, 4 F Group 2: 58.86 (34–74) (mean)/6 M, 8 F	Thoracic, lumbar first sacral vertebra; 206 vertebra treated
Kasperk et al <sup>14</sup>	Retrospective study (3)	KP only, radiation only, systemic therapy only	73	KP: 58.9 (±10.3) (mean)/21 M, 14 F Radiation: 60.4 (±9.1) (mean)/11 M, 7 F Control: 62.6 (±8.3) (mean)/8 M, 12 F	Thoracic and lumbar spine

Abbreviations: F, female; KP, kyphoplasty; M, male; NA, not available; PV, percutaneous vertebroplasty; RFA, radio frequency ablation; SR, stereotactic radiosurgery.

combination of PV with radio frequency ablation (RFA)—that have been shown to reduce pain, improve mobility, and stabilize vertebral bodies<sup>14</sup> and are used currently for refractory back pain from MM.

Kyphoplasty and PV are cement augmentation techniques in which polymethylmethacrylate (PMMA) is injected into vertebrae using image guidance.<sup>13</sup> In KP, a balloonlike inflatable bone tamp (IBT) is passed through the bone channel and inflated to produce a cavity within the vertebral body and restore lost height prior to PMMA injection.<sup>15,16</sup> Kyphoplasty has been shown to lead to lower rates of cement leaks in contrast with PV due to creation of a cavity, which allows for the use of a high-viscosity cement.<sup>17</sup> The major hindrance in the use of KP lies in the higher costs and overall complexity of the procedure.<sup>13</sup>

Percutaneous vertebroplasty, in contrast, does not use an IBT prior to PMMA injection. The limitations to PV include the high incidence of cement leakages and the fact that it does not address the restoration of lost vertebral height or spinal deformities.<sup>18</sup> Cement leakages can lead to further complications including cement extravasation into the foraminal, dural, or epidural spaces, or into the paravertebral veins, leading to pulmonary or cerebral emboli, cardiac perforation, or even death.<sup>19</sup>

Due to the radiosensitive nature of MM, patients have been successfully treated with radiation therapy with few complications. The shortcomings of radiation therapy in MM treatment present in the lack of longevity in pain relief, as patients that are living longer suffer from failures at radiation sites and new vertebral fractures, requiring repeat radiation and/or an alternative treatment. Stereotactic radiosurgery may prove beneficial for these patients requiring repeat radiation.<sup>20</sup> Stereotactic radiosurgery is used to accurately and precisely aim highly focused radiation beams at MM lesions in vertebral bodies in an attempt to limit complications from repeat radiation therapy.<sup>21</sup>

Radiofrequency ablation uses high-frequency alternating current to cause coagulative necrosis of the tumor, reducing its size and leaving behind a cavity that can be followed by PV injection of PMMA cement to stabilize the vertebrae.<sup>22</sup> Complications are related to thermal damage to spinal cord structures.

This paper reviews the literature for these 4 treatment modalities—SR, PV, KP, and PV following RFA—assessing the short-term and long-term pain and functional score improvements, clinical outcomes, complications, and overall efficacy of these procedures in improving patient quality of life.

## MATERIALS AND METHODS

A search of the PubMed (MEDLINE) database was performed on February 1st, 2017, ranging back to January 1995, for papers relevant to the treatment of vertebral disease in myeloma patients. A multitude of search terms in various combinations were used, including but not limited to: “vertebroplasty,” “kyphoplasty,” “radiation,” “multiple myeloma,” “radiotherapy,” and “radio-surgery.” Relevant articles were reviewed using the Preferred Reporting Items for Systematic Reviews and Meta-Analysis (PRISMA) statement as a guideline. Two independent researchers compared search results to ensure completeness. Both reviewers individually screened all full title abstracts, removed duplicates, and confirmed the eligibility of each paper. A third reviewer was used to resolve any differences.

Eligibility of each paper was established via predetermined inclusion and exclusion criteria. Study design inclusion criteria were constituted by English-written randomized control trials as well as prospective and retrospective cohort studies that used a multidisciplinary approach of tumor treatment and vertebral stabilization. All case reports, narrative reviews, or case series with less than 9 patients, animal studies, studies without confirmation of MM diagnosis, and cases that included osteoporotic/traumatic vertebral compression fractures or spinal metastases, but did not stratify by MM, were excluded from the review.

Our analysis of procedural techniques for each combination included the following: procedural methods, number of patients, number of sessions or doses of treatment, use of imaging techniques, and follow-up time. Outcomes of treatment of interest included the following: vertebral height restoration, pain intensity time course, durability and reduction, use of analgesics, symptomatic complications, neurological outcomes, mobility, and functional scores.

The pain score improvements for each treatment were calculated using weighted means and standard deviations. Independent 2-sample *t* tests were

**Table 2.** Radiotherapy studies characteristics.

Study	Symptomatic Relief	Follow Up	Change in Pain Score (Score Type)	Symptomatic Complications	Neurological Deterioration	Vertebral Body Height Changes	Radiation Dose
Jin et al <sup>21</sup>	Complete relief in 54% of the patients, partial relief in 32% of the patients	Median 11.2 mo (1–55)	–6 (median, numerical rating pain 0–10)	Extremity weakness and sensory deficits (n = 7), of which 5 made complete neurological recoveries in 1–6 months, postoperation; surgical decompression performed (n = 1); other complications: acute esophagitis and pharyngitis leading to mild dysphagia	n = 0 patients	NA	Single fraction radiation dose of 10–18 Gy, median 16 Gy
Miller et al <sup>20</sup>	41% achieved pain relief	Median 26 mo (1–67)	NA	Vertebral fractures (n = 12 vertebra, 21%)	n = 2 patients (5%)	NA	Single fraction radiation dose, median 14 Gy (10–24), (1–4 fractions)
Lecouvet et al <sup>23</sup>	NA	Mean 35 mo (10–75)	NA	Vertebral fractures (n = 3 vertebra, 5%)	NA	NA	2 Gy daily for 5 d/wk to a total of 30 or 40 Gy
Kasperk et al <sup>14</sup>	NA	<2 y	–35 (mean, VAS 0–100)	NA	NA	Progressive height loss: control ( $P = .015$ ), radiation group ( $P = .013$ )	Dose of 25–50 Gy

Abbreviations: NA, not available, VAS, visual analog scale.

performed comparing the weighted mean pain improvements for each treatment modality individually against each other modality.  $P$  values less than .05 were considered statistically significant. All analyses were performed using SPSS version 24.0 for Macintosh.

## RESULTS

Our initial search resulted in a total of 219 articles, which was subsequently reduced to 10 papers following abstract, title, and full-text review. Further bibliography review yielded an additional 9 papers for a total of 19 articles meeting inclusion criteria (Figure 1). These papers were then grouped by treatment modality: radiotherapy, cementoplasty, or combination therapy (Table 1). The majority of the reviewed literature was found to be retrospective and showed significant pain and functional score improvement across all treatment modalities as well as improved preservation of vertebral height in the cementoplasty group when compared to control therapy. While complications of treatment did occur, particularly with cemento-

plasty, few complications were noted to be clinically significant.

Weighted mean pain improvement for SR, KP, PV, and RFA/PV were found to be 46.3, 41.8, 63.6, and 61.3%, respectively. There were no significant differences in pain improvement between any of the treatment modalities.

## DISCUSSION

### Radiotherapy

Of the 4 studies (Lecouvet et al,<sup>23</sup> Jin et al,<sup>21</sup> Kasperk et al,<sup>14</sup> and Miller et al<sup>20</sup>) that examined radiation therapy as a standalone treatment, 3 noted overall pain relief in their treated MM patients (Lecouvet et al did not report pain scores; Table 2).

Regardless of modest pain relief numbers, patients in these studies were not completely free from risk of postoperative neurological deterioration and complications. Miller et al reported 2 (5%) of their patients experienced neurological deterioration and found vertebral fractures following 12 treatments (21%), 10 of which were due to progression of

preexisting fractures—cumulative incidence of fractures at the 6- and 12-month time points were both 18%. Jin et al had more than 2 patients with other complications from SR (Table 2). In the Lecouvet study, fractures were found in 5% of the irradiated treatment group versus 20% in the nonirradiated group ( $P = .044$ ), and new focal lesions were found in 4% of the irradiated group versus 27% of the nonirradiated group ( $P < 10^{-5}$ ; Table 2).

Study designs varied in terms of doses of radiation, number of fractions given, and follow-up times (Table 2). The studies lacked a consistent measurement for pain (ie, 2 studies did not report pain scores, 1 used VAS scoring, and another used a numerical rating scale). Additionally, the patients in the Miller study had more baseline neurological deficits, making it problematic to assess the validity of the therapeutic benefits of radiotherapy.

Miller et al suggested that SR might be more beneficial to MM patients suffering from epidural disease and cord compression, rather than for those with chronic mechanical pain from osteolytic myeloma lesions. Lecouvet et al argued that the most significant finding from their study is the long-term viability of SR for MM patients. The authors attribute this to 2 reasons. First, radiation therapy could have a protective effect on the bone, leading to bone healing, remodeling, and reossification, thus strengthening the bone. Second, the decrease in lesions might be due to the fact that radiation has a tumoricidal effect on malignant cells and also inhibits the migration of neoplastic lesions to bone due to severe microenvironment changes secondary to radiation.

Although radiation therapy proves beneficial for the treatment of refractory back pain from MM, the complications seen in these studies invite the use of other therapies mentioned in this paper in lieu of SR. Furthermore, Jin et al concluded that, although SR is a noninvasive technique that achieves an excellent response in MM spinal cord compression, there are long-term limitations to the procedure. In addition to the acute and chronic complications of radiating healthy tissue (ie, weakened bone), the resolution of the tumor may cause the vertebral body to be unsupported, resulting in collapse, requiring a surgical procedure such as KP or PV. Stereotactic radiosurgery is a valuable adjunct that can be favorable in the setting of epidural disease but may not be the best choice as a standalone therapy, particularly in the setting of significantly

collapsed vertebrae. Thus, we recommend the use of vertebroplasty in place of SR for MM patients with refractory back pain.

### Kyphoplasty

Patients treated with KP were considered in 4 studies (Bartolozzi et al,<sup>24</sup> Dudeney et al,<sup>18</sup> Audat et al,<sup>12</sup> and Kasperk et al<sup>14</sup>) All noted significant improvements in pain and functional scores following KP procedures (Table 3). No major complications were reported by any of the 4 studies. Leaks were found in 3 of the studies, with extravasation not recorded in the Bartolozzi et al study (Table 3).

Differences between studies included varying follow-up times and amount of cement used (Table 3). The longer follow-up times in Kasperk et al<sup>14</sup> and Audat et al allow us to assess the strength of KP for up to 2 and 3 years, respectively, which showed that KP-treated vertebrae remained stable for an extended time with no further height loss. The KP procedure performed in all 4 studies did not have significant differences. Kasperk et al, who performed KP on both fractured and nonfractured vertebrae, suggested that, since perforations of cortical bone from osteolytic lesions, which are not detected by computed tomography (CT) scans, can cause leakages, pre-KP CT scans were performed. If cortical perforations were noted, highly viscous PMMA was applied. However, their study showed higher rates of leakage compared to Dudeney et al (30.6 versus 4%, respectively).

The Bartolozzi et al, Kasperk et al, and Audat et al studies compared KP with other treatment modalities. Bartolozzi et al treated patients with KP or PV in fractured vertebrae only. They made their decision on which procedure to perform via magnetic resonance imaging (MRI) and spiral CT scan; PV was chosen for those vertebrae that had a collapsed body, especially if there was destruction of the posterior lamina or increased bone density, while KP was chosen when the risk for cement extravasation was high from instability. Only fractured vertebrae were treated. The authors concluded no significant differences in clinical outcomes between PV and KP.

The Kasperk et al study compared radiation therapy and KP in both fractured and nonfractured vertebrae. Kasperk et al found improvements in the Oswestry Disability Index (ODI) after 1 year in their KP-only group ( $P < .001$ ) and no such improvements in their radiation-only group. Kyphoplasty

**Table 3.** Kyphoplasty study characteristics.

Study	Follow Up	Change in Pain Score (Score Type)	Functional Scores	Cement Leakage	Symptomatic Complications/ Neurological Deterioration	Vertebral Body Height Changes
Dudeny et al <sup>18</sup>	Mean 7.4 mo	+32.1 improvement (bodily pain score from SF36 Health Survey)	From SF36: +29.3 physical function ( $P = .0010$ ), +16.2 vitality ( $P = .010$ ), +24.2 social functioning ( $P = .014$ )	2 vertebra (4%)	None	Of measured (39/55 vertebra), 34% (0–100%) mean percentage of height lost that was restored; complete restoration (n = 4 vertebra), 56% restoration (n = 23 vertebra)
Kasperk et al <sup>14</sup>	<2 y	–66 (VAS, 0–100 mean)	Reduction in ODI after 1 y ( $P < 0.001$ ) in KP group only	34 vertebra (30.6%)	Revision surgery (n = 2 patients, 2.7%) due to a dorsal leak and spinal stenosis, respectively	Vertebral height remained stable after KP ( $P = .283$ ); 4.2% height restoration ( $P = .044$ )
Audat et al <sup>12*</sup>	Mean 36 mo	ODI: –10.06, SS: +2.58, SINS: –5.65	ODI: –10.06, SS: +2.58, SINS: –5.65	3 vertebra (1.4%)	Deaths (n = 1, 7.1%, KP/PV/conventional therapy group) from acute long embolism on day of surgery	NA
Bartolozzi et al <sup>24†</sup>	Median 10 mo (1–16)	–6 (VAS, median)	+20 median Karnofsky performance status, 24 h posttreatment	NA	None	NA

Abbreviation: KP, kyphoplasty; NA, not available; ODI, Oswestry Disability Index; SINS, Spinal Instability Neoplastic Score; SS, standard score; VAS, visual analog scale. \*KP/PV on same patient.

†KP only vs PV only results not differentiated.

patients in this study showed the vertebral height remaining stable after KP ( $P = .283$ ), with a small improvement in height from 64.4 to 68.6% ( $P = .044$ ), in contrast to a progressive height loss in the other groups ( $P = .013$  and  $P = .015$  for radiation only and systemic therapy only, respectively).

Audat et al compared chemotherapy and/or radiation (Group I) with KP/PV/conventional therapy (Group II) in both fractured and non-fractured vertebrae. The larger improvements in SS, ODI, and SINS scores (Table 3) in the cementoplasty group suggest the significant improvement in clinical outcomes for MM patients when using cementoplasty therapy over conventional therapy (Table 3).

Kyphoplasty can also be advantageous in that it can restore lost vertebral height, resulting in improved stability, mobility, and pain relief. Dudeny et al saw a restoration of 34% of lost height in the 39/55 vertebrae they were able to measure, while Kasperk et al saw a small but significant height improvement from 66.4 to 68.6% ( $P = .044$ ). Additionally, compared to their radiation and

control groups, the KP group saw fewer new fractures of all thoracic and lumbar vertebrae ( $P < .002$  and  $P = .026$ , respectively) in a 2-year period.

Dudeny et al argued that timely treatment of the vertebral fractures is of major importance and that KP should be the treatment of choice, unless the posterior wall of the vertebra is deficient, inviting risk for bone fragment displacement when inflating. Kasperk et al further argued that KP's benefits may be related to the morphological changes from partial restoration of lost vertebral height. This restoration can reduce the risk of further fractures by reducing strain, improving posture, and restoring proper body mechanics.<sup>14</sup> Furthermore, Audat et al argued that cementoplasty followed by conventional therapy showed significantly better results in terms of pain, vertebral height restoration, improvements in mobility, and sagittal balance. Although mortality rates did not differ between the groups, morbidity rates did improve for the KP/PV/conventional therapy.<sup>12</sup> Additionally, at 3 years, they found that all but 1 patient was completely mobile, all were back pain free except for 3 patients who had

**Table 4.** Percutaneous vertebroplasty study characteristics.

Study	Change in Pain Score (Score Type)	Time to Follow Up	Functional Scores	Cement Leakage	Symptomatic Complications/Neurological Deterioration	Vertebral Body Height Changes
Masala et al <sup>25</sup>	-6.12 (VAS, mean)	6 mo	NA	NA	None	NA
Masala et al <sup>26</sup>	-6 (VAS, mean)	6 mo	NA	1 patient (2.5%)	None	NA
Nas et al <sup>27</sup>	-8 (VAS, mean)	NA	NA	68 vertebrae (41%)	None	166 vertebra with loss of height (100%)
Chen et al <sup>28</sup>	-4.3 (VAS, mean)	24 h, at 3 mo and at 1 y	NA	2 patients (8.3%)	None	NA
Anselmetti et al <sup>1</sup>	-8 (VAS, median)	28.2 mo ± 12.1	NA	121 vertebra (22.9%)	Deaths: 2 patients (1.6%) via disseminated intravascular coagulopathy and <i>Staphylococcus aureus</i> infection, respectively	NA
McDonald et al <sup>29</sup>	-5.3 (VAS, median)	1 y	Improvement in mobility 1 wk postoperation (n = 47 patients, 70%) NA	13 patients (19.4%)	Symptomatic compression fractures (5 patients, 7.4%)	NA
Simony et al <sup>30</sup>	-5.3 (VAS median)	3 mo	NA	8 vertebra (12.2%)	Peroneal paresis (1 patient, 6%)	NA
Ramos et al <sup>31</sup>	-2.5 (VAS, mean)	Median 3.2 y (2–56 mo)	-0.6 ECOG scale	16 vertebrae (84%)	None	NA
Diamond et al <sup>32</sup>	-15 (VAS 0–25, mean)	6 wk	Significant improvement	None	None	NA
Thang et al <sup>33</sup>	-5.38 (VAS, mean)	Median 41 mo (3–81)	-1.04 mean ECOG E12 score	8 patients (24%)	Transient thoracic pain or dyspnea (2 patients, 7%)	NA
Bartolozzi et al <sup>33</sup>	-6 (VAS, median)	Median 10 mo (1–16)	+20 median Karnofsky performance status, 24 h posttreatment	NA	None	NA
Orgera et al <sup>34</sup>	-7 (VAS, mean)	6 mo	NA	2 patients (7%)	None	NA

Abbreviations: ECOG, Eastern Cooperative Oncology Group; NA, not available; VAS, visual analog scale.

complications from disc disease or fracture of vertebral end plate over cement, and all had preserved vertebral height and sagittal balance, except for 1 patient. Their results continued for 3 years, suggesting the persistent, long-term benefits of cementoplasty. For height restoration, in collapsed vertebrae, cementoplasty can be used as a standalone therapy or in combination with other therapies except in the setting of vertebra plana. If concern for extravasation is high, then KP should be selected over PV, and cement volume should be reduced under direct fluoroscopic visualization.

### Percutaneous Vertebroplasty

We found 12 studies (Masala et al,<sup>25,26</sup> Nas et al,<sup>27</sup> Chen et al,<sup>28</sup> Anselmetti et al,<sup>1</sup> McDonald et al,<sup>29</sup> Simony et al,<sup>30</sup> Ramos et al,<sup>31</sup> Diamond et al,<sup>32</sup> Thang et al,<sup>33</sup> Bartolozzi et al,<sup>24</sup> and Orgera et al<sup>34</sup>) that evaluated PV alone. All studies reported improvements in pain scores, and of those that

commented on functional scores, all saw improvements as well (Table 4).

Studies differed in their follow-up times and amount of cement used. There was no discernable pattern in differences in pain scores based on the time of follow up. Differences in procedural performance included different needle gauge, amount of strict bed rest following the procedure, and whether a C-arm was used.

Extravasation was found in 10/11 studies, with Bartolozzi et al being the only study that did not comment on cement leaks. Four studies (33%) found any additional clinical or radiographic complications caused by extravasation with none leading to any neurological deterioration. In terms of height loss, only Nas et al reported any data, based on a semiquantitative visual assessment index developed by Genant et al<sup>35</sup> (Table 4).

As was mentioned in the Miller et al paper, SR might be more effective for patients who lack spinal

**Table 5.** Cementoplasty and/or radio frequency ablation study characteristics.

Study	Symptomatic Relief	Time to Follow Up	Change in Pain Score (Score Type)	Symptomatic Complications/Neurological Deterioration
Trumm et al <sup>36*</sup>	20 patients (71.4%) reported a reduction of pain, 4 patients (14.3%) reported no change in pain, and 4 patients (14.3%) reported an increase in pain	Mean 9 mo	-3.2 (VAS, mean)	None
Orgera et al <sup>34</sup>	NA	24 h, 6 wk, and MRI at 1, 3, and 6 mos	-7.1 (VAS, mean)	None

Abbreviation: MRI, magnetic resonance imaging; NA, not available; VAS, visual analog scale.

\*Performed radio frequency ablation prior to cementoplasty in 6 patients for tumor debulging.

fractures. Thang et al examined PV for vertebrae treated that were not fractured and found a continued clinical improvement in pain and functionality in these patients, which made the authors suggest that extending PV procedures to nonfractured vertebrae as well as multiple vertebrae to treat refractory bone pain is effective. They base this finding on the antitumor properties of PMMA and their results of increased pain killing when multiple vertebrae were treated (range 1–9).<sup>33</sup> Given KP's higher cost and the finding that both PV and KP lead to improvements in pain and functional scores in both fractured and nonfractured vertebrae, PV may be the ideal choice for treatment of refractory back pain in MM patients, even with the slightly increased rate of complications from PV.

#### Percutaneous Vertebroplasty and Radio Frequency Ablation

Two studies examined RFA followed by PV (Orgera et al<sup>34</sup> and Trumm et al<sup>36</sup>), with both finding improvements in pain scores (Table 5). Trumm et al focused their study on patients treated with PV, but had 6 (15.4%) of their patients treated with RFA prior to PV for tumor debulging. They did not differentiate their results, and thus, conclusions cannot be formed.

In the comparison of PV versus RFA/PV by Orgera et al, the authors found similar results in terms of pain reduction, disability score improvements, and decrease in postoperative analgesic use. Radio frequency ablation is theorized to reduce pain via local destruction of pain-sensitive nerves and decrease in production of cytokines and growth factors via necrosis,<sup>37,38</sup> which can provide greater control during the cement filling stage, reducing the leakage rate for PV. Additionally, RFA before cement injection is theorized to reduce the risk of tumor cell spread by either mechanically creating an

ablation-shell barrier or via embolization of necrotic tumor cells. However, the authors did not find that additional RFA treatment prior to cementoplasty provided any advantage in terms of pain and functionality improvement and cement leak rates. The authors argue that given the cost, time, and potential for thermal damage, RFA does not provide any added benefit to MM patients.<sup>34</sup>

It is important to note other combination therapies that are used in metastatic bone disease outside of MM that may serve as future directions of study. A study by Pichon et al investigated SR with zoledronate therapy in patients with refractory back pain from metastatic bone disease. They found significant improvements in pain at 1 and 3 months posttherapy.<sup>39</sup> Another study by Barzilai et al investigated SR in combination with cementoplasty for metastatic bone disease, finding that cementoplasty prior to SR is safe.<sup>40</sup>

## CONCLUSIONS

Delivery of radiation therapy appeared to be consistently linked to improved pain and functional scores, with Miller et al showing improved results in the setting of spinal cord abutment. However, optimal dosing and radiation fractioning are unknown, and long-term studies are suggestive of increased rates of radiographic failure and vertebral collapse. Comparative analyses of pain scores, neurologic outcomes, and disability indices between radiotherapy and cementoplasty are difficult to perform given the large baseline variability in the studied cohorts, with the exception of 1 retrospective publication. The direct comparison of Kasperk et al demonstrated significantly improved pain and functional scores with preserved vertebral height in favor of KP over radiotherapy in both fractured vertebrae and in the setting of osteolytic lesions.



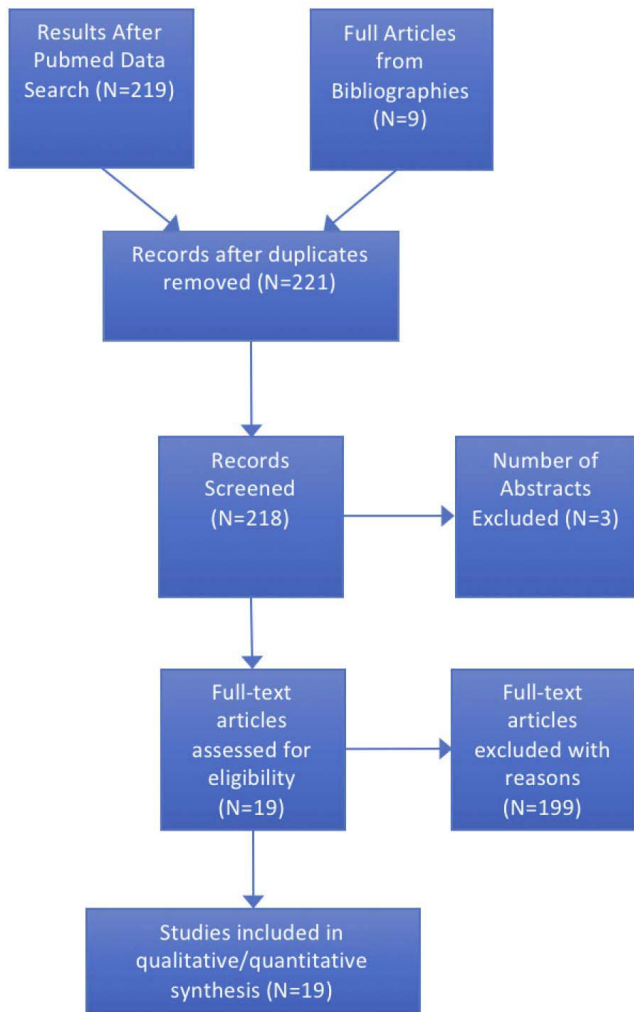


Figure 1. Literature review flowchart.

Bartolozzi et al found no statistical differences in pain and functional scores between their patients treated with KP and PV, albeit rates of cement leakage in PV have been called into question in the literature, with rates of leakage reported to be between 30–60%.<sup>41–43</sup> Unless contraindicated, we advocate for some form of cementoplasty for optimal pain relief, functional outcomes, and future fracture prevention, although the volume of cement necessary remains controversial.<sup>44</sup> If risk of extravasation is high, then we recommend KP, unless contraindicated, such as in the setting of destroyed posterior aspect of the vertebral body. Although performing RFA in conjunction with cementoplasty might prove to provide better results for the cementoplasty because of the theorized synergistic destruction of local pain-sensitive nerves and providing greater control of filling, the randomized control trial done by Orgera et al did not find that

additional RFA treatment prior to cementoplasty provided any appreciable advantage. This finding may be related to smaller sample size and only 6 weeks of recorded outcome measures.

At this time, there does not appear to be a consensus on the optimum treatment algorithm for vertebral myeloma lesions. The aim of future directed studies should focus on standardization of dose-based variables in treatment modalities (eg, cement viscosity, radiation amount delivered based upon tumor burden, and RFA protocols) and the implementation of alternative adjunctive therapies already used in metastatic lesion treatment. Moreover, larger cohort studies with a predetermined treatment protocol for myeloma patients based upon structural and neurologic scoring systems, similar to the neurologic, oncologic, mechanical, and systemic decision tree are necessary and should be employed.<sup>45</sup>

## REFERENCES

1. Anselmetti GC, Manca A, Montemurro F, et al. Percutaneous vertebroplasty in multiple myeloma: prospective long-term follow-up in 106 consecutive patients. *Cardiovasc Intervent Radiol*. 2012;35(1):139–145.
2. Anderson KC. Multiple myeloma: a clinical overview. *Oncology (Williston Park)*. 2011;25 Suppl 2:3–9.
3. Angtuaco EJ, Fassas AB, Walker R, Sethi R, Barlogie B. Multiple myeloma: clinical review and diagnostic imaging. *Radiology*. 2004;231(1):11–23.
4. Lecouvet FE, Malghem J, Michaux L, et al. Vertebral compression fractures in multiple myeloma. Part II. Assessment of fracture risk with MR imaging of spinal bone marrow. *Radiology*. 1997;204(1):201–205.
5. Lecouvet FE, Vande Berg BC, Maldaque BE, et al. Vertebral compression fractures in multiple myeloma. Part I. Distribution and appearance at MR imaging. *Radiology*. 1997;204(1):195–199.
6. Vincent Rajkumar S. Multiple myeloma: 2014 update on diagnosis, risk-stratification, and management. *Am J Hematol*. 2014;89(10):999–1009.
7. Bjorkstrand B, Gahrton G. High-dose treatment with autologous stem cell transplantation in multiple myeloma: past, present, and future. *Semin Hematol*. 2007;44(4):227–233.
8. Curran MP, McKeage K. Bortezomib: a review of its use in patients with multiple myeloma. *Drugs*. 2009;69(7):859–888.
9. Raab MS, Breitkreutz I, Anderson KC. Targeted treatments to improve stem cell outcome: old and new drugs. *Bone Marrow Transplant*. 2007;40(12):1129–1137.
10. von Lilienfeld-Toal M, Hahn-Ast C, Furkert K, et al. A systematic review of phase II trials of thalidomide/dexamethasone combination therapy in patients with relapsed or refractory multiple myeloma. *Eur J Haematol*. 2008;81(4):247–252.
11. Musto P, Petrucci MT, Bringhen S, et al. A multicenter, randomized clinical trial comparing zoledronic acid versus

observation in patients with asymptomatic myeloma. *Cancer*. 2008;113(7):1588–1595.

12. Audat ZA, Hajjousef MH, Fawareh MD, et al. Comparison if the addition of multilevel vertebral augmentation to conventional therapy will improve the outcome of patients with multiple myeloma. *Scoliosis Spinal Disord*. 2016;11:47.

13. Tosi P. Diagnosis and treatment of bone disease in multiple myeloma: spotlight on spinal involvement. *Scientifica (Cairo)*. 2013;2013:104546.

14. Kasperk C, Haas A, Hillengass J, et al. Kyphoplasty in patients with multiple myeloma a retrospective comparative pilot study. *J Surg Oncol*. 2012;105(7):679–686.

15. Belkoff SM, Mathis JM, Deramond H, Jasper LE. An ex vivo biomechanical evaluation of a hydroxyapatite cement for use with kyphoplasty. *AJNR Am J Neuroradiol*. 2001;22(6):1212–1216.

16. Belkoff SM, Mathis JM, Fenton DC, Scribner RM, Reiley ME, Talmadge K. An ex vivo biomechanical evaluation of an inflatable bone tamp used in the treatment of compression fracture. *Spine (Phila Pa 1976)*. 2001;26(2):151–156.

17. Lieberman IH, Dudeney S, Reinhardt MK, Bell G. Initial outcome and efficacy of “kyphoplasty” in the treatment of painful osteoporotic vertebral compression fractures. *Spine (Phila Pa 1976)*. 2001;26(14):1631–1638.

18. Dudeney S, Lieberman IH, Reinhardt MK, Hussein M. Kyphoplasty in the treatment of osteolytic vertebral compression fractures as a result of multiple myeloma. *J Clin Oncol*. 2002;20(9):2382–2387.

19. Al-Nakshabandi NA. Percutaneous vertebroplasty complications. *Ann Saudi Med*. 2011;31(3):294–297.

20. Miller JA, Balagamwala EH, Chao ST, et al. Spine stereotactic radiosurgery for the treatment of multiple myeloma. *J Neurosurg Spine*. 2017;26(3):282–290.

21. Jin R, Rock J, Jin JY, et al. Single fraction spine radiosurgery for myeloma epidural spinal cord compression. *J Exp Ther Oncol*. 2009;8(1):35–41.

22. Klimo P Jr, Schmidt MH. Surgical management of spinal metastases. *Oncologist*. 2004;9(2):188–196.

23. Lecouvet F, Richard F, Vande Berg B, et al. Long-term effects of localized spinal radiation therapy on vertebral fractures and focal lesions appearance in patients with multiple myeloma. *Br J Haematol*. 1997;96(4):743–745.

24. Bartolozzi B, Nozzoli C, Pandolfo C, et al. Percutaneous vertebroplasty and kyphoplasty in patients with multiple myeloma. *Eur J Haematol*. 2006;76(2):180–181.

25. Masala S, Anselmetti GC, Marcia S, Massari F, Manca A, Simonetti G. Percutaneous vertebroplasty in multiple myeloma vertebral involvement. *J Spinal Disord Tech*. 2008;21(5):344–348.

26. Masala S, Volpi T, Fucci FP, Cantonetti M, Postorino M, Simonetti G. Percutaneous osteoplasty in the treatment of extraspinal painful multiple myeloma lesions. *Support Care Cancer*. 2011;19(7):957–962.

27. Nas ÖF, Inecikli MF, Hacıkurt K, et al. Effectiveness of percutaneous vertebroplasty in patients with multiple myeloma having vertebral pain. *Diagn Interv Radiol*. 2016;22(3):263–268.

28. Chen LH, Hsieh MK, Niu CC, Fu TS, Lai PL, Chen WJ. Percutaneous vertebroplasty for pathological vertebral compression fractures secondary to multiple myeloma. *Arch Orthop Trauma Surg*. 2012;132(6):759–764.

29. McDonald RJ, Trout AT, Gray LA, Dispenzieri A, Thielen KR, Kallmes DF. Vertebroplasty in multiple myeloma: outcomes in a large patient series. *AJNR Am J Neuroradiol*. 2008;29(4):642–648.

30. Simony A, Hansen EJ, Gaurilcik M, Abildgaard N, Andersen MØ. Pain reduction after percutaneous vertebroplasty for myeloma-associated vertebral fractures. *Dan Med J*. 2014;61(12):A4945.

31. Ramos L, de Las Heras JA, Sánchez S, et al. Medium-term results of percutaneous vertebroplasty in multiple myeloma. *Eur J Haematol*. 2006;77(1):7–13.

32. Diamond TH, Hartwell T, Clarke W, Manoharan A. Percutaneous vertebroplasty for acute vertebral body fracture and deformity in multiple myeloma: a short report. *Br J Haematol*. 2004;124(4):485–487.

33. Tran Thang NN, Abdo G, Martin JB, et al. Percutaneous cementoplasty in multiple myeloma: a valuable adjunct for pain control and ambulation maintenance. *Support Care Cancer*. 2008;16(8):891–896.

34. Orgera G, Krokidis M, Matteoli M, et al. Percutaneous vertebroplasty for pain management in patients with multiple myeloma: is radiofrequency ablation necessary? *Cardiovasc Intervent Radiol*. 2014;37(1):203–210.

35. Genant HK, Wu CY, van Kuijk C, Nevitt MC. Vertebral fracture assessment using a semiquantitative technique. *J Bone Miner Res*. 1993;8(9):1137–1148.

36. Trumm C, Jakobs T, Pahl A, et al. CT fluoroscopy-guided percutaneous vertebroplasty in patients with multiple myeloma: analysis of technical results from 44 sessions with 67 vertebrae treated. *Diagn Interv Radiol*. 2012;18(1):111–120.

37. Dupuy DE, Liu D, Hartfeil D, et al. Percutaneous radiofrequency ablation of painful osseous metastases: a multicenter American College of Radiology Imaging Network trial. *Cancer*. 2010;116(4):989–997.

38. Woolf CJ, Allchorne A, Safieh-Garabedian B, Poole S. Cytokines, nerve growth factor and inflammatory hyperalgesia: the contribution of tumour necrosis factor alpha. *Br J Pharmacol*. 1997;121(3):417–424.

39. Pichon B, Champion L, Delpon G, et al. High-dose hypofractionated radiation therapy for noncompressive vertebral metastases in combination with zoledronate: a phase I study. *Int J Radiat Oncol Biol Phys*. 2016;96(4):840–847.

40. Barzilai O, DiStefano N, Lis E, et al. Safety and utility of kyphoplasty prior to spine stereotactic radiosurgery for metastatic tumors: a clinical and dosimetric analysis. *J Neurosurg Spine*. 2018;28(1):72–78.

41. Watts NB, Harris ST, Genant HK. Treatment of painful osteoporotic vertebral fractures with percutaneous vertebroplasty or kyphoplasty. *Osteoporos Int*. 2001;12(6):429–437.

42. Martin JB, Jean B, Sugi K, et al. Vertebroplasty: clinical experience and follow-up results. *Bone*. 1999;25(2 Suppl):11s–15s.

43. Ratliff J, Nguyen T, Heiss J. Root and spinal cord compression from methylmethacrylate vertebroplasty. *Spine (Phila Pa 1976)*. 2001;26(13):E300–E302.

44. Cotten A, Dewatre F, Cortet B, et al. Percutaneous vertebroplasty for osteolytic metastases and myeloma: effects of the percentage of lesion filling and the leakage of methyl methacrylate at clinical follow-up. *Radiology*. 1996;200(2):525–530.

45. Laufer I, Rubin DG, Lis E, et al. The NOMS

framework: approach to the treatment of spinal metastatic tumors. *Oncologist*. 2013;18(6):744–751.

**Disclosures and COI:** The authors have no conflicts of interest to disclose.

**Corresponding Author:** Manan Sunil Patel, BA, University of Miami Miller School of Medicine, 2941 SW 1st Ave., Miami, FL 33129. Phone: (502)

432-9452; Fax: (305) 324-7658; Email: msp131@med.miami.edu.

Published 15 October 2018

This manuscript is generously published free of charge by ISASS, the International Society for the Advancement of Spine Surgery. Copyright © 2018 ISASS. To see more or order reprints or permissions, see <http://ijssurgery.com>.