

Neurologically Asymptomatic Lumbar Traumatic Dislocation With Vascular Compression in a Patient With Ankylosing Spondylitis: Case Report

Jacinto Mata-Gómez, Ignacio Javier Gilete-Tejero, María Rico-Cotelo, Manuel Royano-Sánchez, Aurora Moreno-Flores and Marta Ortega-Martínez

Int J Spine Surg 2021, 14 (s4) S16-S20

doi: <https://doi.org/10.14444/7159>

<https://www.ijssurgery.com/content/14/s4/S16>

This information is current as of May 12, 2025.

Email Alerts Receive free email-alerts when new articles cite this article. Sign up at:
<http://ijssurgery.com/alerts>

Neurologically Asymptomatic Lumbar Traumatic Dislocation With Vascular Compression in a Patient With Ankylosing Spondylitis: Case Report

JACINTO MATA-GÓMEZ, MD,¹ IGNACIO JAVIER GILETE-TEJERO, MD,² MARÍA RICO-COTELO, MD,²
MANUEL ROYANO-SÁNCHEZ, MD,² AURORA MORENO-FLORES, MD,¹ MARTA ORTEGA-
MARTÍNEZ, MD²

¹Neurosurgery Department, Complejo Hospitalario Universitario de Badajoz, Spain, ²Neurosurgery Department, Complejo Hospitalario Universitario de Cáceres, Spain

ABSTRACT

Background: Ankylosing spondylitis (AS) is associated with high rates of severe thoracolumbar fractures, in many cases with neurological deficits. It is currently a point of debate as to whether the optimal surgical treatment is posterior fixation and fusion or combined approaches. Vascular injuries in this kind of fracture are a challenging issue to solve in the management of these patients.

Methods: We are reporting the case of a 65-year-old man who presented an L4 traumatic fracture-dislocation. He had a long history of symptomatic AS. No neurological deficits were detected during the initial exploration. During the preoperative work-up, a lumbar spine computed tomography (CT) scan was taken with vascular reconstruction of the abdominal vessels. It confirmed the compression of the abdominal aorta, which had caused more than 90% stenosis. A posterior approach, an open reduction, and fixation with pedicle screws were performed, without hemodynamic or neurological changes. A postoperative angiography demonstrated a complete recovery of the vessel caliber, without contrast leaks.

Results: After a 2-year follow-up, the patient was pain free and the CT scan revealed bone fusion.

Conclusions: The vascular structures involved in severe thoracolumbar fractures present a dangerous situation that should be considered in the choice of the surgical approach. The posterior approach alone may be a good option in the absence of vascular damage. However, due to risk of vessel rupture during the fracture reduction, vascular surgeons must take part in the surgery.

Level of Evidence: 5.

Clinical Relevance: The article provides help for surgeons who have to treat severe fractures in the context of ankylosing spondylitis

Lumbar Spine

Keywords: ankylosing spondylitis, thoracolumbar spine, fracture dislocation, posterior fusion, vascular compression

INTRODUCTION

Ankylosing spondylitis (AS) is a rheumatological disease characterized by a progressive ossification of osseoligamentous elements of the spine. The final result is the appearance of syndesmophytes at the level of the discs, progressive osseous fusion that results in the formation of an ankylosed spine (called “Bamboo spine”). The estimated prevalence^{1,2} of AS is 0.1%–4% of the general population and is more common in males, with a male to female ratio of 2:1

AS is associated with an elevated risk of vertebral fractures. Some studies have reported rates from approximately 10%–43% in patients with AS.^{3,4}

These fractures are common in the context of mild traumas. Neurological deficits appear in between 21% and 100% of cases, according to published studies.⁵ It is usually necessary to treat these fractures surgically because there is mechanical instability and a risk of delayed neurological deficits as well as osteoporosis, which hinders osseous fusion. The posterior approach is the most common one to treat this kind of fracture. However, combined approaches could be an option in severe cases.

A thoracolumbar fracture-dislocation is a rare and severe injury among the fractures in AS. The damage in the osseous structures and ligaments is

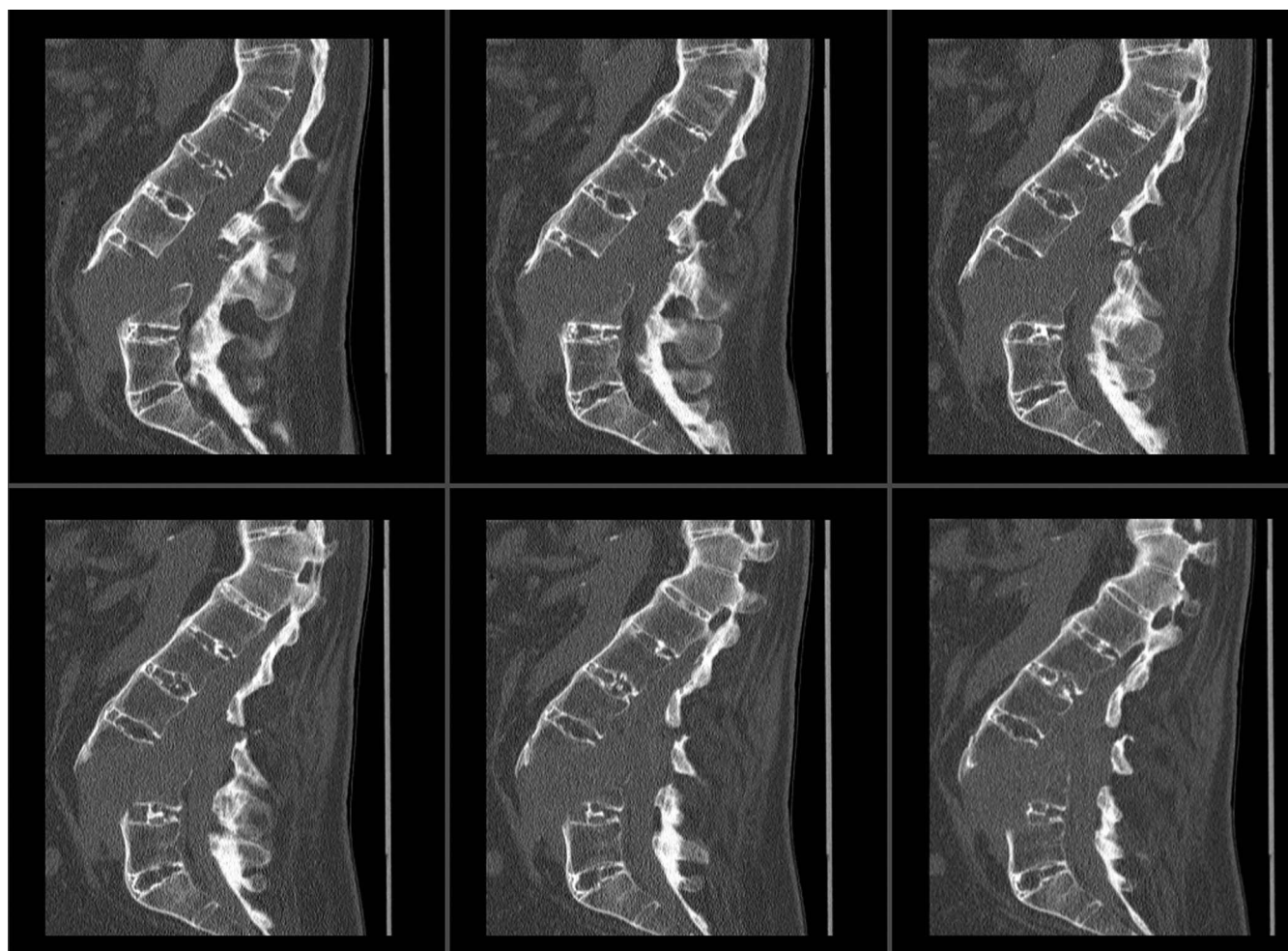


Figure 1. Preoperative sagittal plane lumbar computed tomography (CT) scan. The anterior displacement of the superior spine suggests abdominal vascular involvement.

associated with significant instability, and the neurological function is damaged in most cases.⁶ Visceral or vascular structures can be involved in some cases, which poses a challenge in the diagnosis and management of these fractures. We are reporting a case of lumbar fracture-dislocation with vascular compression in a symptomatic patient with AS.

CASE REPORT

History and Examination

A 65-year-old male patient who had a 3-m fall was admitted in the emergency room of our institution with intensive low back pain and mild left L4 distribution pain. He suffered from a long-course HLA B27-positive AS with secondary thoracolumbar hyperkyphosis. In the initial neurological examination, we found normal muscular balance and no sensory deficits in either superficial

or proprioceptive explorations. The osteomuscular reflexes were symmetrical and normal and presented a negative Babinski sign. The initial radiological work-up consisted of plain lumbar x-rays and a computed tomography (CT) scan (Figure 1). They revealed L3-L4 fracture-dislocation (type C in the AO Spine thoracolumbar fractures classification⁷) with anterior displacement of the upper spine, which suggested compression or injury of the abdominal vascular structures. An angio-CT scan was taken (Figure 2). It showed a severe narrowing in the final segment of the abdominal aorta close to the bifurcation in the iliac branches, but no hemoperitoneum or other signs of rupture of the vessels. The laboratory tests were also normal. Because compression was likely, we consulted the vascular surgeon. He completed the study with a Doppler ultrasonography of the lower limb arteries that showed a decreased pulse wave, but it was maintained in the main branches.

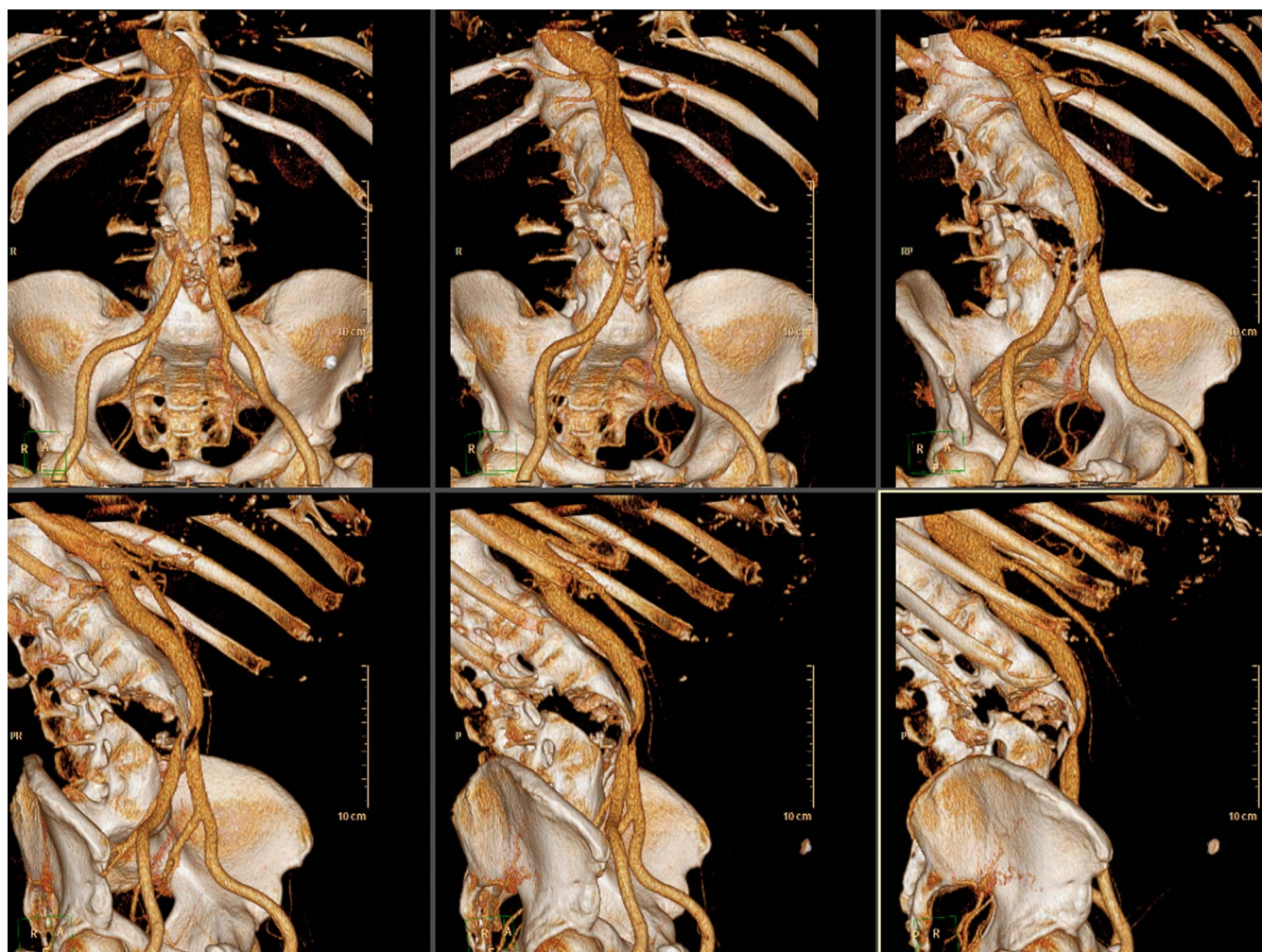


Figure 2. Reconstruction of vascular abdominal computed tomography (CT) scan. There was a compression of the abdominal aorta close to the bifurcation of the iliac arteries, but the flow in these arteries was conserved.

Surgical Operation and Follow-Up

We initially performed a posterior approach, an open reduction, an L3-L4 laminectomy, and a fixation with titanium pedicle screws and rods. During the operation, the vascular surgeon was present in case vascular injuries occurred during the reduction maneuvers. There was no hemodynamic instability during the surgical procedure. The intraoperative C-arm image indicated that spine alignment was achieved. After surgery the patient remained neurologically intact. An arteriography of the lower limbs was taken the same day, showing a restitution of the abdominal aorta diameter. The patient was discharged 10 days after surgery. No medical complications, wound infection, or cerebral spinal fluid fistula were recorded. He resumed his everyday activities at home without lumbar pain.

Seven months after surgery, the patient complained of increased lumbar pain. The lumbar x-rays

revealed a unilateral titanium rod had ruptured and the osseous fusion had not been achieved yet. We decided to reoperate upon the patient and replace the titanium rods with cobalt chrome ones. No more complications were recorded during the follow-up. Two years after surgery a CT scan was taken. It revealed the realignment of the spine and osseous fusion (Figure 3).

DISCUSSION

Thoracolumbar fracture-dislocations are complex injuries that involve the 3 columns of the spine and are usually related to neurological damage. Occasionally, these kinds of fractures may produce visceral or vascular injuries. There are few publications⁸⁻¹⁴ about these complications, but the severity of the injuries in these cases result in fatal outcomes.¹⁵ Our case is exceptional due to the lack of neurological and vascular symptoms, even more

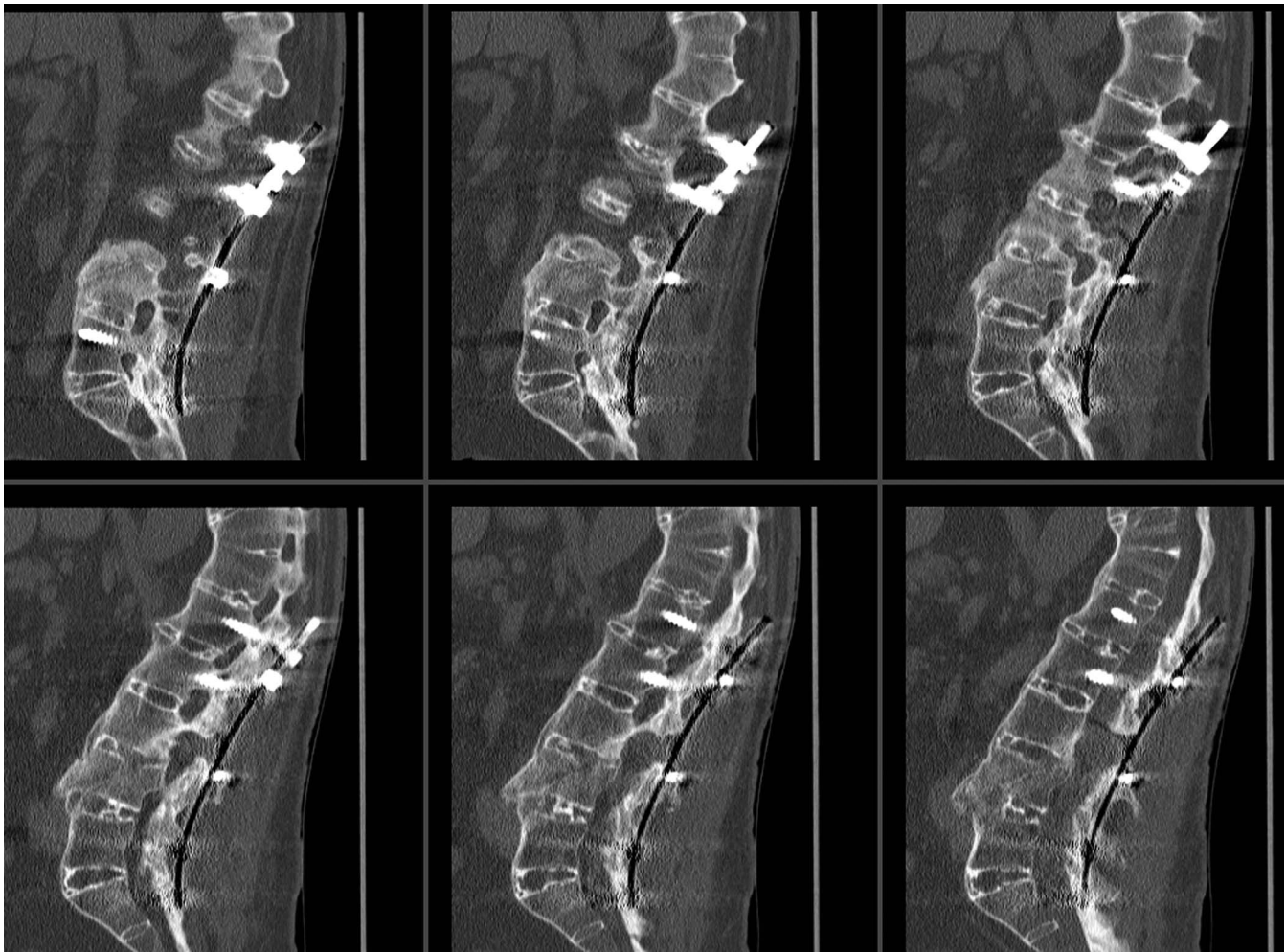


Figure 3. Two-year control lumbar computed tomography (CT) scan. Progressive osseous fusion was obtained after the placement of cobalt-chrome rods.

in the association with AS.^{8,10,12,13,16} Nevertheless, the presence of vascular compression should be considered an indication of urgent spinal realignment. The maintenance of this condition may produce progressive ischemia of visceral structures¹⁵ or lower limbs. The correct management of vascular injuries depends on the type of injuries. Ruptures of the vessels should be treated directly with open or endovascular¹⁷ repair before fracture reduction. However, compressions may be managed conservatively if the spinal deformity disappears and no hemodynamic changes occur during the reduction of the fractures. An angiography should be taken in the early postoperative course to check the vessels' integrity. If the angiography does not show new injuries, such as pseudoaneurysm or intimal tears, antithrombotic prophylaxis should be maintained for 3–4 weeks at least. Nevertheless, due to the possibility of severe intraoperative vascular complications during the reduction of the fracture, the

vascular surgeon must be also in the surgery to treat an unexpected rupture.

The optimal surgical treatment of these kinds of fractures is already under discussion. The posterior approach is the most common approach.^{5,6} It provides good possibilities of reduction, fixation, and decompression of neurological structures. Although this technique is good enough in most cases, some authors⁶ indicate that the lack of anterior support may produce progressive kyphosis and instrumentation failure in the long run. Therefore, they prefer the posteroanterior approach or thoracic interbody fusion.^{6,18} In AS, in which there is a tendency to form bone in the fracture focus, the posterior approach is more likely to be effective. However, in our case, the lack of osseous fusion did not provide enough anterior support and, consequently, a rupture of 1 rod was recorded during the follow-up. The use of cobalt chrome rods during the initial surgical procedure may reduce this

complication due to the more rigid construction that this material provides.

Combined approaches may be an option in severe fractures. These approaches provide better anterior support, but the rate of complications also increases. Vascular injuries need an initial anterior approach to repair the damage, but the realignment of the spine using only this approach is very complicated. However, the choice of optimal approach depends on the associated injuries, individual comorbidities, and the experience of the surgeon.

REFERENCES

1. Fan D, Liu L, Ding N, et al. Male sexual dysfunction and ankylosing spondylitis: a systematic review and metaanalysis. *J Rheumatol*. 2015;42:252–257.
2. Stolwijk C, Essers I, van Tubergen A, et al. The epidemiology of extra-articular manifestations in ankylosing spondylitis: a population-based matched cohort study. *Ann Rheum Dis*. 2015;74:1373–1378.
3. Jacobs WB, Fehlings MG. Ankylosing spondylitis and spinal cord injury: origin, incidence, management, and avoidance. *Neurosurg Focus*. 2008;24:E12. doi:10.3171/FOC/2008/24/1/E12
4. Zhang M, Li XM, Wang GS, et al. The association between ankylosing spondylitis and the risk of any, hip, or vertebral fracture: a meta-analysis. *Medicine (Baltimore)*. 2017;96:e8458. doi:10.1097/MD.00000000000008458
5. Rustagi T, Drazin D, Oner C, et al. Fractures in spinal ankylosing disorders: a narrative review of disease and injury types, treatment techniques and outcomes. *J Orthop Trauma*. 2017;31:S57–S74.
6. Hao D, Wang W, Duan K, et al. Two-year follow-up evaluation of surgical treatment for thoracolumbar fracture-dislocation. *Spine (Phila Pa 1976)*. 2014;39:E1284–E1290.
7. Vaccaro AR, Owner C, Kepler CK, et al. AO Spine thoracolumbar spine injury classification system: fracture description, neurological status, and key modifiers. *Spine (Phila Pa 1976)*. 2017;38:2028–2037.
8. Blockx L, Ramboer K. Aortic rupture complicating the fracture of an ankylosed lumbar spine. *JBR-BTR*. 2014;97:142–143.
9. Inaba K, Kirkpatrick AW, Finkelstein J, et al. Blunt abdominal aortic trauma in association with thoracolumbar spine fractures. *Injury*. 2001;32:201–207.
10. Lifshutz J, Lidar Z, Maiman D. Thoracic aortic pseudoaneurysm after spine trauma in ankylosing spondylitis. *J Neurosurg Spine*. 2005;2:218–221.
11. Santoro G, Ramieri A, Chiarella V, Vigliotta M, Domenicucci M. Thoraco-lumbar fractures with blunt traumatic aortic injury in adult patients: correlations and management. *Eur Spine J*. 2018;27(suppl 2):248–257.
12. Schaberg FJ. Aortic injury occurring after minor trauma in ankylosing spondylitis. *J Vasc Surg*. 1986;4:410–411.
13. Savolaine ER, Ebraheim NA, Stitgen S, Jackson WT. Aortic rupture complicating a fracture of an ankylosed thoracic spine: a case report. *Clin Orthop Relat Res*. 1991;272:136–140.
14. Tiesenhausen K, Thalhammer M, Koch G, Schleifer P. Traumatic aortic rupture in ankylosing spondylitis—a fatal complication. *Unfallchirurg*. 2001;104:1101–1103.
15. Pontikis G, Hershberger RC. Severe aortic compression from displaced chance fracture after traumatic fall. *J Vasc Surg Venous Lymphat Disord*. 2016;4:345. doi:10.1016/j.jvsv.2015.12.003
16. Fazl M, Bilbao JM, Hudson AR. Laceration of the aorta complicating spinal fracture in ankylosing spondylitis. *Neurosurgery*. 1981;8:732–734.
17. Domenicucci M, Ramieri A, Lenzi J, Fontana E, Martini S. Pseudo-aneurysm of a lumbar artery after flexion-distraction injury of the thoraco-lumbar spine and surgical realignment: rupture treated by endovascular embolization. *Spine (Phila Pa 1976)*. 2008;33:E81–E84.
18. Wang XB, Yang M, Li J, Xiong GZ, Lu C, Lü GH. Thoracolumbar fracture dislocations treated by posterior reduction, interbody fusion and segmental instrumentation. *Indian J Orthop*. 2014;48:568–573.

Disclosures and COI: The authors received no funding for this study and report no conflicts of interest.

Corresponding Author: Jacinto Mata-Gómez, Servicio de Neurocirugía. Complejo Hospitalario Universitario de Badajoz, Avda de Elvas s/n. 06080. Badajoz, España. Phone: +34-629973312; Email: jacinto.mata@gmail.com.

Published 11 February 2021

This manuscript is generously published free of charge by ISASS, the International Society for the Advancement of Spine Surgery. Copyright © 2020 ISASS. To see more or order reprints or permissions, see <http://ijssurgery.com>.