INTERNATIONAL JOURNAL of SPINE SURGERY

Adult Congenital Spine Deformity: Clinical Features and Motivations for Surgical Treatment

Javier Pizones, Lucía Moreno-Manzanaro, Alba Vila-Casademunt, Nicomedes Fernández-Baíllo, José Sánchez-Márquez, Gloria Talavera, Ibrahim Obeid, Ahmet Alanay, Frank Kleinstück, Ferran Pellisé and Francisco Javier Sánchez Perez-Grueso

Int J Spine Surg 2021, 15 (6) 1238-1245
doi: https://doi.org/10.14444/8157
http://ijssurgery.com/content/15/6/1238

This information is current as of April 20, 2024.

Email Alerts Receive free email-alerts when new articles cite this article. Sign up at: http://ijssurgery.com/alerts

The International Journal of Spine Surgery
2397 Waterbury Circle, Suite 1,
Aurora, IL 60504, Phone: +1-630-375-1432
© 2021 ISASS. All Rights Reserved.
Downloaded from http://ijssurgery.com/ by guest on April 20, 2024

International Journal of Spine Surgery, Vol. 15, No. 6, 2022, pp. 1238–1245
https://doi.org/10.14444/8157
© International Society for the Advancement of Spine Surgery

Adult Congenital Spine Deformity: Clinical Features and Motivations for Surgical Treatment

JAVIER PIZONES, MD, PHD[1]; LUCÍA MORENO-MANZANARO, BA[1]; ALBA VILA-CASADEMUNT, MSC[2]; NICOMEDES FERNÁNDEZ-BAÍLLO, MD[1]; JOSÉ SÁNCHEZ-MÁRQUEZ, MD, PHD[1]; GLORIA TALAVERA, MD[1]; IBRAHIM OBEID, MD[3]; AHMET ALANAY, MD, PHD[4]; FRANK KLEINSTÜCK, MD[5]; FERRAN PELLISÉ, MD, PHD[6]; FRANCISCO JAVIER SÁNCHEZ PEREZ-GRUESO, MD[1]; ON BEHALF OF THE ESSG (EUROPEAN SPINE STUDY GROUP)

[1]Spine Unit, Department of Orthopedic Surgery, Hospital Universitario La Paz, Madrid, Spain; [2]Spine Research Unit, Vall d'Hebron Institute of Research, Barcelona, Spain; [3]Spine Surgery Unit, Pellegrin University Hospital, Bordeaux, France; [4]Department of Orthopedics and Traumatology, Acibadem Mehmet Ali Aydinlar University, Istanbul, Turkey; [5]Department of Orthopedics, Schulthess Klinik, Zurich, Switzerland; [6]Spine Surgery Unit, Hospital Universitario Vall d'Hebron, Barcelona, Spain

ABSTRACT

Background: There is scarce information available about adult congenital spine deformity (ACSD) in the literature, especially its impact after the pediatric age. The aim was to define ACSD characteristics and to establish the drivers for surgical intervention.

Methods: Cross-sectional study of data collected in an adult deformity multicenter database. Only ACSD patients were included. Demographic and radiographic data, as well as patient-reported outcome measures, were assessed. Conservatively (C) vs surgically (S) treated patients were compared using Student *t* test, χ^2, and Mann-Whitney *U* test.

Results: Fifty-two patients were included. They were young adults ($x = 37.7$ years), mostly female (71%). Among them, 60% had single hemivertebrae (HV), 35% had multiple HV, and 5% had segmentation defects. Also, 75% had mainly coronal deformity (Cobb 62.5° ± 29.6) and 25% had sagittal deformity.

Mean Oswestry Disability Index (ODI) was 29.6% ± 17 and mean Scoliosis Research Society 22-item survey (SRS-22) total score was 3.2 ± 0.8. Of note, mean SRS-22 self-image score was 2.8 ± 0.9 and 36-item Short Form Health Survey (SF-36) physical function score was 40.9 ± 11.

Thirty patients were treated conservatively (C), whereas 22 patients underwent surgery (S). No differences were found regarding age, type or location of the deformity, comorbidities, or radiographic parameters. Operated patients had worse Core Outcome Measurement Index (COMI) back scores (C: 3.8 ± 2.4 vs S: 6.7 ± 2.4; $P = 0.004$); worse SRS-22 self-image (C: 3 ± 0.9 vs S: 2.5 ± 0.9; $P = 0.047$), and SRS-22 total scores (C: 3.4 ± 0.8 vs S: 2.9 ± 0.7; $P = 0.01$); worse SF-36 physical component summary (C: 43.3 ± 10.8 vs S: 36.7 ± 10.4; $P = 0.048$); and worse SF-36 physical role, function, and social function.

Conclusion: Adult congenital deformity patients were mainly female young adults, with formation defects (HV), worried about their image and presenting some degree of functional impairment and pain. These symptoms were the essential drivers for surgery, rather than the radiographic deformity itself.

Clinical Relevance: One of the few studies describing the characteristics and clinical concerns of patients with congenital spinal deformities.

Level of Evidence: 3.

Special Categories

Keywords: congenital adult scoliosis, adult hemivertebrae, congenital scoliosis treatment, hemivertebrae surgery, motivations for surgery

INTRODUCTION

Congenital scoliosis comprises a variety of spine skeletal deformities affecting the coronal and/or sagittal plane. There are three categories in the classification, that is, defects of formation, defects of segmentation, or mixed defects.[1] This pathology is usually discovered in the early stages of life and should be followed closely during growth. Treatment depends on the morphology, location, and progression of the specific malformation.[2,3] Clinical observation is advised at the beginning, and surgical treatment is reserved for those cases with progression or/and high-magnitude deformity.[4,5]

Despite all the available knowledge on this condition, literature mainly applies to the pediatric population. In the past decade, many studies have described general adult spinal deformity (ASD) characteristics, management options, and surgical outcomes and complications. However, the information available exclusively on adult

Downloaded from http://ijssurgery.com/ by guest on April 20, 2024

congenital deformity is limited. There is still space for improvement in the understanding of this disorder and how it affects the adult population for both neglected and treated patients. We still have a lack of knowledge regarding its impact after the pediatric age.

The aim of our study was to define the characteristics and clinical features of adult congenital spine deformity (ACSD) patients seeking specialized medical attention, and to establish their motivations and drivers for surgical treatment.

MATERIAL AND METHODS

We conducted a cross-sectional study of baseline data collected at the time of enrollment in an adult international multicenter deformity database (European Spine Study Group). The database includes patients aged 18 years or older, having a coronal spinal curvature ≥20° or sagittal vertical axis (SVA) >5 cm, or a pelvic tilt >25° or thoracic kyphosis >60°. Institutional review board's approval was obtained at each participating institution prior to patient enrollment into the database.

The database was searched to identify those patients with adult congenital deformity, defined as having defects of formation, segmentation, or mixed defects, including any kind of previous treatment (neglected, conservative, or surgical). All other adult spinal deformity etiologies were excluded.

Demographic parameters were collected: age, sex, height, weight, and body mass index (BMI). Data such as ASA classification, comorbidities, previous surgery, deformity type, and deformity location were also assessed.

Several coronal and sagittal radiological preoperative parameters were evaluated, such as main Cobb, coronal balance, SVA, Global Tilt (GT), T10-L2 kyphosis, L1-S1 lumbar lordosis (LL), pelvic incidence (PI), PI-LL mismatch, and total deformity angular ratio (T-DAR: calculated as the Cobb angle of the maximum scoliosis and kyphosis curve divided by the number of vertebral levels involved).

Clinical symptoms and quality of life data were gathered to assess the sample using the following patient-reported outcome measures (PROM): Numerical Rating Scale (NRS) back pain (0–10) and NRS leg pain (0–10); Core Outcome Measurement Index (COMI) Back and COMI Neck; Oswestry Disability Index (ODI; %); and to measure specific and general quality of life, we used the Scoliosis Research Society 22-item (SRS-22) and the 36-item Short Form Health Survey (SF-36) questionnaires.

Two groups were made depending on the treatment that followed our decision-making, after our clinical evaluation (regardless of their previous history and management) conservative (C) and surgical (S).

Statistical Methods

Statistical analysis was carried out using the SPSS software (version 20; SAS Institute Inc., Cary, NC, USA). Normal distribution was analyzed with Kolmogorov–Smirnov test. The distribution of variables is given as mean and standard deviation, median and interquartile range, or percentages as appropriate. Comparisons between surgical and conservative cohorts were performed using a two-tailed independent t test or Mann-Whitney U test, the Fisher exact test, and χ^2 statistics as appropriate, with a significance level of 5% ($P < 0.05$).

RESULTS

From the 1932 adult patients in our database by the time of data extraction, 52 met inclusion criteria for having ACSD.

Analyzing the whole cohort, we found an average age of 37.7 ± 12.7 years old, mostly female (71%). Following previous classification,[6] 60% of the patients presented a single hemivertebrae (HV), 35% had multiple HV, and 5% had segmentation defects. Most of the patients (75%) had mainly coronal deformity (main Cobb 62.5° ± 29.6), and the rest (25%) suffered sagittal deformity—mainly lumbar or thoracolumbar (TL)—with the following average parameters: TL kyphosis 19.8° ± 33, GT 20.3° ± 15, SVA 17.5 mm ± 51, and PI-LL mismatch –2° ± 24.8. Total DAR was 9.5 ± 4.7. From all of these patients, 32.7% had undergone previous surgery (before database enrollment) addressing the congenital anomalies during their pediatric age. We found 8 patients with in situ fusion without instrumentation, 6 with posterior instrumented long fusions, and 3 patients with short posterior instrumented fusions.

Describing PROM scores of the whole sample, we found a mean NRS back pain of 5.5 ± 3, a mean COMI back of 4.9 ± 2.8, mean ODI score of 29.6% ± 17, mean SRS-22 total score of 3.2 ± 0.8, a mean SF-36 physical component summary of 40.9 ± 11, and mental component summary of 44.7 ± 11. Worth noticing was low average self-image score (SRS-22 SI = 2.8 ± 0.9).

From these 52 patients, we decided to continue conservative treatment for 30 patients (conservative group: C), whereas we decided to operate on 22 patients

Downloaded from http://ijssurgery.com/ by guest on April 20, 2024

Table 1. Demographic and radiographic comparisons between patients treated conservatively and those undergoing surgery.

Preoperative Data	Surgical	Conservative	Student $t/\chi 2$
Demographic parameters			
Age, y	36.5 ± 10.6	38.6 ± 14.2	0.55
Gender, F/M	86.4%/13.6%	60%/40%	0.038a
Height, cm	151.7 ± 10.1	157.9 ± 11.6	0.07
Weight, kg	59.2 ± 14.5	65.9 ± 16	0.15
BMI	25.9 ± 4.8	26.4 ± 5	0.76
Comorbidities	40.9%	33.3%	0.121
Previous surgery	45.5%	23.3%	0.093
Deformity type 1			0.746
Scoliosis	77.3%	73.3%	
Kyphosis	22.7%	26.7%	
Deformity type 2			0.811
Simple HV	64%	56%	
Multiple HV	30%	39%	
Segment defects	6%	5%	
Deformity Location			0.166
Proximal thoracic	4.5%	16.7%	
Main thoracic	36.4%	46.7%	
Thoracolumbar	31.8%	10%	
Lumbar	27.3%	26.7%	
Radiographic parameters			
Main Cobb, °	59.3 ± 33.4	64.8 ± 27.1	0.52
Coronal balance, mm	−9.3 ± 36.9	−0.8 ± 26.3	0.42
SVA, mm	14.2 ± 42.8	19.6 ± 56.1	0.73
Global tilt, °	22.9 ± 15.3	18.6 ± 14.6	0.36
T10-L2 kyphosis, °	13.7 ± 31.2	25.4 ± 35	0.24
PI-LL mismatch, °	−0.7 ± 26	−2.9 ± 24.3	0.765
LL, °	49.2 ± 27.4	57.3 ± 23.6	0.265
PI, °	47.8 ± 13.9	51.2 ± 16.5	0.458
T-DAR	8.9 ± 4.8	9.9 ± 4.6	0.464

Data presented as mean ± SD and percentages.
[a]Statistically significant.
Abbreviations: BMI, body mass index; HV, hemivertebrae; LL, lumbar lordosis; PI, pelvic incidence; SVA, sagittal vertical axis; T-DAR, total deformity angular ratio.

(surgical group: S). These two groups were compared to analyze factors influencing surgical decision.

Between groups, only differences in gender were found to be statistically significant. The rest of the variables did not show significant differences: age, height or weight, BMI, comorbidities, type or location of the deformity, or any of the radiographic studied parameters (Table 1). However, statistical differences were found in several PROM scores as follows (Table 2).

Operated patients had worse COMI back scores (C: 3.8 ± 2.4 vs S: 6.7 ± 2.4; $P = 0.004$), but no statistical differences were found regarding NRS back or leg pain.

Although SRS-22 scores were worse in all domains for those undergoing surgical treatment, statistical differences were found for only SRS-22 self-image score (C: 3 ± 0.9 vs S: 2.5 ± 0.9; $P = 0.047$), SRS-22 subtotal score (C: 3.4 ± 0.8 vs S: 2.8 ± 0.7; $P = 0.022$), and SRS-22 Total scores (C: 3.4 ± 0.8 vs S: 2.9 ± 0.7; $P = 0.01$).

Surgical patients also demonstrated worse physical function scores measured with the SF-36 physical component summary (C: 43.3 ± 10.8 vs S: 36.7 ± 10.4; $P = 0.048$). SF-36 physical role, physical function, and social function were also worse (with mean values under 38 points) for patients in the surgical group ($P < 0.005$). In both the SF-36 physical and the SRS-22 self-image scores, differences between groups were higher than the minimal clinically important differences.[7,8]

DISCUSSION

Despite the wide volume of literature describing ASD in general, little attention has been directed toward congenital deformity. There is a need for information describing this population's characteristics and concerns, the type and magnitude of the deformity, the process of treatment decision-making, and their final motivations to undergo surgery.

Taking advantage of our large ASD multicenter database, we studied those patients seeking medical advice due to adult congenital deformity. Our aim was not to describe the rate of congenital pathology within our cohort, but to describe their characteristics to better understand this pathology. We found a cohort of young adult female patients, one-third of them consulted years after primary surgery, with high concern on image perception and carried some degree of functional impairment and local pain. Those having greater amount of these symptoms opted for further surgical treatment. Patients who were less symptomatic were more apt to choose nonsurgical treatment despite the magnitude of their deformity.

The true incidence of congenital deformities in the pediatric population is unknown, as some anomalies produce little deformity and go unrecognized. However, it has been estimated that in 8% of infants who present with scoliosis, the cause is a congenital malformation.[9] We encountered 52 adult patients seeking for consultation with congenital deformity in our database, accounting for 2.7% of all enrolled ASD patients at the time of data extraction. Although this is not a real photography of the true prevalence, it gives an idea of the small amount of patients consulting for this specific reason.

Patient's dissatisfaction was based in three main symptoms: mild back pain, some degree of functional impairment, and low self-image perception. All of them together affecting their quality of life. These symptoms are similar to those reported by young adult patients with noncongenital ASD,[10] which have been demonstrated to be worse compared to normative general population data.[11]

Downloaded from http://ijssurgery.com/ by guest on April 20, 2024

Table 2. PROMs comparisons between patients treated conservatively and those undergoing surgery.

	Surgical		Conservative			
Preoperative Data	**Mean ± SD**	**Median (IQR)**	**Mean ± SD**	**Median (IQR)**	**Student *t* test**	**Mann-Whitney *U* test**
PROMs						
NRS back pain	5.2 ± 3.2		5.6 ± 3		0.61	
NRS leg pain	3.6 ± 3.2	4 (0–6)	2.6 ± 3.3	0.5 (0–4.25)		0.233
COMI back	6.7 ± 2.4		3.8 ± 2.4		0.004a	
COMI neck	3.3 ± 2.1		2.6 ± 2.4		0.67	
ODI (%)	34.6 ± 19.2		26.9 ± 15.9		0.15	
SRS-22						
SRS-22 function	3.1 ± 0.8	3 (2.5–4)	3.6 ± 1	4 (3–4)		0.089
SRS-22 pain	2.9 ± 1.2		3.1 ± 1		0.56	
SRS-22 self-image	2.5 ± 0.9	2 (2–3)	3 ± 0.9	3 (2–4)		0.047a
	2.9 ± 1	3 (2–4)		3.5 (3–4)		
SRS-22 mental health			3.5 ± 0.8			0.083
SRS-22 satisfaction	3.2 ± 1.3 3.5	(2.25–4)	3.6 ± 1	4 (3–4)		0.533
SRS-22 subtotal	2.82 ± 0.7	3 (2–3)	3.4 ± 0.8	4 (3–4)		0.020a
SRS-22 total	2.9 ± 0.7	3 (2–3)	3.4 ± 0.8	4 (3–4)		0.014a
SF-36						
SF-36 function	38.6 ± 8.9		45.1±9.2		0.023a	
SF-36 physical role	33.7 ± 12.4		42.6 ± 12.8		0.026a	
SF-36 pain	38.3 ± 11.9		41 ± 10.4		0.43	
SF-36 vitality	46.5 ± 8		47.9 ± 9.4		0.59	
SF-36 social function	34.9 ± 8.5	37 (27–37)	43.7 ± 12.4	47 (32–57)		0.022a
SF-36 emotional role	40.9 ± 13		42.5 ± 11.3		0.67	
SF-36 mental health	43.8 ± 10.2		44.8 ± 9		0.72	
SF-36 general health	41.9 ± 10.4		43.2 ± 11.3		0.68	
SF-36 PCS	36.7 ± 10.4		43.3 ± 10.8		0.048a	
SF-36 MCS	44.2 ± 11.4		45.1 ± 10.9		0.79	

Parametric data presented as mean ± SD. Nonparametric data presented as median (IQR).
[a]Statistically significant.
Abbreviations: COMI, Core Outcome Measurement Index; IQR, interquartile range; MCS, mental component summary; NRS, Numerical Rating Scale; ODI, Oswestry Disability Index; PCS, physical component summary; PROM, patient-reported outcome measures; SF-36, 36-item Short Form Health Survey; SRS-22, Scoliosis Research Society 22-item questionaire.

Regarding the treatment that they followed, both the conservative and surgical groups were comparable in age, height, weight, and BMI. Female patients were more predominant in the surgical treatment branch. Although not significant, it is worth mentioning that having previous surgery during childhood tended to be a risk factor for undergoing further surgery in adulthood (Figure 1). The reason could be curve progression; a 15% rate of crankshaft phenomenon after posterior spinal arthrodesis for congenital scoliosis has been reported strongly associated with larger curves and earlier fusions.[12]

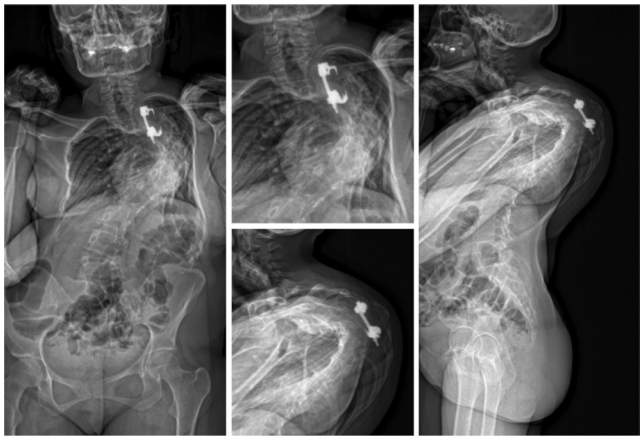

Figure 1. A 24-year-old woman with chronic pulmonary disease. She underwent previous surgery during childhood with a T4-T7 early short fusion due to hemivertebrae. Along the years, she developed a crankshaft phenomenon showing a residual Cobb angle of 100°. Patient-reported outcome measure scores were as follows: Numerical Rating Scale back, 5; Oswestry Disability Index, 27%; Scoliosis Research Society 22-item self-image, 2; and 36-item Short Form Health Survey physical component summary, 45. Surgical indication was established for a T6-T8 vertebral column resection with T2-L3 post instrumentation and added thoracoplasty.

Congenital defects appear in the early stages of life and are associated with other organ abnormalities, mainly cardiac, renal and neurologic, due to their single mesodermal origin.[13,14] It is interesting to note that in our cohort, one third of the patients suffered medical comorbidities, which might be potentially linked to the congenital deformity. The most frequent were chronic pulmonary disease, cardiac disease, hypertension, and depression/anxiety symptoms. The presence of these comorbidities did not seem to affect treatment decision-making (Figure 2).

The most common malformation seen in our patients were defects of formation, as single or multiple HV (Figure 3).[1,6,15] These anomalies were homogenously distributed between the thoracic and lumbar spine (Figure 4). Only a few patients suffered segmentation defects that were mostly affecting the lumbar spine producing angular segmental kyphosis, and the consequent loss of lumbar lordosis (Figure 5). Although we saw more conservatively treated patients having mostly thoracic deformity location, and greater amount of patients undergoing surgery with thoracolumbar defects, differences in curve location were not significant between treatment options. We suppose that patients with severe angular thoracic scoliosis, frequently associated with pulmonary disease, and higher neurological

Downloaded from http://ijssurgery.com/ by guest on April 20, 2024

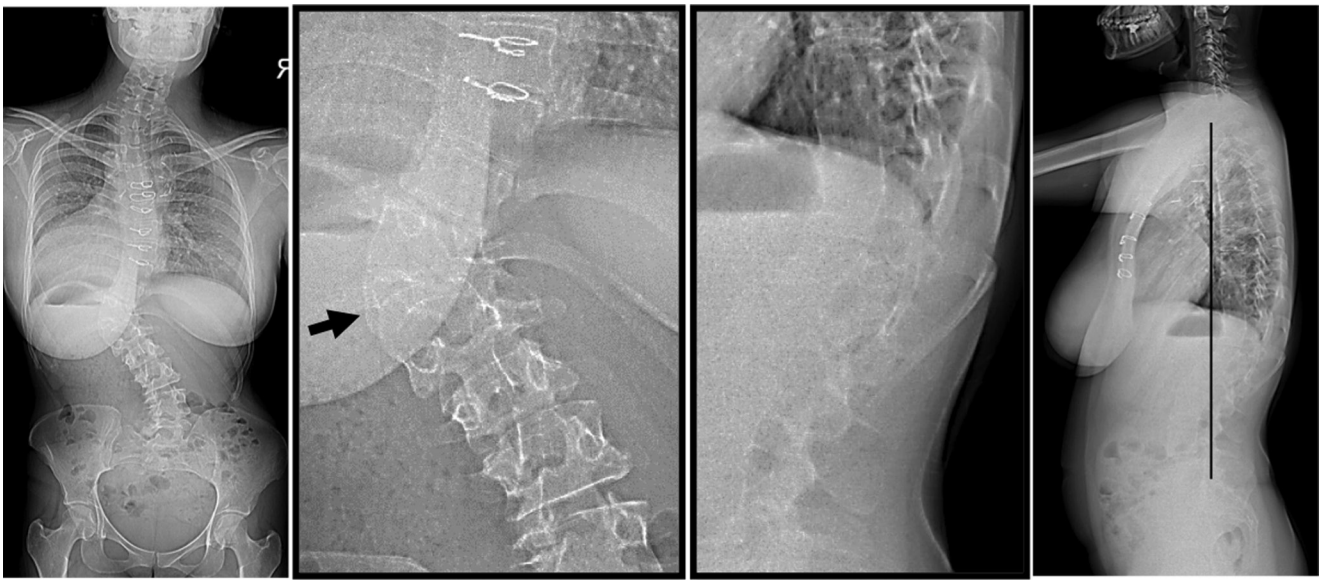

Figure 2. A 29-year-old woman with cardiopathy (previous cardiac surgery). She had a T12 hemivertebra producing a T10-L1 coronal curve with 67° Cobb angle, and a thoracolumbar rotational kyphosis with a sagittal T10-L2 of 47°, well aligned. Patient-reported outcome measures scores were as follows: Numerical Rating Scale back, 6; Core Outcome Measurement Index back, 6; Oswestry Disability Index, 29%; Scoliosis Research Society 22-item survey (SRS-22) pain, 2.8; SRS-22 self-image, 2.2; and 36-item Short Form Health Survey physical component summary, 41.3. Surgery was indicated and a T9-L3 posterior fusion with T12 asymmetric osteotomy was planned.

risk were less prone to undergo surgery. Whereas for thoracolumbar-lumbar deformities that usually exhibit more pain, less pulmonary disease, and less neurological risk, surgery is more easily indicated. Anyhow, none of these analyzed parameters seemed to influence treatment in our cohort.

Our overall cohort comprises of patients having high Cobb magnitude (over 60°) but good coronal balance. One-fourth of the patients suffered sagittal deformity mostly located at the thoracolumbar junction drawing an average segmental kyphosis of almost 20°. This was originated mainly by thoracolumbar rotational kyphosis either by HV located at the TL transition (Figure 2), or by double major curves with high lumbar component. Some of these sagittal deformities originated in lumbar

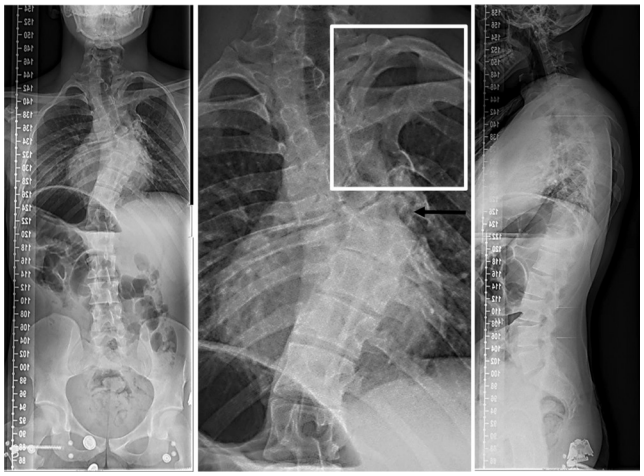

Figure 3. A 26-year-old man with chronic pulmonary disease. He suffered a T7 hemivertebra and ipsilateral T2-T5 rib fusion. Coronal Cobb angle from T1-T5 was 35° and from T5-T9 was 61°. Patient-reported outcome measure scores were as follows: Numerical Rating Scale back, 0; Core Outcome Measurement Index back, 2; Oswestry Disability Index, 2%; Scoliosis Research Society 22-item survey (SRS-22) pain, 5; SRS-22 self-image, 3.6; and 36-item Short Form Health Survey physical component summary, 58.8. He followed conservative treatment.

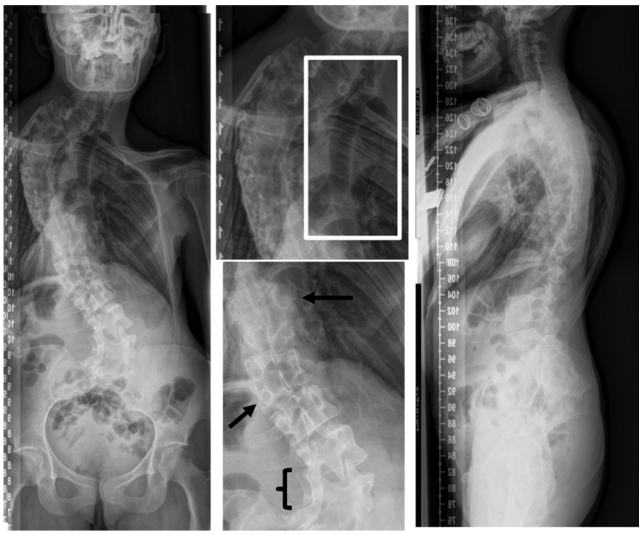

Figure 4. A 34-year-old woman with no comorbidities. Radiographs showed multiple anomalies: T10 right hemivertebra, L1 left hemivertebra, T4-T10 ribs fusions, and L4-L5 left bar. Coronal Cobb angles were T1-T9 73° and L3-L5 54°. Patient-reported outcome measure scores were as follows: Numerical Rating Scale back, 4; Core Outcome Measurement Index back, 3; Oswestry Disability Index, 18%; Scoliosis Research Society 22-item survey (SRS-22) pain, 3.2; SRS-22 self-image, 3.2; and 36-item Short Form Health Survey physical component summary, 42.7. Conservative treatment was indicated.

Downloaded from http://ijssurgery.com/ by guest on April 20, 2024

Figure 5. A 39-year-old woman without comorbidities. Radiographs showed multiple segmentation defects at T10-T11, L2-L3, and L4-L5 drawing a lumbar flat back with correct global sagittal alignment. Patient reported outcome measure scores were as follows: Numerical Rating Scale back, 9; Core Outcome Measurement Index back, 7; Oswestry Disability Index, 58%; Scoliosis Research Society 22-item survey (SRS-22) pain, 1.2; SRS-22 self-image, 3; and 36-item Short Form Health Survey physical component summary, 21. Cobb angle T12-L4 42°. Surgical treatment was proposed for an L4 PSO and T11-iliac instrumentation.

segmentation defects with segmental lordosis loss. However, as they were young adults able to compensate, sagittal balance was preserved (Figure 6). Interestingly, radiographic deformity was not a main driver for surgery. Neither magnitude, nor location, nor the type of deformity influenced decision-making. Although deformity thresholds define a big amount of our daily surgical indications in spinal deformity,[16] symptoms seemed to be more important for surgical indication. These symptoms are not necessarily directly related with the presence of relevant radiological findings (Figure 7).[17]

Figure 6. A 40-year-old woman with no comorbidities. She presented a T7-T10 right incarcerated hemivertebrae and contralateral bar, and an L4 hemivertebrae. Coronal T6-T12 Cobb angle was 90° and L1-L5 Cobb angle was 66°. Patient-reported outcome measure scores were as follows: Numerical Rating Scale back, 6; Oswestry Disability Index, 33%; Scoliosis Research Society 22-item survey (SRS-22) pain, 2; SRS-22 self-image, 3; and 36-item Short Form Health Survey physical component summary, 40. Pelvic parameters of pelvic incidence, 45°; sacral slope, 20°; and pelvic tilt, 25° were compensating but well balanced. She was planned for a T8 vertebral column resection, surrounding Smith-Peterson osteotomies and T2-Iliac posterior instrumentation.

Downloaded from http://ijssurgery.com/ by guest on April 20, 2024

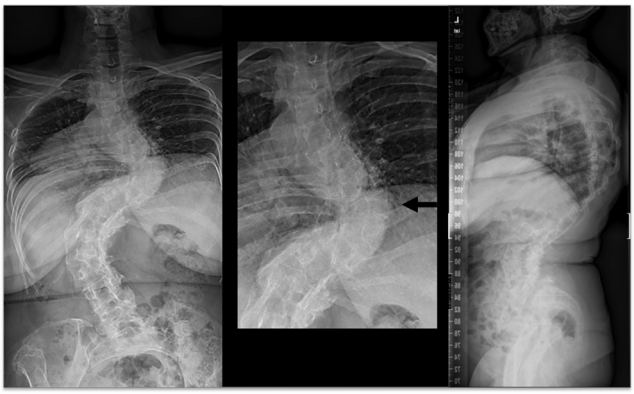

Figure 7. A 60-year-old woman with hypertension. She had a T8 hemivertebra with coronal T6-T10 Cobb angle of 87° and T11-L3 of 90°. Patient-reported outcome measure scores were as follows: Numerical Rating Scale back, 3; Oswestry Disability Index, 18%; Scoliosis Research Society 22-item survey (SRS-22) pain, 3.7; SRS-22 self-image, 1.2; and 36-item Short Form Health Survey physical component summary, 46.4. The patient followed conservative treatment.

The motivations to undergo surgery in our patients were based on dissatisfaction with body appearance, moderate back pain, and some degree of disability. Surgical indication was established on worse COMI back scores; worse function, social function, and physical role assessed by SF-36; and a clearly worse image perception measured with the SRS-22 self-image tool. Similar findings on back pain and quality of life impact have been found in patients selected for surgery due to noncongenital idiopathic or degenerative ASD.[18,19] Passias et al reported that ASD patients' conversion from conservative treatment to surgery depended on higher degrees of disability and worse PROMs, but similar spinal deformity.[20] Clinical motivations and not radiographic deformity, have also been found to drive surgery in the adult idiopathic scoliosis population.[21,22]

Compared to these[10,18,20—22] published data of patients undergoing surgery for adult deformity, we infer that congenital scoliosis patient's motivations for surgery are very similar to general ASD and to only idiopathic scoliosis patients. The older the cohort, the greater the back pain and disability. Mental health is very similar across cohorts, although congenital patients seem to suffer a little bit more on this domain. And remarkably self-image, which is the greatest concern no matter the age or the etiology of the scoliosis.

There are several limitations in this study. First, this is only a cross-sectional observation of patients seeking specialized medical attention. The reported data do not represent the entire adult population with congenital spinal deformity. Second, the small sample size. Despite our high-volume database, patients with congenital deformities were very few, at least fewer compared to pediatric rates as abovementioned. Some differences may have not reached statistical power due to small numbers. We had patients with previous surgery that could affect greatly their quality of life, thus conservatively treated or untreated patients were even lower in number. And finally, treatment decision-making on who to operate with complex spinal pathology and additional medical problems due to congenital mesodermal origin is not only based on measurable parameters such as radiographic deformity or magnitude of clinical symptoms. The interaction between surgeons and patients is essential, and sometimes even more important than measurable factors. We were unable to determine if the surgeon or the patient ultimately decided the treatment modality; we would assume it was a consensual decision. However, some patients may have refused operative treatment to avoid the risks of surgery, even when suffering important clinical symptoms or having big deformity. This uncountable variable cannot be assessed for statistical purposes.

CONCLUSION

Adult congenital deformity is still a concern after the pediatric age for some patients. Patients seeking medical advice for congenital scoliosis in our adult deformity database were mainly young female adults. Most of this cohort presented with single and multiple hemivertebrae, and only a few consulted due to defects of segmentation. Symptoms such as back pain, function impairment and especially self-image were the essential drivers for surgery, rather than the radiographic deformity itself.

ACKNOWLEDGEMENTS

This paper was presented at the GEER National meeting 2020

REFERENCES

1. Winter RB, Moe JH, Eilers VE. Congenital scoliosis a study of 234 patients treated and untreated. *The Journal of Bone & Joint Surgery*. 1968;50(1):1–15. doi:10.2106/00004623-196850010-00001

2. McMaster MJ, Singh H. Natural history of congenital kyphosis and kyphoscoliosis. A study of one hundred and twelve patients. *J Bone Joint Surg Am*. 1999;81(10):1367–1383. doi:10.2106/00004623-199910000-00002

3. Marks DS, Qaimkhani SA. The natural history of congenital scoliosis and kyphosis. *Spine*. 2009;34(17):1751–1755. doi:10.1097/BRS.0b013e3181af1caf

4. Leatherman KD, Dickson RA. Two-stage corrective surgery for congenital deformities of the spine. *J Bone Joint Surg Br*. 1979;61-B(3):324–328. doi:10.1302/0301-620X.61B3.479255

Downloaded from http://ijssurgery.com/ by guest on April 20, 2024

5. Ruf M, Harms J. Hemivertebra resection by a posterior approach: innovative operative technique and first results. *Spine*. 2002;27(10):1116–1123. doi:10.1097/00007632-200205150-00020

6. McMaster MJ, Ohtsuka K. The natural history of congenital scoliosis. A study of two hundred and fifty-one patients. *J Bone Joint Surg Am*. 1982;64(8):1128–1147. doi:10.2106/00004623-198264080-00003

7. Berven S, Baron M, Deviren V, Glassman S, Bridwell K, Verma K. The assessment of clinically significant differences in treating spinal deformity using the SRS questionnaire: what is the threshold of change that is meaningful to patients? *Int J Spine Surg*. 2019;13(2):153–157. doi:10.14444/6020

8. Carreon LY, Kelly MP, Crawford CH, et al. SRS-22R Minimum clinically important difference and substantial clinical benefit after adult lumbar scoliosis surgery. *Spine Deform*. 2018;6(1):79–83. doi:10.1016/j.jspd.2017.05.006

9. Feldman DS, Schachter AK, Alfonso D, Lonner BS, Razi AE. Congenital scoliosis. Errico TJ, Lonner BS, Moulton AW, eds. *Surgical Management of Spinal Deformities*. ; 2009:129–141. doi:10.1016/B978-141603372-1.50012-3

10. Bess S, Boachie-Adjei O, Burton D, et al. Pain and disability determine treatment modality for older patients with adult scoliosis, while deformity guides treatment for younger patients. *Spine*. 2009;34(20):2186–2190. doi:10.1097/BRS.0b013e3181b05146

11. Bess S, Line B, Fu K-M, et al. The health impact of symptomatic adult spinal deformity: comparison of deformity types to United States population norms and chronic diseases. *Spine*. 2016;41(3):224–233. doi:10.1097/BRS.0000000000001202

12. Kesling KL, Lonstein JE, Denis F, et al. The crankshaft phenomenon after posterior spinal arthrodesis for congenital scoliosis: a review of 54 patients. *Spine*. 2003;28(3):267–271. doi:10.1097/01.BRS.0000042252.25531.A4

13. Chan G, Dormans JP. Update on congenital spinal deformities: preoperative evaluation. *Spine*. 2009;34(17):1766–1774. doi:10.1097/BRS.0b013e3181ab62d8

14. Hensinger RN. Congenital scoliosis: etiology and associations. *Spine*. 2009;34(17):1745–1750. doi:10.1097/BRS.0b013e3181abf69e

15. Kawakami N, Tsuji T, Imagama S, et al. Classification of congenital scoliosis and kyphosis: a new approach to the three-dimensional classification for progressive vertebral anomalies requiring operative treatment. *Spine*. 2009;34(17):1756–1765. doi:10.1097/BRS.0b013e3181ac0045

16. Weinstein SL, Zavala DC, Ponseti IV. Idiopathic scoliosis: long-term follow-up and prognosis in untreated patients. *J Bone Joint Surg Am*. 1981;63(5):702–712. doi:10.2106/00004623-198163050-00003

17. Sánchez-Mariscal F, Gomez-Rice A, Izquierdo E, Pizones J, Zúñiga L, Alvarez-González P. Correlation of radiographic and functional measurements in patients who underwent primary scoliosis surgery in adult age. *Spine*. 2012;37(7):592–598. doi:10.1097/BRS.0b013e318227336a

18. Glassman SD, Schwab FJ, Bridwell KH, Ondra SL, Berven S, Lenke LG. The selection of operative versus nonoperative treatment in patients with adult scoliosis. *Spine*. 2007;32(1):93–97. doi:10.1097/01.brs.0000251022.18847.77

19. Neuman BJ, Baldus C, Zebala LP, et al. Patient factors that influence decision making: randomization versus observational nonoperative versus observational operative treatment for adult symptomatic lumbar scoliosis. *Spine*. 2016;41(6):E349-58. doi:10.1097/BRS.0000000000001222

20. Passias PG, Jalai CM, Line BG, et al. Patient profiling can identify patients with adult spinal deformity (ASD) at risk for conversion from nonoperative to surgical treatment: initial steps to reduce ineffective ASD management. *Spine J*. 2018;18(2):234–244. doi:10.1016/j.spinee.2017.06.044

21. Pizones J, Martin-Buitrago MP, Sánchez Perez-Grueso FJ, et al. Untreated thoracic curve in adult idiopathic scoliosis: What are patients' concerns? *Spine Deform*. 2016;4(6):439–445. doi:10.1016/j.jspd.2016.05.004

22. Pizones J, Pérez Martin-Buitrago M, Perez-Grueso FJS, et al. Function and clinical symptoms are the main factors that motivate thoracolumbar adult scoliosis patients to pursue surgery. *Spine*. 2017;42(1):E31–E36. doi:10.1097/BRS.0000000000001694

Funding: A Johnson and Johnson DePuy-Synthes Spine and Medtronic research grant was received in partial support of this work.

Declaration of Conflicting Interests: The authors report no conflicting interests related to this article.

Patient Consent for Publication: All patients gave their informed consent in participating in the study and publication of the results

Ethics Approval: This study has IRB approval/Research Ethics Committee for each site. The study procedures were in accordance with the ethical standards of the responsible committee on human experimentation (institutional and national) and with the Helsinki Declaration of 1975, as revised in 2000.

Corresponding Author: Javier Pizones, Department of Orthopedic Surgery, Hospital La Paz, Paseo de la Castellana 261, 28046, Madrid, Spain; javierpizones@gmail.com

Published 24 January 2022

This manuscript is generously published free of charge by ISASS, the International Society for the Advancement of Spine Surgery. Copyright © 2021 ISASS. To see more or order reprints or permissions, see http://ijssurgery.com.

Downloaded from http://ijssurgery.com/ by guest on April 20, 2024