

Lumbar Dynamic Stabilization With 2-Stage Surgery: Early Results

Ali Fahir Özer, Ahmet Tulgar Basak, Muhammet Arif Özbek, Mehdi Hekimoglu, Ahmet Levent Aydin, Özkan Ates, Caner Günerbüyük, Turgut Akgül, Mehdi Sasani and Tunç Öktenoglu

Int J Spine Surg 2022, 16 (4) 638-645

doi: <https://doi.org/10.14444/8306>

<https://www.ijssurgery.com/content/16/4/638>

This information is current as of May 1, 2025.

Email Alerts Receive free email-alerts when new articles cite this article. Sign up at:
<http://ijssurgery.com/alerts>

Lumbar Dynamic Stabilization With 2-Stage Surgery: Early Results

ALI FAHIR ÖZER, MD^{1,2}; AHMET TULGAR BAŞAK, MD²; MUHAMMET ARIF ÖZBEK, MD³;
MEHDI HEKIMOĞLU, MD²; AHMET LEVENT AYDIN, MD¹; ÖZKAN ATEŞ, MD¹; CANER GÜNERBÜYÜK, MD⁴;
TURGUT AKGÜL, MD⁴; MEHDI SASANI, MD^{1,2}; AND TUNÇ ÖKTENOĞLU, MD^{1,2}

¹Neurosurgery Department, Koc University School of Medicine, Istanbul, Turkey; ²Neurosurgery Department, American Hospital, Istanbul, Turkey; ³Neurosurgery Department, Medipol University, Istanbul, Turkey; ⁴Orthopaedics Department, Koc University School of Medicine, Istanbul, Turkey

ABSTRACT

Background: Screw loosening, which is a major problem in dynamic systems, can be easily overcome with 2-stage surgery. In this article, the clinical and radiological results of patients undergoing dynamic stabilization with a Dynesys device in 2 stages are discussed.

Methods: A total of 10 male and 13 female adult patients were included in this single-center retrospective study conducted between 2018 and 2021. The mean age of the patients was 65.6 years. All of the patients had pain complaints that affected their daily lives. Bone density *T* scores were determined with the dual-energy x-ray absorptiometry method before patients were admitted for surgery. In the first surgery, Dynesys system pedicle screws were inserted. After 6 months of osteointegration, Dynesys system spacers and elastic bandages were placed. Preoperative, early postoperative, and late postoperative visual analog pain scale (VAS) scores and Oswestry Disability Index (ODI) scores were determined and statistically compared.

Results: Patients were followed for an average of 30 months. Complications and recurrence were not observed. Neurological deficits were not observed after patients recovered from anesthesia. Significant improvement was observed in the ODI and VAS parameters in the preoperative (ODI: 66.2%, VAS: 7.8), early postoperative (ODI: 20.3%, VAS: 2.4), and late postoperative (ODI: 6.8% and VAS: 1.1) periods. Symptomatic improvement was seen in all patients. No screw breakage or loosening was detected by radiological evaluation in any of the patients during the 2-year follow-up period.

Conclusions: In our experience, the insufficiency of the proximal and distal end screws is eliminated when 2 stages of dynamic system stabilizations are completed after osteointegration of the screws.

Level of Evidence: 4.

Lumbar Spine

Keywords: dynamic stabilization, dynesys, osteointegration, 2-stage surgery

INTRODUCTION

The most critical aspect of dynamic stabilization is screw loosening. This problem becomes more serious, especially as we age and the risk of pathological conditions increases.^{1,2} Dynamic stabilization is not the same as acute instability surgery. It is ideal to perform dynamic stabilization in patients with slow developing instability and without fixed spinal balancing disorders. In dynamic stabilizations applied to patients with single-level pathologies, the results are acceptable.³ However, as the pathological risk increases, the problem of screw loosening arises in particular.⁴ In older patients, decreased bone quality, increased body mass index, and muscle atrophy associated with fatty degeneration cause an increase in the load on the instrument, and screw loosening develops easily.

To solve this problem, if patients have an unstable pathology that develops slowly at more than a single level, patients do not have significant neurological deficits, and

patients can tolerate pain, dynamic stabilization should be performed in 2 stages. While performing 2-stage surgery in dynamic systems, we were impressed by the implant technology used in dentistry. When we look at the literature, it is expected that the implant would be placed on the tooth first, and if the osteointegration process occurs early, within 3 to 6 months, the tooth would be placed on the implant after 6 months and would be ready for loading. Osteointegration occurs more quickly in long bone fractures when connections are made with plates and screws.⁵⁻⁸

The surface properties of the material used in osteointegration are important; in this regard, titanium alloys and stainless steel implants have been shown to be suitable for the development of osteointegration.^{5,8} Dynamic stabilization was performed using the Dynesys system (Zimmer Spine, Warsaw, IN). Screws are medical titanium alloys and are very suitable for osteointegration. The Dynesys system was described by Dubois in 1994. The system consists of pedicle screws and a polyester cord polyethylene terephthalate

(Sulene-PET) that combines them. In addition, the polycarbonate urethane (Sulene-PCU) cylindrical spacers used in this system prevent excessive compression.⁵ In the first surgery, pedicle screws were inserted percutaneously, and after osteointegration was completed (on average 6 months after the first surgery), polyester cords with polycarbonate urethane cylindrical spacers were placed on the screws and fixed properly.

MATERIALS AND METHODS

Between 2018 and 2021, 10 male and 13 female patients were included in this single-center retrospective study. The mean age of the patients was 65.6 years. All of the patients had complaints of pain that affected their daily lives. Institutional review board approval was not required for the retrospective study. All patients provided consent to be included in the study.

Patients who were operated on in 2 stages should have clinical characteristics that would be relevant to the osteointegration process. The common symptoms in all of these patients were low back pain, inability to stand for long periods, and inability to walk long distances. The common symptom in painful discs is that while patients continue their normal daily lives in a pain-free period, severe low back pain often comes with a moderate load and the patient becomes unable to move. This occurrence is mostly seen in 1- or 2-level discs at the beginning of degeneration with a disc height close to normal. In patients with chronic degenerative disc disease with reduced height, the symptomatology classically includes no pain when lying down but

pain that occurs immediately when the patient stands up or walks.

Diagnosis of Patients

Spinal lumbar stenosis was diagnosed in 9 patients, degenerative spondylolisthesis was diagnosed in 4 patients, painful degenerative disc disease was diagnosed in 4 patients, painful degenerative spondylolysis was diagnosed in 2 patients, and spinal instability due to previous discectomy surgeries was diagnosed in 4 patients. Bone density *T* scores were determined by performing bone scintigraphy with the dual-energy x-ray absorptiometry method before the patients were admitted to surgery (Table 1). In the first surgery, Dynesys system pedicle screws were inserted into the patients. After an average of 6 months of waiting for osteointegration that was then confirmed by computed tomography (CT), Dynesys system spacers and elastic bandages were placed in the patients. Preoperative, early postoperative (after the completion of the second-stage surgery), and late postoperative (2 years after the completion of the second-stage surgery) visual analog pain scale (VAS) scores and Oswestry Disability Index (ODI) scores were determined and compared in a statistical analysis (Table 2).

Surgical Technique

Dynesys dynamic stabilization was performed in patients. The Dynesys system was described by Dubois in 1994. The system consists of pedicle screws and a polyester cord polyethylene terephthalate (Sulene-PET) that

Table 1. Patients' demographic information, diagnosis, and bone-density scores.

Patient No	Age	Gender	Level	Type	Stabilization Levels	Bone Density <i>T</i> Scores
1	61	M	L4	Degenerative disc disease	L3-L5	-3.56
2	74	M	L2 and L4	Spinal stenosis	L2-L5	-2.86
3	58	M	L3	Spinal instability (operated)	L2-L5	-2.57
4	67	F	L3 and L4	Spinal stenosis	L2-iliac	-3.08
5	60	F	L4	Degenerative disc disease	L3-L5	-2.88
6	62	M	L4	Spondylolisthesis	L3-L5	-2.76
7	66	F	L2	Spondylolysis	T12-iliac	-2.69
8	72	M	L3 and L4	Spinal stenosis	L2-S1	-3.08
9	75	F	L4	Spondylolisthesis	L3-S1	-3.11
10	69	M	L5	Spinal instability (operated)	L4-S1	-2.73
11	56	F	L2	Spondylolysis	T12-S1	-2.81
12	65	F	L3	Degenerative disc disease	T10-S1	-2.95
13	64	F	L4 and L5	Spinal stenosis	T10-S1	-2.66
14	62	F	L4	Spinal instability (operated)	L3-S1	-2.82
15	60	M	L4	Degenerative disc disease	L2-S1	-2.63
16	69	F	L4 and L5	Spinal stenosis	T10-iliac	-2.58
17	63	M	L5 and S1	Spondylolisthesis	L4-iliac	-2.51
18	62	F	L4	Spinal instability (operated)	L3-L5	-2.59
19	76	F	L3 and L4	Spinal stenosis	L2-iliac	-3.24
20	72	M	L4	Spondylolisthesis	L3-L5	-3.41
21	58	F	L2	Spinal stenosis	L1-L3	-2.62
22	60	F	L5	Spinal stenosis	L4-S1	-2.54
23	77	M	L4 and L5	Spinal stenosis	L4-S1	-3.02

Table 2. Patients' preoperative, postoperative, and late postoperative VAS and ODI scores.

Patient No	VAS Preoperative	VAS Early Postoperative	VAS 2-Y Postoperative	ODI Preoperative	ODI Early Postoperative	ODI 2-Y Postoperative
1	8	2	1	68%	17%	3%
2	9	3	1	80%	26%	7%
3	10	3	2	84%	32%	9%
4	8	2	1	64%	14%	6%
5	7	1	0	44%	6%	0%
6	7	2	1	54%	12%	5%
7	7	2	0	52%	11%	0%
8	9	3	0	74%	28%	8%
9	9	3	2	76%	24%	6%
10	8	2	1	70%	22%	6%
11	8	2	0	72%	19%	1%
12	8	3	1	80%	27%	4%
13	7	1	0	48%	9%	0%
14	7	2	1	66%	17%	5%
15	7	2	0	66%	17%	4%
16	8	3	2	76%	23%	7%
17	9	7	7	74%	68%	62%
18	7	2	1	62%	18%	6%
19	7	2	1	64%	16%	4%
20	7	2	1	58%	14%	3%
21	7	2	1	56%	13%	2%
22	8	3	1	66%	17%	6%
23	8	2	1	70%	17%	4%

Abbreviations: ODI, Oswestry Disability Index; VAS, visual analog scale.

combines them. In addition, the polycarbonate urethane (Sulene-PCU) cylindrical spacers used in this system prevented excessive compression.⁹ In flexion, movement was controlled by tension on the band; in extension, spacers allowed a limited amount of extension. Compared to other pure band-like systems, the posterior provided protection against compression in the annulus and provided symmetrical distribution of painful load. In our study, screws were inserted percutaneously,

and patients were discharged (Figures 1–4). Patients were evaluated with CT after an average of 6 months (Figure 5). After it was determined that the osteointegration of screws was complete, if necessary, primary pathologies were fixed, and then the Dynesys system's rods were placed and connected in the patients (Figures 6 and 7).

It is necessary to restore impaired lumbar lordosis in patients. To bring the forward slipped sagittal vertical axis back to the sacrum, patients with flat back deformity were placed in a lordotic position on the table and controlled with a C-arm. If necessary, iliac long segment dynamic system (Dynesys) stabilization was performed to ensure the continuity of the lordotic position.

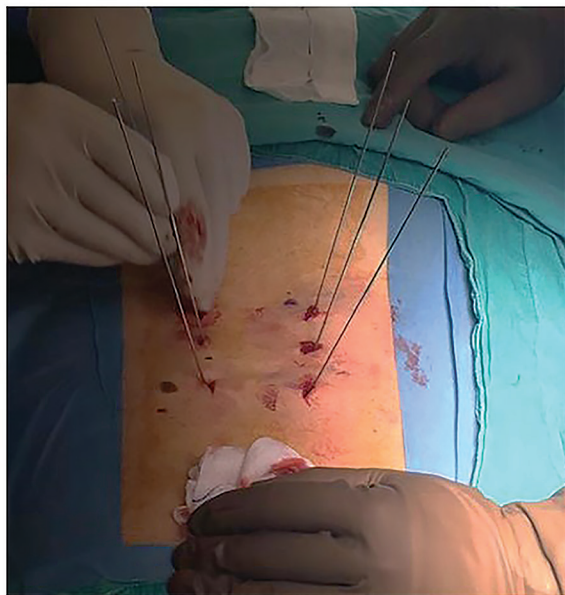


Figure 1. Small incisions were made on the skin, and screws were inserted percutaneously through small holes.

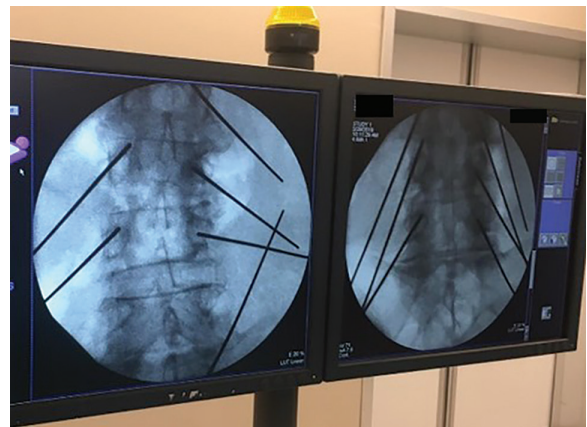

Figure 2. Appearance of guidewires in the C-arm.

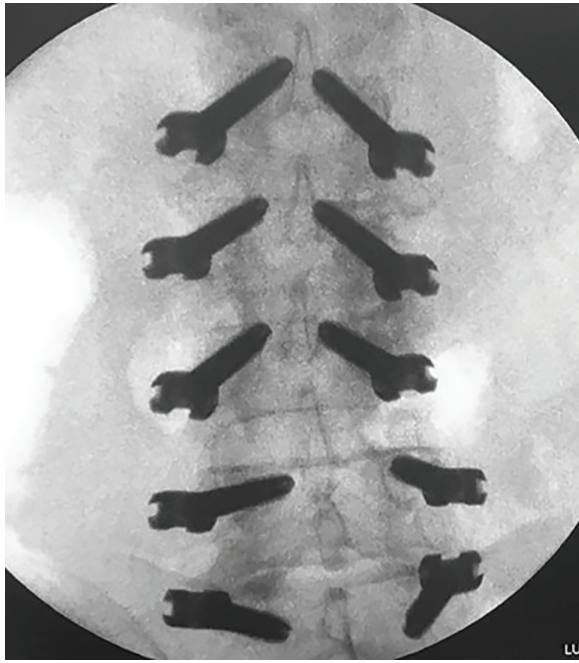


Figure 3. Anteroposterior image of the screws placed on the spine over the guidewires.

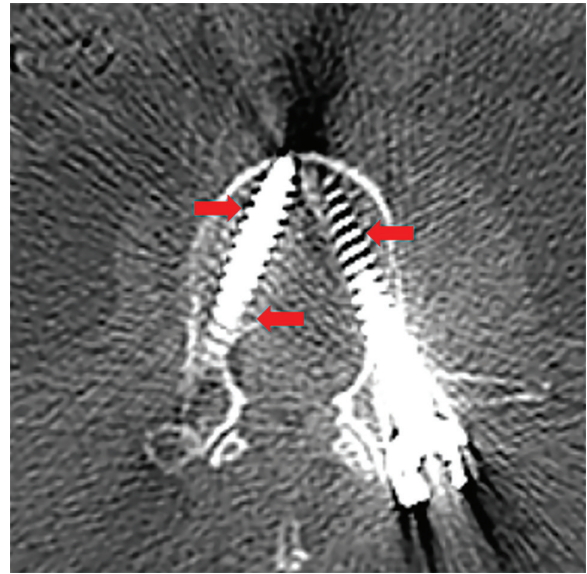


Figure 5. Six months after surgery, osteointegration of the screws to the bone was observed on computed tomography images. In the entire vertebral body, the bone tissue was observed to be populated between the screw threads (red arrows).

Patient Follow-Up

After the operation, imaging examinations (CT and x-ray imaging) were performed, and VAS and ODI evaluations were repeated. At monthly follow-up, the radiological examinations were repeated and osteointegration of the screws was tested. Patients underwent clinical follow-ups using VAS and ODI tests preoperatively and postoperatively (after system rods and 2 years after the completion of the second-stage surgery).

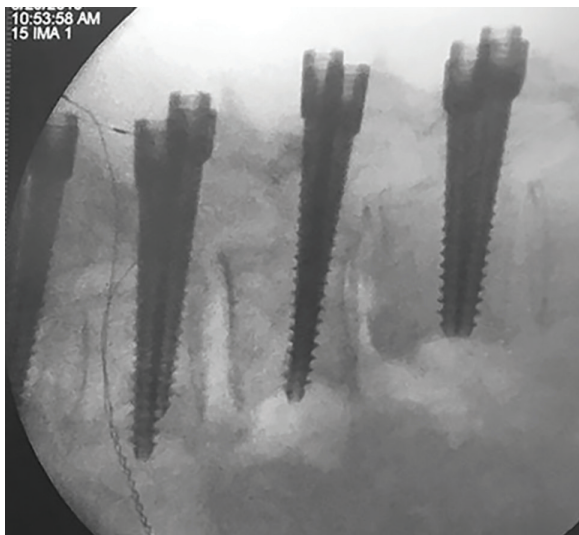


Figure 4. Lateral image of the screws placed on the spine over the guidewires.

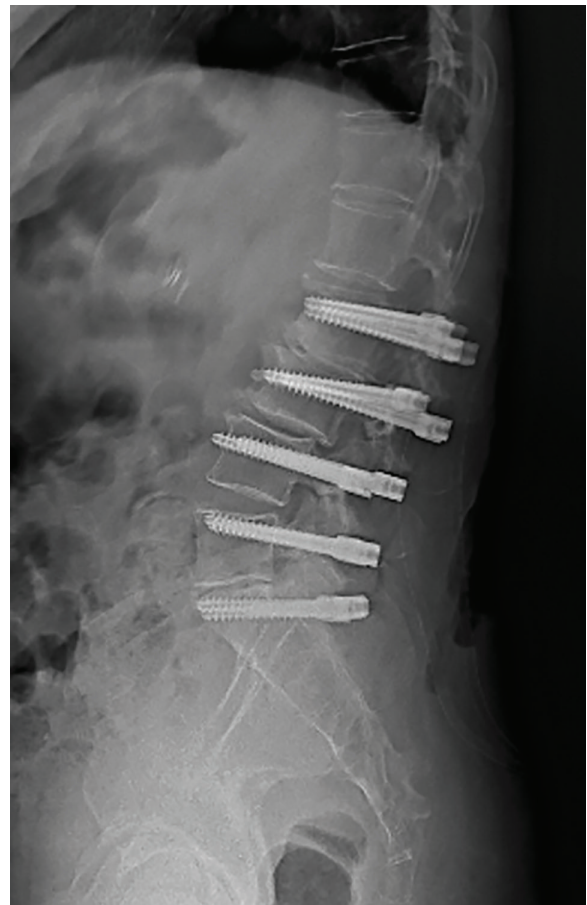

Figure 6. Lateral x-ray image after surgery shows the connection of the Dynesys system after osteointegration.

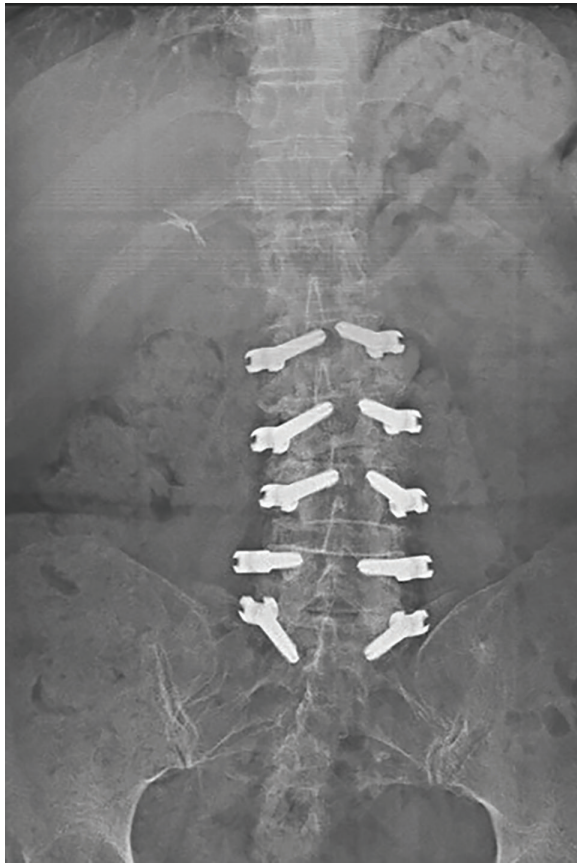

Figure 7. Anteroposterior x-ray image after surgery.

Statistics

Data analysis was performed using IBM SPSS Statistics version 25. The data were first analyzed using a 1-way analysis of variance (ANOVA). The Bonferroni test was used to compare the ODI and VAS scores of the

patients at different times. The ODI and VAS correlation coefficients (r) were calculated with the Pearson test. The significance level was set at $P < 0.01$ for all analyses.

RESULTS

Patients were monitored for an average of 30 months. Complications and recurrence were not observed in the patients. Neurological deficits were not observed after patients recovered from anesthesia. Significant improvement was observed in the ODI and VAS parameters in the preoperative (ODI: 66.2% and VAS: 7.8), early postoperative (ODI: 20.3% and VAS: 2.4), and late postoperative (ODI: 6.8% and VAS: 1.1) periods. Symptomatic improvement was seen in all patients. No screw breakage or loosening was detected by radiological evaluation in any of the patients during the 2-year follow-up.

The outcomes were extremely gratifying for patients and are presented in Tables 2–7. The only patient who was not satisfied was fitted with moving screws due to L5-S1 degenerative spondylolisthesis in accordance with the procedure, and the patient developed healthy osteointegration between the screw and the bone during the months of follow-up evaluation. However, the patient was found to have used opioid and was directed to go to the psychiatry department.

One-way ANOVA was used to determine the statistical significance of the corresponding integrals among VAS preoperative, VAS early postoperative, and VAS second-year follow-up of the surgery by group means. The significance of the test was determined at $P < 0.05$ (Table 3).

Table 3. Data analysis of VAS scores and pairwise comparisons.

Descriptive Statistics						
VAS			Mean	SD	N	
VAS preoperative			7.83	0.88	23	
VAS early operative			2.43	1.16	23	
VAS 2-y postoperative			1.13	1.42	23	
Pairwise Comparisons						
Measure: VAS						
(I) Time	(J) Time	Mean Difference (IJ)	Std. Error	P Value ^b	95% CI for Difference ^b	
					Lower Bound	Upper Bound
1	2	5.39 ^a	0.19	<0.001	4.88	5.90
	3	6.69 ^a	0.27	<0.001	5.99	7.39
2	1	−5.39 ^a	0.19	<0.001	−5.90	−4.88
	3	1.30 ^a	0.13	<0.001	0.96	1.64
3	1	−6.69 ^a	0.27	<0.001	−7.39	−5.99
	2	−1.30 ^a	0.13	<0.001	−1.64	−0.96

Abbreviation: VAS, visual analog scale.

Note: Based on estimated marginal means.

^aThe mean difference is significant at the.

^bAdjustment for multiple comparisons: Bonferroni.

Table 4. Data analysis of ODI scores and pairwise comparisons.

Descriptive Statistics						
ODI			Mean		SD	N
ODI preoperative			66.26		10.554	23
ODI early operative			20.30		12.197	23
ODI 2-y postoperative			6.87		12.282	23
Pairwise Comparisons						
Measure: ODI						
(I) Time	(J) Time	Mean Difference (IJ)	Std. Error	P Value ^b	95% CI for Difference ^b	
					Lower Bound	Upper Bound
1	2	45.957 ^a	2.075	<0.001	40.579	51.334
	3	59.391 ^a	2.823	<0.001	52.077	66.705
2	1	-45.957 ^a	2.075	<0.001	-51.334	-40.579
	3	13.435 ^a	1.037	<0.001	10.749	16.121
3	1	-59.391 ^a	2.823	<0.001	-66.705	-52.077
	2	-13.435 ^a	1.037	<0.001	-16.121	-10.749

Abbreviation: ODI, Oswestry Disability Index.

Note: Based on estimated marginal means.

^aThe mean difference is significant at the.^bAdjustment for multiple comparisons: Bonferroni.

One-way ANOVA was used to determine the statistical significance of the corresponding integrals among the preoperative ODI, early postoperative ODI, and second-year ODI of the surgery by group means. The significance of the test was determined at $P < 0.05$ (Table 4).

There was a significantly high correlation between the preoperative measured VAS and ODI values ($r = 811$, $P < 0.01$) (Table 5).

There was a significantly high correlation between the VAS and ODI values measured early operatively ($r = 960$, $P < 0.01$) (Table 6).

There was a significantly high correlation between VAS and ODI values measured at the second-year follow-up of the surgery ($r = 937$, $P < 0.01$) (Table 7).

DISCUSSION

In slow developing instability, the motion segment gradually deteriorates.¹⁰ The annulus and nucleus of the disc degenerate, and osteophytes begin to form and force the ligament structure to separate from the bone structure; also, the ligament structure changes

and their robustness decreases, indicating hypertrophy. After a while, the facet joints are affected by this aging process and experience deterioration of the capsular ligaments and facets. Another important point is that as a result of the deterioration of bone quality, the facet joints that face axial loading are gradually shifted toward the media with the forming facet trophism.¹¹ In the motion segment, the neutral zone gradually begins to expand, and the segment gradually becomes unstable over time.^{12,13} The muscles are the only system that protects the motion segment against all this slow developing deterioration. Muscles are affected by the genes inherited from one's parents and are structures that need to be well protected. If individuals have a strong muscle structure, they go through this process without problems and then enter the final process of degeneration. However, if there is no strong muscle structure, the motion segment, which remains under constant pressure, continues to deteriorate faster. Interventions, such as discectomy and facetectomy, to such an impaired

Table 5. Preoperative correlations of VAS and ODI scores.

Measure	VAS Preoperative	ODI Preoperative
VAS preoperative		
Pearson correlation	1	0.811 ^a
P value (2-tailed)		<0.001
N	23	23
ODI preoperative		
Pearson correlation	0.811 ^a	1
P value (2-tailed)	<0.001	
N	23	23

Abbreviations: ODI, Oswestry Disability Index; VAS, visual analog scale.

^aCorrelation is significant at the 0.01 level (2-tailed).**Table 6.** Early postoperative correlations VAS and ODI scores.

Measure	VAS Early Postoperative	ODI Early Postoperative
VAS early postoperative		
Pearson correlation	1	0.960 ^a
P value (2-tailed)		<0.001
N	23	23
ODI early postoperative		
Pearson correlation	0.960 ^a	1
P value (2-tailed)	<0.001	
N	23	23

Abbreviations: ODI, Oswestry Disability Index; VAS, visual analog scale.

^aCorrelation is significant at the 0.01 level (2-tailed).

Table 7. Late postoperative correlations of VAS and ODI scores.

Measure	ODI 2-y Postoperative	VAS 2-y Postoperative
ODI 2-y postoperative		
Pearson correlation	1	0.937 ^a
P value (2-tailed)		<0.001
N	23	23
VAS 2-y postoperative		
Pearson correlation	0.937 ^a	1
P value (2-tailed)	<0.001	
N	23	23

Abbreviations: ODI, Oswestry Disability Index; VAS, visual analog scale.

^aCorrelation is significant at the 0.01 level (2-tailed).

motion segment can result in disaster or accelerate this process even further.

Dynamic systems are exactly the kind of systems that support the spine against this form of deterioration. In the opinion of the advocates of dynamic systems, the use of fusion surgery in such minor instabilities is an overtreatment. It destroys the motion segment and easily triggers the emergence of pathologies, such as adjacent segment disease, especially in tissues with reduced resistance at advanced ages. Graf therefore developed the Graf ligament and pioneered the use of the concept.⁹

In summary, these systems compensate for the short-fall in muscle segments. A system that provides motion segment biomechanics close to that experienced in healthy individuals would be the ideal system. Biomechanically, finite element and cadaver work have shown that the best system is mobile rods and screws.^{14–16} However, there is no dynamic rod for multilevel pathologies that has these characteristics. The most dynamic rods that we can use in our patients are the Dynesys system and PEEK rods with dynamic screws; clinical outcomes are also successful with this system.¹⁷

The biggest criticism of these systems is the loosening of the proximal and distal end screws. In our own experience that is also the case. Especially as the bone stock begins to decrease, the likelihood of screw loosening increases.^{1,2,4} The ratio of screw loosening is low in a single mobile segment, but it increases in 2, 3, or more mobile segments. On the other hand, if we have no chance of interbody fusion in dynamic systems, we can also decide to place screws on the iliac wings so that the S1 screws do not become loose.^{18,19}

The question of why 2-stage surgery should be considered in these patients is very important. Therefore, when we looked at all of these patients, we saw that the vast majority of patients had minor symptoms with which they could manage their daily lives. The symptom seen in the first phase was axial back pain. Patients complained of not being able to stand or walk long distances for a long time. Neurological deficits initially occurred

at the level of root irritation. The patient complained of pain in his leg when he stood or walked for a long time, depending on foraminal or canal stenosis. Sometimes this is caused by degenerative small disc herniations. Patients endure this condition for a long time, but when they are not treated, neurological damage gradually sets in.

There is a long period of time that we can support the spine before patients develop neurological signs that they cannot tolerate. We can easily perform a 2-stage surgery, which includes 2 simpler operations that the patient can tolerate, on these patients with low bone quality. This is the most important approach as it saves the patient from future revision surgeries, and these 2 operations can also be performed with spinal anesthesia. Especially in patients with deformities who need long segment stabilization, there are serious complications and mortality problems, ranging from blood loss during surgery to delirium tremens, in fusion operations.^{20,21}

In order to prevent patients from experiencing these complications, the screws and rods should be inserted first, followed by a reasonable osteointegration within 4 to 6 months, and at this stage, surgical decompression, if necessary, provides a much more reasonable outcome. Although 6 months is a theoretically sufficient time for osteointegration, the adequacy of the compatibility between metal and bone should be confirmed by CT. When the literature was reviewed, we did not encounter a case series treated with 2-stage surgery, excluding the treatment of emergency cases that developed during surgery and severe deformity cases. Therefore, we believe that 2-stage surgery is a recommendation that should be considered. Furthermore, there is no indication that a segment that is implemented in a dynamic system will maintain movement to some extent if there is no severe degeneration.

The superficial properties of the material used in osteointegration are very important. Pure titanium or titanium alloys are suitable materials for osteointegration. Since the structure of the system we used was medical titanium alloy, we did not experience any problems in osteointegration in any patients.^{22,23}

CONCLUSION

Notably, screw loosening, which is a problem in dynamic systems, can be easily overcome with 2-stage surgery. In addition, based on this group of patients mostly consisting of older individuals who had additional medical problems, we recommend that the patient can tolerate 2 stages more easily. We share and

recommend this experience, as we have not had serious complications in the group of patients we have treated.

REFERENCES

1. Kuo C-H, Chang P-Y, Tu T-H, et al. The effect of lumbar lordosis on screw loosening in dynesys dynamic stabilization: four-year follow-up with computed tomography. *Biomed Res Int*. 2015;2015:152435. doi:10.1155/2015/152435
2. Ko C-C, Tsai H-W, Huang W-C, et al. Screw loosening in the dynesys stabilization system: radiographic evidence and effect on outcomes. *Neurosurg Focus*. 2010;28(6):E10. doi:10.3171/2010.3.FOCUS1052
3. Ozer AF, Oktenoglu T, Egemen E, et al. Lumbar single-level dynamic stabilization with semi-rigid and full dynamic systems: a retrospective clinical and radiological analysis of 71 patients. *Clin Orthop Surg*. 2017;9(3):310–316. doi:10.4055/cios.2017.9.3.310
4. Ciplak NM, Suzer T, Senturk S, et al. Complications of 2-level dynamic stabilization: a correlative clinical and radiological analysis at two-year follow-up on 103 patients. *Turk Neurosurg*. 2018;28(5):756–762. doi:10.5137/1019-5149.JTN.21036-17.1
5. Albrektsson T, Wennerberg A. The science of osseointegration. In: Zarb H, Eckert J, eds. *Prosthetic Treatment for Edentulous Patients*. St. Louis: Elsevier; 2013:323–329.
6. Beumer J, Faulkner R, Shah K, Moy P. *Fundamentals of Implant Dentistry*. Hanover Park, Ill: Quintessence Publishing; 2015.
7. Rowan M, Lee D, Pi-Anfruns J, Shiffler P, Aghaloo T, Moy PK. Mechanical versus biological stability of immediate and delayed implant placement using resonance frequency analysis. *J Oral Maxillofac Surg*. 2015;73(2):253–257. doi:10.1016/j.joms.2014.09.024
8. Agarwal R, García AJ. Biomaterial strategies for engineering implants for enhanced osseointegration and bone repair. *Adv Drug Deliv Rev*. 2015;94:53–62. doi:10.1016/j.addr.2015.03.013
9. Graf H. Lumbar instability: surgical treatment without fusion. *Rachis*. 1992;412:123–137.
10. Benzel EC. *The Anatomical Basis of Spinal Instability*. Clinical Neurosurgery. Baltimore: Williams and Wilkins; 1993:224–241.
11. Kirkaldy-Willis WH, Hill RJ. A more precise diagnosis for low-back pain. *Spine (Phila Pa 1976)*. 1979;4(2):102–109. doi:10.1097/00007632-197903000-00003
12. Panjabi MM. The stabilizing system of the spine. Part II. Neutral zone and instability hypothesis. *J Spinal Disord*. 1992;5(4):390–396. doi:10.1097/00002517-199212000-00002
13. Panjabi MM, Oxland TR, Yamamoto I, Crisco JJ. Mechanical behavior of the human lumbar and lumbosacral spine as shown by three-dimensional load-displacement curves. *J Bone Joint Surg Am*. 1994;76(3):413–424. doi:10.2106/00004623-199403000-00012
14. Erbulut DU, Kiapour A, Oktenoglu T, Ozer AF, Goel VK. A computational biomechanical investigation of posterior dynamic instrumentation: combination of dynamic rod and hinged (dynamic) screw. *J Biomech Eng*. 2014;136(5):051007. doi:10.1115/1.4027060
15. Oktenoglu T, Erbulut DU, Kiapour A, et al. Pedicle screw-based posterior dynamic stabilisation of the lumbar spine: in vitro cadaver investigation and a finite element study. *Comput Methods Biomech Biomed Engin*. 2015;18(11):1252–1261. doi:10.1080/10255842.2014.890187
16. Kaner T, Sasani M, Oktenoglu T, Aydin AL, Ozer AF. Minimum two-year follow-up of cases with recurrent disc herniation treated with microdiscectomy and posterior dynamic transpedicular stabilisation. *Open Orthop J*. 2010;4:120–125. doi:10.2174/1874325001004010120
17. Kaner T, Sasani M, Oktenoglu T, Cosar M, Ozer AF. Utilizing dynamic rods with dynamic screws in the surgical treatment of chronic instability: a prospective clinical study. *Turk Neurosurg*. 2009;19(4):319–326.
18. Özer AF, Aydın AL, Hekimoğlu M, et al. Should iliac wing screws be included in long segment dynamic stabilization? *Cureus*. 2021;13(2):e13543. doi:10.7759/cureus.13543
19. Yilmaz A, Senturk S, Sasani M, et al. Disc rehydration after dynamic stabilization: a report of 59 cases. *Asian Spine J*. 2017;11(3):348–355. doi:10.4184/asj.2017.11.3.348
20. Brown CH, LaFlam A, Max L, et al. Delirium after spine surgery in older adults: incidence, risk factors, and outcomes. *J Am Geriatr Soc*. 2016;64(10):2101–2108. doi:10.1111/jgs.14434
21. Nasser R, Yadla S, Maltenfort MG, et al. Complications in spine surgery. *J Neurosurg Spine*. 2010;13(2):144–157. doi:10.3171/2010.3.SPINE09369
22. Lausmaa J, Linder L. Surface spectroscopic characterization of titanium implants after separation from plastic-embedded tissue. *Biomaterials*. 1988;9(3):277–280. doi:10.1016/0142-9612(88)90098-1
23. Kumar A, Kumar V, Goel M, Mehta R, Bhayana G, Wadhwa S. Implant surface modification and osseointegration-past, present and future. *Journal of Oral Health and Community Dentistry*. 2014;8(2):113–118. doi:10.5005/johcd-8-2-113

Funding: The authors received no financial support for the research, authorship, and/or publication of this article.

Declaration of Conflicting Interests: The authors report no conflicts of interest in this work.

Corresponding Author: Ali Fahir Özer, Neurosurgery Department, Koc University School of Medicine, Rumelifeneri Yolu Sarıyer, Istanbul 34450, Turkey; alifahirozer@gmail.com

Published 10 June 2022

This manuscript is generously published free of charge by ISASS, the International Society for the Advancement of Spine Surgery. Copyright © 2022 ISASS. To see more or order reprints or permissions, see <http://ijssurgery.com>.