

Incidence and Associated Factors for Kyphosis Progression in Short-Segment Fixation Thoracolumbar Spine Fractures

Kongtush Choovongkomol, Urawit Piyapromdee, Terdpong Tanaviriyachai, Sarut Jongkittanakul and Weera Sudprasert

Int J Spine Surg 2022, 16 (5) 815-820

doi: <https://doi.org/10.14444/8343>

<https://www.ijssurgery.com/content/16/5/815>

This information is current as of May 17, 2025.

Email Alerts Receive free email-alerts when new articles cite this article. Sign up at:
<http://ijssurgery.com/alerts>

Incidence and Associated Factors for Kyphosis Progression in Short-Segment Fixation Thoracolumbar Spine Fractures

KONGTUSH CHOOVONGKOMOL, MD¹; URAWIT PIYAPROMDEE, MD¹; TERDPONG TANAVIRIYACHAI, MD¹; SARUT JONGKITTANAKUL, MD¹; AND WEERA SUDPRASERT, MD¹

¹Department of Orthopedic Surgery, Maharat Nakhon Ratchasima Hospital, Nakhon Ratchasima, Thailand

ABSTRACT

Background: The thoracolumbar spine is the most frequently affected portion of the spine during fractures. In surgical management, short-segment fixation is the treatment of choice because of preserved spine motion and fewer complications. However, this technique causes concerns of kyphosis progression compared with long-segment fixation. The widely used load-sharing classification was of limited value for predicting kyphosis progression in recent literature. The goal of this study was to identify the incidence and explore the factors associated with kyphosis progression in short-segment fixation in thoracolumbar spine fractures.

Study Design: Retrospective cohort study.

Methods: Patients with thoracolumbar spine fractures and no known neurological deficits treated by short-segment fixation and followed up for at least 12 months during January 2015 to October 2019 were included in this study. Demographic and radiographic data parameters were collected from the hospital database. Incidence of kyphosis progression was collected, and multivariable logistic regression analysis was used to explore associated factors.

Results: A total of 91 patients were included in this study. The most common fractures were AO-type A3 in 57.7% of patients, followed by A4 in 31.9%, A2 in 9.9%, and B in 6.6%. Posterior ligamentous complex (PLC) injuries were found in 51.7%. The incidence of kyphosis progression was 35.2%. The PLC was found to be significantly associated with kyphosis progression (OR 3.14, $P = 0.040$). Intermediate screw insertion was a preventive factor (OR 0.11, $P = 0.043$). Age, body mass index, and type of fracture were not significant associated factors.

Conclusion: The incidence of kyphosis progression was 35.2%. The PLC injury and intermediate screw insertion were significant associated factors. Long-segment fixation in a patient who had PLC injury or intermediate screw insertion should be considered to prevent kyphosis progression.

Clinical Relevance: PLC injury was significantly associated with kyphosis progression in short segment thoracolumbar fracture fixation. Therefore, the surgeon should carefully select treatment options for these groups of patients.

Level of Evidence: 3.

Lumbar Spine

Keywords: spinal fracture, thoracolumbar spine, pedicle screws, kyphosis

INTRODUCTION

Thoracolumbar spine fractures are the most frequently affected part of spine injuries, which can be treated surgically and nonsurgically. The consequences of these injuries can be devastating, such as neurological deficits and severe kyphotic deformities, which reduce a patient's quality of life. Primary treatment is very important for the injury; otherwise, kyphosis deformities can subsequently develop, leading to decreased quality of life and progressive weakness. If these complications manifest, revision surgery is necessary, which is associated with a high rate of complications.¹

Thoracolumbar burst fractures can be classified using the AO method, as originally described by Magerl et al.^{2,3} Type A injuries of the vertebral body result from compression force. Subtype A1 injuries include impaction fractures, subtype A2 injuries include split fractures in the sagittal or coronal plane, and subtype A3 consists of cases of partial or total comminution with or without retropulsion of fragments to the spinal canal. Subtype A3 can be further subdivided into the following: A3.1, incomplete burst fractures; A3.2, burst split fracture; and A3.3, complete burst. Type B consists of fractures due to flexion-distraction, and type C consists of any fracture mentioned above with a superimposed rotational component.

The rationale of these injuries had been developed according to the Denis classification.^{4,5} Fractures that involve 3 columns of the spine are unstable and require surgical treatment. In 2005, Vaccaro et al proposed the thoracolumbar injury classification and severity score (TLICS),⁶ which classifies fracture morphology, posterior ligamentous complex (PLC), and neurological status. TLICS is used to guide the treatment method.

Unstable thoracolumbar spine fractures should be treated surgically by pedicle screw fixation. Short-segment posterior pedicle screw fixation is useful as it preserves motion and less intraoperative morbidity. However, there are reports that short-segment fixation procedures have a high rate of failure.⁷⁻⁹ In 1994, McCormack et al proposed a load-sharing classification (LSC) score, which described fractures in comminution, apposition, and kyphosis reduction. Fractures with an LSC score greater than 6 may require anterior structural support or long-segment fixation.⁹

However, recent reports on successful treatment of thoracolumbar spine fractures with short-segment posterior pedicle screw fixation suggested that the LSC has limited value in prediction of kyphosis progression.¹⁰⁻¹⁴ In this study, we retrospectively identified the incidence of kyphosis progression and explored associated factors in patients with thoracolumbar spine fractures who underwent short-segment pedicle screw fixation.

MATERIALS AND METHODS

A retrospective cohort study was conducted on patients with single thoracolumbar fractures without neurological deficits who were diagnosed and treated by short-segment pedicle screw fixation during January 2015 to October 2019. Ethics approval was obtained from the Institutional Review Board, Maharat Nakhon Ratchasima Hospital Ethics Committee (MNRH IRB No.135/2020). We excluded patients who had a follow-up of less than 12 months, osteoporosis, patients with pathological fractures, and incomplete data from our hospital database.

Patients were divided into 2 groups: the kyphosis progression group and the stable group. Kyphosis progression was determined by a kyphosis angle increase of more than 5° during the follow-up period (Figure 1). We collected associated factors for kyphosis progression—age, gender, body weight, and height—and TLICS score from the hospital database. The study flow is shown in Figure 2. The fracture type was classified according to the AO method.^{2,3} Measurements of kyphosis angle were made in accordance with the Cobb method¹⁵ after producing lateral view radiographs

of the affected segments. PLC injuries were defined by magnetic resonance imaging as follows: (1) discontinuity or nonvisualization of the black stripe (low signal intensity) representing supraspinous ligament on sagittal T1- and/or T2-weighted images and (2) bright, high signal intensity of interspinous space on sagittal T2-weighted images, which indicate hemorrhage or scar formation of the interspinous ligament¹⁶ or computed tomography images showing facet joint diastasis, sagittal translation, or increased interspinous distance more than 2 mm.^{17,18}

All patients underwent short-segment pedicle screw fixation with either an open procedure or minimally invasive technique from a single experienced surgeon. Short-segment pedicle screw fixation was defined as pedicles that were fixed at 1 cranial and caudal vertebra from the index level without laminectomy or posterior spinal fusion in both groups. The global standard screw (GSS, GS Medical Co, Ltd, Geumcheon-gu, Seoul, Korea) monoaxial pedicle screw system was used in an open procedure. The Aesculap S4 element minimally invasive surgery system (Aesculap Implant Systems, Center Valley, PA, USA) was used in a minimally invasive procedure. The 6.5-mm diameter pedicle screws were used in both systems. The indirect reduction was performed by positioning a patient in the hyperextended prone position.

Statistical Methods

All data are presented as frequencies and percentages, or means and SD, as appropriate. Fisher exact tests were used to test for relationships between categorical variables to examine proportional differences. Two sample *t* tests were performed to examine mean differences between groups. To assess the associated factors of the loss correction, we performed multivariable logistic regression analyses. All statistical analyses were performed using STATA software version 14.0 for Mac (StataCorp, College Station, TX, USA). A *P* value of less than 0.05 was considered statistically significant.

RESULTS

Ninety-one patients were eligible for the study. Mean age was 43.12 ± 12.9 years. Of those patients, 59 (64.84%) were men. Level of fracture was T11 in 1 (1.0%), T12 in 22 (24.2%), L1 in 45 (49.5%), and L2 in 23 (25.2%) patients. According to AO thoracolumbar spine fracture, type A2 9 (9.9%), A3 47 (51.6%), A4 29 (31.9%), and B 6 (6.6%) patients. We found PLC injuries in 47 (51.7%) patients. Mean TLICS scores were 4.65

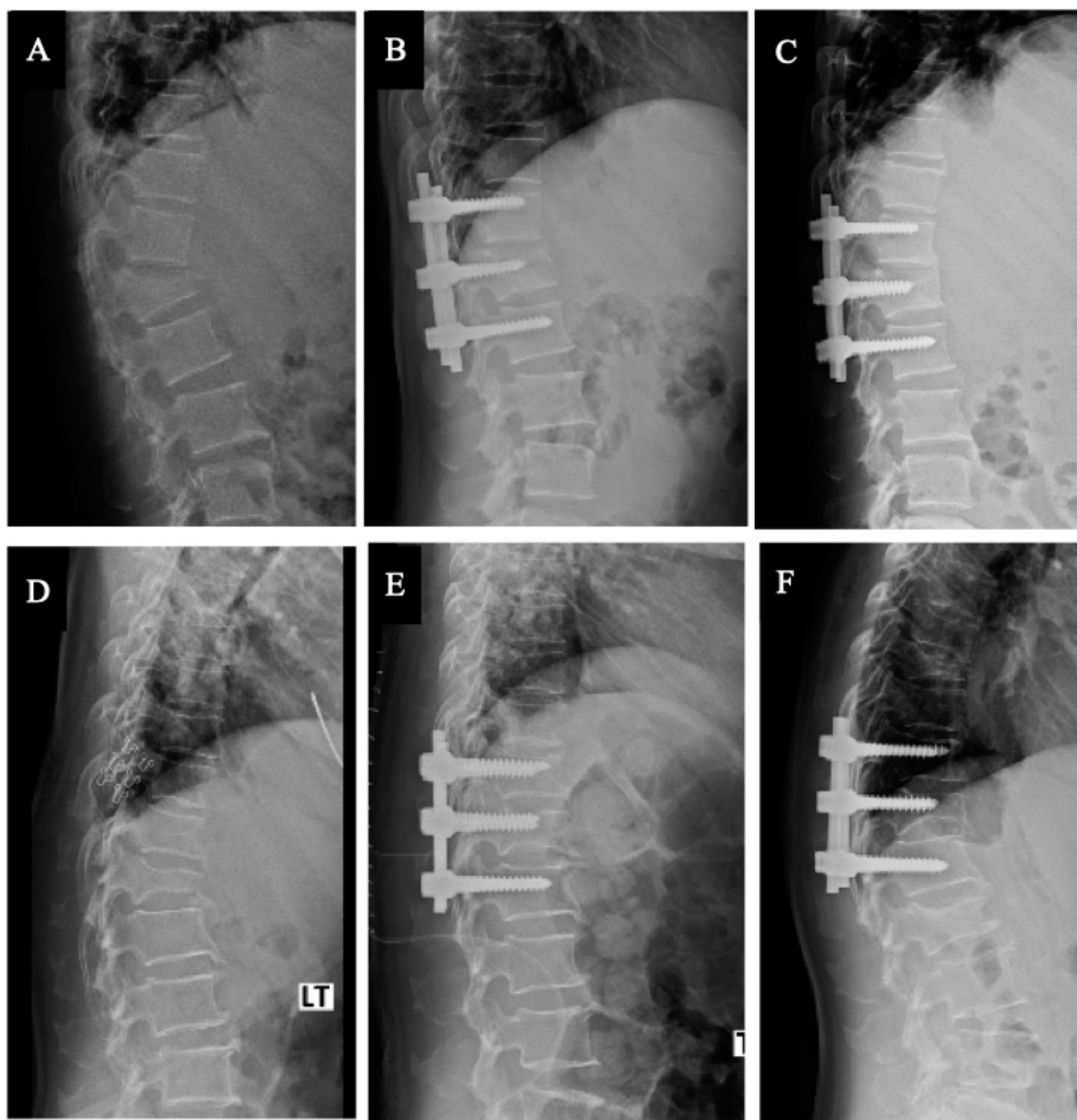


Figure 1. Radiographs of patients who are stable (A, B, and C) and kyphosis progression (D, E, and F) after short-segment pedicle fixations. (A) and (D) were obtained immediately after injuries. (B) and (E) were obtained after fixation. (C) and (F) were obtained at a 2-y follow-up.

± 0.79 . Mean prekyphotic angles were $15.20^\circ \pm 8.8^\circ$. Mean postkyphotic angles were $4.13^\circ \pm 7.6^\circ$. Intermediate screws were inserted in 83 (91.2%) patients. Mean follow-up time was 25.07 ± 10.23 months. In this study, we found that 32 (35.2%) patients had kyphosis progression. There were no patients who needed revision surgery. Mean loss correction angle during follow-up was $4.81^\circ \pm 4.3^\circ$. According to the LSC, the mean total

score was 6.27 ± 1.5 . A total of 39 (42.9%) patients had an LSC total score of greater than 6. Sixty-four (70.3%) patients underwent surgery by a minimally invasive technique.

Demographic comparison between the kyphosis progression and stable group was shown in Table 1. Mean loss correction angle during follow-up was 9.47 ± 3.6 in the kyphosis progression group and 2.29 ± 1.7 in the

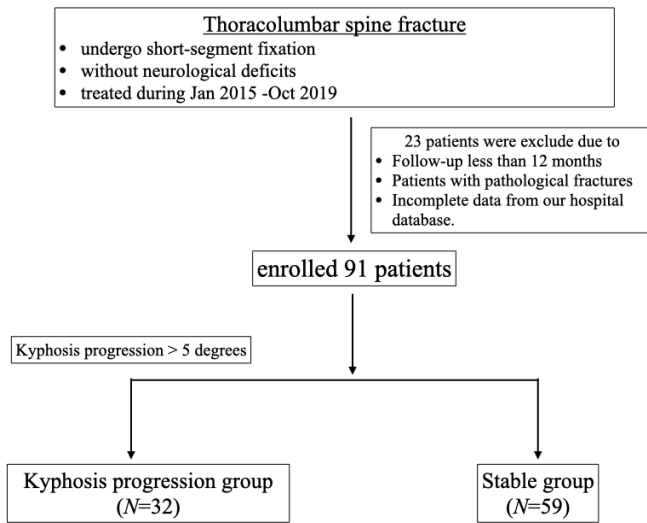


Figure 2. Study flowchart.

stable group ($P < 0.001$). We found that follow-up time in the stable group was longer than the kyphosis progression group ($P = 0.031$). There were no significant differences between the 2 groups in other factors associated with kyphosis progression ($P > 0.05$). There were no significant differences in TLICS scores, total LSC scores, comminution, apposition, or kyphosis reduction between the 2 groups.

After multivariable logistic analysis, we found that PLC injuries and intermediate screw insertion were statistically significant (OR 3.14, $P = 0.040$ and OR 0.11, $P = 0.043$, respectively). Age, body mass index, type of fracture, and surgical technique were not statistically significant (Table 2). The proportion of patients with LSC score >6 was not statistically significant between the kyphosis progression and stable groups (OR 1.91, $P = 0.147$) (Table 3).

Table 1. Demographic data compared between the kyphosis progression and stable groups.

Associated Factors	Kyphosis Progression Group (n = 32)	Stable Group (n = 59)	P Value
Age, y, mean \pm SD	43.56 \pm 15.5	42.92 \pm 11.5	0.821
>60 y, n (%)	5 (15.6%)	4 (6.8%)	0.269
Gender, n (%)			
Male	23 (71.8%)	36 (61.2%)	0.362
Female	9 (28.2%)	23 (38%)	
Body mass index, mean \pm SD	23.24 (\pm 3.4)	22.63 (\pm 3.3)	0.403
>25, n (%)	9 (28.1%)	14 (23.7%)	0.801
Fracture level, n (%)			
T11	0	1 (1.7%)	0.711
T12	6 (18.8%)	16 (27.1%)	
L1	16 (50.0%)	29 (49.2%)	
L2	10 (31.2%)	13 (22.0%)	
AO spine Thoracolumbar injuries system, n (%)			
B1/B2	1 (3.0%)	5 (8.5%)	0.326
A2	3 (9.4%)	6 (10.2%)	
A3	14 (43.8%)	33 (55.9%)	
A4	14 (43.8%)	15 (25.4%)	
Posterior ligamentous complex injuries, n (%)	20 (62.5%)	27 (45.8%)	0.187
Thoracolumbar injury classification and severity score, mean \pm SD	4.69 \pm 0.64	4.62 \pm 0.87	0.399
Initial kyphotic angle, mean \pm SD	15.41 \pm 9.9	15.08 \pm 8.3	0.869
Postoperative kyphotic angle, mean \pm SD	3.72 \pm 8.0	4.36 \pm 7.4	0.705
Loss correction angle, mean \pm SD	9.47 \pm 3.6	2.29 \pm 1.7	<0.001
Intermediate screw, n (%)	29 (90.6%)	54 (91.5%)	1.000
Surgical technique, n (%)			
Open technique	10 (31.3%)	17 (28.8%)	0.814
Minimally invasive technique	22 (68.7%)	42 (71.2%)	
Follow-up time, mean \pm SD	21.98 \pm 10.3	26.76 \pm 9.9	0.031
Load-sharing classification			
Comminution			
1	9 (28.1%)	18 (30.5%)	0.569
2	12 (37.5%)	27 (45.8%)	
3	11 (34.4%)	14 (23.7%)	
Apposition			
1	11 (34.4%)	23 (39.0%)	0.769
2	14 (43.8%)	27 (45.8%)	
3	7 (21.8%)	9 (15.2%)	
Reduction			
1	3 (9.4%)	6 (10.2%)	0.466
2	8 (25%)	22 (37.3%)	
3	21 (65.6%)	31 (52.5%)	
Total score >6	17 (53.1%)	22 (37.3%)	0.185

Table 2. Multivariable logistic regression analysis between associated factors and kyphosis progression.

Associated Factors	OR	95% CI	P Value
Age >60 y	3.81	0.66–21.88	0.133
Body mass index >25	1.97	0.63–6.09	0.241
AO spine TL system			
B1/B2	1.00		
A2	4.45	0.28–70.59	0.290
A3	4.70	0.41–53.29	0.212
A4	7.95	0.69–91.85	0.097
Posterior ligamentous complex injuries	3.14	1.05–9.38	0.040
Intermediate screw	0.11	0.01–0.93	0.043
Minimally invasive technique	0.80	0.27–2.41	0.690

Results were already controlled by the initial and postoperative kyphotic angle and follow-up time.

The area under the receiver operating characteristic curve for the LSC was 0.58.

DISCUSSION

Previous studies have reported that in the treatment of thoracolumbar fractures, short-segment pedicle screw fixation without provision of support of the anterior column was associated with a high rate of early instrumentation failure and progression of kyphotic progression.^{7–9} On the contrary, although our study has shown a relatively large incidence of kyphosis progression (35.16%), there were no cases with clinical symptoms or revision surgery that were required throughout the follow-up period.

Nevertheless, various reports have suggested risk factors associated with kyphosis progression or instrumental failure of short-segment screw fixation such as an LSC score greater than 6 (which includes comminution, apposition, and kyphosis correction)⁹ and type A3 fracture.¹⁹ Intermediate screw insertion in fractured vertebra was a preventive factor.²⁰ In our study, PLC injuries were significantly associated with kyphosis progression. Intermediate screw insertion also was a preventive factor. Type of fracture, age, and body mass index were not significant in this study.

In a systematic review, Stam et al²¹ reported that LSC scores were of limited value in predicting sagittal collapse and posterior instrumentation failure. About 57% of the studies reviewed suggested that LSC scores had no effect on the outcome. However, the remaining 43% of the

studies found that either there was either an association between a high LSC score and loss of correction or surgeons had already opted for the surgical approach based on the LSC score.²¹ In our study, there was no significant difference between the 2 groups with regard to comminution, apposition, or kyphosis reduction ($P > 0.05$). Furthermore, total LSC scores were shown to have a limited prediction value for kyphosis progression (Table 3). The area under the receiver operating characteristic curve for the LSC score was 0.58, and there was no significant difference between the kyphosis progression and stable groups ($P = 0.147$).

Denis et al proposed that the posterior column was 1 of 3 important columns for spinal stability.⁴ PLC injuries were factored into the TLICS to aid in decision-making regarding which fracture would require surgical management.⁶ Furthermore, this study showed that PLC injuries were a significant factor associated with kyphosis progression (OR 3.14, $P = 0.040$). Based on the results of our study and review of available literature, we suggest that surgeons consider PLC injuries before selecting short-segment pedicle screw fixation as the method of treatment to prevent kyphosis progression in these patients.

Intermediate screw insertion was used to prevent instrumental failure and kyphosis progression in previous studies.^{14,22} In our study, there was a statistically significant difference between the kyphosis progression and stable groups (OR 0.11, $P = 0.043$). The OR suggested a significant preventive factor in the intermediated screw insertion.

This study had some limitations. First, this study was a retrospective study in which information bias might occur. Second, this study had limited case numbers, which might not show significant differences between the kyphosis progression and stable groups. Third, kyphosis progression might not be associated with the functional outcome of patients. A well-designed prospective study should be conducted to gain further insight, especially regarding functional score outcomes. Because a single surgeon performed all operations in this study, the controlled factors of surgical technique and experience were the strengths of this study.

CONCLUSION

The incidence of kyphosis progression in this study was 35.2%. PLC injury was the significant associated factor for kyphosis progression. Being able to place screws into the fractured level could reduce the probability of kyphosis progression. Long-segment fixation in a patient who had PLC injury or intermediate screw insertion should be considered to prevent kyphosis progression. Risks and benefits should be discussed with patients.

Table 3. Logistic regression analysis and area under ROC curve between load-sharing classification score and kyphosis progression.

Load-Sharing Classification	OR	95% CI	Area Under ROC Curve	P Value
Total score				
≤6	1.00			
>6	1.91	0.80–4.56	0.58	0.147

Abbreviation: ROC, receiver operating characteristic.

REFERENCES

1. Mazel C, Ajavon L. Malunion of post-traumatic thoracolumbar fractures. *Orthop Traumatol Surg Res.* 2018;104(1S):S55–S62. doi:10.1016/j.otsr.2017.04.018
2. Magerl F, Aebi M, Gertzbein SD, Harms J, Nazarian S. A comprehensive classification of thoracic and lumbar injuries. *Eur Spine J.* 1994;3(4):184–201. doi:10.1007/BF02221591
3. Aebi M. AO spine classification system for thoracolumbar fractures. *Eur Spine J off Publ Eur Spine Soc Eur Spinal Deform Soc Eur Sect Cerv Spine Res Soc.* 2013;22(10):2147–2148. doi:10.1007/s00586-013-3062-4
4. Denis F. The three column spine and its significance in the classification of acute thoracolumbar spinal injuries. *Spine (Phila Pa 1976).* 1983;8(8):817–831. doi:10.1097/00007632-198311000-00003
5. Denis F. Spinal instability as defined by the three-column spine concept in acute spinal trauma. *Clin Orthop.* 1984;(189):65–76.
6. Vaccaro AR, LehmanRJ, Hurlbert RJ, et al. A new classification of thoracolumbar injuries: the importance of injury morphology, the integrity of the posterior ligamentous complex, and neurologic status. *Spine (Phila Pa 1976).* 2005;30(20):2325–2333. doi:10.1097/01.brs.0000182986.43345.cb
7. Ebelke DK, Asher MA, Neff JR, Kraker DP. Survivorship analysis of VSP spine instrumentation in the treatment of thoracolumbar and lumbar burst fractures. *Spine (Phila Pa 1976).* 1991;16(8 Suppl):S428–32. doi:10.1097/00007632-199108001-00024
8. McLain RF, Sparling E, Benson DR. Early failure of short-segment pedicle instrumentation for thoracolumbar fractures. a preliminary report. *J Bone Joint Surg Am.* 1993;75(2):162–167. doi:10.2106/00004623-199302000-00002
9. McCormack T, Karaiovic E, Gaines RW. The load sharing classification of spine fractures. *Spine (Phila Pa 1976).* 1994;19(15):1741–1744. doi:10.1097/00007632-199408000-00014
10. Aligizakis AC, Katonis PG, Sapkas G, Papagelopoulos PJ, Galanakis I, Hadjipavlou A. Gertzbein and load sharing classifications for unstable thoracolumbar fractures. *Clin Orthop Relat Res.* 2003;(411):77–85.
11. Gelb D, Ludwig S, Karp JE, et al. Successful treatment of thoracolumbar fractures with short-segment pedicle instrumentation. *J Spinal Disord Tech.* 2010;23(5):293–301. doi:10.1097/BSD.0b013e3181af20b6
12. Kose KC, Inanmaz ME, Isik C, Basar H, Caliskan I, Bal E. Short segment pedicle screw instrumentation with an index level screw and cantilevered hyperlordotic reduction in the treatment of type-A fractures of the thoracolumbar spine. *Bone Joint J.* 2014;96-B(4):541–547. doi:10.1302/0301-620X.96B4.33249
13. Aono H, Tobimatsu H, Ariga K, et al. Surgical outcomes of temporary short-segment instrumentation without augmentation for thoracolumbar burst fractures. *Injury.* 2016;47(6):1337–1344. doi:10.1016/j.injury.2016.03.003
14. Rojas-Tomba F, Hernández-Ruiz Á, Menéndez-Quintanilla I, García de Quevedo-Puerta D, Moriel-Durán J, Villanueva-Pareja F. Radiologic and functional outcomes in unstable thoracolumbar fractures treated with short-segment pedicle instrumentation. *Clin Spine Surg.* 2017;30(10):459–465. doi:10.1097/BSD.0000000000000393
15. Harrison DE, Cailliet R, Harrison DD, Janik TJ, Holland B. Reliability of centroid, cobb, and harrison posterior tangent methods: which to choose for analysis of thoracic kyphosis. *Spine (Phila Pa 1976).* 2001;26(11):E227–E234. doi:10.1097/00007632-200106010-00002
16. Haba H, Taneichi H, Kotani Y, et al. Diagnostic accuracy of magnetic resonance imaging for detecting posterior ligamentous complex injury associated with thoracic and lumbar fractures. *J Neurosurg.* 2003;99(1 Suppl):20–26. doi:10.3171/spi.2003.99.1.0020
17. Rajasekaran S, Maheswaran A, Aiyer SN, Kanna R, Dumpa SR, Shetty AP. Prediction of posterior ligamentous complex injury in thoracolumbar fractures using non-MRI imaging techniques. *Int Orthop.* 2016;40(6):1075–1081. doi:10.1007/s00264-016-3151-1
18. Barcelos A, Joaquim AF, Botelho RV. Reliability of the evaluation of posterior ligamentous complex injury in thoracolumbar spine trauma with the use of computed tomography scan. *Eur Spine J.* 2016;25(4):1135–1143. doi:10.1007/s00586-016-4377-8
19. Curfs I, Grimm B, van der Linde M, Willems P, van Hemert W. Radiological prediction of posttraumatic kyphosis after thoracolumbar fracture. *Open Orthop J.* 2016;10:135–142. doi:10.2174/1874325001610010135
20. Lin Y-C, Fan K-F, Liao J-C. Two additional augmenting screws with posterior short-segment instrumentation without fusion for unstable thoracolumbar burst fracture - comparisons with transpedicular grafting techniques. *Biomed J.* 2016;39(6):407–413. doi:10.1016/j.bj.2016.11.005
21. Stam WT, Deunk J, Elzinga MJ, Bloemers FW, Giannakopoulos GF. The predictive value of the load sharing classification concerning sagittal collapse and posterior instrumentation failure: a systematic literature review. *Global Spine J.* 2020;10(4):486–492.
22. Yang M, Ding GZ, Xu ZJ. Surgical outcome in thoracolumbar fractures managed by short-segment pedicle instrumentation. *Ann Acad Med Singap.* 2014;43(1):24–32.

Funding: The authors received no financial support for the research, authorship, and/or publication of this article.

Declaration of Conflicting Interests: The authors report no conflicts of interest in this work.

Ethics Approval: Ethics approval was obtained from the Maharat Nakhon Ratchasima Hospital Institutional Review Board: MNRH IRB No. 135/2020. The study was registered at Thaiclinicaltrial.org (Identifier: TCTR20210927001).

Corresponding Author: Kongtush Choovongkomol, Department of Orthopedic Surgery, Maharat Nakhon Ratchasima Hospital, 49 Changpueak Rd, Amphoe Mueang, Nakhon Ratchasima, 30000, Thailand; kongtushc@gmail.com

Published 31 August 2022

This manuscript is generously published free of charge by ISASS, the International Society for the Advancement of Spine Surgery. Copyright © 2022 ISASS. To see more or order reprints or permissions, see <http://ijssurgery.com>.