

## Fusion Mass Screws in Revision Spinal Deformity Surgery: A Simple and Safe Alternative Fixation

Ashish Mittal, Alexander Rosinski, Khalid Odeh, Cristian Balcescu, Victor Ungurean, Jr, Victor Ungurean, Sr and Dimitriy G. Kondrashov

*Int J Spine Surg* 2023, 17 (1) 17-24

doi: <https://doi.org/10.14444/8352>

<http://ijssurgery.com/content/17/1/17>

This information is current as of April 17, 2024.

---

**Email Alerts** Receive free email-alerts when new articles cite this article. Sign up at:  
<http://ijssurgery.com/alerts>

# Fusion Mass Screws in Revision Spinal Deformity Surgery: A Simple and Safe Alternative Fixation

ASHISH MITTAL, MD<sup>1</sup>; ALEXANDER ROSINSKI, MD<sup>1</sup>; KHALID ODEH, MD<sup>1</sup>; CRISTIAN BALCESCU, MD<sup>1</sup>; VICTOR UNGUREAN, JR<sup>2</sup>; VICTOR UNGUREAN, SR, MD<sup>3</sup>; AND DIMITRIY G. KONDRASHOV, MD<sup>1</sup>

<sup>1</sup>St. Mary's Medical Center, San Francisco Orthopaedic Residency Program, San Francisco, CA, USA; <sup>2</sup>The Taylor Collaboration, San Francisco, CA, USA; <sup>3</sup>Institute of Emergency Medicine, Chisinau, Moldova

## ABSTRACT

**Background:** Revision spinal deformity surgery has a high rate of complications. Fixation may be challenging due to altered anatomy. Screws through a fusion mass are an alternative to pedicle screw fixation.

**Objective:** The purpose of this retrospective study was to further elucidate the safety and efficacy of fusion mass screws (FMSs) in revision spinal deformity surgery.

**Design:** Retrospective case series.

**Methods:** Fifteen freehand FMSs were placed in 6 patients with adult spinal deformity between 2016 and 2018 by the senior author. FMSs were combined with pedicle screws, at times at the same level. FMSs were used to save distal levels from fusion, assist in closing a 3-column osteotomy and provide additional fixation in cases of severe instability. Computed tomography (CT) was used to assess bone mineral density (BMD) and thickness of each fusion mass preoperatively along with accuracy of FMS placement postoperatively.

**Results:** The mean BMD of the fusion mass was 397 Hounsfield units (HU; range: 156–628 HU). The mean AP thickness of the fusion mass was  $15.5 \pm 4.8$  mm (range: 8.6–24.4 mm). The mean FMS length was  $35.3 \pm 5.5$  mm (range: 25–40 mm). There was no evidence of FMS loosening, breakage, or pseudarthrosis at latest follow-up (mean: 2.2 years, range: 1.4–3.1 years). No neurologic deficits were observed. 1/15 screws had a low-grade breach into the canal (<2 mm). No patients required revision surgery.

**Conclusion:** FMSs may be used to augment fixation in revision spinal deformity cases when pedicle screw placement may be challenging. FMSs may also provide an additional anchor at levels with pedicular fixation.

**Level of Evidence:** 3.

Complications

Keywords: fusion mass, spinal deformity, revision, pedicular dysplasia, extrapedicular fixation

## INTRODUCTION

Rates of revision in patients undergoing correction for adult spinal deformity have been found to range from 9% to 19.9%.<sup>1–3</sup> A substantial portion of these cases require a revision of the old instrumentation.<sup>2</sup> Revision spinal deformity instrumentation in a previously fused spine often presents a number of challenges.<sup>4</sup> Conventional landmarks for pedicle screw placement may be obscured or nonexistent, increasing the potential for spinal cord or nerve root injury.<sup>4,5</sup> Altered tactile feedback, complex anatomy, and dysplastic pedicles can further confound this process. These patients often require substantial deformity correction, which makes stable points of fixation paramount.<sup>4</sup> A study of 10,912 patients demonstrated a statistically significant increase in risk of procedure-related complications, neurological complications, and vessel/nerve injury

in the revision setting compared to the primary setting.<sup>6</sup> A large report by the Scoliosis Research Society looking at 108,419 procedures found a 41% higher rate of a new neurological deficit in the revision setting.<sup>7</sup>

While techniques have been described to improve the accuracy of pedicle screw placement, pedicle screw misplacement has still been shown to occur 2.0% to 18.6% of the time.<sup>5,8,9</sup> Furthermore, some of those techniques rely on computer-aided navigation and stereotactic image guidance, which may not be widely available.<sup>8,10</sup> An additional method of screw fixation may have considerable utility where the traditional pedicle screw fixation appears challenging.

Fusion mass screws (FMSs) can provide an additional anchor for fixation in patients with a prior history of spinal fusion. These are screws that are placed coronally or obliquely across the posterior

**Table 1.** Clinical data for 6 adult spinal deformity patients treated with FMS fixation during revision spine surgery.

Case	Age (y), Gender	Diagnosis	Levels Fused	FMS Levels	Indication for FMS Placement	Complications	Follow-Up (y)
1	29, M	Juvenile onset scoliosis, sagittal imbalance	T2-L4	T12, L2	Pedicular dysplasia, pedicle compromise from prior instrumentation	None	2.4
2	66, M	Adult spinal deformity, osteomyelitis, fusion mass fracture at T6 and T7	T3-S1	T8, T10	Assist in closure of 3-column osteotomy	Pneumothorax	1.7
3	58, F	Adolescent idiopathic scoliosis, fusion mass fracture at T11, sagittal imbalance	C2-pelvis	T9, T10, T11	Fusion mass fracture, assist in closure of 3-column osteotomy	None	2.1
4	57, F	T12 burst fracture and T12 paraparesis, charcot arthropathy at L3-L4 and L4-L5	T9-Pelvis	T12, L1	Augment fixation at prior corpectomy site	Anaphylaxis, FMS low-grade breach into spinal canal at T12 (Figure 2)	1.4
5	57, F	Adolescent idiopathic scoliosis, pseudarthrosis at L3-L4, distal junctional failure at L4-S1.	T1-Pelvis	L2, L5	Augment pedicle screw fixation	None	2.3
6	28, F	Juvenile onset scoliosis, neurofibromatosis-1, pseudarthrosis at T12-L1	T6-L4	T9, T10, T11, T12	Pedicular dysplasia	Dural tear	3.1

Abbreviation: FMS, fusion mass screw.

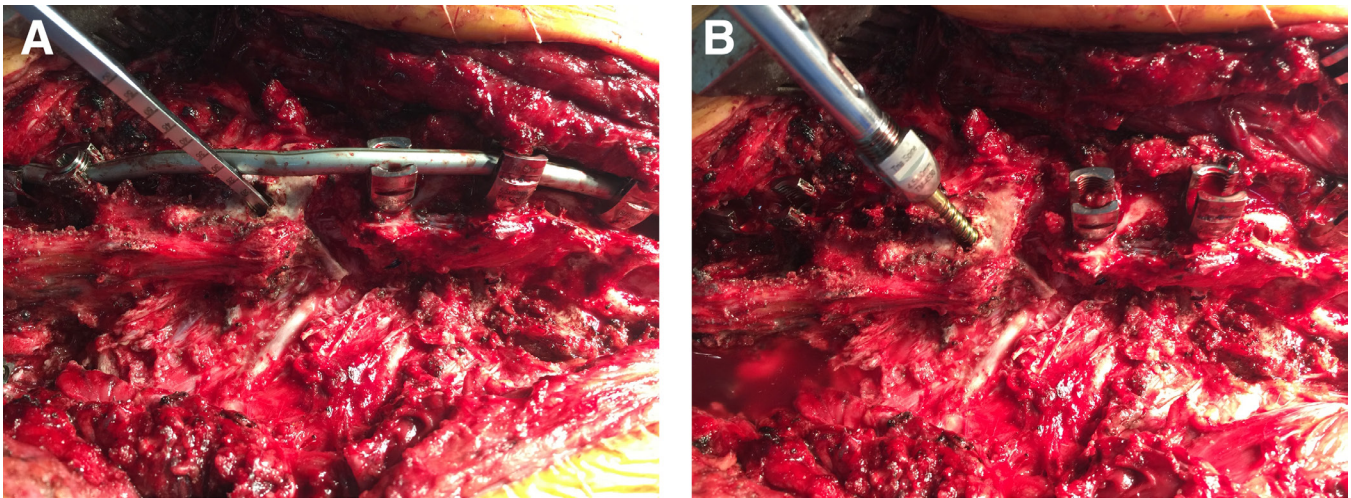
bone formed as a result of a prior spinal fusion. These screws may provide added stability while reducing the risk of a neurological injury during revision surgery. Two cases have been previously described in the literature, with successful results.<sup>4</sup> We aim to further elucidate the use of FMSs in revision spinal deformity surgery.

## METHODS

A retrospective review was conducted of 6 patients who underwent revision spinal deformity surgery with FMS placement between 2016 and 2018 (Table 1). Our hospital's Institutional Review Board had approved this study, and a waiver of informed consent was granted. Pedicle screws were preferentially placed when their safe placement was considered possible based on the preoperative imaging. Bone mineral density (BMD) and dimensions of the posterolateral fusion masses at different levels were determined on the preoperative CT to assess the possible levels for FMS placement. FMS screws were placed to augment the fixation with or without concurrent pedicle screws present at the same level. The indication for a revision was a fusion mass fracture in 2 cases, Charcot arthropathy in 1 case, distal junctional failure in 1 case, and iatrogenic sagittal imbalance in 2 cases. Four out of 6 patients had a 3-column osteotomy. Patients were followed clinically to monitor for pain, disability, or neurological symptoms. Screw placement and presence of pseudarthrosis were evaluated on postoperative CT scans.

## FMS Technique

Standard 5.0- or 5.5-mm pedicle screws were placed medially across the posterolateral fusion mass (Figure 1). The starting points were chosen to line up with pedicle screws above and below the FMS to allow for easy connection to the rod. In other instances, FMSs were connected to other levels using an accessory rod construct. Adjacent pedicle screws were placed prior to the FMSs. FMSs were preferably inserted from the convex side of the curve since severe rotation of the vertebrae relative to the chest wall may result in an unsafe trajectory from the concave side.<sup>4</sup> Since fusion masses are thinnest at the level of the interlaminar space, FMSs were placed proximal to this region. Screw position was confirmed using orthogonal fluoroscopic views. A high-speed burr was used to establish a starting point at a depth of approximately 5 mm. A standard pedicle probe was then inserted and directed medially across the fusion mass. A flexible ball-tipped probe was used to assess for cortical breaches, most importantly of the ventral wall adjacent to the spinal canal. After measuring the depth and under-tapping the screw path, standard 5.0-mm or 5.5-mm pedicle screws ranging from 25 mm to 50 mm in length were placed within the fusion mass. Somatosensory evoked potentials (SSEP) and motor-evoked potentials were monitored and recorded throughout each case. The threshold for stimulation was above 15 milliamps for all screws.



**Figure 1.** (A) Intraoperative photograph of fusion mass screw cannulation lateral to medial immediately inferior to a chevron posterior column osteotomy using a Lenke probe. (B) Intraoperative photograph of polyaxial screw placement into the fusion mass.


## RESULTS

Fifteen freehand FMSs were placed in 6 cases of adult spinal deformity. In all cases, FMSs were combined with pedicle screws, and 45% of the screws were placed concurrently with pedicle screws at the same level. All screws were either 5.0 or 5.5 mm in diameter. There were no neurophysiologic alerts observed during FMS placement and no neurologic deficits or complications postoperatively. On postoperative CT, 1/15 screws had a low-grade breach into the spinal canal (Figure 2). The mean BMD of the fusion mass was  $397.2 \pm 144.4$  HU (range: 156–628 HU). The mean AP thickness of the fusion mass was  $15.5 \pm 4.8$  mm (range: 8.6–24.4 mm) at the level of FMS placement. The mean FMS length was

$35.3 \pm 5.5$  mm (range: 25–40 mm) (Table 2). BMP was utilized in 5/6 cases. There was no evidence of FMS loosening, breakage, or pseudarthrosis at latest follow-up (mean: 2.2 years, range: 1.4–3.1 years). The mean preoperative Oswestry Disability Index (ODI) was 48 ( $n = 4$ , range: 32–76). The mean postoperative ODI was 45 ( $n = 5$ , range: 24–63) at a mean follow-up of 8 months. None of the 6 patients required a revision surgery to date.

### Case 1

A 29-year-old man with a history of juvenile onset scoliosis and a prior posterior spinal fusion from T2 to L4 more than 10 years ago presented with a recurrent back pain and lower extremity weakness. His prior postoperative course was complicated by an infection, for which he underwent irrigation and debridement, as well as hardware revision 1 year following his original procedure. Imaging revealed a sagittal vertebral axis of 7 cm and a  $15^\circ$  mismatch between pelvic incidence and lumbar lordosis. He was also found to have a medial pedicle breach at one of the levels. The patient underwent a revision posterior spinal fusion from T2 to L4 with a pedicle subtraction osteotomy at L1. There was no evidence of a recurrent infection intraoperatively. Two 5.5-mm right-sided FMSs measuring 40 and 35 mm, respectively, were placed at T12 and L2 as those pedicles were found to be compromised by prior instrumentation (Figure 3). At both levels, the patient had an ample thickness and density of the fusion mass (Table 2, Figure 4). Two short rods were placed from T12 to L2, and 2 long rods were placed from T2 to L4. All screws were stimulated and found to be within normal limits.



**Figure 2.** Axial computed tomography image showing low-grade breach (<2 mm) into spinal canal of a fusion mass screw placed at T12, Case 4.

**Table 2.** Comparison of fusion mass thickness, BMD, and screw length in 6 adult spinal deformity patients treated with FMS fixation during revision spine surgery.

Case	Level	Fusion Mass Thickness (mm)	Fusion Mass BMD (HU)	Screw Length (mm)	Complications Related to FMS Placement	FMS Loosening, Breakage, or Pseudarthrosis at Latest Follow-Up
1	T12	23.7	315	40	None	None
1	L2	24.4	475	35	None	None
2	T8	15.8	628	40	None	None
2	T10	13.3	544	40	None	None
3	T9	8.6	574	40	None	None
3	T10	10.4	496	35	None	None
3	T11	12.8	378	40	None	None
4	T12	18.7	500	35	Spinal canal breach	None
4	L1	19.4	378	35	None	None
5	L2	11.1	455	40	None	None
5	L5	13.9	372	40	None	None
6	T9	10.7	156	30	None	None
6	T10	14.3	284	30	None	None
6	T11	19.6	215	25	None	None
6	T12	16.5	188	25	None	None
Mean ± SD	–	15.5 ± 4.8	397 ± 144	35 ± 5.5	–	–

Abbreviations: BMD, bone mineral density; CT, computed tomography; FMS, fusion mass screw; HU, Hounsfield units.

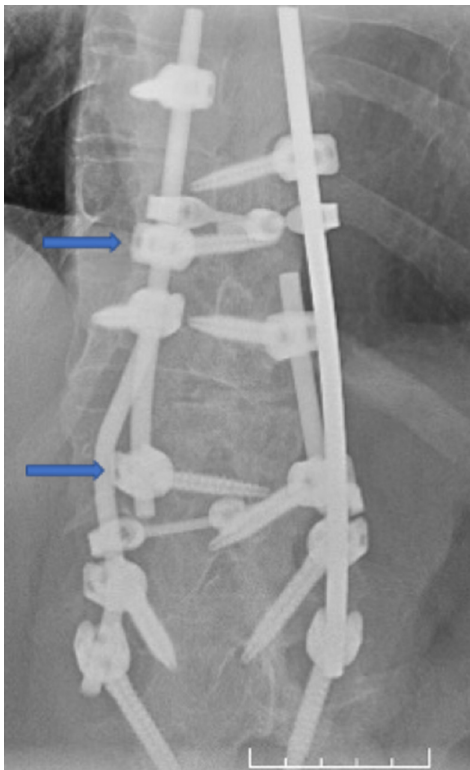
Note: There was no evidence of FMS loosening, breakage, or pseudarthrosis on CT at a mean of 2.2 years of follow-up (range: 1.4 to 3.1 years). On postoperative CT, 1 out of 15 screws had a low-grade breach (<2 mm) into the canal (Case 4 at T12). There were otherwise no complications related to FMS placement.

There were no neuromonitoring deficits noted. His sagittal vertebral axis was restored to within normal limits and lumbar lordosis was within 10° of pelvic incidence. There were no breaches noted on postoperative CT. At 2.4-year clinical follow-up, he demonstrated a resolution of preoperative symptoms with no new deficits or subjective complaints. The use of the FMSs below the

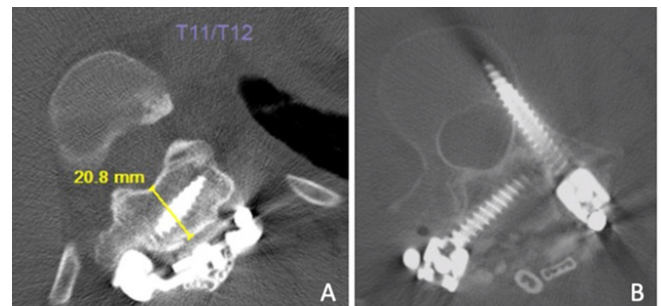
3-column osteotomy has augmented the distal fixation and obviated the need to go distal to L4.

### Case 2

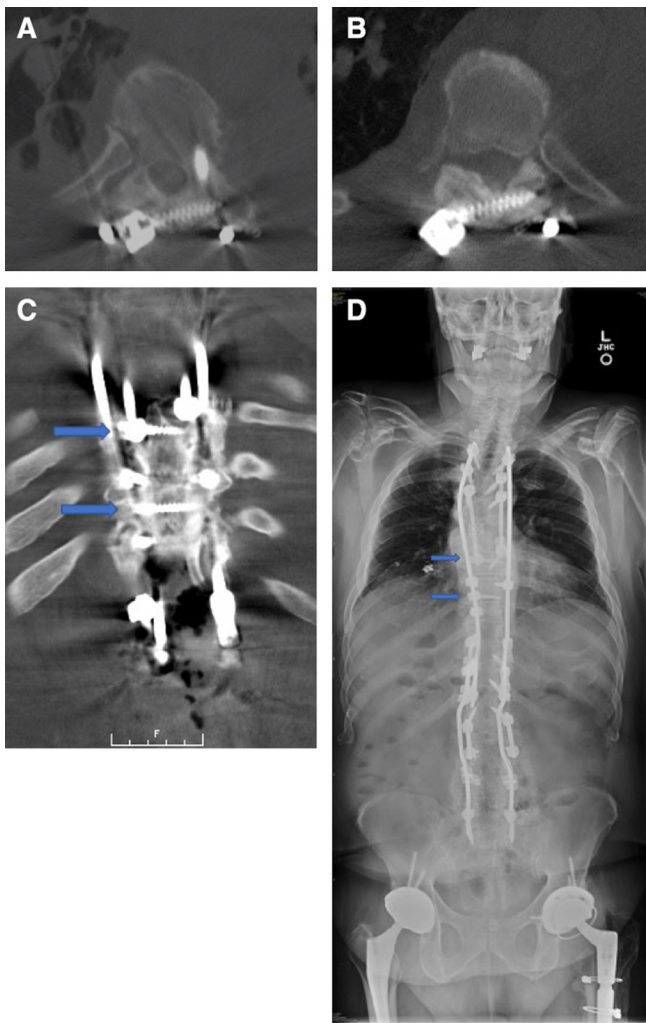
A 66-year-old man with a progressive adult spinal deformity following multiple prior surgeries including a prior pedicle subtraction osteotomy at L2 and a posterior spinal fusion from T3 to S1 4 years prior presented with a progressive back pain, difficulty walking, and recurrent fevers. His prior postoperative course had been complicated by multiple infections and symptomatic hardware requiring removal from T3 to T10. Imaging revealed evidence of recurrent osteomyelitis with a fusion mass fracture at T6 to T7. He underwent a vertebrectomy at T6 to T7 and a fusion from T3 to S1 (Figure 5). Two FMSs were placed at T8 and T10 concurrently with pedicle screws to aid with the osteotomy closure (Figure 6). At both levels, there was an ample fusion mass thickness (15.8 and 13.3 mm) to



**Figure 3.** Fusion mass screws (arrows) assisting in osteotomy closure and providing an additional anchor to save a distal fusion level below a 3-column osteotomy.



**Figure 4.** (A) Axial computed tomography (CT) image showing fusion mass screws (FMSs) placement at T12 through a thick fusion mass bed measuring 21.8 mm. (B) CT image showing right-sided FMS placement with a concurrent pedicle screw placement at L2.



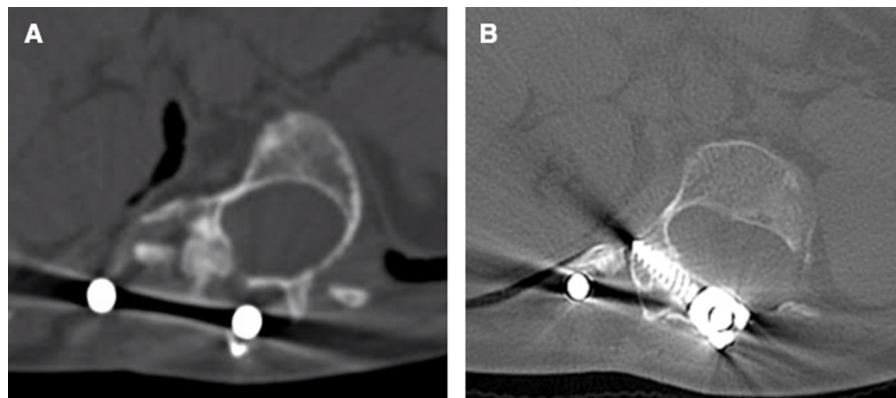
**Figure 5.** (A-C) CT and (D) full-length standing radiograph images demonstrating fusion mass screw placement at T8 and T10 (arrows) distal to the vertebral column resection to assist in osteotomy closure. Concurrent pedicle screw placement is also shown at T8.

accommodate FMSs (Table 2). Screws of 40 mm were used and placed inferior to the pedicle screws at each level. A quadruple rod construct was used for the definitive fixation. All screws were stimulated and found to be within normal limits. There were no neuromonitoring deficits noted. The procedure was complicated by a right-sided pneumothorax requiring a chest tube. He had recovered well from the operation. No new neurological deficits were noted. The patient did have a chronic right lower extremity weakness that was present for several years before this operation, that had persisted. There were no breaches noted on the postoperative CT. At 1.7-year clinical follow-up, he had demonstrated improvement in his symptoms with no new deficits.

## DISCUSSION

Spinal deformity surgery has a high rate of revision. The most common causes for revision include implant failure, infection, curve progression, pseudarthrosis, and a junctional disease.<sup>3</sup> Patients have been shown to have a higher rate of complications and reoperation after every subsequent surgery.<sup>3,11</sup> Each revision represents an additional significant cost burden on society.<sup>12,13</sup> Many of these cases require a reinstrumentation with a subset of cases requiring corrective osteotomies.

Revision spinal fusion presents numerous challenges in fixation. Pedicle screws remain the gold standard of spinal fixation due to their biomechanical advantages in load-to-failure, pullout strength, and ability to control all 3 columns of the spine. However, in the revision setting, the screw placement can be more difficult due to obscured landmarks, complex anatomy, altered tactile feedback, and dysplastic pedicles. Achieving the



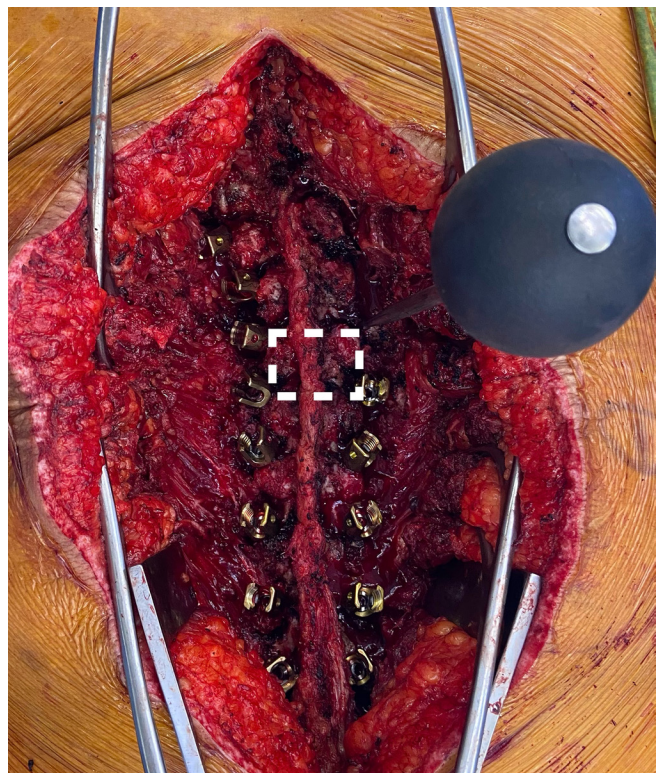
**Figure 6.** (A) Axial computed tomography images of Patient 6 demonstrating pedicular dysplasia in the setting of neurofibromatosis-1 and juvenile onset scoliosis. (B) Fusion mass screw placed at T12. Pedicle screw placement was avoided due to dysplasia and obscured landmarks intraoperatively. The pedicles were 2.2 and 3.9 mm in width at this level.

necessary fixation in those cases has been correlated with a higher rate of neurologic and overall complications.

A mature fusion mass consists of a dense, spacious bone for screw fixation. The mean fusion mass thickness at the instrumented levels was 15.5 mm in this study, with the lowest thickness of 8.6 mm. It has been previously described that a minimum thickness of 8 mm is required for fixation with a 4.5-mm screw.<sup>4</sup> Screws of 5.0 or 5.5 mm were utilized for all the levels in this study. The reliability of Hounsfield units (HU) in determining BMD has previously been described.<sup>14</sup> Measurements of 100.8 and 78.5 HU have been shown to correspond to osteopenia and osteoporosis respectively.<sup>14</sup> The mean BMD in our series was 397 HU, with the lowest BMD of the instrumented fusion mass being 156 HU, well above the osteopenic/osteoporotic range. Although our series did not have any cases of a screw loosening or breakage, it is possible that this could be the case with lower bone densities. The placement of FMSs in the revision setting offers an increased construct strength with a potentially lower risk to the neural elements. FMSs may be used to achieve a stable fixation in revision spinal deformity cases when pedicles are dysplastic or when normal anatomical landmarks are obscured by an extensive fusion mass (Figure 6).

Additionally, FMSs may provide an additional anchor at a level where pedicle screws are already placed to increase the strength and rigidity of the construct, assist in osteotomy closure, provide an anchor for an additional rod and potentially shorten the construct. The quadruple rod constructs were used in each case of a 3-column osteotomy. In addition to the fusion mass fixation, there are several other techniques that have been described to this end.

The quadrangulation method is a freehand technique that uses instrumentation at adjacent levels to guide the placement of standard pedicle screws through a fusion mass (Figure 7).<sup>8</sup> This technique relies on the meticulous exposure and initial screw placement at virgin levels, where landmarks are not obscured by the fusion mass. If only the fusion mass is being instrumented, the levels with the clearest landmarks are instrumented first and used as a guide for adjacent levels. The lateral aspect of the transverse processes can often be located even in the presence of most fusion masses. The fusion mass pedicle screw starting sites are located at the same distance from adjacent virgin screw holes to make a quadrangular shape (Figure 7). The general steps of a screw placement are then similar to those involving a freehand pedicle screw placement in the virgin spine.



**Figure 7.** Intraoperative photograph demonstrating identification of the pedicle screw starting point using a quadrangulation technique as described by Kim et al.<sup>8</sup>

Palpation, intraoperative fluoroscopy, and stimulus-evoked electromyography (EMG) monitoring are used to confirm the accurate screw placement. Using this technique, Kim et al reported a pedicle screw misplacement rate of 1.99% on the intraoperative radiographic evaluation and 1.09% on the EMG evaluation.<sup>8</sup> There were no screw-related neurological or vascular complications. However, there were no postoperative CT images to evaluate for a screw misplacement. They did not include any documented cases of a pedicular dysplasia. The quadrangulation method is a technically challenging, but an effective method of instrumentation in a previously fused spine.

Stereotactic image-guided navigation may also be used to aid with a pedicle screw placement in a mature fusion mass. Using preoperative CT scans, stereotaxy theoretically allows for an accurate localization of a starting point and a screw trajectory. A case series of 122 pedicle screws placed in a fusion mass using stereotaxy showed a 4.1% rate of cortical perforation on the postoperative CT imaging.<sup>9</sup> The rate of a perforation was higher (13%) in patients with a scoliosis. None of those patients had postoperative neurological deficits. A cadaveric study using a fused spine model demonstrated a 0% perforation rate using the stereotactic CT-guided

placement and an 8.33% perforation rate using the fluoroscopic-assisted placement.<sup>15</sup> The non-image-guided group in this study had a 21.43% incidence of a cortical breach. Stereotactic guidance can certainly be helpful in the revision surgery, but the cost, added surgical time, and accessibility limit its widespread use. There is also the added downside of additional radiation to the patient.

Extrapedicular fixation using hooks into the fusion mass has also been described in the revision surgery setting. A case series of 8 patients undergoing a revision posterior spinal fusion in the setting of a spinal deformity showed that hooks can aid in providing a stable fixation at a 30-month follow-up with a concurrent pedicle screw fixation.<sup>10</sup> The authors did not observe any hook loosening or failure at the latest follow-up.

Extrapedicular fixation in the thoracic spine with fixation of the transverse processes and vertebral bodies has also been described with good results.<sup>16</sup> Intralaminar screw placement has also been presented as an alternative technique for a fixation in the setting of a difficult pedicle screw, in addition to a laminar hook placement in the revision setting.<sup>17</sup> Translaminar screw placement in the thoracic spine has been described with good results for a short-segment fusion.<sup>18</sup>

Certain criteria must be met prior to a fusion mass fixation. A sufficient thickness, width, and density of the fusion mass is necessary for a safe FMS placement. A rotational deformity can further limit its placement, especially at the concavity of the curve.

Limitations of our study include a relatively small sample size and limited patient-reported outcomes. In addition, the FMSs used in our study were part of a larger construct, which included pedicle screws and interbody cages. It is unclear if FMS can be used in a standalone setting. Further studies are needed to better define the efficacy and safety of FMSs. Biomechanical testing could better elucidate the stability of those screws in various planes. While our mean follow-up was 2.2 years, a longer follow-up is likely needed to assess the stability of those screws over time.

## CONCLUSION

FMSs can add stability and strength to spinal constructs in revision spinal deformity surgery. They provide a reliable and safe method to augment the pedicle screw fixation with a simple and cost-effective technique. They can be used at the same levels as pedicle screws for an additional fixation or without pedicle screws where their placement is difficult/impossible due to altered pedicle morphology.

## REFERENCES

- Poorman GW, Zhou PL, Vasquez-Montes D, et al. Differences in primary and revision deformity surgeries: following 1,063 primary thoracolumbar adult spinal deformity fusions over time. *J Spine Surg.* 2018;4(2):203–210. doi:10.21037/jss.2018.05.06
- Cho SK, Bridwell KH, Lenke LG, et al. Major complications in revision adult deformity surgery: risk factors and clinical outcomes with 2- to 7-year follow-up. *Spine (Phila Pa 1976).* 2012;37(6):489–500. doi:10.1097/BRS.0b013e3182217ab5
- Pitter FT, Lindberg-Larsen M, Pedersen AB, Dahl B, Gehrchen M. Revision risk after primary adult spinal deformity surgery: a nationwide study with two-year follow-up. *Spine Deform.* 2019;7(4):619–626. doi:10.1016/j.jspd.2018.10.006
- Lewis SJ, Arun R, Bodrogi A, et al. The use of fusion mass screws in revision spinal deformity surgery. *Eur Spine J.* 2014;23 Suppl 2:181–186. doi:10.1007/s00586-013-2843-0
- Rampersaud YR, Lee KS. Fluoroscopic computer-assisted pedicle screw placement through a mature fusion mass: an assessment of 24 consecutive cases with independent analysis of computed tomography and clinical data. *Spine (Phila Pa 1976).* 2007;32(2):217–222. doi:10.1097/01.brs.0000251751.51936.3f
- Diebo BG, Passias PG, Marascalchi BJ, et al. Primary versus revision surgery in the setting of adult spinal deformity: a nationwide study on 10,912 patients. *Spine (Phila Pa 1976).* 2015;40(21):1674–1680. doi:10.1097/BRS.0000000000001114
- Hamilton DK, Smith JS, Sansur CA, et al. Rates of new neurological deficit associated with spine surgery based on 108,419 procedures: a report of the scoliosis research society morbidity and mortality committee. *Spine (Phila Pa 1976).* 2011;36(15):1218–1228. doi:10.1097/BRS.0b013e3181ec5fd9
- Kim Y-W, Lenke LG, Kim YJ, et al. Free-hand pedicle screw placement during revision spinal surgery: analysis of 552 screws. *Spine (Phila Pa 1976).* 2008;33(10):1141–1148. doi:10.1097/BRS.0b013e31816f28a1
- Lim MR, Girardi FP, Yoon SC, Huang RC, Cammisia FP. Accuracy of computerized frameless stereotactic image-guided pedicle screw placement into previously fused lumbar spines. *Spine (Phila Pa 1976).* 2005;30(15):1793–1798. doi:10.1097/01.brs.0000171905.38459.b7
- Liu N, Wood KB. Multiple-hook fixation in revision spinal deformity surgery for patients with a previous multilevel fusion mass: technical note and preliminary outcomes. *J Neurosurg Spine.* 2017;26(3):368–373. doi:10.3171/2016.8.SPINE16432
- Hu X, Lieberman IH. Revision adult spinal deformity surgery: does the number of previous operations have a negative impact on outcome? *Eur Spine J.* 2019;28(1):155–160. doi:10.1007/s00586-018-5747-1
- Yeramaneni S, Robinson C, Hostin R. Impact of spine surgery complications on costs associated with management of adult spinal deformity. *Curr Rev Musculoskelet Med.* 2016;9(3):327–332. doi:10.1007/s12178-016-9352-9
- Terran J, McHugh BJ, Fischer CR, et al. Surgical treatment for adult spinal deformity: projected cost effectiveness at 5-year follow-up. *Ochsner J.* 2014;14(1):14–22.
- Schreiber JJ, Anderson PA, Rosas HG, Buchholz AL, Au AG. Hounsfield units for assessing bone mineral density and strength: a tool for osteoporosis management. *J Bone Joint Surg Am.* 2011;93(11):1057–1063. doi:10.2106/JBJS.J.00160
- Austin MS, Vaccaro AR, Brislin B, Nachwalter R, Hilibrand AS, Albert TJ. Image-guided spine surgery: a cadaver study comparing



conventional open laminoforaminotomy and two image-guided techniques for pedicle screw placement in posterolateral fusion and nonfusion models. *Spine (Phila Pa 1976)*. 2002;27(22):2503–2508. doi:10.1097/01.BRS.0000031274.34509.1E

16. Husted DS, Yue JJ, Fairchild TA, Haims AH. An extrapedicular approach to the placement of screws in the thoracic spine: an anatomic and radiographic assessment. *Spine (Phila Pa 1976)*. 2003;28(20):2324–2330. doi:10.1097/01.BRS.0000085361.32600.63

17. Lewis SJ, Canavese F, Keetbaas S. Intralaminar screw insertion of thoracic spine in children with severe spinal deformities: two case reports. *Spine (Phila Pa 1976)*. 2009;34(7):E251–4. doi:10.1097/BRS.0b013e318194ece1

18. Aepli M, Mannion AF, Grob D. Translaminar screw fixation of the lumbar spine: long-term outcome. *Spine (Phila Pa 1976)*. 2009;34(14):1492–1498. doi:10.1097/BRS.0b013e3181a0934f

**Funding:** The authors received no financial support for the research, authorship, and/or publication of this article.

**Declaration of Conflicting Interests:** Dimitriy G. Kondrashov reports receiving royalties and consulting fees from Spineart. The remaining authors have no relevant or material financial interests that relate to the research described in this paper.

**Corresponding Author:** Dimitriy G. Kondrashov, St. Mary's Medical Center, 1 Shrader St Suite 600, San Francisco, CA 94117, USA; sfspine@gmail.com

Published 01 August 2022

This manuscript is generously published free of charge by ISASS, the International Society for the Advancement of Spine Surgery. Copyright © 2023 ISASS. To see more or order reprints or permissions, see <http://ijssurgery.com>.