

## Assessment of Cervical and Lumbar Kinematics in Simulated Open and Closed Kinetic Chain

Farid Amirouche, Martine Dolan, Sonia Pradhan, Mark Mikhael and Jad Bou Monsef

*Int J Spine Surg* 2023, 17 (1) 51-59

doi: <https://doi.org/10.14444/8382>

<https://www.ijssurgery.com/content/17/1/51>

This information is current as of April 30, 2025.

---

**Email Alerts** Receive free email-alerts when new articles cite this article. Sign up at:  
<http://ijssurgery.com/alerts>

# Assessment of Cervical and Lumbar Kinematics in Simulated Open and Closed Kinetic Chain

FARID AMIROUCHE, PhD<sup>1,2</sup>; MARTINE DOLAN, BS<sup>2</sup>; SONIA PRADHAN, MPT<sup>2</sup>; MARK MIKHAEL, MD<sup>1,3</sup>; AND JAD BOU MONSEF, MD<sup>4</sup>

<sup>1</sup>Department of Orthopaedic Surgery, Northshore University HealthSystem an Affiliate of University of Chicago Pritzker School of Medicine, Evanston, IL, USA;

<sup>2</sup>Department of Orthopaedic Surgery, University of Illinois College of Medicine at Chicago, Chicago, IL, USA; <sup>3</sup>Orthopaedic Spine Surgery, Illinois Bone and Joint Institute, Glenview, IL, USA; <sup>4</sup>Department of Orthopaedic Surgery and Rehabilitation Medicine, SUNY Downstate Health Sciences University, Brooklyn, NY, USA

## ABSTRACT

**Background:** The pelvic girdle and spine vertebral column work as a long chain influenced by pelvic tilt. This study aims to assess the effect of open and closed chain anterior pelvic tilt (APT) or posterior pelvic tilt (PPT) on cervical and lumbar spine kinematics using an in vitro cadaveric spine model.

**Methods:** Three human cadaveric spines with intact pelvis were suspended with the skull fixed in a metal frame. Optotrak 3-dimensional motion system captured coordinates of pin markers at 24 different points for real-time tracking of cervical and lumbar regions. Additional geometric parameters were measured to calculate pelvic incidence and pelvic tilt. A force-torque digital gauge applied consistent force to standardize the acetabular or sacral axis' APT and PPT during simulated open- and closed-chain movements, respectively.

**Results:** In closed-chain PPT, significant differences in relative intervertebral decompression were noted between spinal levels C2/C3 (4.85 mm) and C5/C6 (1.26 mm), while compression was noted between L1/L2 (–2.54 mm) and L5/S1 (–11.84 mm) and between L3/L4 (–2.78 mm) and L5/S1 (–11.84 mm) ( $P < 0.05$ ). Displacement during closed-chain PPT was significantly greater than during open-chain PPT for cervical and lumbar spines. In closed-chain APT, significant differences in relative intervertebral decompression were noted between spinal levels L1/L2 (2.87 mm) and L5/S1 (24.48 mm) and between L3/L4 (2.94 mm) and L5/S1 (24.48 mm) ( $P < 0.05$ ). Pelvic incidence remained the same as the pelvis tilted anterior and posterior.

**Conclusions:** In PPT, open-chain pelvic tilts did not produce as much cervical and lumbar intervertebral displacement compared with closed-chain pelvic tilts. In contrast, APT saw fewer differences between open- and closed-chain tilting. There was a reciprocal relationship between pelvic tilt and sacral slope, producing a constant pelvic incidence throughout all pelvic tilt angles.

**Clinical Relevance:** The results of this study may help determine how a patient's pelvic tilt is causing pain and using that knowledge to guide rehabilitation of stabilizing muscles. The data produced here may also be helpful in determining which rehabilitation exercises may be more difficult or prone to injury for patients with either excessive anterior or posterior pelvic tilt.

**Level of Evidence:** 5.

Biomechanics

Keywords: pelvic tilt, kinematics, lumbar spine, cervical spine

## INTRODUCTION

Pelvic tilt (PT) denotes the rotation of the innominate bones of the pelvic girdle in either the anterior or posterior direction.<sup>1</sup> Both anterior PT (APT) and posterior PT (PPT) can occur in the setting of either an open or closed kinetic chain. The entire chain is supposed to span the length of the body, and the pelvis's motions are defined as closed if both the head and feet remain fixed. In contrast, movements of the pelvis are considered open when either the head or feet rotate along with the pelvis. For example, open chain can occur when the spine, pelvis, and femur move in a coordinated fashion to produce a range of motion greater than that available

to 1 segment alone, like during hip flexion with a straight leg. On the other hand, when both ends of the chain are aligned (head held upright over feet), axial skeleton segments function as part of a closed chain, as can be seen when performing an exercise such as a push-up or squat.

While open-chain movements can be a part of a workout regimen or specific daily activities (eg, bending down to pick things up), the body is typically held up as a closed chain.<sup>2</sup> Excessive PTs within closed-chain movements of the spine are often seen in the presence of orthopedic pathologies, either of muscular or skeletal origin. For example, tight hip flexor muscles can cause the pelvic girdle to tilt anteriorly, setting off

an unconscious adjustment that works to maintain the head upright over the sacrum. As a result, the hip will still flex, but the lumbar spine will extend in response to keep an upright stature, producing excessive lumbar lordosis.<sup>3</sup>

The most frequently encountered pathologies that can produce a closed-chain pelvic misalignment are adult spinal deformity (ASD) and cervical spondylotic myelopathy (CSM). Both of these spinal conditions demonstrate how the body attempts to correct sagittal plane misalignments through excessive PT, either posteriorly or anteriorly, to maintain upright stature and forward gaze.<sup>4</sup> Unfortunately, as the pelvis tilts beyond its natural position, this often creates additional pain and further disability for the patient because of pathological compensatory changes to other spine segments and even the lower limbs.<sup>5-7</sup> Prior literature analyzing PT and spine kinematics has focused on the closed kinetic chain lumbar kinematics.<sup>1,8,9</sup> However, with an expanding elderly population, spine conditions will become more prevalent, making it essential to understand how pathologic closed-chain APT or PPT impacts both lumbar and cervical spinal segments. Therefore, it is critical to comprehend pelvic compensation's effects on other spinal segments, so rehabilitation methods can be more effectively designed to alleviate pain and protect patients from aggravating previously sensitive areas.

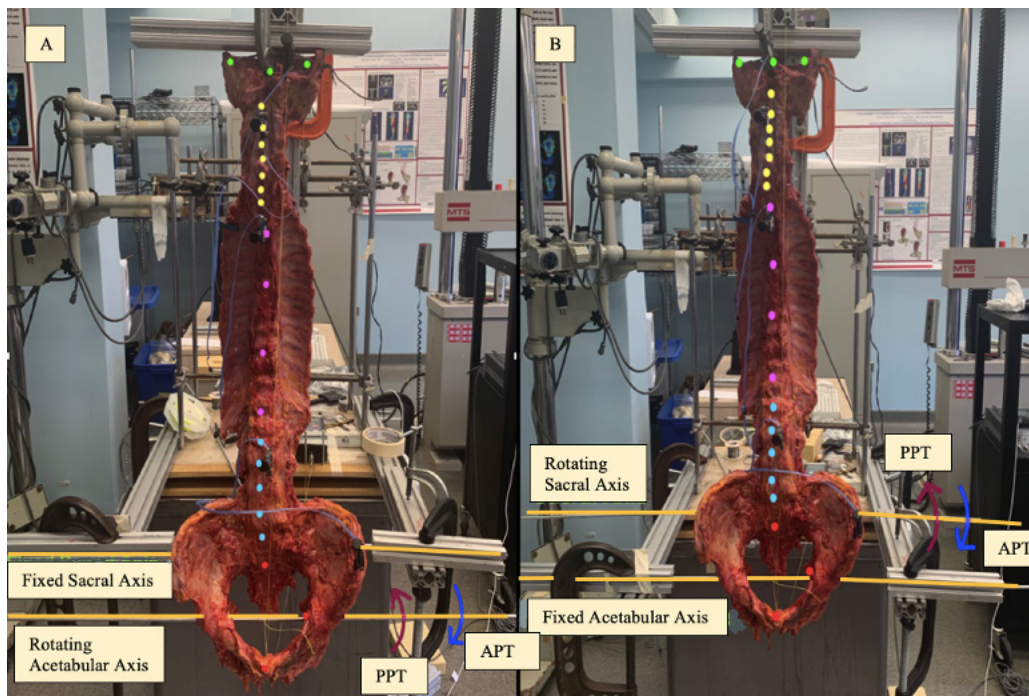
This is important because closed-chain exercises tend to be utilized early during rehabilitation, while some open-chain movements may be incorporated later.<sup>10-12</sup> In addition, understanding the effects of sagittal misalignment may aid spinal assessment before and after surgeries closely coupled to the spine, such as total hip arthroplasty.<sup>13</sup>

Our study uses an in vitro cadaveric spine model to simulate open- and closed-chain pelvic tilting in the anterior and posterior directions to assess the influence on cervical and lumbar spine kinematics.

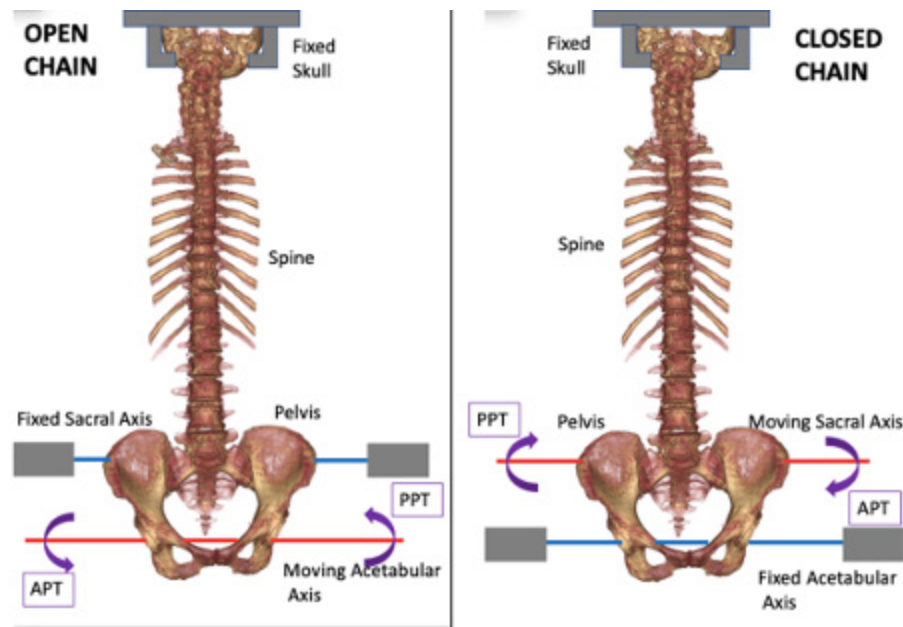
## METHODS

Three fresh-frozen human cadaveric spines, each with the pelvis and lower skull intact, were suspended and aligned in the center of a custom metal frame by fixing the skull superiorly and using wire and a metal rod passing through the sacral and acetabular (Acet) axis (Figure 1).

Before attachment on the frame, a hole was drilled through the pelvic ilium, passing through the upper part of the sacrum at the S1 level and exiting through the contralateral ilium. A rod was passed through the column to establish the sacral axis. A second hole was drilled in the center of each acetabulum, and a rod was passed through to set the Acet axis. Open-chain APT



**Figure 1.** Experimental setup: (A) coronal/front view with sacral axis fixed and (B) coronal/front view with acetabular axis fixed. The dots represent the digitized points taken for the Optotrak: 3 green dots for the skull, 7 yellow dots for the cervical spine vertebral body (VB), 4 pink dots for the thoracic spine VB, 5 blue dots for the lumbar spine VB, and 5 red dots for the sacrum and pelvis (only 3 seen in the frontal plane). APT, anterior pelvic tilt; PPT, posterior pelvic tilt.

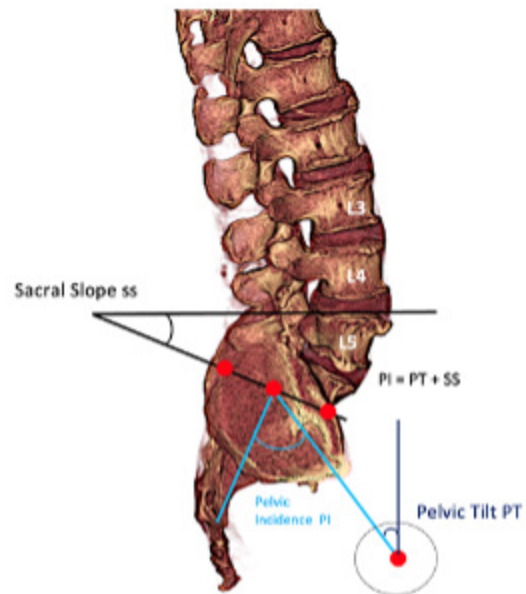


**Figure 2.** Simulated open- vs closed-chain movement. In open-chain movements (left image), the sacral axis is fixed, and the pelvis rotates using the acetabular axis. In closed-chain movements (right image), the acetabular axis is fixed, and the pelvis rotates using the sacral axis. APT, anterior pelvic tilt; PPT, posterior pelvic tilt.

and PPT were simulated by fixing the skull superiorly and the sacral axis inferiorly, allowing pelvic rotation to occur using a mobile Acet axis (Figure 2A). Our setup was based on the definition of an open kinetic chain as an open loop with 1 end free to move while the other end is fixed. Closed-chain APT and PPT were simulated by fixing the skull superiorly and the Acet axis inferiorly, allowing pelvic rotation to occur using a mobile sacral axis (Figure 2B). A closed kinetic chain, defined as a closed loop with both ends fixed, was the basis for our setup. The tilt range for each spine was standardized using a digital force gauge.

A 3-camera Optotrak Certus, placed in the sagittal plane of the spine, captured 3-dimensional coordinates for 24 digitized points along each cadaveric spine: 3 on the skull, 4 evenly spaced throughout the thoracic spine, 7 on the center of the anterior cervical vertebral bodies, 5 on the center of the anterior lumbar vertebral bodies, and 5 on the sacrum and pelvis (Figure 1 and Figure 3). The coordinates along the lumbar and cervical vertebral bodies were used to calculate intervertebral displacement during pelvic rotation. APT follows a counter-clockwise motion in the sagittal plane with computed angles represented by negative values. PPT follows a clockwise motion in the sagittal plane with computed angles represented by positive values. Kruskal Wallis test was used to assess differences in intervertebral displacements, and post hoc analysis was performed using pairwise comparison with Dunn-Bonferroni correction.

With the help of the digitized points, PT, sacral slope (SS), and pelvic incidence (PI) were calculated using the formula  $PI = PT + SS$ . As seen in Figure 3, PI was calculated by first finding the midpoint of the S1 vertebra, which was determined by dividing the distance between digitized points marking the anterior and posterior extent of the vertebra. A perpendicular line was passed through this



**Figure 3.** Visualization of how pelvic incidence (PI), pelvic tilt (PT), and sacral slope (SS) were determined. The red dots represent the digitized Optotrak points used to calculate these values.



midpoint, which is then connected by another line with the endpoint digitized at the acetabulum center to obtain the PI. A perpendicular line was passed through the Acet point to determine the PT, and the line connecting the acetabulum center to the S1 midpoint represents the PT angle. SS was later calculated with the PI formula (Figure 3).

## RESULTS

In closed-chain PPT, significant differences in relative intervertebral decompression displacement were noted between spinal levels C2/C3 (4.85 mm) and C5/C6 (1.26 mm) ( $P < 0.05$ ). At the lumbar level, significant differences in relative intervertebral compression displacement were noted between spinal levels L1/L2 (-2.54 mm) and L5/S1 (-11.84 mm) and between L3/L4 (-2.78 mm) and L5/S1 (-11.84 mm) ( $P < 0.05$  for both). On the contrary, in open-chain PPT, no significant differences in relative intervertebral displacement were noted at cervical or lumbar spinal levels. When comparing closed-chain PPT with open-chain PPT, intervertebral decompression displacement was significantly greater during closed chain at the cervical spine levels C2/C3 (4.85 vs 1.20 mm) and C3/C4 (3.48 vs 1.39 mm) ( $P < 0.05$ ) (Figure 4A). At lumbar spinal levels, intervertebral compression during closed-chain PPT was significantly greater than open-chain PPT at L1/L2 (-2.54 vs -0.69 mm), L2/L3 (-6.99 vs -0.43 mm), L3/L4 (-2.78 vs -1.17 mm), and L4/L5 (-6.10 vs -0.40 mm) ( $P < 0.05$  for all) (Figure 4B).

In closed-chain APT, significant differences in relative intervertebral decompression displacement were noted between spinal levels L1/L2 (2.87 mm) and L5/S1 (24.48 mm) and between L3/L4 (2.94 mm) and L5/S1 (24.48 mm) ( $P < 0.05$  for both). In open-chain APT, significant differences in relative intervertebral decompression displacement existed between spinal levels L4/L5 (1.53 mm) and L5/S1 (25.14 mm) and between L2/L3 (1.68 mm) and L5/S1 (25.14 mm) ( $P < 0.05$  for both) (Figure 5). No significant differences in intervertebral compression displacement were noted at cervical spinal levels during either open- or closed-chain APT. When comparing APT closed- and open-chain movements, no significant differences in relative intervertebral displacement were noted at lumbar or cervical spinal levels.

PI angles were calculated for the 3 spines about both Acet and sacral axes, and each axis underwent APT and PPT. Thus, we had 4 PI graphs for each spine: Acet APT, Acet PPT, sacral APT, and sacral

PPT. Figure 6 shows the change in SS, PT, and PI values when the intact spine moves from a neutral position (blue graphs) to maximum PT (orange graphs). As seen in the figures, the PI remained the same before and after the PT but then changed in the values of SS as the PT adjusted from neutral to maximum APT or PPT. Thus, there was a reciprocal relationship between PT and SS, with an increase in PT leading to a decrease in SS and a decrease in PT leading to a rise in SS.

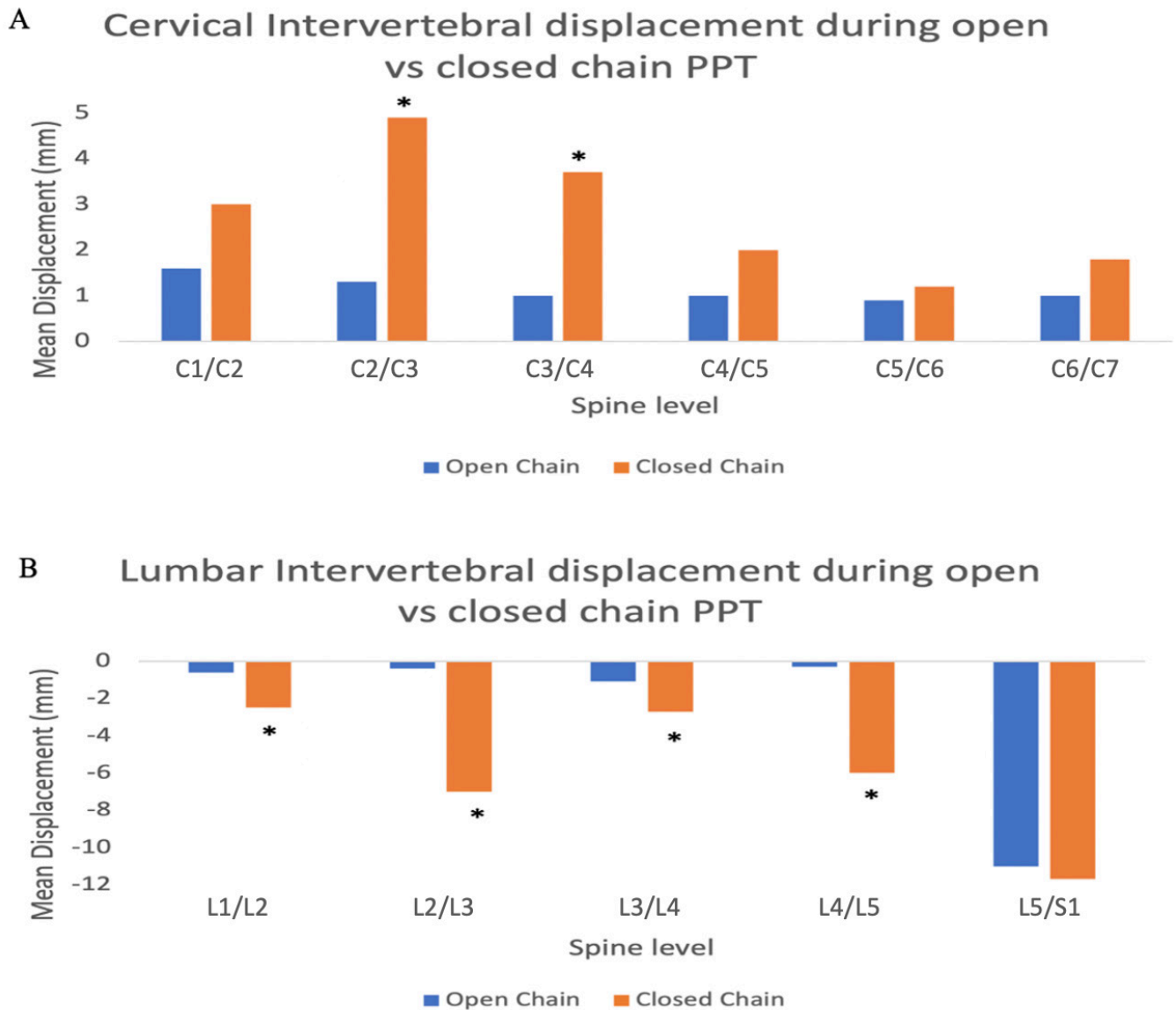
## DISCUSSION

This study's data showed that overall, open-chain PTs did not produce as much cervical and lumbar intervertebral displacement compared with closed-chain PTs. This is consistent with what was expected, given that open-chain movements allow joints to move independently from other segments of the body.<sup>14</sup>

When the spine acts as a closed chain, usually when sitting, standing, and during normal daily activities, other portions of the spine can be easily displaced during an excessive PT. This study showed that during PPT, similar to what is seen in ASD, both cervical and lumbar portions of the spine showed significant intervertebral displacement. Cervical displacement can be seen to decompress, whereas lumbar displacement shows compression between the vertebra, illustrating that most stress may be transitioned to the lumbar portion of the spine. Alternatively, open-chain posterior tilting of the pelvis produced minimal intervertebral displacement in the cervical and lumbar regions. The 1 exception was the space between L5 and S1, which had similar compression in both the closed and open chain.

Closed-chain APT is a condition similar to what is seen in CSM. Overall, the closed chain produced more displacement over the lumbar and cervical vertebra, but with no significant differences between the open and closed chain. The area of greatest decompression was the L5/S1 region, with the other lumbar vertebra showing slight decompression. The cervical region showed increased compression for both closed- and open-chain movements.

As mentioned earlier, an essential clinical example of a closed-chain spinal movement is seen in patients with sagittal imbalance caused by ASD,<sup>15</sup> a condition in the adult population that affects the thoracic or thoracolumbar spine.<sup>16</sup> The compensatory responses by the body due to sagittal imbalance from ASD have been researched and well described. Studies have shown that one of the first skeletal adjustments during ASD is the degenerative loss of lumbar lordosis, which produces

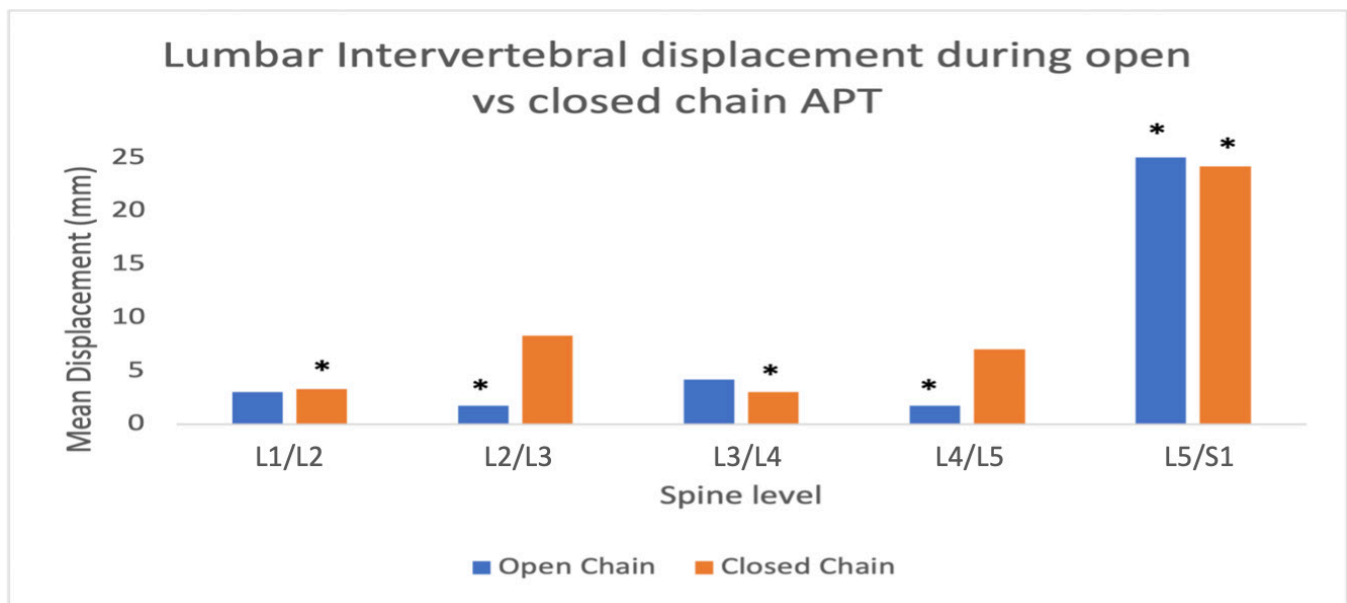


**Figure 4.** Cervical (graph A) and lumbar (graph B) intervertebral displacement in an open-chain and closed-chain pelvic tilt. Asterisk indicates significant differences between open- and closed-chain posterior pelvic tilt (PPT) at a specific spinal level. (A) Intervertebral decompression during closed-chain PPT was significantly greater than open-chain PPT at the cervical spine levels C2/C3 (4.85 vs 1.20 mm) and C3/C4 (3.48 vs 1.39 mm) ( $P < 0.05$ ). (B) Intervertebral compression during closed-chain PPT was significantly greater than open-chain PPT at L1/L2 (-2.54 vs -0.69 mm), L2/L3 (-6.99 vs -0.43 mm), L3/L4 (-2.78 vs -1.17 mm), and L4/L5 (-6.10 vs -0.40 mm) ( $P < 0.05$  for all).

a retroversion of the pelvis and, therefore, a posterior pelvic shift to bring the head alignment posterior over the sacrum<sup>17,18</sup> (negative sagittal alignment). This PPT may also produce compensatory reductions in the natural thoracic kyphosis to keep the head aligned in a closed chain after the loss of lumbar lordosis.<sup>19</sup> This loss of lumbar lordosis coupled with a PPT aligns with the compression displacement noted at lumbar levels in this study. This compression was shown to be much more significant at almost all lumbar levels during closed-chain movements. The anterior lumbar spine compression produced an almost complete loss

of lumbar lordosis. Additionally, the decompression seen in this study at several cervical spinal levels may indicate that the cervical spine should be more closely examined before surgical correction in ASD patients to determine if patients may develop a postoperative cervical deformity after surgery.<sup>20</sup>

Patients experiencing ASD, who may compose up to 68% of the population, typically exhibit pain and may become disabled due to the increased stress shifted to other areas of the body to regain pelvic balance.<sup>21</sup> Because ASD may produce disruption to spinal alignment in 3 dimensions, the focus has previously been on



**Figure 5.** Lumbar intervertebral displacement in open- and closed-chain anterior pelvic tilt (APT). Since there were no significant differences between open and closed chains, asterisks indicate significant differences between spinal levels within either open or closed chains. In closed-chain APT, significant differences in relative intervertebral decompression displacement were noted between spinal levels L1/L2 (2.87 mm) and L5/S1 (24.48 mm) and between L3/L4 (2.94 mm) and L5/S1 (24.48 mm) ( $P < 0.05$  for both). In open-chain APT, significant differences in relative intervertebral decompression displacement existed between spinal levels L4/L5 (1.53 mm) and L5/S1 (25.14 mm) and between L2/L3 (1.68 mm) and L5/S1 (25.14 mm) ( $P < 0.05$  for both).

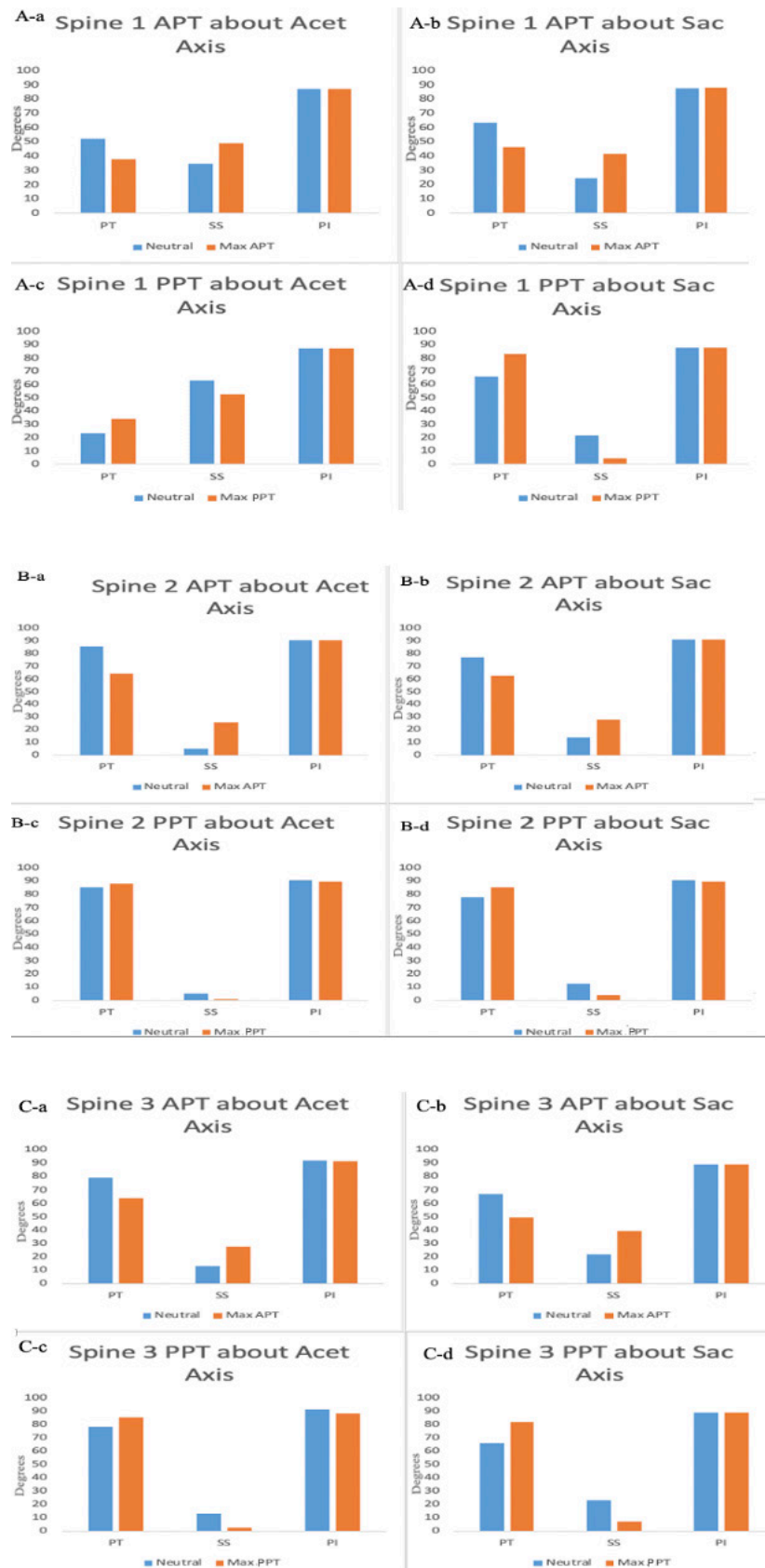
correcting the coronal plane alignment; however, more recent research has suggested the improvement of sagittal plane imbalance is just as significant to a patient's recovery.<sup>21,22</sup>

Patients with ASD have generally been encouraged to seek medical/interventional treatment before considering surgical options; however, results from these interventions are not well studied as to their efficacy.<sup>23</sup> Typically, patients are indicated for surgery when there is persistent low back/leg pain, the appearance of neurological symptoms, or a progressive decline of spinal balance in the sagittal and coronal plane significantly affecting the activities of daily living. Decompression and fusion are procedures most often used to correct misalignments in ASD patients. Decompression alone can be appropriate for patients with minimal spinal degeneration and low instability. In contrast, a combined decompression and fusion procedure can be used in patients with more severe conditions.<sup>22</sup> Despite increased complication rates, surgical intervention is especially beneficial for older patients by providing better pain relief, decreased disability, and improved quality of life.<sup>24</sup>

Another previously mentioned spinal cord condition that produces a sagittal misalignment is CSM, the most common cause of myelopathy in adults older than 55 years old.<sup>25</sup> A degenerative condition characterized by compression of the cervical spinal cord,<sup>26,27</sup> CSM can be asymptomatic or present with radiculopathy if

cervical nerve roots become affected,<sup>28</sup> and/or myelopathic symptoms such as gait instability, fine motor dysfunction, or proximal weakness. Because of the cervical spine breakdown, these patients have been shown to exhibit a smaller cervical lordosis.<sup>8</sup> This disruption to healthy alignment manifests as an increased APT and a more significant lumbar lordosis, all to re-establish a closed-chain center of gravity that keeps the head upright.<sup>29</sup> This significant increase in lumbar lordosis is consistent with our study results showing anterior relative decompression at several lumbar spinal levels. This decompression was most significantly seen in the L5/S1 level. It did not change with closed- or open-chain movements, indicating this change in lumbar spine curvature was consistent across many different activities, situations, and body movements. Our results indicated no relative differences in cervical intervertebral displacement, potentially showing that any compression seen in the cervical spine was uniform and not affected by closed- vs open-chain movements.

Even more so than ASD, the literature regarding the treatment of CSM lacks the comparison of conservative and surgical treatment.<sup>30</sup> Surgical intervention can be varied, including several different anterior, posterior, or combined approaches. Surgery is typically offered to patients to decompress the cervical spinal cord halt any further neurologic decline. However, with multiple techniques available, the surgical decision is derived from surgeon expertise and patient's specific anatomy



**Figure 6.** Bar graphs for pelvic tilt (PT), sacral slope (SS), and pelvic incidence (PI) for 3 spines. (A) (a–d) represent graphs for spine 1, (B) (a–d) represent graphs for spine 2, and (C) (a–d) represent spine 3. The graphs are represented for anterior pelvic tilt (APT) about acetabular (Acet) and sacral (Sac) axes and posterior pelvic tilt (PPT) about Acet and Sac axes. These bar graph values represent the concept  $PT + SS = PI$ .



and related pathology<sup>31</sup> to decompress the cord while restoring cervical alignment.

The results of this study illustrate how the spine adjusts during APT or PPT when someone is subjected to different spine motions about a different axis of rotation. Most of these regular activities are typically within a closed chain. Our results show that the difference in open- and closed-chain movements with APT may not significantly differ in how the spinal segments adapt. However, with PPT, our results indicate that the closed-chain movements can produce much more vertebral movement and discomfort for the patient when compared with open-chain movements. These kinematic results suggest that both the lumbar and cervical spine are affected differently with posterior tilt when comparing between adjacent vertebral segments and between open- and closed-chain movements. Only the lumbar portions show different displacements within that specific spinal segment with no significant differences between the open and closed chains during anterior tilt. The results of this study may be helpful to determine how a patient's PT may cause impingement pathology or other pain in some regions of the spine, which can be used to determine which stabilizing muscles are essential to rehabilitating help provide support and restore alignment. The data produced here may also help determine which rehabilitation exercises may be more difficult or prone to injury for excessive anterior or posterior tilt patients.

A notable finding across both APT and PPT with both closed- and open-chain movements was the magnitude of intervertebral displacement seen in the L5/S1 segment. This region exhibited the largest displacement among all the spinal segments under study, which was an expected finding due to this segment being the transition point between lumbar and sacral spines, and the point where lumbar lordosis becomes sacral kyphosis. Loads are transferred to the pelvis at this point, putting higher degrees of biomechanical stress on the L5/S1 spinal segment.<sup>32</sup> Our results illustrate the susceptibility of this region by demonstrating intervertebral displacement that spans from approximately -12 mm during PPT to approximately 25 mm during APT, meaning this segment must translate stress under a large amount of displacement variability. We believe these results support existing evidence that this segment of the spine is most likely to exhibit degeneration and spinal injuries,<sup>33,34</sup> which may be due to the forces it must withstand throughout a wide range of intervertebral displacement during pelvic movements. Additionally, because of the range of motion needed in the L5/S1 segment for appropriate load transfer, the choice for L5/S1 spinal fusion should be carefully considered given the implications on spine biomechanics.

As seen from the PI graphs, during APT and PPT, PI remains the same as the spine moves from neutral to maximum PT. This is due to an interchangeable increase in PT and SS during the PT. When PT is high, the SS is on the lower end and vice versa. Our study abided well by the concept that PI is made up of PT and SS, as shown by the interchangeable nature of the SS and PT. We did not see a clear difference between the PI angles during APT and PPT when comparing movements about the Acet axis with that of the sacral axis. We expect this to be the case as more differences may be visible at the vertebral level than at the pelvic level when comparing the Acet vs the sacral axis of rotation.

## CONCLUSION

This study shows a detailed cervical and lumbar kinematic assessment in a simulated open and closed kinetic chain. The closed-chain PTs produced cervical and lumbar intervertebral displacements, whereas the open-chain PTs did not produce any significant displacements. The Acet axis, responsible for the open-chain movements, allows joints to move independently from other body segments. Still, the sacral axis, responsible for the closed-chain movements, created an interconnected chain, which resulted in pelvic movements causing significant changes in intervertebral joints of the spine. Understanding of these findings may help surgeons during evaluation and surgical planning in patients with ASD or CSM. It may also help in rehabilitation exercises in patients with variable pelvic alignment.

## REFERENCES

1. So-Hyun Park PT, Goon-Chang Yuk PT, Ahn S-H, et al. Lumbar spine kinematics during anterior and posterior pelvic tilting in supine and prone positions. *J Korean Phys Ther.* 2011;23(6):9–14.
2. Alderink GJ. The sacroiliac joint: review of anatomy, mechanics, and function. *J Orthop Sports Phys Ther.* 1991;13(2):71–84. doi:10.2519/jospt.1991.13.2.71
3. Malarvizhi D, Varma SK, SivakumarVPR. Measurement of anterior pelvic tilt in low back pain - an observational study. *Asian J Pharm Clin Res.* 2017;10(4):115. doi:10.22159/ajpcr.2017.v10i4.16254
4. Roussouly P, Nnadi C. Sagittal plane deformity: an overview of interpretation and management. *Eur Spine J.* 2010;19(11):1824–1836. doi:10.1007/s00586-010-1476-9
5. Barrey C, Roussouly P, Perrin G, Le Huec JC. Sagittal balance disorders in severe degenerative spine. Can we identify the compensatory mechanisms? *Eur Spine J.* 2011;20(Suppl 5):626–633. doi:10.1007/s00586-011-1930-3
6. Diebo BG, Ferrero E, Lafage R, et al. Recruitment of compensatory mechanisms in sagittal spinal malalignment is age and regional deformity dependent: a full-standing axis

analysis of key radiographical parameters. *Spine (Phila Pa 1976)*. 2015;40(9):642–649. doi:10.1097/BRS.0000000000000844

7. Savage JW, Patel AA. Fixed sagittal plane imbalance. *Global Spine J*. 2014;4(4):287–296. doi:10.1055/s-0034-1394126

8. Haddas R, Patel S, Arakal R, Boah A, Belanger T, KL J. Spine and lower extremity kinematics during gait in patients with cervical spondylotic myelopathy. *Spine J*. 2018;18(9):1645–1652. doi:10.1016/j.spinee.2018.04.006

9. Levine D, Whittle MW. The effects of pelvic movement on lumbar lordosis in the standing position. *J Orthop Sports Phys Ther*. 1996;24(3):130–135. doi:10.2519/jospt.1996.24.3.130

10. Sciascia A, Cromwell R. Kinetic chain rehabilitation: a theoretical framework. *Rehabil Res Pract*. 2012;2012:853037. doi:10.1155/2012/853037

11. Elgelid S. Musculoskeletal interventions: techniques for therapeutic exercise. *Phys Occup Ther Geriatr*. 2008;26(4):71–72. doi:10.1080/02703180801964053

12. Kibler WB, Livingston B. Closed-chain rehabilitation for upper and lower extremities. *J Am Acad Orthop Surg*. 2001;9(6):412–421. doi:10.5435/00124635-200111000-00006

13. Niemeier TE, Wills BW, Theiss SM, Strom SF. Sagittal pelvic kinematics in hip arthroplasty. *Curr Rev Musculoskelet Med*. 2020;13(3):240–246. doi:10.1007/s12178-020-09628-w

14. Thabet A, Alshehri MA, Helal OF, Refaat B. The impact of closed versus open kinetic chain exercises on osteoporotic femur neck and risk of fall in postmenopausal women. *J Phys Ther Sci*. 2017;29(9):1612–1616. doi:10.1589/jpts.29.1612

15. Uribe JS, Januszewski J, Wang M, et al. Patients with high pelvic tilt achieve the same clinical success as those with low pelvic tilt after minimally invasive adult deformity surgery. *Neurosurgery*. 2018;83(2):270–276. doi:10.1093/neuros/nyx383

16. Diebo BG, Shah NV, Boachie-Adjei O, et al. Adult spinal deformity. *The Lancet*. 2019;394(10193):160–172. doi:10.1016/S0140-6736(19)31125-0

17. Ferrero E, Liabaud B, Challier V, et al. Role of pelvic translation and lower-extremity compensation to maintain gravity line position in spinal deformity. *J Neurosurg Spine*. 2016;24(3):436–446. doi:10.3171/2015.5.SPINE14989

18. Lafage V, Schwab F, Patel A, Hawkinson N, Farcy JP. Pelvic tilt and truncal inclination: two key radiographic parameters in the setting of adults with spinal deformity. *Spine (Phila Pa 1976)*. 2009;34(17):E599–E606. doi:10.1097/BRS.0b013e3181aad219

19. Protosaltis TS, Diebo BG, Lafage R, et al. Identifying thoracic compensation and predicting reciprocal thoracic kyphosis and proximal junctional kyphosis in adult spinal deformity surgery. *Spine (Phila Pa 1976)*. 2018;43(21):1479–1486. doi:10.1097/BRS.00000000000002843

20. Passias PG, Soroceanu A, Smith J, et al. Postoperative cervical deformity in 215 thoracolumbar patients with adult spinal deformity: prevalence, risk factors, and impact on patient-reported outcome and satisfaction at 2-year follow-up. *Spine (Phila Pa 1976)*. 2015;40(5):283–291. doi:10.1097/BRS.0000000000000746

21. Makhni MC, Shillingford JN, Laratta JL, Hyun SJ, Kim YJ. Restoration of sagittal balance in spinal deformity surgery. *J Korean Neurosurg Soc*. 2018;61(2):167–179. doi:10.3340/jkns.2017.0404.013

22. Youssef JA, Orndorff DO, Patty CA, et al. Current status of adult spinal deformity. *Global Spine J*. 2013;3(1):51–62. doi:10.1055/s-0032-1326950

23. Ames CP, Scheer JK, Lafage V, et al. Adult spinal deformity: epidemiology, health impact, evaluation, and management. *Spine Deform*. 2016;4(4):310–322. doi:10.1016/j.jspd.2015.12.009

24. Good CR, Auerbach JD, O'Leary PT, Schuler TC. Adult spine deformity. *Curr Rev Musculoskelet Med*. 2011;4(4):159–167. doi:10.1007/s12178-011-9101-z

25. de Oliveira Vilaça C, Orsini M, Leite MAA, et al. Cervical spondylotic myelopathy: what the neurologist should know. *Neurol Int*. 2016;8(4):6330. doi:10.4081/ni.2016.6330

26. Young WF. Cervical spondylotic myelopathy: a common cause of spinal cord dysfunction in older persons. *Am Fam Physician*. 2000;62(5):1064–1070. .

27. Emery SE. Cervical spondylotic myelopathy: diagnosis and treatment. *J Am Acad Orthop Surg*. 2001;9(6):376–388. doi:10.5435/00124635-200111000-00003

28. Toledano M, Bartleson JD. Cervical spondylotic myelopathy. *Neurol Clin*. 2013;31(1):287–305. doi:10.1016/j.ncl.2012.09.003

29. Haddas R, Lieberman I, Arakal R, Boah A, Belanger T, Ju K. Effect of cervical decompression surgery on gait in adult cervical spondylotic myelopathy patients. *Clin Spine Surg*. 2018;31(10):435–440. doi:10.1097/BSD.0000000000000719

30. Bakhsheshian J, Mehta VA, Liu JC. Current diagnosis and management of cervical spondylotic myelopathy. *Global Spine J*. 2017;7(6):572–586. doi:10.1177/2192568217699208

31. Iyer A, Azad TD, Tharin S. Cervical spondylotic myelopathy. *Clin Spine Surg*. 2016. doi:10.1097/BSD.0000000000000397

32. Dramer GD. *Clinical Anatomy of the Spine, Spinal Cord, and ANS*. Mosby; 2014.

33. Saleem S, Aslam HM, Rehmani MAK, Raees A, Alvi AA, Ashraf J. Lumbar disc degenerative disease: disc degeneration symptoms and magnetic resonance image findings. *Asian Spine J*. 2013;7(4):322–334. doi:10.4184/asj.2013.7.4.322

34. Donnally CJ, Butler AJ, Varacallo M. *Lumbosacral Disc Injuries*. StatPearls Publishing; 2020.

**Funding:** The authors received no financial support for the research, authorship, and/or publication of this article.

**Declaration of Conflicting Interests:** The authors report no conflicts of interest in this work.

**Disclosures:** Mark Mikhael discloses that he received consultant fees from Clariance Spine and royalties from Oxford University for textbook editing. The remaining authors have nothing to disclose.

**Corresponding Author:** Farid Amirouche, Department of Orthopaedic Surgery, College of Medicine, University of Illinois at Chicago, 835 S. Wolcott, E-190 MSB MC 844, Chicago, IL 60612, USA; amirouch@uic.edu

Published 27 October 2022

This manuscript is generously published free of charge by ISASS, the International Society for the Advancement of Spine Surgery. Copyright © 2023 ISASS. To see more or order reprints or permissions, see <http://ijssurgery.com>.