

Lateral Lumbar Interbody Fusion Using Expandable vs Static Titanium Interbody Cages: A Prospective Cohort Study of Clinical and Radiographic Outcomes

Cecilia W. Huo, Gregory M. Malham, Dean T. Biddau, Timothy Chung and Yi Yuen Wang

Int J Spine Surg 2023, 17 (2) 265-275

doi: <https://doi.org/10.14444/8422>

<http://ijssurgery.com/content/17/2/265>

This information is current as of April 19, 2024.

Email Alerts Receive free email-alerts when new articles cite this article. Sign up at:
<http://ijssurgery.com/alerts>

Errata An erratum has been published regarding this article. Please see [next page](#) or:
</content/18/1/117.full.pdf>

Lateral Lumbar Interbody Fusion Using Expandable vs Static Titanium Interbody Cages: A Prospective Cohort Study of Clinical and Radiographic Outcomes

CECILIA W. HUO, PhD¹; GREGORY M. MALHAM, FRACS^{2,3}; DEAN T. BIDDAU, BBIOMEDSC^{2,3}; TIMOTHY CHUNG, MBBS⁴; AND YI YUEN WANG, FRACS^{2,5,6}

¹Department of Neurosurgery, The Royal Melbourne Hospital, Melbourne, VIC, Australia; ²Neuroscience Institute, Epworth Hospital, Melbourne, VIC, Australia; ³Spine Surgery Research, Swinburne University of Technology, Melbourne, VIC, Australia; ⁴Department of Orthopedic surgery, The Royal Melbourne Hospital, Melbourne, VIC, Australia; ⁵Department of Neurosurgery, St Vincent's Hospital, Melbourne, VIC, Australia; ⁶Department of Surgery, The University of Melbourne, VIC, Australia

ABSTRACT

Background: Expandable cages are a recent development employed to reduce subsidence and improve fusion compared with static cages as they alleviate the need for repeated trialing or overdistraction of the disc space. This study aimed to compare the radiographic and clinical outcomes in patients undergoing lateral lumbar interbody fusion (LLIF) with either an expandable or static titanium cage.

Methods: This was a prospective study of 98 consecutive patients undergoing LLIF performed over a 2-year period, with the first 50 patients receiving static cages and the following 48 receiving expandable cages. Radiographic evaluation included interbody fusion status, cage subsidence, and change in segmental lordosis and disc height. Clinical evaluation assessed patient-reported outcome measures (PROMs), including the Oswestry Disability Index, visual analog scale (VAS) for back and leg pain, and short form-12 physical and mental health survey scores collected at 3, 6, and 12 months postoperatively.

Results: The 98 patients had 169 cages impacted (84 expandable vs 85 static). Mean age was 69.2 years, and 53.1% were women. There was no significant difference between the 2 groups in terms of age, gender, body mass index, or smoking status. The expandable cage group had higher rates of interbody fusion (94.0% vs 82.9%, $P = 0.039$) at 12 months as well as significantly reduced implant subsidence rates at all follow-up timepoints (4% vs 18% at 3 months; 4% vs 20% at 6 and 12 months). Patients from the expandable cage group showed a mean 1.9 more points of reduction in VAS back pain ($P = 0.006$) and 2.49 points greater reduction in VAS leg pain ($P = 0.023$) at 12-month follow-up.

Conclusions: Expandable lateral interbody spacers resulted in significantly improved fusion rates with reduced subsidence risks and statistically significant improvement in PROMs up to 12 months postoperatively compared with impacted lateral static cages.

Clinical Relevance: The data provide clinical relevance in favoring expandable cages over static cages for enhanced fusion outcomes in lumbar fusions.

Level of Evidence: 2.

Lumbar Spine

Keywords: expandable cage, radiographic outcomes, fusion rate, subsidence, lateral Lumbar interbody fusion, spine surgery

INTRODUCTION

Modern interbody fusion techniques treat degenerative lumbar conditions that have failed to respond to conservative treatment, such as spondylolisthesis, disc disease, or neural compression, whereby decompression alone may result in instability. The main approaches include minimally invasive surgery transforaminal lumbar interbody fusion, posterior lumbar interbody fusion, anterior lumbar interbody fusion, or lateral lumbar interbody fusion (LLIF). Each method has its strengths and drawbacks. By accessing the intervertebral disc space via a lateral surgical corridor, LLIF not only has the advantages of preserving segmental

stabilizing elements such as anterior longitudinal ligament, posterior longitudinal ligament, ligamentum flavum, and the facets, but it also eliminates the need for nerve root retraction and avoids the risk of iatrogenic nerve root injury.¹ Minimally invasive LLIF allows for a wide endplate preparation area and large footprint cage insertion that can achieve desirable segmental lordosis.² However, LLIF may place the lumbar plexus at risk via its transpsoas surgical trajectory and can be limited by a high-rising iliac crest.³ Regardless of the approach, the core principle in lumbar fusion lies in the utilization of an interbody cage filled with bone substitute or graft to achieve fusion of the opposing vertebral endplates for

structural stability and to restore sagittal alignment and disc and foraminal height.⁴⁻⁷

Impacted static intervertebral lumbar cages were first introduced by Bagby and Kuslich in the 1990s⁸ and have undergone technical advancement aimed at reducing morbidities associated with the surgical approach.^{9,10} Excessive trialing and repeated impaction causing endplate violation have been associated with reduced fusion rates and cage subsidence.^{9,10} Vertically expandable cages first appeared on the market in the early 2000s¹¹ in an attempt to circumvent some of the limitations inherent to the static cages. They are inserted into the disc space in a collapsed configuration, which abolishes the need for repeated trialing or other maneuvers to expand the disc space. They are then expanded in situ to achieve the optimal disc height and segmental lordosis.¹² Theoretically, expandable cages minimize endplate trauma and should reduce the risk of subsidence,¹³ yet results are mixed on whether expandable cages are associated with better patient outcomes than static cages.¹⁴⁻¹⁹ Interbody cages are mostly polyetheretherketone (PEEK) or titanium (Ti) cages that differ in biomechanical properties, endplate osteointegration, and radiolucency for assessment of fusion.²⁰⁻²² Thus, to control for these variables, we evaluated Ti lateral cages. In this study, we aimed to compare the radiographic and clinical outcomes after LLIF using expandable vs static Ti cages.

METHODS

Study Design and Patient Population

This was a multicenter prospective cohort study with institutional ethics committee approvals obtained (St Vincent's Hospital Quality Assurance reference number: 21036; Epworth HealthCare Ethics approval: Professor Nikolas Zeps, Group Director of Research and Development). Ninety-eight consecutive patients underwent LLIF, with a total of 169 operative levels performed between December 2018 and February 2021 by 2 senior spinal fellowship trained neurosurgeons using the same surgical techniques. Informed consents were obtained from all patients. The first 50 patients received static interbody cages, and the following 48 patients had expandable interbody spacers. The patient selection criteria are detailed in Table 1.

Surgical Technique

Patients were given general anesthesia and placed in the lateral decubitus position on a radiolucent operating table. Fluoroscopy was utilized to plan the skin incision

Table 1. Inclusion and exclusion criteria for patient recruitment.

Inclusion Criteria	Exclusion Criteria
<ul style="list-style-type: none"> • Adult patients (≥18 y old) • Symptomatic degenerative lumbar spondylolisthesis unresponsive to conservative management for at least 6 mo • Undergoing lateral lumbar interbody fusion 	<ul style="list-style-type: none"> • Patients with active infection or malignancy • Significant osteoporosis • Previous lumbar spine surgery • Previous spinal trauma

and confirm the targeted disc segment. First, an oblique small skin incision was made along Langer's lines with dissection through the lateral abdominal wall muscle layers under direct vision. The psoas major muscle was then safely traversed using neuromonitoring to dock the retractor and expose the lateral annulus of the targeted intervertebral disc space. Where neuromonitoring was deemed unsafe, the retractor was repositioned via a more anterior placement, allowing posterior retraction of the psoas muscle prior to docking of the retractor. Subsequent clearance of the disc space was performed with sequential annulotomy, discectomy, and endplate preparation in the orthogonal plane, followed by cage insertion. When using a static cage, the intervertebral space was gradually distracted by the impaction of trials that were incremental in size by 2 mm each. The optimal height of the cage was achieved when there was a firm fit and restoration of lumbar lordosis shown on lateral intraoperative radiographs. The selected cage was then inserted into the disc space, prepacked with bone graft. When using an expandable cage, the spacer was inserted in a collapsed configuration (7 mm height; prepacked with bone graft), which was then expanded in situ to achieve the optimal endplate-to-endplate contact, followed by backfilling with bone graft.

For both cage groups, the bone graft used was a combination of recombinant human bone morphogenic protein-2 (BMP-2; 1.5 mg/mL) applied to an absorbable collagen sponge (Infuse; Medtronic, Inc., Memphis, TN, USA), which was trimmed to the cage volume and allograft (Grafton Crunch, Medtronic). The Infuse dose used per level was volume-dependent (ie, the internal cage volume equaled BMP volume in cc). A small kit of BMP (2.8 cc providing a 4.2-mg dose) was used as per the manufacturer's recommendation, following a 1-hour absorption into the carrier period.²³ No Infuse was placed outside the cage. The second stage of the operation involved positioning patients prone for minimally invasive pedicle screw fixation secured with rods and caps. Intraoperative fluoroscopy was used to confirm the position of the implants.

Table 2. RISE-L cage adjustable lordosis expansion range.

Drive screw revolutions	0	2	4	6	8	10	12	14
Anterior height, mm	7	8	9	10	11	12	13	14
Posterior height, mm	6.0	6.5	6.9	7.4	7.9	8.3	8.8	9.3
Lordotic angle	3°	4.7°	6.4°	8.1°	9.8°	11.5°	13.2°	15°

Source: Globus Medical Inc.

Interbody Cages

The expandable interbody spacer used in this study was the Ti RISE-L (Globus Medical, Inc., Audubon, PA), and the static cage used was the Ti Modulus XLIF (NuVasive, Inc., San Diego, CA). RISE-L is loaded with a torque-limited driver, allowing a maximum of 3 N·m force to prevent overexpansion. The anterior expansion ranged from 7 to 14 mm, with corresponding rises in posterior height and lordotic angle (Table 2). The RISE-L allowed for backfilling of bone graft post cage expansion via a funnel reaching the lateral aperture of the cage. The expansion is uniplanar in the craniocaudal direction, with its surface area size coming in fixed options of 45, 50, 55, and 60 mm, just as Modulus. In both groups, the footprint of the cage selected aimed to maximize endplate of the apophyseal ring, by the use of trials visualized on intraoperative anterior-posterior radiographs. With regard to cage height and lordotic angle, Modulus provided a choice of anterior height of 8, 10, or 12 mm, with a cage lordosis of 10° or 15°.

Clinical Outcomes

Clinical metrics included patient self-reported outcome measures by the Oswestry Disability Index (ODI), the visual analog scale (VAS) for back and leg pain, the short form-12 (SF -12; both physical and mental components) surveys that were evaluated preoperatively as baseline and then at 3, 6, and 12 months postoperatively. The minimum clinically important

difference relative to baseline for VAS is at least a 2-point reduction in pain severity, a 15-point reduction in ODI score, and a 5.7-point increase for physical component score (PCS) or mental component score (MCS).²⁴⁻²⁶

Radiographic Outcomes

All patients underwent high-definition, low-dose computed tomography (CT) images preoperatively and 2 days postoperatively to assess cage and instrumentation positioning and at 6 and 12 months until solid interbody fusion was confirmed on coronal and sagittal views. To reduce the radiation exposure, no scans were performed after confirming interbody fusion. Fusion was defined as bridging interbody trabecular bone on coronal and sagittal views.²³ Radiographic parameters also assessed by CT included pre- and postoperative disc height, segmental lordosis, and presence of subsidence²⁷ and its type.²⁸ The definitions of these metrics are listed in Table 3. An independent radiologist and independent senior neurosurgeon interpreted the CT results with high interobserver reliability ($r^2 > 0.87$). When the differences in measurements were < 3 mm or 3° , the mean of the 2 measurements was taken as the final value. When the differences exceeded 3 mm or 3° , a third reviewer was involved and the mean of the 2 closest measurements was used as the final value.

Table 3. Definitions of radiographic parameters for outcome measurement.

Radiographic Parameters	Definition
Fusion status	The Bridwell interbody fusion grading system: Grade 1: fused with remodeling and trabeculae present Grade 2: graft intact, not fully remodeled and incorporated, but no lucency present Grade 3: graft intact, potential lucency present at top and bottom of the graft Grade 4: fusion absent with collapse/resorption of graft
Subsidence	Loss of disc height by > 2 mm compared with 6-wk postoperative disc height, as measured from the vertebral endplate to the caudal or cranial margin of the cage
Subsidence type	Type 1: cage subsidence into the contralateral caudal endplate without anterior cage tilt Type 2: bilateral cage subsidence into the anterior aspect of the caudal endplate, producing an anterior tilt of the cage Type 3: cage subsidence into both the caudal and cranial endplates bilaterally without cage tilt
Index-level segmental lordosis	The angle between the inferior endplate of the caudal vertebral body to the superior endplate of the cephalad vertebral body of the fusion segment
Anterior disc height	The distance at the most anterior point of the vertebral body from endplate to endplate
Posterior disc height	The distance at the most posterior point of the vertebral body from endplate to endplate, as a surrogate marker for foraminal height

Table 4. Patient demographic and perioperative characteristics.

Characteristic	Expandable Cage (n = 48)	Static Cage (n = 50)	P Value
Patient Demographics			
Age, y, mean (range, SD)	71.2 (43–84, 8.5)	67.2 (27–89, 13.2)	0.143
Sex, n (%)			0.838
Men	21 (43.8)	25 (50.0)	
Women	27 (56.2)	25 (50.0)	
Body mass index, mean (range, SD)	28.7 (18–39, 4.3)	28.5 (18–46, 5.5)	0.567
Current smoker, n (%)			0.618
Yes	0	3 (6.0)	
No	45 (93.8)	44 (88.0)	
Unknown	3 (6.2)	3 (6.0)	
Operative Characteristics			
Operated spinal segments n (%)			>0.999
Single level	35 (52.0)	34 (56.0)	
2 Levels	10 (36.0)	12 (28.0)	
3 Levels or more	3 (12.0)	4 (16.0)	
Treated lumbar segments, n (%)			0.308
L1-L2	7 (9.3)	5 (7.3)	
L2-L3	18 (27.9)	15 (24.4)	
L3-L4	28 (41.9)	22 (34.1)	
L4-L5	13 (20.9)	27 (34.1)	
Radiographic Parameters			
Preoperative disc height, mm, mean (range, SD)			
Anterior	6.0 (1–11.5, 2.5)	6.4 (1–19.2, 3.4)	0.251
Posterior	3.4 (1–5.9, 1.1)	3.3 (1–7.0, 1.5)	0.834
Postoperative disc height, mm, mean (range, SD)			
Anterior ^a	10.0 (6.8–14.0, 1.8)	9.4 (8–12, 2.3)	0.004
Posterior	5.8 (3–8.5, 1.1)	5.3 (1.1–9.2, 1.4)	0.121
% Increase in disc height postoperative, mean (range, SD)			
Anterior disc height	242.8 (99–1180, 178.6)	238.9 (69.5–1130, 230.8)	0.114
Posterior disc height	193.5 (89.7–541.7, 91.06)	203.6 (56.9–650, 140.4)	0.266
Postoperative change in segmental lordosis degrees, mean (range, SD)	3.6 (–3.6 to 19.2, 4.2)	3.3 (–8.4 to 14.6, 4.2)	0.947

^aRefers to expanded final height in the expandable cage group, whereas static cages were of 8, 10, or 12 mm in height. Total levels decompressed for the expandable group: 84; for the static group: 85.

Statistical Methods

All tests were performed in GraphPad, Prism software. Normality was assessed using the D'Agostino-Pearson omnibus normality test. For parametric data, unpaired *t* test was used to determine whether there was any difference between the expandable cage and the static cage groups; for nonparametric data, the Mann-Whitney test was utilized. All statistical tests were 2-sided with statistical significance set at *P* value <0.05.

RESULTS

Patient Demographic and Operative Characteristics

The patient demographic features for both cage groups were comparable, as shown in Table 4. The expandable cage group comprised 56% women with a mean age of 71.2 years, while the static cage group had an equal gender distribution with a younger mean age of 67.2 years. Both groups had a mean body mass index of 28, with the majority of patients (88% in static and 93.8% in expandable) being nonsmokers. The most

common surgical indication was central canal or foraminal stenosis with or without intervertebral disc disease. There was no significant difference in the pattern of spinal pathologies between the groups, as illustrated in Figure 1A (error bar indicates mean with SD). No patients were lost to follow up at 12 months postoperatively.

The operative characteristics were again similar for both cage groups (Table 4), with just over half of the patients undergoing single-level LLIF (52% in expandable vs 56% in static). Surgery was the most common at the L3-L4 level (41.9%) followed by L2-L3 (27.9%) in the expandable group, while L3-L4 and L4-L5 were both the most common targeted levels (34.1%) in the static group. The difference in the mean postoperative anterior cage height between the 2 groups was small (0.6 mm) yet statistically significant (*P* = 0.004) (Table 4), with the range of final heights achieved in the expandable group being broader than the 3 fixed options available for the static cage group (Figure 1B, error bar indicates mean with SD).

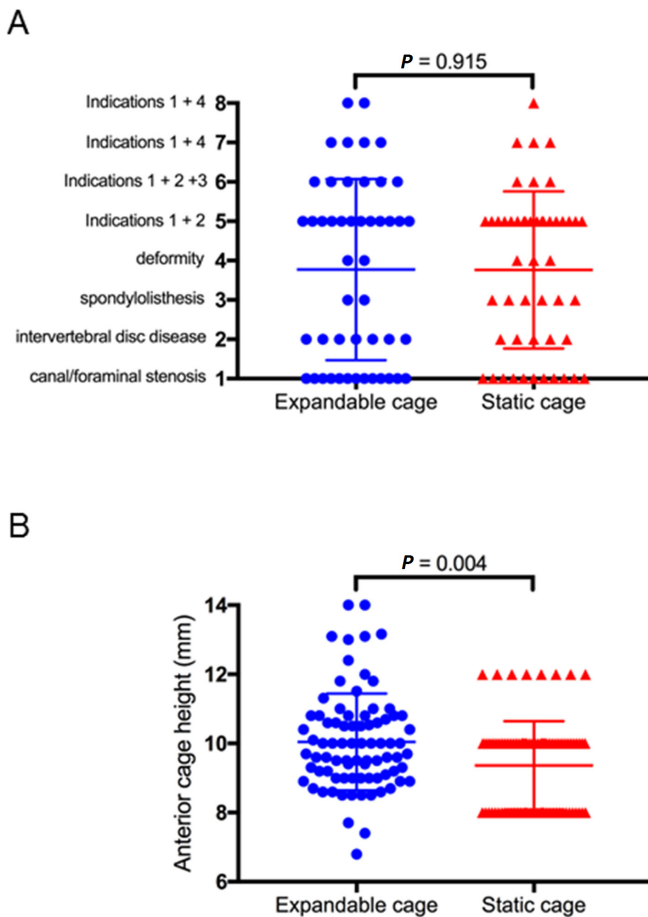


Figure 1. Surgical indications and cage heights. (A) Numerical numbers were assigned to different pathologies as shown, for which the operations were performed in each study group. (B) Postoperative anterior cage height was measured in millimeters for each study group. Error bar indicates standard error of the mean.

Radiographic Outcomes

As detailed in Table 4, the mean increases in the expandable group for anterior and posterior disc height were 5.3 and 2.3 mm, respectively, which were not significantly higher than that of the static group (4.4 mm increase for anterior and 1.9 mm increase for posterior). The postoperative segmental lordosis was comparable (3.5° increase in expandable vs 3.1° increase in static) for both cohorts. Bone interbody fusion (Bridwell grade 1) shown by CT (Figure 2A) was 64.8% in the expandable group at 6 months and increased to 94.0% at 12 months. In contrast, 58.5% in the static group fused at 6 months, and the percentage reached 82.9% by 12 months. The difference in fusion grades was statistically significant ($P = 0.039$) at 12 months.

Radiographic subsidence was seen in 2 patients from the expandable group at 3 months; both received conservative treatment. In comparison, 9 patients in the static group showed cage subsidence at 3 months and 1 more patient at 6 months. Five of these 10 patients

from the static group needed reoperations for extension of fusion subsequently. The distinction in subsidence rates between the 2 cage groups was statistically significant at 3, 6, and 12 months (Figure 2B, error bar indicates mean with SD). Reviewing the intraoperative fluoroscopy images for those with subsidence, 1 patient demonstrated endplate damage at the time of surgery from repeated static trialing, a phenomenon previously reported by Malham et al.²⁹

Clinical Outcomes

The clinical outcomes are summarized in Table 5. As changes in patient self-reported outcome measure scores were calculated by subtracting the preoperative baseline from the follow-up score, an increasingly negative number suggests improvement in ODI and VAS, while positive values indicate improvement in SF-12. There was no significant difference in the mean ODI between the 2 groups during follow-up. VAS of patients from the expandable group demonstrated a significant reduction in back pain at 3 months with a mean difference of 2 lower points postoperatively ($P = 0.006$) and a significant decrease in leg pain at 12 months (mean 2.49 points of more reduction, $P = 0.023$) than those from the static group. The MCS of SF-12 showed significantly better scores from the expandable group with a mean 4 points higher in improvement than their static counterparts ($P = 0.009$) at 3 months; these improvements were maintained at 6 months ($P = 0.026$). At 6 months, the PCS of SF-12 also revealed substantially higher scores by the expandable group (mean 7.44 points of further improvement, $P = 0.035$), although these differences in MCS and PCS of SF-12 did not persist at 12 months between the 2 groups.

Subgroup analyses of the static cage group (Table 6) found that patients with lower Bridwell fusion grade (3 or 4 ± radiographic evidence of subsidence) had significantly worse ODI scores at 3 months (mean 13.49 lower scores, $P = 0.045$), markedly less leg pain improvement at 12 months (mean 6.11 less pain reduction, $P = 0.048$), and a trend of worse SF-12 PCS scores at 12 months and lower MCS scores throughout the follow-up period than that in those with higher Bridwell fusion grade (1 or 2 without subsidence).

DISCUSSION

Expandable cages have conventionally been reserved for corpectomy reconstructions,³⁰ while static cages are the gold standard for lumbar fusions. Although static cages have produced acceptable clinical outcomes,³¹⁻³³

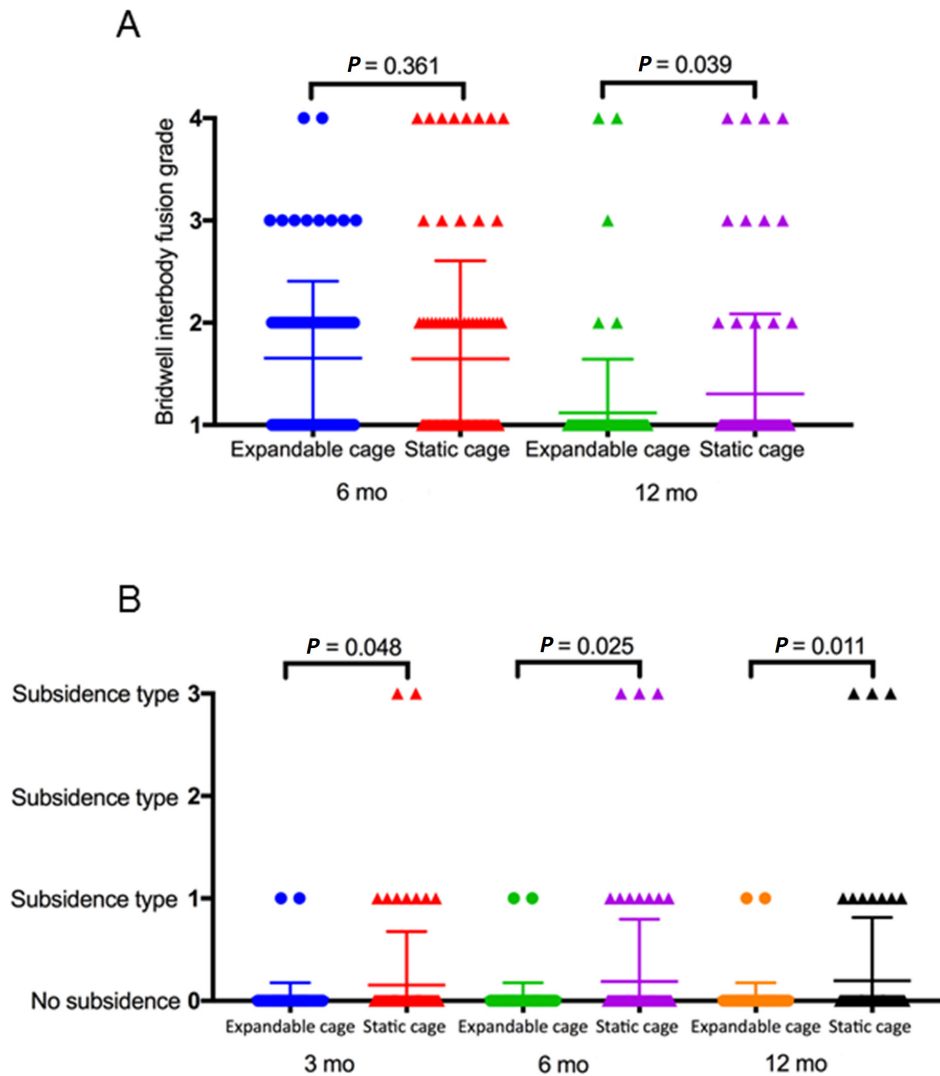


Figure 2. Fusion and subsidence rates. (A) Fusion grade as assessed by the Bridwell interbody fusion grading system was measured for each study group at 6 and 12 mo postoperatively. (B) The occurrence and type of subsidence were recorded for each study group at 3, 6, and 12 mo postoperatively. Error bar indicates standard error of the mean.

excessive spacer trialing, forceful impaction, and overdistraction of the intervertebral space during cage insertion remain a significant concern, which have been associated with endplate damage and secondary complications such as cage migration, pseudarthrosis, and subsidence.^{34–36} Subsidence can lead to a loss in lordosis, adjacent segmental disease, persistent back or leg pain with associated poor health functioning, and sometimes revision surgery.^{37,38} Conversely, it has been well established that satisfactory radiological parameters correlated with improved functional outcomes.^{14–16} Consistent with existing literature, we found significantly larger improvements in ODI and VAS for leg pain in patients with satisfactory fusion than that of those with poor fusion and/or subsidence within the static cage group. Furthermore, 5 out of the 12 patients with subsidence had to undergo revision surgery.

The use of expandable cages in lumbar fusion represents a valuable addition to the spinal surgery armamentarium. By design, the ability to be inserted as a low profile cage that is then expanded in situ to achieve the optimal anterior column support and lordosis, significantly reduces the risk of iatrogenic endplate damage and overdistraction. In particular, they may be well suited for patients with a collapsed disc space.¹⁸ The potential drawbacks that had been proposed, included overexpansion that places undue stress over a focal area of the endplate, raising the risk of endplate violation and cage subsidence, especially in patients with poor bone quality¹³; a possibility of leaving a void in the expanded cage without adequate amounts of bone graft, raising the chance of nonfusion³⁹; and a substantially higher cost than static spacers that remained to be justified by superior clinical outcomes.^{17,40} In our

Table 5. Patient self-reported outcomes of the 2 cage groups.

Study Arm	Changes ^a in ODI (%): Mean (Range, SD)		
	3 mo	6 mo	12 mo
Expandable cage	-14.61 (-48 to 28, 14.5)	-19.03 (-58 to 4, 14.6)	-20.81 (-60 to 8, 16.6)
Static cage	-10.41 (-28 to 16, 16.5)	-16.21 (-52 to 14, 19.5)	-20.24 (-58 to 42, 22.1)
<i>P</i> value	0.289	0.541	0.894
Study Arm	Changes ^a in VAS—Back: Mean (Range, SD)		
	3 mo	6 mo	12 mo
Expandable cage	-4.46 (-9 to 2, 2.7)	-4.65 (-9 to 0, 3.0)	-5.20 (-10 to 6, 3.3)
Static cage	-2.5 (-9 to 2, 2.8)	-3.71 (-9 to 1, 2.7)	-3.32 (-9 to 5, 3.4)
<i>P</i> value	0.006	0.231	0.062
Study Arm	Changes ^a in VAS—Both Legs Combined: Mean (Range, SD)		
	3 mo	6 mo	12 mo
Expandable cage	-6.70 (-18 to 9, 6.8)	-6.22 (-17 to 4, 5.5)	-6.76 (-18 to 4, 4.6)
Static cage	-5.46 (-13 to 1, 3.9)	-5.55 (-13 to 2, 4.3)	-4.27 (-14 to 9, 5.1)
<i>P</i> value	0.447	0.654	0.023
Study Arm	Changes ^{a*} in SF-12 (PCS): Mean (Range, SD)		
	3 mo	6 mo	12 mo
Expandable cage	7.46 (-34.2 to 29.3, 10.2)	13.24 (-13.1 to 38.9, 10.0)	10.39 (-27.8 to 37.9, 14.6)
Static cage	7.12 (-3.4 to 21.2, 7.0)	5.80 (-25.7 to 22, 12.5)	12.68 (-7.4 to 37, 10.7)
<i>P</i> value	0.624	0.035	0.988
Study Arm	Changes ^a in SF-12 (MCS): Mean (Range, SD)		
	3 mo	6 mo	12 mo
Expandable cage	4.54 (-63.6 to 22.41, 14.1)	4.13 (-47.3 to 28.6, 14.1)	6.24 (-28.9 to 28.6, 13.4)
Static cage	-0.72 (-26.1 to 22.7, 10.6)	2.75 (-67.1 to 20.0, 20.3)	3.08 (-23 to 38.0, 13.2)
<i>P</i> value	0.009	0.026	0.273

Abbreviations: MCS, mental component score; ODI, Oswestry Disability Index; PCS, physical component score; SF-12, 12-Item short form survey; VAS, visual analog scale.

^aThe value of the change is the difference between the score at the targeted follow-up minus preoperative baseline score. ODI (a score of 0–100, with higher scores indicating worse disability); VAS (a score of 0–20 for both legs combined, with higher scores indicating more severe pain); PCS (range of 0–100, with higher scores indicating better physical health functioning); MCS (range of 0–100, with higher scores indicating better mental health functioning).

experience, the expandable spacer had an inherent limit for maximal torque to prevent overexpansion and allowed backfilling of bone graft post cage expansion. The cost of the expandable cage used in our study was the same as the static one, at A\$3335 per cage.⁴¹ In addition, as illustrated in Figure 1B, the degree of individualization that was realized for the final cage height tailored toward each patient's own anatomy was unparalleled, compared with the static cages that came in fixed height options. To control for any influence from cage material, design, and surface features, we used Ti cages in both study groups. The expandable Ti cage was opted for given the increased lordotic options, expansion ranges with backfilling capacity as compared with earlier generation PEEK expandable cages.

As this technology gains popularity, it is paramount to evaluate whether its theoretical benefits and ease of implantation indeed translate into improved clinical outcomes for patients. To date, the evidence on expandable cages is scarce and predominantly involved retrospective studies of small sample sizes, with many lacking a control group or without directly comparing expandable with static cages. In those published data, expandable cages have not been consistently shown to be superior. For patients undergoing

LLIF, Li and colleagues⁴² found in a retrospective cohort of 62 patients that there was a significantly higher subsidence rate (16.1% vs 6.7% in the Ti expandable) and markedly less improvement in pain and ODI scores in the static PEEK cage group than that of the expandable cage group at 6 and 24 months follow-up. Frisch et al reported similarly increased subsidence rate in the static PEEK cage group (16.1% vs 0% with the expandable PEEK cages) in a prospective study of 56 patients who had LLIF, yet other radiographic metrics and clinical outcomes were similar between the 2 groups.⁴³ To date, the only prospective randomized control trial comparing 2 different types of cages was conducted in a group of patients undergoing PLIF (73 randomized to expandable vs 72 to static)—Korovesis and colleagues found that despite significant increases in anterior and posterior disc heights in the expandable group, fusion rates and clinical outcomes as measured by ODI, VAS, and SF-36 scores were similar between the 2 groups.⁴⁴ A meta-analysis of 12 studies (706 patients) on the use of expandable cages vs static cages in the minimally invasive surgery transforaminal lumbar interbody fusion reported no significant difference in fusion, subsidence rate, or changes in lumbar lordosis, although the mean

Table 6. Patient self-reported outcomes as per fusion outcomes within the static cage group.

Static Cage Group	Changes ^a in ODI (%): Mean (Range, SD)		
	3 mo	6 mo	12 mo
Poor fusion	3.2 (-4 to 16, 7.6)	-3.5 (-22 to 14, 15.3)	-15.64 (-46 to 16, 22.0)
Satisfactory fusion	-10.29 (-36 to 18, 15.6)	-18 (-44 to 14, 17.6)	-23.87 (-58 to 18, 19.6)
<i>P</i> value	0.045	0.171	0.256
	Changes ^a in VAS—Back: Mean (Range, SD)		
	3 mo	6 mo	12 mo
Poor fusion	-2.2 (-9 to 1, 4.2)	-3.5 (-9 to 1, 4.8)	-3.7 (-9 to 5, 4.1)
Satisfactory fusion	-2.58 (-6 to 2, 2.5)	-3.5 (-7 to 0, 2.1)	-4.24 (-10 to 2, 3.2)
<i>P</i> value	0.520	0.983	0.661
	Changes ^a in VAS—Both Legs Combined: Mean (Range, SD)		
	3 mo	6 mo	12 mo
Poor fusion	-4 (-7 to 0, 3.3)	-3.17 (-8 to 2, 3.9)	-1 (-14 to 9, 6.1)
Satisfactory fusion	-5.83 (-12 to 1, 4.0)	-6.28 (-15 to 9, 5.1)	-7.11 (-14 to 1, 4.7)
<i>P</i> value	0.478	0.091	0.048
	Changes ^a in SF-12 (PCS): Mean (Range, SD)		
	3 mo	6 mo	12 mo
Poor fusion	9.68 (5.4–16, 4.5)	10.65 (5.7–16.1, 5.0)	11.81 (-0.4 to 29, 10.3)
Satisfactory fusion	7.44 (-2.7 to 21.2, 7.1)	10.03 (-1 to 22, 6.6)	14.53 (-2.8 to 37, 9.9)
<i>P</i> value	0.535	0.790	0.439
	Changes ^a in SF-12 (MCS): Mean (Range, SD)		
	3 mo	6 mo	12 mo
Poor fusion	-7.2 (-26.1 to 0.7, 10.9)	-6.43 (-17.8 to 9.3, 12.9)	1.97 (-22.9 to 38, 15.2)
Satisfactory fusion	0.55 (-13.2 to 12.9, 8.8)	3.21 (-10.8 to 20, 6.7)	5.05 (-23 to 28.2, 12.7)
<i>P</i> value	0.142	0.202	0.514

Abbreviations: MCS, mental component score; ODI, Oswestry Disability Index; PCS, physical component score; SF-12, 12-item short form survey; VAS, visual analog scale. Note: Poor fusion is defined as fusion Bridwell grade 3 or 4, with or without subsidence. Satisfactory fusion is defined as Bridwell fusion grade 1 or 2, with no radiographic evidence of subsidence.

^aThe value of the change is the difference between the score at the targeted follow-up minus preoperative baseline score. It denotes statistical significance. ODI (a score of 0–100, with higher scores indicating worse disability); VAS (a score of 0–20 for both legs combined, with higher scores indicating more severe pain); PCS (range of 0–100, with higher scores indicating better physical health functioning); MCS (range of 0–100, with higher scores indicating better mental health functioning).

change in segmental lordosis was significantly higher for the expandable group.⁴⁵ Overall, the discordance in published results could be attributed to variations in the type of cages used (Ti vs PEEK), which may have distinct construct stiffness, different fusion grading systems, and assessment modalities utilized (CTs vs x-rays, or magnetic resonance imaging) and heterogeneities in study designs, fusion approaches, and surgeons' experience and techniques. In some studies, certain radiographic parameters were more favorable with expandable cages while clinical outcomes being equivocal between the 2 cage groups.^{43–45} This lack of correlation between radiographic and clinical results could be explained by the potentially large proportion of asymptomatic patients with radiographic evidence of suboptimal fusion and/or subsidence; the baseline low incidence of poor outcomes with static cages, especially in the hands of experienced surgeons; and clinical differences that may not have been readily captured by the commonly used quality-of-life questionnaires. All of these factors would necessitate studies of large cohorts, with longer

follow-up periods than what has been published for any significant distinction in clinical outcomes to be revealed.

In our study, we compared 2 cohorts of patients with similar demographic profiles treated by 2 experienced spinal surgeons using the same LLIF techniques and graft materials. We demonstrated a significantly higher subsidence rate and lower fusion rate as assessed on CT imaging, in the static group compared with that in the expandable cage group. We also observed significantly higher improvements in pain (mean VAS back pain, and leg pain) as well as functional status (MCS and PCS of the SF-12 surveys) at follow-up for the expandable group compared with the static cage group. The mean ODI remained comparable between the 2 groups postoperatively.

Strengths of our study were the prospective, multi-center design with both study surgeons past their learning curve with LLIF having each performed over 200 LLIF procedures prior to the commencement of this study. All patients had radiographic follow-up at each study time-point by CT assessed by an independent radiologist and

senior neurosurgeon, with final 12-month CT optimal for detection of subsidence and fusion assessment. Study limitations were inherent to its nonrandomized design; however, there was a sequential enrollment of 1 cage type followed by the other with the cohorts similar based on demographics, conditions treated, and operated levels. We used Ti cages for both study arms with the same biologics for bone graft to minimize variables; however, the surface texture may not be identical between the 2 types of cages, potentially contributing to the current results. The follow-up period of 12 months may also be inadequate in detecting delayed complications such as adjacent segmental disease.

CONCLUSION

In consecutive cohorts of patients undergoing LLIF, patients with expandable Ti cages achieved significantly higher fusion rates and lower subsidence rates at 12 months postoperative by CT assessment compared with Ti static cages. Patients with expandable cages demonstrated significant improvements in postoperative back and leg pain as well as in both SF-12 physical and mental components compared with patients with static cages. Our findings provide evidence for the clinicoradiographic benefits of the expandable cages in LLIF. Larger-scale randomized control trials with a multicenter prospective design would further establish any benefits of expandable lateral interbody devices.

ACKNOWLEDGMENTS

We thank Alison Magee for her assistance in data collection and management.

REFERENCES

1. Kwon B, Kim DH. Lateral lumbar interbody fusion: indications, outcomes, and complications. *J Am Acad Orthop Surg*. 2016;24(2):96–105. doi:10.5435/JAAOS-D-14-00208
2. Rihn JA, Patel R, Makda J, et al. Complications associated with single-level transforaminal lumbar interbody fusion. *Spine J*. 2009;9(8):623–629. doi:10.1016/j.spinee.2009.04.004
3. Macki M, Hamilton T, Haddad YW, Chang V. Expandable cage technology-transforaminal, anterior, and lateral lumbar interbody fusion. *Oper Neurosurg (Hagerstown)*. 2021;21(Suppl 1):S69–S80. doi:10.1093/ons/opa342
4. Ha KY, Na KH, Shin JH, Kim KW. Comparison of posterolateral fusion with and without additional posterior lumbar interbody fusion for degenerative lumbar spondylolisthesis. *J Spinal Disord Tech*. 2008;21(4):229–234. doi:10.1097/BSD.0b013e3180eaa202
5. Liao JC, Lu ML, Niu CC, Chen WJ, Chen LH. Surgical outcomes of degenerative lumbar spondylolisthesis with anterior vacuum disc: can the intervertebral cage overcome intradiscal

vacuum phenomenon and enhance posterolateral fusion? *J Orthop Sci*. 2014;19(6):851–859. doi:10.1007/s00776-014-0618-z

6. McAfee PC, DeVine JG, Chaput CD, et al. The indications for interbody fusion cages in the treatment of spondylolisthesis: analysis of 120 cases. *Spine (Phila Pa 1976)*. 2005;30(6 Suppl):S60–5. doi:10.1097/01.brs.0000155578.62680.dd
7. Oda I, Abumi K, Yu BS, Sudo H, Minami A. Types of spinal instability that require interbody support in posterior lumbar reconstruction: an in vitro biomechanical investigation. *Spine (Phila Pa 1976)*. 2003;28(14):1573–1580. doi:10.1097/01.BRS.0000076916.90238.37
8. McAfee PC, Boden SD, Brantigan JW, et al. Symposium: a critical discrepancy—a criteria of successful arthrodesis following interbody spinal fusions. *Spine (Phila Pa 1976)*. 2001;26(3):320–334. doi:10.1097/00007632-200102010-00020
9. Patel AA, Zfass-Mendez M, Lebowitz NH, et al. Minimally invasive versus open lumbar fusion: a comparison of blood loss, surgical complications, and hospital course. *Iowa Orthop J*. 2015;35:130–134.
10. Choi WS, Kim JS, Hur JW, Seong JH. Minimally invasive transforaminal lumbar interbody fusion using banana-shaped and straight cages: radiological and clinical results from a prospective randomized clinical trial. *Neurosurgery*. 2018;82(3):289–298. doi:10.1093/neuros/nyx212
11. McGilvray KC, Easley J, Seim HB, et al. Bony ingrowth potential of 3D-printed porous titanium alloy: a direct comparison of interbody cage materials in an in vivo ovine lumbar fusion model. *Spine J*. 2018;18(7):S1529-9430(18)30076-7:1250–1260. doi:10.1016/j.spinee.2018.02.018
12. Vaishnav AS, Saville P, McAnany S, et al. Retrospective review of immediate restoration of lordosis in single-level minimally invasive transforaminal lumbar interbody fusion: a comparison of static and expandable interbody cages. *Oper Neurosurg (Hagerstown)*. 2020;18(5):518–523. doi:10.1093/ons/opa240
13. Crandall DG, Chung AS, Lara N, Revella J. Risk factors for expandable cage subsidence in patients undergoing transforaminal lumbar interbody fusion. *The Spine Journal*. 2017;17(10):S188–S189. doi:10.1016/j.spinee.2017.08.030
14. Glassman SD, Bridwell K, Dimar JR, Horton W, Berven S, Schwab F. The impact of positive sagittal balance in adult spinal deformity. *Spine (Phila Pa 1976)*. 2005;30(18):2024–2029. doi:10.1097/01.brs.0000179086.30449.96
15. Lazennec JY, Ramaré S, Arafati N, et al. Sagittal alignment in lumbosacral fusion: relations between radiological parameters and pain. *Eur Spine J*. 2000;9(1):47–55. doi:10.1007/s005860050008
16. Glassman SD, Berven S, Bridwell K, Horton W, Dimar JR. Correlation of radiographic parameters and clinical symptoms in adult scoliosis. *Spine (Phila Pa 1976)*. 2005;30(6):682–688. doi:10.1097/01.brs.0000155425.04536.f7
17. Yee TJ, Joseph JR, Terman SW, Park P. Expandable vs static cages in transforaminal lumbar interbody fusion: radiographic comparison of segmental and lumbar sagittal angles. *Neurosurgery*. 2017;81(1):69–74. doi:10.1093/neuros/nyw177
18. Hawasli AH, Khalifeh JM, Chatrath A, Yarbrough CK, Ray WZ. Minimally invasive transforaminal lumbar interbody fusion with expandable versus static interbody devices: radiographic assessment of sagittal segmental and pelvic parameters. *Neurosurg Focus*. 2017;43(2):E10. doi:10.3171/2017.5.FOCUS17197
19. Chang C-C, Chou D, Pennicooke B, et al. Long-Term radiographic outcomes of expandable versus static cages in transforaminal

lumbar interbody fusion. *J Neurosurg Spine*. 2020;1–10. doi:10.3171/2020.6.SPINE191378

20. Walsh WR, Pelletier M, Wills D, Wang T, Bannigan S, Vizesi F. Undercut macrostructure topography on and within an interbody cage improves biomechanical stability and interbody fusion. *Spine J*. 2020;20(11):S1529–9430(20)30955-4):1876–1886. doi:10.1016/j.spinee.2020.06.023

21. Seaman S, Kerezoudis P, Bydon M, Torner JC, Hitchon PW. Titanium vs. polyetheretherketone (peek) interbody fusion: meta-analysis and review of the literature. *J Clin Neurosci*. 2017;44:S0967-5868(17)30433-2:23–29. doi:10.1016/j.jocn.2017.06.062

22. Rao PJ, Pelletier MH, Walsh WR, Mobbs RJ. Spine interbody implants: material selection and modification, functionalization and bioactivation of surfaces to improve osseointegration. *Orthop Surg*. 2014;6(2):81–89. doi:10.1111/os.12098

23. Damien CJ, Grob D, Boden SD, Benedict JJ. Purified bovine BMP extract and collagen for spine arthrodesis: preclinical safety and efficacy. *Spine (Phila Pa 1976)*. 2002;27(16 Suppl 1):S50–8. doi:10.1097/00007632-200208151-00012

24. Jenkinson C. The SF-36 physical and mental health summary measures: an example of how to interpret scores. *J Health Serv Res Policy*. 1998;3(2):92–96. doi:10.1177/135581969800300206

25. Fairbank JC, Pynsent PB. The Oswestry disability index. *Spine (Phila Pa 1976)*. 2000;25(22):2940–2952. doi:10.1097/00007632-200011150-00017

26. Ostelo RWJG, de Vet HCW. Clinically important outcomes in low back pain. *Best Pract Res Clin Rheumatol*. 2005;19(4):593–607. doi:10.1016/j.berh.2005.03.003

27. Choi JY, Sung KH. Subsidence after anterior lumbar interbody fusion using paired stand-alone rectangular cages. *Eur Spine J*. 2006;15(1):16–22. doi:10.1007/s00586-004-0817-y

28. Malham GM, Parker RM, Blecher CM, Seex KA. Assessment and classification of subsidence after lateral interbody fusion using serial computed tomography. *J Neurosurg Spine*. 2015;23(5):589–597. doi:10.3171/2015.1.SPINE14566

29. Malham GM, Parker RM, Blecher CM, Seex KA. Assessment and classification of subsidence after lateral interbody fusion using serial computed tomography. *J Neurosurg Spine*. 2015;23(5):589–597. doi:10.3171/2015.1.SPINE14566

30. Arts MP, Peul WC. Vertebral body replacement systems with expandable cages in the treatment of various spinal pathologies: a prospectively followed case series of 60 patients. *Neurosurgery*. 2008;63(3):537–544. doi:10.1227/01.NEU.0000325260.00628.DC

31. Rouben D, Casnellie M, Ferguson M. Long-Term durability of minimal invasive posterior transforaminal lumbar interbody fusion: a clinical and radiographic follow-up. *J Spinal Disord Tech*. 2011;24(5):288–296. doi:10.1097/BSD.0b013e3181f9a60a

32. Shunwu F, Xing Z, Fengdong Z, Xiangqian F. Minimally invasive transforaminal lumbar interbody fusion for the treatment of degenerative lumbar diseases. *Spine (Phila Pa 1976)*. 2010;35(17):1615–1620. doi:10.1097/BRS.0b013e3181c70fe3

33. McAfee PC, DeVine JG, Chaput CD, et al. The indications for interbody fusion cages in the treatment of spondylolisthesis: analysis of 120 cases. *Spine (Phila Pa 1976)*. 2005;30(6 Suppl):S60–5. doi:10.1097/01.brs.0000155578.62680.dd

34. Chen L, Yang H, Tang T. Cage migration in spondylolisthesis treated with posterior lumbar interbody fusion using Bak cages. *Spine (Phila Pa 1976)*. 2005;30(19):2171–2175. doi:10.1097/01.brs.0000180402.50500.5b

35. Aoki Y, Yamagata M, Nakajima F, et al. Examining risk factors for posterior migration of fusion cages following transforaminal lumbar interbody fusion: a possible limitation of unilateral pedicle screw fixation. *J Neurosurg Spine*. 2010;13(3):381–387. doi:10.3171/2010.3.SPINE09590

36. Malham GM, Ellis NJ, Parker RM, et al. Maintenance of segmental lordosis and disk height in stand-alone and instrumented extreme lateral interbody fusion (XLIF). *Clin Spine Surg*. 2017;30(2):E90–E98. doi:10.1097/BSD.0b013e3182aa4c94

37. Marchi L, Abdala N, Oliveira L, Amaral R, Coutinho E, Pimenta L. Stand-Alone lateral interbody fusion for the treatment of low-grade degenerative spondylolisthesis. *ScientificWorldJournal*. 2012;2012:456346:456346. doi:10.1100/2012/456346

38. Tempel ZJ, McDowell MM, Panczykowski DM, et al. Graft subsidence as a predictor of revision surgery following stand-alone lateral lumbar interbody fusion. *J Neurosurg Spine*. 2018;28(1):2017.5.SPINE16427):50–56. doi:10.3171/2017.5.SPINE16427

39. Bektor JG, Pockett RD, Verghese N. The expandable transforaminal lumbar interbody fusion-two years follow-up. *J Craniovertebr Junction Spine*. 2018;9(1):50–55. doi:10.4103/jcvjs.JCVJS_21_18

40. Vaishnav AS, Saville P, McAnany S, et al. Retrospective review of immediate restoration of lordosis in single-level minimally invasive transforaminal lumbar interbody fusion: A comparison of static and expandable interbody cages. *Operative Neurosurgery*. 2019;0:1–6.

41. Do H. *Prostheses List - Part A* [Australian Government Accessed]. December 18, 2021. <https://www.health.gov.au/resources/publications/prostheses-list>.

42. Li YM, Frisch RF, Huang Z, et al. Comparative effectiveness of expandable versus static interbody spacers via MIS LLIF: a 2-year radiographic and clinical outcomes study. *Global Spine J*. 2020;10(8):998–1005. doi:10.1177/2192568219886278

43. Frisch RF, Luna IY, Brooks DM, Joshua G, O'Brien JR. Clinical and radiographic analysis of expandable versus static lateral lumbar interbody fusion devices with two-year follow-up. *J Spine Surg*. 2018;4(1):62–71. doi:10.21037/jss.2018.03.16

44. Korovessis P, Repantis T, Baikousis A, Iliopoulos P. Postero-lateral versus circumferential instrumented fusion for monosegmental lumbar degenerative disc disease using an expandable cage. *Eur J Orthop Surg Traumatol*. 2012;22(8):639–645. doi:10.1007/s00590-011-0890-y

45. Alvi MA, Kurian SJ, Wahood W, Goyal A, Elder BD, Bydon M. Assessing the difference in clinical and radiologic outcomes between expandable cage and nonexpandable cage among patients undergoing minimally invasive transforaminal interbody fusion: a systematic review and meta-analysis. *World Neurosurg*. 2019;127:S1878-8750(19)30965-9:596–606. doi:10.1016/j.wneu.2019.03.284

Funding: A research grant was provided to St. Vincent's Hospital, Melbourne, by Globus Medical.

Declaration of Conflicting Interests: Yi Yuen Wang reports a retractor design contract from SeaSpine; consulting fees from Globus Medical, SeaSpine, BrainLab, Device Technologies, Australia; and a leadership role for the Australian Pituitary Foundation. Gregory M. Malham reports consulting fees from

Globus Medical, Life HealthCare, and Medtronic; payment/honoraria from Globus (Lateral Symposium); and support for attending meetings/travel from Life HealthCare and Globus Medical. The remaining authors have nothing to disclose.

Corresponding Author: Yi Yuen Wang, Neuroscience Institute, Epworth Hospital, PO Box 586,

Camberwell, VIC 3124, Australia; y.wang@keyhole-neurosurgery.com.au

Published 08 March 2023

This manuscript is generously published free of charge by ISASS, the International Society for the Advancement of Spine Surgery. Copyright © 2023 ISASS. To see more or order reprints or permissions, see <http://ijssurgery.com>.

Corrections

Huo CW, Malham GM, Biddau DT, Chung T, Wang YY. Lateral lumbar interbody fusion using expandable vs static titanium interbody cages: a prospective cohort study of clinical and radiographic outcomes. *Int J Spine Surg.* 2023;17(2):265-275. <https://doi.org/10.14444/8422>

The authors report that in discussion with the research governance teams of both St Vincent’s Hospital Melbourne and Epworth HealthCare, it has come to their attention that some errors occurred in this recently published article. The authors thus submit the following:

The article states the following on page 266: “This was a multicenter prospective cohort study with institutional ethics committee approvals obtained (St Vincent’s Hospital Quality Assurance reference number: 21036; Epworth HealthCare Ethics approval: Professor Nikolas Zeps, Group Director of Research and Development). Ninety-eight consecutive patients underwent LLIF, with a total of 169 operative levels performed between December 2018 and February 2021 by 2 senior spinal fellowship trained neurosurgeons using the same surgical techniques. Informed consents were obtained from all patients.”

First, while we individually obtained institutional approval to undertake a retrospective analysis of our own patient records (essentially, audits of our own respective practices), we are now aware that we did not obtain the necessary institutional approval to use our aggregated (non-identifiable) data in a published, combined comparison study. A single site quality assurance retrospective audit was registered with St Vincent’s Hospital Melbourne and institutional ethics approval from Epworth HealthCare was not received. Accordingly, stating that the “multicenter prospective cohort study” had “institutional ethics committee approvals” from the two institutions was a mistake.

Second, we obtain patient consent for surgery at each institution, to allow analysis of patient treatment and outcome data for the purposes of quality assurance and quality improvement in our practices, as part of our routine consent to treatment. We believe that this is essential to maintaining high standards of safety and quality in our practices. However, we have now become aware that although we obtained patient consent prospectively to perform routine analysis of our own patient outcomes (including for research), specific patient consent for inclusion of their non-identifiable data in this published study was not obtained.

A further consequence of this is that although consent was obtained prospectively, this does not mean that our study was prospective. That is, as we did not have the purpose of the study specifically in mind when we obtained the relevant patient consent, the study is in fact a retrospective analysis of routine clinical data collated prospectively.

It is important to note that neither of these issues has had any adverse consequences for, or adverse effect on, either (a) patient safety or welfare, or (b) the integrity of the data that is the subject of the study. The amalgamation of our non-identifiable data was a decision that we made in good faith because we believed that it would create a larger and therefore more statistically robust data set. This decision did not involve any change to patient treatment, or the sharing of identifiable personal information with unauthorized persons (for example). At all times, the confidentiality of patient data has been maintained (as only non-identifiable data were used in the study). At all times, we acted in good faith in attempting to obtain the necessary approvals for this study.

Thus, the following corrections have been made to this article:

- The title of the article is changed from “Lateral Lumbar Interbody Fusion Using Expandable vs Static Titanium Interbody Cages: A Prospective Cohort Study of Clinical and Radiographic Outcomes” to “Lateral Lumbar Interbody Fusion Using Expandable vs Static Titanium Interbody Cages: A Retrospective Study of Clinical and Radiographic Outcomes”
- The approvals and consent statements previously listed are changed to “This was a multicenter retrospective cohort study. Institutional ethics committee approvals were obtained (St Vincent’s Hospital Quality Assurance reference number: 21036; Epworth HealthCare Ethics approval: Professor Nikolas Zeps, Group Director of Research and Development). Ninety-eight consecutive patients underwent LLIF, with a total of 169 operative levels performed between December 2018 and February 2021 by 2 senior spinal fellowship trained neurosurgeons using the same surgical techniques. Informed consent was obtained from patients at the time of data collection.”

(doi:10.14444/8422.cxx)

Copyright © 2024 ISASS. This article is distributed under Creative Commons Licensing Agreement CC BY-NC-ND. For commercial entities seeking to order reprints or permissions, visit <http://ijssurgery.com>.