

Collagen Matrix Inlay Graft for Management of Incidental Durotomy During Full-Endoscopic Lumbar Spine Surgery: Technique and Case Series

Peter B. Derman, Mary P. Rogers-LaVanne and Alexander M. Satin

Int J Spine Surg 2023, 17 (3) 399-406

doi: <https://doi.org/10.14444/8457>

<http://ijssurgery.com/content/17/3/399>

This information is current as of April 28, 2024.

Email Alerts Receive free email-alerts when new articles cite this article. Sign up at:
<http://ijssurgery.com/alerts>

Collagen Matrix Inlay Graft for Management of Incidental Durotomy During Full-Endoscopic Lumbar Spine Surgery: Technique and Case Series

PETER B. DERMAN, MD, MBA¹; MARY P. ROGERS-LAVANNE, PhD¹; AND ALEXANDER M. SATIN, MD¹

¹Texas Back Institute, Plano, TX, USA

ABSTRACT

Background: Endoscopic spine surgery (ESS) has a reduced rate of incidental durotomy (ID) compared with open spine surgery. However, there are unique challenges regarding the management of ID in ESS due to the single, deep, narrow working corridor and aqueous environment. Here, we present a collagen matrix inlay graft technique for the management of ID encountered during ESS.

Methods: Three patients were identified via medical record review of full ESS where an intraoperative ID was encountered. These were all addressed endoscopically. All surgeries were performed by a single surgeon in the years 2019 to 2023. Patient, operative, and postoperative details, including patient-reported outcomes, were recorded. Briefly, the collagen matrix inlay graft technique included introducing a segment of collagen matrix into the surgical field and manipulating the collagen matrix so that it passed through the durotomy and resided within the dura, plugging the hole.

Results: Three IDs were identified out of a total of 295 eligible cases (1.02%). The IDs measured 2 to 2.5 mm in length. For these 3 patients, the duration of hospital stay ranged from 172 to 1,068 minutes. No patients exhibited signs or symptoms of cerebrospinal fluid leak at any postoperative timepoint. At the 6-week postoperative visit, all patients had achieved the minimum clinically important difference in Oswestry Disability Index, and all patients with available visual analog scale scores for leg and low back pain had achieved the cutoff for the minimum clinically important difference.

Conclusions: We presented 3 cases of ID during uniportal full ESS who were repaired using a collagen matrix inlay technique. Prolonged bed rest was avoided, and all patients achieved excellent clinical outcomes without further complication. This technique may also be appropriate for other minimally invasive spine surgery techniques.

Clinical Relevance: ID is a common and undesirable complication of degenerative lumbar spine surgery. Endoscopic ID repair techniques provide an option to avoid conversion to open or tubular surgery for the management of ID.

Level of Evidence: 4.

Novel Techniques & Technology

Keywords: durotomy, inlay graft, endoscopic spine surgery, minimally invasive spine surgery, lumbar spine surgery

INTRODUCTION

Incidental durotomy (ID) is a common and undesirable complication of degenerative lumbar spine surgery, with rates of up to 17% reported in open surgery.^{1–5} Certain factors increase the risk of ID during lumbar spine surgery, including revision surgery, smoking, diabetes, age, obesity, and surgical invasiveness.^{3–8} Some patients who sustain an ID during surgery recover without issue. However, others require additional procedures due to persistent cerebrospinal fluid (CSF) leak and resulting spinal headaches, pseudomeningocele, meningitis, infection, and/or symptomatic nerve root entrapment.^{9–13} ID also results in increased costs for patients.¹⁴ Evidence regarding the clinical impact of ID on patient outcomes varies, with some authors reporting good outcomes^{2,4,13,15,16} and

others reporting worse outcomes^{17,18} in patients with durotomies.

Over the past 2 decades, there has been a significant increase in the utilization of minimally invasive spine surgery (MISS).¹⁹ MISS refers to surgical techniques designed to reduce pain, blood loss, and damage to adjacent structures when compared with traditional open techniques.²⁰ More recently, full-endoscopic spine surgery (ESS), a type of MISS, has become more popular.²¹ Uniportal ESS utilizes a single, subcentimeter working cannula with advanced visualization technology and continuous irrigation. While full ESS has numerous advantages over other techniques, including a reduced rate of ID, unique challenges regarding the repair and management of ID exist due to the single, deep, narrow working corridor and aqueous environment.^{22,23}

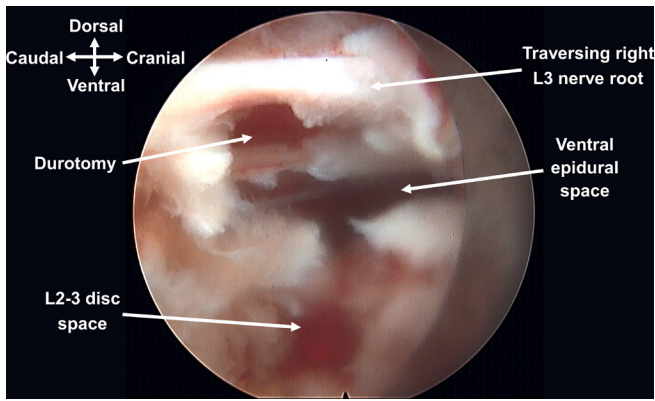


Figure 1. Intraoperative image depicting a durotomy encountered during a uniportal full-endoscopic lumbar spine surgery.

A recent international survey of spine surgeons found that 12% of respondents did not have a plan to manage IDs encountered during endoscopic surgery for spinal decompression.²⁴ Furthermore, the risk for ID during ESS is higher in surgeons with fewer than 5 years of experience.²⁵ Increasing knowledge about dural repair techniques is critical to help ensure that endoscopic spine surgeons are fully prepared for this potential complication.

The option to convert to open or tubular techniques for the management of ID during full ESS exists, but most surgeons hope to avoid this due to the associated morbidity and increased time. Some authors have described good results with nonpenetrating titanium clips for the repair of ID during ESS.^{23,26} However, this technique is unique to biportal full ESS as it requires an additional working portal. Management strategies for ID during uniportal full ESS have been described but are limited.^{27–30} Here, we present our technique for the management of ID during uniportal full ESS.

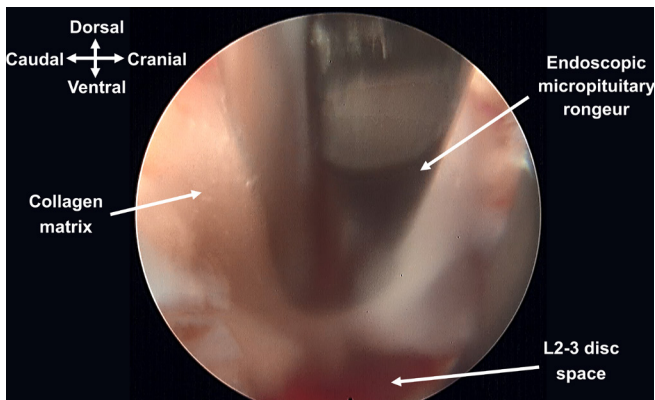


Figure 2. An endoscopic micropituitary rongeur is used to introduce a segment of collagen matrix for use as an inlay graft in the management of a durotomy encountered during a uniportal full-endoscopic lumbar spine surgery. The collagen matrix had been cut to be slightly larger than the dimensions of the dural tear.

METHODS

Medical records were reviewed for full ESSs where an intraoperative dural tear was encountered. These tears were all addressed endoscopically. Combined cases involving nonendoscopic techniques were excluded. All surgeries were performed at a single institution by 1 surgeon in between November 2019 and March 2023 using the Joimax (Irvine, California, USA) iLESSYS Pro or TESSYS endoscopic systems. The study was determined to be exempt from Institutional Review Board oversight (HCA Institutional Review Board #2022–949).

Data were gathered on preoperative, intraoperative, and postoperative variables. Data included patient factors, diagnoses, surgical approaches, operative time, length of hospital stay (LOS), and postoperative symptoms. The size and location of the dural tear as well as the repair technique were recorded.

To evaluate patient-reported outcomes, scores were compiled for the preoperative and 6-week postoperative Oswestry Disability Index (ODI) and visual analog scale (VAS) for low back and leg pain. One patient was missing information on preoperative VAS scores. Scores were assessed for whether or not they met the minimum clinically important difference (MCID). The definition of MCID varies based on the method of calculation.³¹ In this study, the MCID for leg pain was defined as an improvement of at least 1.6 points; the MCID for low back pain was defined as an improvement of at least 1.2 points; and the MCID for ODI was defined as an improvement of at least 12.8 points.³¹ Descriptive statistical analyses were conducted in R. Analyses were run in R version 4.1.1.³² The main R packages used in this project included the following: dplyr, epiR, ggplot2, tidyverse, and vtable.^{33–37}

Technique

Regardless of when the ID was identified during the procedure, the decompression was completed and the initial goals of surgery were achieved before addressing the tear. No modifications were necessary to the irrigation fluid settings, although reducing the pressure might be beneficial if the surgeon suspects a substantial influx of irrigation fluid or debris through the durotomy.

IDs (Figure 1) were then managed in the following fashion: A segment of collagen matrix (Duragen, Integra, Plainsboro, New Jersey, USA) was cut to a size slightly larger than the dimensions of the dural tear. It was then introduced into the surgical field using an endoscopic micropituitary rongeur (Figure 2). A variety

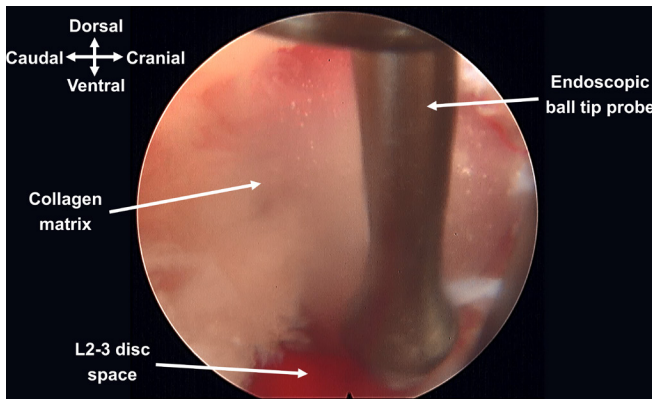


Figure 3. An endoscopic ball tip probe is used to manipulate the collagen matrix so that it passes through the durotomy and resides within the dura, plugging the hole.

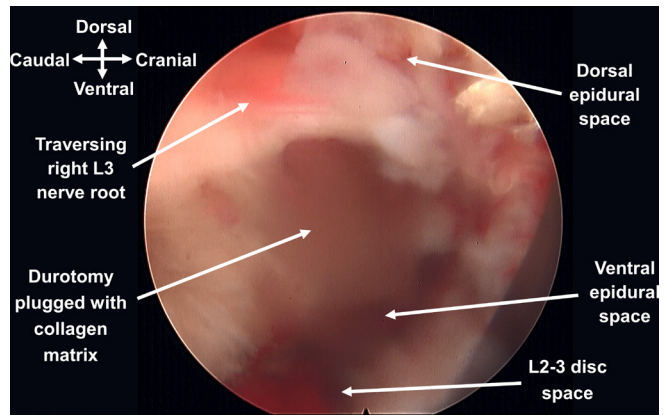


Figure 5. Final appearance of the durotomy plugged with the collagen matrix. The endoscopic fluid pressure can be shut off, and an intraoperative Valsalva was performed to confirm that the inlay graft is well fixed.

of instruments, including an endoscopic ball tip probe (Figure 3) and nerve hook (Figure 4), were utilized to manipulate the collagen matrix so that it passed through the durotomy and resided within the dura, plugging the hole (Figure 5). Deployable and spring-action curved instruments (eg, ball tip probes and micropituitaries) were especially helpful in collagen matrix graft delivery during transforaminal (TF) cases given the more constrained nature of this approach. Once the collagen matrix graft was inserted, the CSF pressure pushed it back against the intact dura, preventing the herniation of rootlets. The endoscopic fluid pressure was shut off, and an intraoperative Valsalva was performed to confirm that the inlay collagen matrix graft was well fixed. A small amount of dural sealant (polyethylene glycol [PEG] hydrogel, DuraSeal, Integra, Plainsboro, New Jersey, USA) was applied at the surgeon’s discretion, but caution was exercised as these products tend to expand with time.³⁸ Given the lack of dead space created during an endoscopic approach, such expansion

may produce iatrogenic neurologic compression in the enclosed bounds of the endoscopic surgical field. Closure was then performed in standard fashion and sealant (Dermabond, Ethicon Inc., Raritan, New Jersey, USA) was applied to the skin.

RESULTS

Patient and Surgical Descriptions

A total of 295 eligible cases were identified. There were 3 instances of intraoperative ID (1.02%). The 3 patients’ ages ranged from 43 to 73 years (mean 55.0 ± 15.9). One patient was a woman and the other 2 patients were men. Patients’ body mass index ranged from 24.1 to 28.1 (mean 26.3 ± 2.0). None of the patients were diabetic, were taking anticoagulants, or smoked.

All 3 patients were diagnosed with symptomatic lumbar disc herniations, causing radiculopathy refractory to conservative care. One patient additionally had underlying facet and ligamentum hypertrophy contributing to her stenosis—she underwent an interlaminar (IL) hemilaminotomy and discectomy, while the other patients underwent TF discectomies. All procedures were performed with the patients in the prone position under general endotracheal anesthesia. None of the patients had a history of prior surgery at the index level. Table 1 provides additional information about patient and surgical variables.

Intraoperative

The operating time ranged from 58 to 123 minutes (mean 89.3 ± 32.6). The dural tears encountered during surgery ranged in size and location: 2 tears measured at 2 mm and 1 tear measured at 2.5 mm. The durotomies incurred during the TF cases involved the

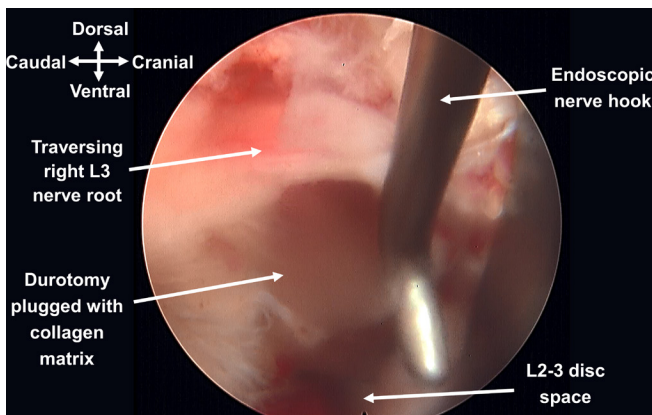


Figure 4. An endoscopic nerve hook is used to manipulate the collagen matrix so that it passes through the durotomy and resides within the dura, plugging the hole.

Table 1. Patient, operative, and immediate postoperative details for the 3 patients included in the case series.

Age, y	Sex	ASA	BMI	Level	Diagnosis	Procedure	Durotomy Location	Durotomy Size, mm	Repair Agent	Operative Time, min	Length of Hospital Stay, min
73	M	3	26.7	L2-L3	Large, central HNP causing canal and right greater than left lateral recess stenosis with right L3 radiculopathy	Right transforaminal discectomy	Ventral nerve root sleeve of the traversing right L3 nerve root	2	Collagen matrix	87	309
49	M	1	28.1	L3-L4	Left-sided foraminal/far lateral HNP causing left L3 radiculopathy	Left transforaminal discectomy	Ventrolateral aspect of the traversing left L4 root	2	Collagen matrix	58	172
43	F	1	24.1	L4-L5	Facet and ligamentum flavum hypertrophy with superimposed left paracentral HNP causing lateral recess stenosis and left L5 radiculopathy	Left interlaminar hemilaminotomy and discectomy	Dorsolateral aspect of the thecal sac	2.5	Collagen matrix and polyethylene glycol hydrogel	123	1068

Abbreviations: ASA, American Society of Anesthesiologists; BMI, body mass index; F, female; HNP, herniated nucleus pulposus; M, male.

traversing nerve roots, while the tear sustained during the IL approach involved the thecal sac. All durotomies were linear, and there was no extravasation of nerve roots in any of the cases. The dural tears were repaired endoscopically using a collagen matrix inlay graft as described above. For the largest tear, a PEG hydrogel sealant was also applied.

Postoperative

The LOSs ranged from 172 to 1068 minutes. Surgery in 1 patient concluded in the late evening so the patient was observed overnight as a precaution rather than discharged home the same day—this resulted in a substantially longer LOS in this patient. That patient was kept on bed rest with head of bed flat overnight, then gradually sat up the next morning and discharged home. The other patients were kept flat for 2 hours and subsequently discharged home. No other changes were made to the postoperative protocols. No patients exhibited signs or symptoms of CSF leak at any postoperative timepoint.

All patients achieved the cutoff for MCID in ODI scores at the 6-week follow-up after surgery (Table 2).

Table 2. Patient-reported outcomes for ODI and VAS pain scores (leg and low back).

Variable	n	Median	Range
ODI			
Preoperative	3	42	20–62
Postoperative	3	0	0–26
VAS leg			
Preoperative	2	7	7–7
Postoperative	3	1	0–2
VAS low back			
Preoperative	2	6	5–7
Postoperative	3	0	0–5

Abbreviations: ODI, Oswestry Disability Index; VAS, visual analog scale.
 Note: All patients with pre- and postoperative scores achieved the cut-off for minimum clinically important differences in ODI and VAS.

Figure 6 displays the pre- and postoperative ODI scores. Two of the 3 patients provided preoperative VAS pain scores for the leg and low back. Each of these patients achieved the cutoff for MCID in VAS scores at the 6-week follow-up visit after surgery. The third patient only provided postoperative VAS scores at the 6-week follow-up, and these scores indicated that the patient was not experiencing any pain (all scores of 0). Figure 7 displays the pre- and postoperative VAS scores.

DISCUSSION

Our management technique for ID during single-portal full ESS and subsequent clinical outcomes is presented. In this series, a collagen matrix inlay graft successfully treated all IDs without sequelae, and all patients achieved excellent clinical outcomes. One patient was kept flat overnight due to the case finishing

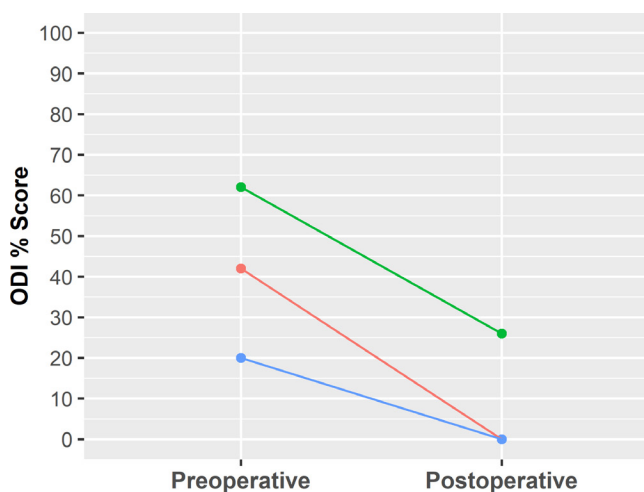


Figure 6. Oswestry Disability Index (ODI) scores for each patient before surgery and at the 6-wk postoperative follow-up appointment. Each line represents a unique patient. All patients achieved the cutoff for minimum clinically important difference.

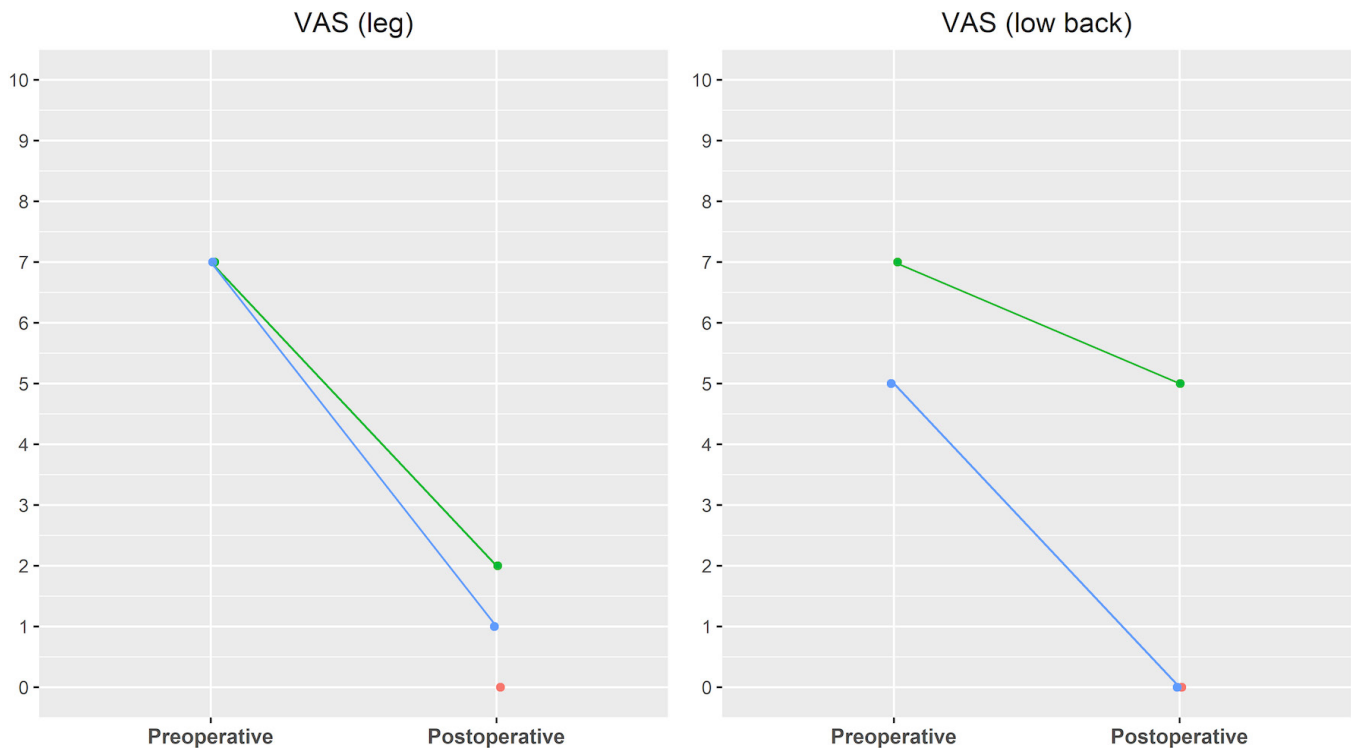


Figure 7. Visual analog scale (VAS) pain scores for each patient before surgery and at the 6-wk postoperative follow-up appointment. Each line represents a unique patient. The red points (all VAS scores at 0) represent an additional patient who only provided postoperative VAS pain scores. All patients reporting pre- and postoperative VAS scores achieved the cutoffs for minimum clinically important difference.

in the evening, but the other 2 ambulated 2 hours after surgery and were discharged home shortly thereafter. This technique takes advantage of the limited dead space created during ESS and utilizes the CSF pressure to seal the closure. Adjuvant PEG hydrogel sealant was used in 1 case and necessitates discontinuation of the irrigation to avoid washout. Great care should be taken to limit operative time after ID during ESS as the dural tear may allow the influx of irrigation fluid and a subsequent increase in intracranial pressure.²⁶

Techniques for the management of ID during single-portal full ESS are limited. In 2018, Shin et al described Youn's technique for direct suture repair of ID during ESS. To date, this is the only described technique for direct suture repair of ID using uniportal endoscopy. Their technique utilizes a double-arm 6-0 prolene suture to create a water-tight repair. According to the authors, the double-arm needle facilitates first passage and reduces the risk of nerve entrapment. The needles are then brought out of the working cannula and knotted outside of the endoscope. An endoscopic curette is used as a knot pusher to pass and tighten the knot. In this study, they did not present clinical outcomes for their technique. While inlay and onlay graft techniques are suitable for smaller ID during ESS, Youn's technique may represent a challenging but effective technique to

avoid conversion to open surgery for larger ID during uniportal full ESS.

Kim et al presented a retrospective evaluation of 330 patients who underwent endoscopic lumbar stenosis decompression via an IL approach. Their incidence of ID was 8.2% ($n = 27$). They also presented a classification system to describe endoscopic dural tears and help guide management. They recommend open repair in cases with large complex tears, failure of endoscopic repair, or when nerve roots remain incarcerated despite endoscopic manipulation. In appropriate cases ($n = 26$), they performed a patch blocking repair. In their technique, a collagen patch was inserted into the dural defect to prevent entry of foreign substances into the thecal sac and herniation of nerve roots. They followed this with the application of a fibrin patch (Tachosil, Nycomed, Linz, Austria) and placed an additional collagen patch onto the fibrin layer to prevent dislodgment by the irrigation. At a mean follow-up of 10.4 months, they reported significant improvement in ODI and VAS scores in patients treated with the patch blocking repair technique.

A recent retrospective multi-institutional study of 553 patients treated by members of the Endoscopic Spine Study Group reported a 0.54% ($n = 3$) durotomy rate.³⁹ Procedures included discectomy (68%), foraminotomy

(28.2%), unilateral laminotomy for bilateral decompression (9.9%), and lateral recess decompression (5.2%). Two of the IDs occurred during discectomies. One was converted to open for decompression purposes and not for management of the dural tear. One was treated conservatively. The other dural defect occurred during an endoscopic laminectomy. Arachnoid was found to be intact, and it was repaired in layers using only collagen matrix followed by fibrin sealant (TISSEEL, Baxter, Deerfield, Illinois, USA). This patient was kept flat for 6 hours and discharged the morning after surgery without complication.

Telfeian et al reported a similarly low rate of ID (0.4%) in a series of 907 TF endoscopic surgeries performed by 2 experienced surgeons. Two of the IDs occurred on the traversing nerve root sleeve during revision discectomies. In 1 case, they applied a Durepair Regeneration Matrix (Medtronic, Dublin, Ireland) patch to the tear with an endoscopic grasper. No sealant or patch was utilized in the other case. The other 2 IDs occurred in revision decompression cases at the site of previous fusion. One case was treated with routine closure and 24 hours of bed rest and the other with a Duragen patch. There were no adverse outcomes. The authors concluded that ID during TF ESS is a rare complication more likely to happen during revision surgeries. While it may be hard to conceive for open surgery, routine closure and bed rest can be effective for the treatment of ID in ESS due to the lack of dead space created. Other authors have reported good outcomes (no return to operating room) in cases of ID treated with routine closure and 72 hours of bed rest.⁴⁰

Similar challenges for direct dural repair exist in minimally invasive tubular surgery due to the narrow and deep working corridor.⁴¹⁻⁴⁴ This has led a number of authors to propose novel dural repair techniques for these cases.⁴¹⁻⁴⁴ Like full ESS, minimally invasive tubular techniques utilize small incisions and include limited lack of dead space, especially when compared with open techniques. As a result, the dural inlay technique is a reasonable option for IDs in select nonendoscopic cases. Our dural inlay technique may be preferred in minimally invasive tubular cases with small tears in difficult to repair locations. However, additional studies are needed to evaluate this technique in non-ESSs.

Our study has a number of limitations. This is a retrospective study without a control group. Furthermore, the included cases were performed by a single surgeon. Nevertheless, this report addresses a lack of available literature on dural repair in uniportal full ESS.

CONCLUSION

In recent years, uniportal full ESS has emerged as an ultraminimally invasive approach for lumbar decompression. While it has numerous advantages over open and other minimally invasive techniques, repair of ID remains a challenge due to the narrow and deep surgical corridor, aqueous environment, single portal, and dearth of dedicated repair instruments and materials. We presented 3 cases of ID during uniportal full ESS that were repaired using a collagen matrix inlay technique. Prolonged bed rest was avoided, and all patients achieved excellent clinical outcomes without further complication. This technique may also be appropriate for other MISS techniques. Future randomized studies are needed to assess and compare dural repair techniques for uniportal full ESS.

REFERENCES

- Ghobrial GM, Theofanis T, Darden BV, Arnold P, Fehlings MG, Harrop JS. Unintended Durotomy in lumbar degenerative spinal surgery: A 10-year systematic review of the literature. *Neurosurg Focus*. 2015;39(4):E8. doi:10.3171/2015.7.FOCUS15266
- Strömqvist F, Jönsson B, Strömqvist B, Swedish Society of Spinal Surgeons. Dural lesions in decompression for lumbar spinal stenosis: incidence, risk factors and effect on outcome. *Eur Spine J*. 2012;21(5):825–828. doi:10.1007/s00586-011-2101-2
- Khan MH, Rihn J, Steele G, et al. Postoperative management protocol for incidental dural tears during degenerative lumbar spine surgery: A review of 3,183 consecutive degenerative lumbar cases. *Spine*. 2006;31(22):2609–2613. doi:10.1097/01.brs.0000241066.55849.41
- Wang JC, Bohlman HH, Riew KD. Dural tears secondary to operations on the lumbar spine. management and results after a two-year-minimum follow-up of eighty-eight patients. *J Bone Joint Surg Am*. 1998;80(12):1728–1732. doi:10.2106/00004623-199812000-00002
- Cammisa FP, Girardi FP, Sangani PK, Parvataneni HK, Cadag S, Sandhu HS. Incidental Durotomy in spine surgery. *Spine (Phila Pa 1976)*. 2000;25(20):2663–2667. doi:10.1097/00007632-200010150-00019
- Baker GA, Cizik AM, Bransford RJ, et al. Risk factors for unintended Durotomy during spine surgery: A multivariate analysis. *Spine J*. 2012;12(2):121–126. doi:10.1016/j.spinee.2012.01.012
- Pechlivanis I, Kuebler M, Harders A, Schmieder K. Perioperative complication rate of lumbar disc Microsurgery depending on the surgeon's level of training. *Cent Eur Neurosurg*. 2009;70(3):137–142. doi:10.1055/s-0029-1216361
- Jankowitz BT, Atteberry DS, Gerszten PC, et al. Effect of fibrin glue on the prevention of persistent cerebral spinal fluid leakage after incidental Durotomy during lumbar spinal surgery. *Eur Spine J*. 2009;18(8):1169–1174. doi:10.1007/s00586-009-0928-6
- Galarza M, Gazzeri R, Alfaro R, de la Rosa P, Arraez C, Piqueras C. Evaluation and management of small dural tears in primary lumbar spinal decompression and Discectomy surgery. *J Clin Neurosci*. 2018;50:177–182. doi:10.1016/j.jocn.2018.01.008

10. Rozen T, Swidan S, Hamel R, Saper J. Trendelenburg position: A tool to screen for the presence of a low CSF pressure syndrome in daily headache patients. *Headache*. 2008;48(9):1366–1371. doi:10.1111/j.1526-4610.2007.01027.x
11. Kaar GF, Briggs M, Bashir SH. Thecal repair in post-surgical Pseudomeningocele. *Br J Neurosurg*. 1994;8(6):703–707. doi:10.3109/02688699409101184
12. Lin T-Y, Chen W-J, Hsieh M-K, et al. Postoperative meningitis after spinal surgery: a review of 21 cases from 20,178 patients. *BMC Infect Dis*. 2014;14:220. doi:10.1186/1471-2334-14-220
13. Adogwa O, Huang MI, Thompson PM, et al. No difference in postoperative complications, pain, and functional outcomes up to 2 years after incidental Durotomy in lumbar spinal fusion: A prospective, multi-institutional, propensity-matched analysis of 1,741 patients. *Spine J*. 2014;14(9):1828–1834. doi:10.1016/j.spinee.2013.10.023
14. Schroeder GD, Kepler CK, Alijanipour P, et al. The economic implications of an incidental Durotomy. *Spine (Phila Pa 1976)*. 2016;41(19):1548–1553. doi:10.1097/BRS.0000000000001583
15. Desai A, Ball PA, Bekelis K, et al. Outcomes after incidental Durotomy during first-time lumbar Discectomy. *J Neurosurg Spine*. 2011;14(5):647–653. doi:10.3171/2011.1.SPINE10426
16. Jones AA, Stambough JL, Balderston RA, Rothman RH, Booth RE. Long-term results of lumbar spine surgery complicated by unintended incidental Durotomy. *Spine (Phila Pa 1976)*. 1989;14(4):443–446. doi:10.1097/00007632-198904000-00021
17. Saxler G, Krämer J, Barden B, Kurt A, Pförtner J, Bernsmann K. The long-term clinical sequelae of incidental Durotomy in lumbar disc surgery. *Spine (Phila Pa 1976)*. 2005;30(20):2298–2302. doi:10.1097/01.brs.0000182131.44670.f7
18. Alluri R, Kang HP, Bouz G, Wang J, Hah RJ. The true effect of a lumbar dural tear on complications and cost. *Spine (Phila Pa 1976)*. 2020;45(3):E155–E162. doi:10.1097/BRS.00000000000003213
19. Oppenheimer JH, DeCastro I, McDonnell DE. Minimally invasive spine technology and minimally invasive spine surgery: A historical review. *Neurosurg Focus*. 2009;27(3):E9. doi:10.3171/2009.7.FOCUS09121
20. McAfee PC, Garfin SR, Rodgers WB, Allen RT, Phillips F, Kim C. An attempt at clinically defining and assessing minimally invasive surgery compared with traditional "open" spinal surgery. *SAS J*. 2011;5(4):125–130. doi:10.1016/j.esas.2011.06.002
21. Simpson AK, Lightsey HM, Xiong GX, Crawford AM, Minamide A, Schoenfeld AJ. Spinal Endoscopy: Evidence, techniques, global trends, and future projections. *Spine J*. 2022;22(1):64–74. doi:10.1016/j.spinee.2021.07.004
22. Bombieri FF, Shafafy R, Elsayed S. Complications associated with lumbar Discectomy surgical techniques: A systematic review. *J Spine Surg*. 2022;8(3):377–389. doi:10.21037/jss-21-59
23. Park H-J, Kim S-K, Lee S-C, Kim W, Han S, Kang S-S. Dural tears in percutaneous Biportal endoscopic spine surgery: Anatomical location and management. *World Neurosurg*. 2020;136:e578–e585. doi:10.1016/j.wneu.2020.01.080
24. Lewandrowski K-U, Hellinger S, De Carvalho PST, et al. Dural tears during lumbar spinal Endoscopy: surgeon skill, training, incidence. *Int J Spine Surg*. 2021;15(2):280–294. doi:10.14444/8038
25. Lewandrowski K-U, Telfeian AE, Hellinger S, et al. Difficulties, challenges, and the learning curve of avoiding complications in lumbar endoscopic spine surgery. *Int J Spine Surg*. 2021;15(suppl 3):S21–S37. doi:10.14444/8161
26. Heo DH, Ha JS, Lee DC, Kim HS, Chung HJ. Repair of incidental Durotomy using Sutureless Nonpenetrating clips via Biportal endoscopic surgery. *Global Spine J*. 2022;12(3):452–457. doi:10.1177/2192568220956606
27. Kim HS, Raorane HD, Wu PH, Heo DH, Sharma SB, Jang I-T. Incidental Durotomy during endoscopic stenosis lumbar decompression: incidence, classification, and proposed management strategies. *World Neurosurgery*. 2020;139:e13–e22. doi:10.1016/j.wneu.2020.01.242
28. Shin JK, Youn MS, Seong YJ, Goh TS, Lee JS. Iatrogenic dural tear in endoscopic lumbar spinal surgery: Full endoscopic dural Suture repair (Youn's technique). *Eur Spine J*. 2018;27(Suppl 3):544–548. doi:10.1007/s00586-018-5637-6
29. Telfeian AE, Shen J, Ali R, Oyelese A, Fridley J, Gokaslan ZL. Incidence and implications of incidental Durotomy in Transforaminal endoscopic spine surgery: Case series. *World Neurosurg*. 2020;134:e951–e955. doi:10.1016/j.wneu.2019.11.045
30. Sen RD, White-Dzuro G, Ruzevick J, et al. Intra- and peri-operative complications associated with endoscopic spine surgery: A multi-institutional study. *World Neurosurg*. 2018;120:e1054–e1060. doi:10.1016/j.wneu.2018.09.009
31. Copay AG, Glassman SD, Subach BR, Berven S, Schuler TC, Carreon LY. Minimum clinically important difference in lumbar spine surgery patients: A choice of methods using the Oswestry disability index, medical outcomes study questionnaire short form 36, and pain scales. *Spine J*. 2008;8(6):968–974. doi:10.1016/j.spinee.2007.11.006
32. R Core Team. R: A language and environment for statistical computing. Vienna, Austria: R Foundation for Statistical Computing, 2021.
33. Huntington-Klein N. Vtable: Variable Table for Variable Documentation. <https://CRAN.R-project.org/package=vtable> 2021.
34. Stevenson M, Sergeant E, Nunes T, et al. epiR: Tools for the Analysis of Epidemiological Data. <https://CRAN.R-project.org/package=epiR> 2022.
35. Wickham H. ggplot2: Elegant Graphics for Data Analysis. <https://ggplot2.tidyverse.org> 2016.
36. Wickham H, Averick M, Bryan J, et al. Welcome to the Tidyverse. *JOSS*. 2019;4(43):1686. doi:10.21105/joss.01686
37. Wickham H, François R, Henry L, et al. dplyr: A Grammar of Data Manipulation. <https://CRAN.R-project.org/package=dplyr> 2022.
38. Kim KD, Ramanathan D, Highsmith J, et al. Dura-seal exact is a safe Adjunctive treatment for Durotomy in spine: Postapproval study. *Global Spine J*. 2019;9(3):272–278. doi:10.1177/2192568218791150
39. Sen RD, White-Dzuro G, Ruzevick J, et al. Intra-and peri-operative complications associated with endoscopic spine surgery: A multi-institutional study. *World Neurosurg*. 2018;120:e1054–e1060. doi:10.1016/j.wneu.2018.09.009
40. Soliman HM. Irrigation endoscopic Decompressive Laminotomy. A new endoscopic approach for spinal stenosis decompression. *Spine J*. 2015;15(10):2282–2289. doi:10.1016/j.spinee.2015.07.009
41. Ruban D, O'Toole JE. Management of incidental Durotomy in minimally invasive spine surgery. *Neurosurg Focus*. 2011;31(4):E15. doi:10.3171/2011.7.FOCUS11122
42. Than KD, Wang AC, Etame AB, La Marca F, Park P. Postoperative management of incidental Durotomy in minimally invasive lumbar spinal surgery. *Minim Invasive Neurosurg*. 2008;51(5):263–266. doi:10.1055/s-0028-1082313

43. Chou D, Wang VY, Khan AS. Primary dural repair during minimally invasive Microdiscectomy using standard operating room instruments. *Neurosurgery*. 2009;64(5 Suppl 2):356–358. doi:10.1227/01.NEU.0000338942.11337.DA

44. Shenoy K, Donnally CJ, Sheha ED, Khanna K, Prasad SK. An investigation of a novel dural repair device for intraoperative incidental Durotomy repair. *Front Surg*. 2021;8:642972. doi:10.3389/fsurg.2021.642972

Funding: The authors received no financial support for the research, authorship, and/or publication of this article.

Declaration of Conflicting Interests: PBD reports royalties, consulting, and speaking for Degen; royalties, consulting, and teaching for Accelus; teaching and consulting for Joimax; research support form Aesculap; and equity and serving on an advisory board for Goldfinch Health. MPRL: No disclosures. AMS reports consulting and royalties form Degen Medical

and stock options and serving on the scientific advisory board and for Agada Medical.

Editor's Note: This new Novel Techniques & Technology section is reserved for pilot studies, case series, and other preliminary investigations that may serve as the stepping stones for future long-term, scientifically rigorous research studies.

Corresponding Author: Peter B. Derman, Texas Back Institute, 6020 W Parker Rd, 200, Plano, TX 75093, USA; pderman@texasback.com

Published 09 June 2023

This manuscript is generously published free of charge by ISASS, the International Society for the Advancement of Spine Surgery. Copyright © 2023 ISASS. To see more or order reprints or permissions, see <http://ijssurgery.com>.