

Biplanar Expandable Cages for Transforaminal Lumbar Interbody Fusion Are Safe and Achieve Good 1-Year Clinical and Radiological Outcomes in an Asian Population

David Shaoen Sim, Ayyadarshan Kasivishvanaath, Lei Jiang, Reuben Chee Cheong Soh and Zhixing Marcus Ling

Int J Spine Surg 2023, 17 (4) 520-525

doi: <https://doi.org/10.14444/8472>

<https://www.ijssurgery.com/content/17/4/520>

This information is current as of May 3, 2025.

Email Alerts Receive free email-alerts when new articles cite this article. Sign up at:
<http://ijssurgery.com/alerts>

Biplanar Expandable Cages for Transforaminal Lumbar Interbody Fusion Are Safe and Achieve Good 1-Year Clinical and Radiological Outcomes in an Asian Population

DAVID SHAOEN SIM, MBChB¹; AYYADARSHAN KASIVISHVANAATH¹; LEI JIANG, FRCS¹; REUBEN CHEE CHEONG SOH, FRCS¹; AND ZHIXING MARCUS LING, FRCS¹

¹Department of Orthopaedic Surgery, Singapore General Hospital, Singapore, Singapore

ABSTRACT

Background: This study investigated 1-year clinical and radiological outcomes of biplanar expandable (BE) cages following transforaminal lumbar interbody fusion (TLIF) in an Asian population.

Methods: A retrospective review was conducted of all consecutive patients who underwent TLIF with BE cages performed by 2 fellowship-trained spine surgeons from 2020 to 2021. Inclusion criteria included open or minimally invasive (MIS) TLIF, of up to 3 spinal segments, performed for treatment of degenerative disc disease, spondylolisthesis, or spinal stenosis. Patient-reported outcomes, including visual analog score (VAS) for back and lower limb pain, Oswestry Disability Index (ODI) and North American Spine Society neurogenic symptom score (NSS), and various radiographic parameters, were evaluated.

Results: A total of 23 patients underwent TLIF with BE cages with a follow-up duration of 1.25 years. Of those patients, 7 (30%) underwent 1-level TLIF, 12 (52%) underwent 2-level TLIF, and 4 (18%) underwent 3-level TLIF, with a total of 43 spinal segments fused. Four patients (17%) underwent MIS TLIF while 19 patients (83%) underwent open TLIF. VAS for back pain scores improved by 4.8 ± 3.4 ($P < 0.001$) from 6.5 ± 2.6 to 1.7 ± 2.2 ; VAS for lower limb pain scores improved by 5.2 ± 3.8 ($P < 0.001$) from 5.7 ± 3.4 to 0.5 ± 1.6 ; ODI scores improved by 29.0 ± 18.1 ($P < 0.001$) from 49.4 ± 15.1 to 20.4 ± 14.2 ; and NSS scores improved by 36.8 ± 22.1 ($P < 0.001$) from 53.3 ± 21.1 to 16.5 ± 19.8 . Significant improvements in radiological parameters included increase in anterior disc height, posterior disc height, foraminal height, segmental lordosis, and lumbar lordosis. There were no implant-related complications, cage subsidence, cage migration, or revision surgery at 1 year.

Conclusions: TLIF performed with BE cages led to significantly improved patient-reported outcomes and radiographic parameters at 1 year and is safe for use in Asians.

Clinical Relevance: The results of this study support the effectiveness and safety of TLIF with biplanar expandable cages.

Level of Evidence: 4.

Lumbar Spine

Keywords: biplanar expandable cages, transforaminal lumbar interbody fusion, lumbar degenerative disc disease, spinal stenosis

INTRODUCTION

Biplanar expandable (BE) cages have been recently designed for use in transforaminal lumbar interbody fusion (TLIF) for treatment of spinal stenosis and spondylolisthesis as they offer advantages over conventional static cages and uniplanar expandable cages. The size of the static intervertebral cage that one can insert into the disc space is limited by the confines of Kambin's triangle, which is a narrow surgical corridor. Hence, expandable implants were developed to bridge the gap between the small size required during insertion and the maximum size desired for optimum anterior column support.¹ However, early uniplanar expandable cages only allowed cage expansion in a cranial-caudal axis,

which risks endplate violation and cage subsidence due to increased stress over a small endplate surface area in contact with the uniplanar expandable cage.² BE cages can expand in width and height, allowing for improved restoration of disc height and segmental lordosis with decreased theoretical risk of subsidence due to greater implant-endplate contact surface area.^{3,4}

The BE cage assessed in this study involves a 2-piece device consisting of an outer polyetheretherketone (PEEK) shell that expands bidirectionally with the insertion of an inner titanium shim.⁵ This cage has an open architecture design, which allows backfilling of bone graft and conforms to patient's endplate configuration.

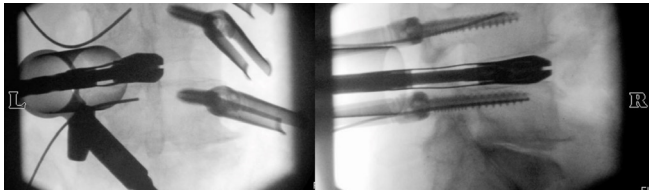


Figure 1. Intraoperative fluoroscopy of trial implants, anterior-posterior and lateral view.

Coric et al demonstrated preliminary evidence for the safety and effectiveness of BE cages for use in open and minimally invasive surgery (MIS) TLIF compared with that of other devices.⁶ These findings were replicated in another similar study performed in the United States by Tan et al.⁷ Their study, which focused on the use of BE cages in MIS TLIF, also demonstrated excellent improvement in radiological parameters.⁷ Both studies reported short-term results of less than 6 months and showed improvement in patient symptoms without any implant-associated adverse events.^{6,7} The aim of this current study is to evaluate midterm 1 year clinical and radiological outcomes, which have not been previously investigated. The efficacy and safety of BE cages in Asians can also be evaluated in this analysis conducted on a predominantly Asian demographic whose build may alter significantly from the Western population.

METHODS

Hypothesis

BE cages can achieve satisfactory 1 year clinical and radiological results for patients with degenerative lumbar spine conditions.

Patient Population

This is a retrospective review of prospectively collected data of all consecutive patients who underwent TLIF with BE cages performed in a single-tertiary orthopedic institution by 2 fellowship-trained spine surgeons from 2020 to 2021 with 1-year follow-up. This study was reviewed by our institution's ethics committee. Inclusion criteria were diagnosis of degenerative disc disease, spondylolisthesis, or spinal stenosis.




Figure 2. Outer polyetheretherketone shell, seen from the top and side.




Figure 3. Inner titanium shim, seen from the top and side.

1-level, 2-level, and 3-level lumbar fusions, performed using either open or MIS technique, were included in this study. Exclusion criteria were previous spinal fusion, infection, or malignancy.

Surgical Technique

TLIF was performed using previously well-described⁸ open or minimally invasive approaches. All patients underwent general anaesthesia and were positioned prone on a Jackson table. After exposure, preparation of the disc space was performed by removing the disc material using sequentially larger disc shavers, curettes, and pituitary rongeurs. Implant sizing was first estimated through preoperative templating, then determined using trial implants (Figure 1), and final verification was performed with intraoperative fluoroscopy. The outer PEEK shell (Figure 2) and inner titanium shim (Figure 3) were loaded in-line onto an inserter instrument (Figure 4), and the implants were then placed into the interbody space. After fluoroscopic confirmation of satisfactory cage position (Figure 5), biplanar expansion of the cage (Figure 6) was achieved via advancing the inner titanium shim into the outer PEEK shell (Figure 7), which was subsequently locked together. A combination of autologous bone graft and allogenic bone chips was postpacked into the expanded cage and posterior disc space through a funnel impactor. A laminectomy was then performed after the insertion of the BE cage to ensure that all affected neural elements at that level were thoroughly decompressed. The surgery was completed with the instrumentation of bilateral pedicles with screws and rods (Figure 8).




Figure 4. Outer polyetheretherketone (PEEK) shell and inner titanium shim loaded in-line onto inserter instrument, seen from the side (direction of advancement of inner titanium shim into outer PEEK shell as demonstrated by the black arrow).

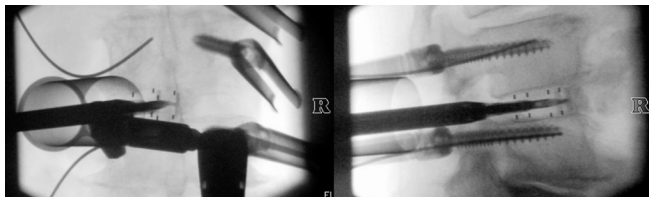


Figure 5. Intraoperative fluoroscopic confirmation of satisfactory cage position before expansion, anterior-posterior and lateral view.

Clinical and Radiological Outcomes

Outcomes evaluated included patient-reported outcomes (visual analog score [VAS] for back pain and lower limb pain, Oswestry Disability Index [ODI], and North American Spine Society neurogenic symptom score [NSS]) and radiographic parameters (segmental lordosis, anterior and posterior disc height, and foraminal height). All clinical assessments were performed by third-party independent health care professionals not involved in the study within our institutional Orthopedic Diagnostic Center using a standardized procedure at routine time intervals.

Standard anterior-posterior and lateral radiographs of the lumbar spine were also taken at routine time intervals, including preoperatively and at 1 year. Segmental lordosis was defined as the angle between the inferior endplate of the cephalad vertebral body and the superior endplate of the caudal vertebral body as previously utilized by Tan et al and Boktor et al.^{7,9} Anterior disc height was defined as the distance between the inferior endplate of the cephalad vertebra and the superior endplate of the caudal vertebra at the anterior vertebral body line as described by Hsieh et al.¹⁰ The posterior disc height was measured in a similar manner albeit at the posterior vertebral body line. Foraminal height was measured as the distance between the inferior pedicle wall of the level above and the superior pedicle wall of the level below.¹⁰ Radiographs were also evaluated for cage migration or subsidence as defined in previous studies.^{11–14}




Figure 6. Biplanar expansion in medial-lateral direction and cranial-caudal direction achieved with advancement of inner titanium shim into outer polyetheretherketone shell, seen from the top and side.

Statistical Analysis

Descriptive statistics were reported as means and SDs. Statistical analysis utilizing paired *t* test for continuous variables was used to evaluate the difference between preoperative and postoperative clinical and radiological outcomes. Clinical improvements were significant if they exceeded the minimum clinically important difference threshold of at least 10 points for ODI and at least 2 points (10-point scale) for VAS.¹⁵ Statistical significance was determined at $P < 0.05$.

RESULTS

A total of 23 patients who underwent TLIF with BE cages with an average follow-up duration of 1.25 ± 0.26 years were included in this study (Table 1). Of these patients, 8 were men. The mean age was 65.5 ± 9.0 years, and mean body mass index was 25.5 ± 3.6 . Four patients (17%) underwent MIS TLIF and 19 patients (83%) underwent open TLIF. Also, 7 patients (30%) underwent 1-level TLIF, 12 patients (52%) underwent 2-level TLIF, and 4 patients (18%) underwent 3-level TLIF, with a total of 43 spinal segments fused. Mean length of stay was 5.2 ± 2.9 days.

Scores on the VAS for back pain improved by 4.8 ± 3.4 ($P < 0.001$) from 6.5 ± 2.6 to 1.7 ± 2.2 ; VAS for lower limb pain improved by 5.2 ± 3.8 ($P < 0.001$) from 5.7 ± 3.4 to 0.5 ± 1.6 ; ODI improved by 29.0 ± 18.1 ($P < 0.001$) from 49.4 ± 15.1 to 20.4 ± 14.2 ; NSS improved by 36.8 ± 22.1 ($P < 0.001$) from 53.3 ± 21.1 to 16.5 ± 19.8 (Table 2). The proportion of patients achieving minimally clinically significant improvement for VAS for back pain, VAS for lower limb pain, ODI, and NSS were 91%, 94%, 87%, and 96%, respectively.

Mean anterior disc height increased by 3.2 ± 2.0 mm from 8.8 ± 2.7 to 12.0 ± 2.4 mm. Mean posterior disc height increased by 2.1 ± 1.5 mm from 5.3 ± 1.5 to 7.4

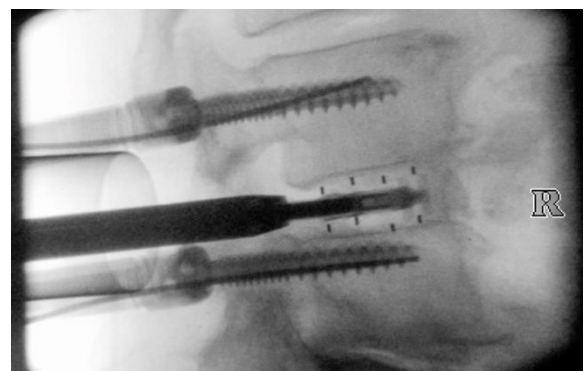


Figure 7. Biplanar expansion of the cage was achieved via advancing the inner titanium shim into the outer polyetheretherketone shell as visualized on lateral intraoperative fluoroscopy.

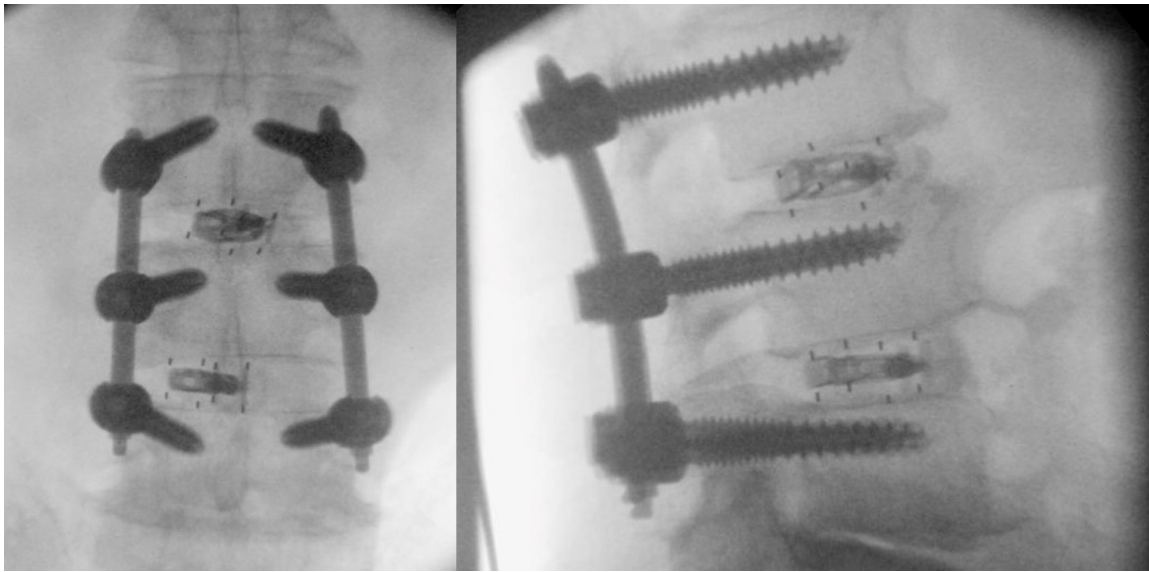


Figure 8. Final position of expanded cage with pedicle screws and rods inserted, anterior-posterior and lateral view.

± 1.5 mm. Mean foraminal height increased by 1.7 ± 1.7 mm from 12.1 ± 2.6 to 13.8 ± 2.9 mm. Mean segmental lordosis improved by $2.8^\circ \pm 2.2^\circ$ from $7.2^\circ \pm 3.9^\circ$ to $10.0^\circ \pm 3.3^\circ$. Mean lumbar lordosis improved by $6.1^\circ \pm 7.2^\circ$ from $36.5^\circ \pm 14.8^\circ$ to $42.6^\circ \pm 12.1^\circ$. The improvements in radiographic parameters were statistically significant ($P < 0.001$).

There were no implant-related complications or revision surgeries at 1 year. There was no incidence of subsidence or posterior cage migration in our patients. However, there were 2 incidences of durotomy, which occurred during laminectomy and decompression of neural elements. One patient had dura repair performed with 6–0 polypropylene sutures, and the other patient had the dura repaired with fibrin sealant patch and collagen-based dural graft. Both these patients were managed with 72 hours of bed rest and had their drains

removed after 24 hours. Both patients were able to ambulate independently afterward and did not experience symptoms of persistent dura leak, including headaches and wound complications.

DISCUSSION

We performed TLIF with BE cages on 23 patients, and most of them achieved clinically significant improvement across the board in ODI, NSS, and VAS for back pain, lower limb pain, and lower limb numbness. To our knowledge, there have only been 2 previous studies investigating the short-term outcomes following lumbar fusion with the same BE device used in the present study.^{6,7} We have been able to demonstrate that patients who underwent TLIF with BE cages have similar good results up to 1 year after surgery with most patients achieving the minimum clinically important difference.

This study demonstrated an improvement in segmental lordosis postoperatively by about 2.8° following TLIF with BE cage (Figure 9). Tan et al⁷ also reported an improvement in segmental lordosis of about 1.7° when using the same BE device used in the present study. Previous studies have shown that other types of expandable cages may have significant improvement in segmental lordosis after surgery,^{9,16} the improvement of segmental lordosis may be greater when compared with static cages^{17,18} and that improvement in segmental lordosis may be correlated with better clinical scores.¹⁷ There was also significant improvement in other radiological parameters following TLIF with BE cages, including

Table 1. Patient demographics, surgical approach, and surgery levels ($N = 23$).

Variable	<i>n</i> (%)
Age, y, mean (SD)	65.5 \pm 9.0
Body mass index, mean (SD)	25.5 \pm 3.6
Gender	
Male	8 (35%)
Female	15 (65%)
Approach	
Open	19 (83%)
MIS	4 (17%)
Levels	
1	7 (30%)
2	12 (52%)
3	4 (17%)
Spinal levels fused	43

Note: Data presented as *n* (%) unless otherwise noted.

Table 2. Clinical and radiological outcomes.

Biplanar Expandable Cage (n = 23)	Preoperative	Postoperative ^a	Difference	P Value	Achieved Minimum Clinically Important Difference (%)
Patient-reported outcome scores					
VAS back pain	6.5 ± 2.6	1.7 ± 2.2	-4.8 ± 3.4	<.001	91%
VAS lower limb pain	5.7 ± 3.4	0.5 ± 1.6	-5.2 ± 3.8	<.001	94%
Oswestry Disability Index	49.4 ± 15.1	20.4 ± 14.2	-29.0 ± 18.1	<.001	87%
Neurogenic symptom score	53.3 ± 21.1	16.5 ± 19.8	-36.8 ± 22.1	<.001	96%
Radiological outcomes					
Segmental lordosis, °	7.2 ± 3.9	10.0 ± 3.3	2.8 ± 2.2	<.001	-
Lumbar lordosis, °	36.5 ± 14.8	42.6 ± 12.1	6.1 ± 7.2	<.001	-
Anterior disc height, mm	8.8 ± 2.7	12.0 ± 2.4	3.2 ± 2.0	<.001	-
Posterior disc height, mm	5.3 ± 1.5	7.4 ± 1.5	2.1 ± 1.5	<.001	-
Foraminal height, mm	12.1 ± 2.6	13.8 ± 2.9	1.7 ± 1.7	<.001	-

Abbreviation: VAS, visual analog scale.

Note: Data presented as mean ± SD.

^aMean follow-up duration (y)—1.25 ± 0.26 (range, 0.94–1.79).

overall lumbar lordosis, anterior disc height, posterior disc height, and foraminal height.

We did not experience any implant-related complications in this study. This study replicates the positive findings found in previous studies on the same BE cage that also did not report any adverse events related to the implant.^{6,7} An assessment of the BE cage found that the open architecture design leads to better conformity with the contour of endplate,⁵ and this has been hypothesized to reduce endplate violation and implant subsidence. The open architecture design also allowed backfilling of bone graft.

The strengths of this study included the following: (1) longer follow-up of more than 1 year of patients who underwent BE cages for TLIF compared with the other studies available on the same type of implant, (2) patient-reported outcomes were assessed by independent

assessors not involved in the study as these clinical outcomes were collected as part of routine care, and (3) there were no patients lost to follow-up. Nevertheless, the investigation was conducted in a single institution and may limit the external validity of our results.

CONCLUSION

Early results of BE cages are promising, and BE cages may prove to be a useful tool in lumbar fusion surgery in the future. This study has shown that patients who underwent TLIF performed with BE cages have good results following surgery with significant improvement of their symptoms at 1 year. TLIF with BE cages also led to an improvement in segmental lordosis. Moreover, this study indicates that BE cages can be used safely in an Asian population while performing TLIF to treat

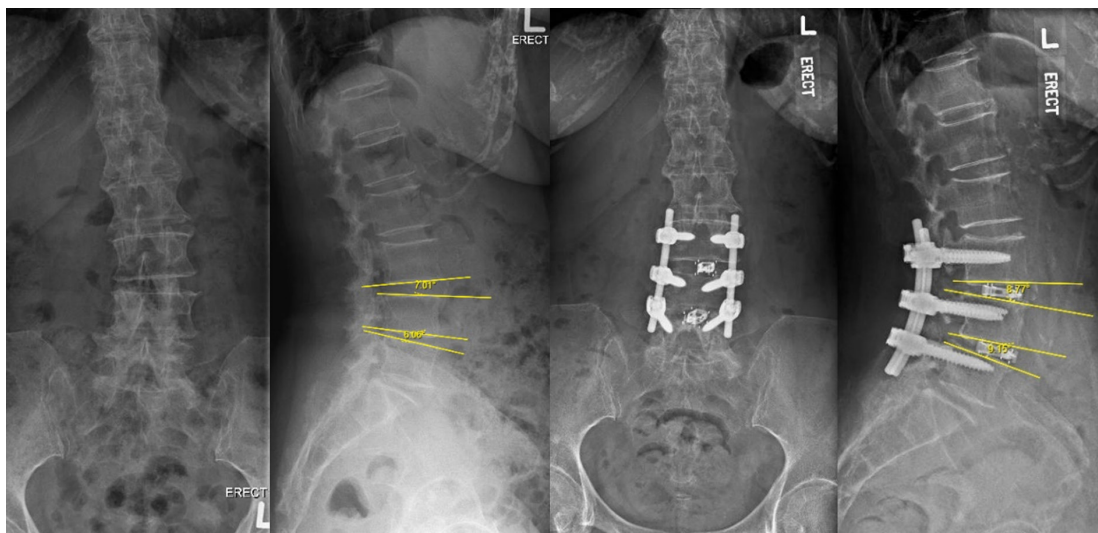


Figure 9. Preoperative and postoperative radiographs of open 2-level transforaminal lumbar interbody fusion performed on a 74-y-old patient who presented with neurogenic claudication.

common lumbar spine conditions. This is clinically relevant as Asians are typically of a smaller build compared with Westerners. Nevertheless, larger studies with longer follow-up duration are required to elucidate the unique potential benefits of BE cages.

REFERENCES

- Lewandrowski KU, Ferrara L, Cheng B. Expandable interbody fusion cages: an editorial on the surgeon's perspective on recent technological advances and their biomechanical implications. *Int J Spine Surg.* 2020;14(s3):S56–S62. doi:10.14444/7127
- Crandall DG, Chung AS, Lara N, Revella J. Risk factors for expandable cage subsidence in patients undergoing transforaminal lumbar interbody fusion. *The Spine Journal.* 2017;17(10):S188–S189. doi:10.1016/j.spinee.2017.08.030
- Cheng BC, Swink I, Yusufbekov R, et al. Current concepts of contemporary expandable lumbar interbody fusion cage designs, part 1: an editorial on their biomechanical characteristics. *Int J Spine Surg.* 2020;14(s3):S63–S67. doi:10.14444/7128
- Khechen B, Haws BE, Patel DV, et al. Static versus expandable devices provide similar clinical outcomes following minimally invasive transforaminal lumbar interbody fusion. *HSS J.* 2020;16(1):46–53. doi:10.1007/s11420-019-09677-z
- Cheng BC, Swink I, Yusufbekov R, Birgelen M, Ferrara L, Coric D. Current concepts of contemporary expandable lumbar interbody fusion cage designs, part 2: feasibility assessment of an endplate conforming bidirectional expandable interbody cage. *Int J Spine Surg.* 2020;14(s3):S68–S74. doi:10.14444/7129
- Coric D, Roybal RR, Grubb M, et al. Bidirectional expandable technology for transforaminal or posterior lumbar interbody fusion: a retrospective analysis of safety and performance. *Int J Spine Surg.* 2020;14(s3):S22–S30. doi:10.14444/7123
- Tan LA, Rivera J, Tan XA, Le VP, Khoo LT, Berven SH. Clinical and radiographic outcomes after minimally invasive transforaminal lumbar interbody fusion-early experience using a biplanar expandable cage for lumbar spondylolisthesis. *Int J Spine Surg.* 2020;14(s3):S39–S44. doi:10.14444/7125
- Sulaiman WAR, Singh M. Minimally invasive versus open transforaminal lumbar interbody fusion for degenerative spondylolisthesis grades 1-2: patient-reported clinical outcomes and cost-utility analysis. *Ochsner J.* 2014;14(1):32–37.
- Boktor JG, Pockett RD, Verghese N. The expandable transforaminal lumbar interbody fusion-two years follow-up. *J Craniovertebr Junction Spine.* 2018;9(1):50–55. doi:10.4103/jcvjs.JCVJS_21_18
- Hsieh PC, Koski TR, O'Shaughnessy BA, et al. Anterior lumbar interbody fusion in comparison with transforaminal lumbar interbody fusion: implications for the restoration of foraminal height, local disc angle, lumbar lordosis, and sagittal balance. *J Neurosurg Spine.* 2007;7(4):379–386. doi:10.3171/SPI-07/10/379
- Marchi L, Abdala N, Oliveira L, Amaral R, Coutinho E, Pimenta L. Radiographic and clinical evaluation of cage subsidence after stand-alone lateral interbody fusion. *J Neurosurg Spine.* 2013;19(1):110–118. doi:10.3171/2013.4.SPINE12319
- Parisien A, Wai EK, ElSayed MSA, Frei H. Subsidence of spinal fusion cages: a systematic review. *Int J Spine Surg.* 2022;16(6):1103–1118. doi:10.14444/8363
- Hu YH, Niu CC, Hsieh MK, Tsai TT, Chen WJ, Lai PL. Cage positioning as a risk factor for posterior cage migration following transforaminal lumbar interbody fusion-an analysis of 953 cases. *BMC Musculoskelet Disord.* 2019;20(1):260. doi:10.1186/s12891-019-2630-0
- Li H, Wang H, Zhu Y, Ding W, Wang Q. Incidence and risk factors of posterior cage migration following decompression and instrumented fusion for degenerative lumbar disorders. *Medicine (Baltimore).* 2017;96(33):e7804. doi:10.1097/MD.0000000000007804
- Ostelo RWJG, Deyo RA, Stratford P, et al. Interpreting change scores for pain and functional status in low back pain: towards international consensus regarding minimal important change. *Spine (Phila Pa 1976).* 2008;33(1):90–94. doi:10.1097/BRS.0b013e31815e3a10
- Russo AJ, Schopler SA, Stetzner KJ, Shirk T. Minimally invasive transforaminal lumbar interbody fusion with expandable articulating interbody spacers significantly improves radiographic outcomes compared to static interbody spacers. *J Spine Surg.* 2021;7(3):300–309. doi:10.21037/jss-20-630
- Hawasli AH, Khalifeh JM, Chatrath A, Yarbrough CK, Ray WZ. Minimally invasive transforaminal lumbar interbody fusion with expandable versus static interbody devices: radiographic assessment of sagittal segmental and pelvic parameters. *Neurosurg Focus.* 2017;43(2):E10. doi:10.3171/2017.5.FOCUS17197
- Alvi MA, Kurian SJ, Wahood W, Goyal A, Elder BD, Bydon M. Assessing the difference in clinical and radiologic outcomes between expandable cage and nonexpandable cage among patients undergoing minimally invasive transforaminal interbody fusion: a systematic review and meta-analysis. *World Neurosurg.* 2019;127:596–606. doi:10.1016/j.wneu.2019.03.284

Funding: The authors received no financial support for the research, authorship, and/or publication of this article.

Declaration of Conflicting Interests: The authors report no conflicts of interest in this work.

Patient Consent for Publication: Waiver of consent was obtained, and all data collected were part of routine clinical care. There was no direct interaction from patients required in this study. Data were deidentified before analysis.

Ethics Standards: Approval was obtained from the institution ethics committee. The procedures used in this study adhere to the tenets of the Declaration of Helsinki.

Corresponding Author: David Shaoen Sim, Department of Orthopaedic Surgery, Singapore General Hospital, 18 Wilkinson Rd, Singapore 436674, Singapore; davidssimshaoen@gmail.com

Published 18 April 2023

This manuscript is generously published free of charge by ISASS, the International Society for the Advancement of Spine Surgery. Copyright © 2023 ISASS. To see more or order reprints or permissions, see <http://ijssurgery.com>.