

## Nonoperative Management of Isolated Thoracolumbar Flexion Distraction Injuries: A Single-Center Study

Reed Butler, Connor Donley, Zuhair Mohammed, Jacob Lepard, Eric Vess, Nicholas Andrews, Gerald McGwin, Sakthivel Rajaram and Steven M. Theiss

*Int J Spine Surg* 2024, 18 (4) 383-388

doi: <https://doi.org/10.14444/8619>

<https://www.ijssurgery.com/content/18/4/383>

This information is current as of May 3, 2025.


---

**Email Alerts** Receive free email-alerts when new articles cite this article. Sign up at:  
<http://ijssurgery.com/alerts>

# Nonoperative Management of Isolated Thoracolumbar Flexion Distraction Injuries: A Single-Center Study

REED BUTLER, MD<sup>1</sup>; CONNOR DONLEY, MD<sup>1</sup>; ZUHAIR MOHAMMED, BS<sup>1</sup>; JACOB LEPARD, MD<sup>1</sup>;  
ERIC VESS, MD<sup>1</sup>; NICHOLAS ANDREWS, MD<sup>1</sup>; GERALD MCGWIN, PhD<sup>2</sup>; SAKTHIVEL RAJARAM, MD<sup>1</sup>; AND  
STEVEN M. THEISS, MD<sup>1</sup>

<sup>1</sup>Department of Orthopedic Surgery, University of Alabama at Birmingham, Birmingham, Alabama, USA; <sup>2</sup>Department of Epidemiology, School of Public Health, University of Alabama at Birmingham, Birmingham, Alabama, USA

 SMT, 332411050

## ABSTRACT

**Background:** Nonoperative management is an appealing option for purely transosseous thoracolumbar flexion-distraction injuries given the prospects of osseous healing and restoration of the posterior tension band complex. This study seeks to examine differences in outcomes following flexion-distraction injuries after operative and nonoperative management.

**Methods:** This study reviews all patients at a single Level 1 trauma center from 2004 to 2022 with AO Spine B1 thoracolumbar injuries treated operatively vs nonoperatively. Inclusion criteria were age greater than 16 years, computed tomography-confirmed transosseous flexion-distraction injuries, and at least 3 months of follow-up with available imaging. The primary outcome assessed was a change in local Cobb angles, with secondary outcomes consisting of complications, time to return to work, and need for subsequent operative fixation.

**Results:** Initial Cobb angles in the operative ( $n = 14$ ) vs nonoperative group ( $n = 13$ ) were  $-5^\circ$  and  $-13^\circ$ , respectively ( $P = 0.225$ ), indicating kyphotic alignment in both cohorts. We noted a significant difference in Cobb angles between cohorts at first follow-up ( $2.6^\circ$  and  $-13.9^\circ$ ,  $P = 0.015$ ) and within the operative cohort from presentation to first follow-up ( $P = 0.029$ ). At the second follow-up, there was no significant difference in Cobb angles between cohorts ( $3.6^\circ$  and  $-12.6^\circ$ ,  $P = 0.07$ ). No significant differences were noted in complication rates ( $P = 1$ ), time to return to work ( $P = 0.193$ ), or resolution of subjective back pain ( $P = 0.193$ ). No crossover was noted.

**Conclusions:** Nonoperative management of minimally displaced transosseous flexion-distraction injuries is a safe alternative to surgery. Patient factors, such as compliance with follow-up, and location of the injury should be factored into the surgeon's management recommendation.

**Clinical Relevance:** Overall, no significant differences in outcomes and complications were noted following nonoperative management of AO Spine B1 injuries, indicating the potential for these injuries to be managed conservatively.

**Level of Evidence:** 3.

Other and Special Categories

Keywords: chance fracture, flexion-distraction injury, trans-osseous tension band injury, B1

## INTRODUCTION

Monosegmental transosseous fractures of the thoracolumbar spine result from a flexion-distraction mechanism and are frequently seen after motor vehicle collisions or falls. They consist of a transverse fracture through the body of the vertebrae that extends posteriorly through the pedicles and often the spinous process.<sup>1,2</sup> These injuries can be devastating, and the incidence of associated neurological injury has been reported to be as high as 25%.<sup>3</sup> Using the AO Spine Injury Classification System published in 2013, these fractures fall under the Type-B “Tension Band” injuries, defined as failure of the posterior constraining elements

(facet joints and posterior ligamentous structures), which are further subdivided into Type B1, transosseous disruption of tension band, and B2, ligamentous disruption with or without osseous involvement.<sup>1–5</sup>

Type B1 flexion-distraction injuries, classically referred to as “bony Chance” fractures, present an opportunity for nonoperative management given their purely osseous nature of injury. Thus, osseous healing can result in the restoration of posterior tension band anatomy. A few studies and case reports previously demonstrated satisfactory outcomes with nonoperative management. However, to our knowledge, no studies in the past 30 years have directly compared outcomes between operative and nonoperative management of

B1 flexion-distraction injuries. Meanwhile, the recommendation remains for patients with these injuries to be treated operatively.<sup>6-9</sup>

Our hypothesis is that these injuries can be effectively treated nonoperatively due to their trans-osseous nature, thus facilitating bony union and restoration of the tension band complex. In this study, we sought to examine clinical and radiographic outcomes in AO Type B1 injuries treated operatively vs nonoperatively. We analyzed local Cobb angles, postoperative complications, and return to work status between the 2 cohorts to determine whether any statistical or clinically significant differences existed.

## MATERIALS AND METHODS

Following institutional review board approval, a retrospective review was conducted by retrieving computed tomography (CT) and/or magnetic resonance imaging studies utilizing Primordial (Nuance, Burlington, MA), with keywords “Chance” or “flexion-distraction” or “bony Chance” in the report, from a single Level 1 trauma center from 2004 to 2021. Inclusion criteria were age >16 years and neurologically intact B1 spinal injuries, as determined according to the AO Spine thoracolumbar injury classification system, identified by CT.<sup>5</sup> Exclusion criteria were prior thoracolumbar surgery; additional spine fractures and/or injuries given increased instability; and pre-existing spine enthesopathies such as seronegative spondyloarthropathies and diffuse idiopathic skeletal hyperostosis, given increased spine rigidity and fragility. In total, 333 patients were screened, with 35 B1 injuries isolated. Twenty-seven patients ultimately met the inclusion criteria for the study (Figure 1). All injuries were classified as AO Spine B1 fractures via CT at the time of presentation.

Magnetic resonance imaging, when obtained, was also used to confirm injury classification.

Patients were divided into 2 cohorts based on initial treatment—operative and nonoperative. Nonoperative patients received a thoracolumbar-sacral orthosis, which they were instructed to wear for comfort as needed. Nonoperative patients were monitored for complications and/or progression to operative treatment. Patients treated operatively were noted for the type of surgery and the number of levels involved. The primary outcome analyzed was local Cobb angles, measured as the angle between the superior endplate of the vertebral segment above the level of injury and the inferior endplate of the vertebral segment below (fracture level - 1 to fracture level + 1). Cobb angle on presentation was measured using sagittal CT, and measurements at follow-up were taken using standing x-ray imaging. Additional patient data collected included demographics, injury characteristics, and outcomes. Outcomes consisted of any complications, length of hospital stay, time to return to work, and mean follow-up length. In addition, nonoperative patients were noted for progression to operative fixation. All patients showed radiographic healing prior to discharge from follow-up.

Descriptive statistics were used to summarize demographic factors. Analysis of proportions for categorical variables was assessed using the Fisher exact test, and for continuous variables, an independent *t* test was employed. Given the slightly skewed distributions of the kyphosis measurements and follow-up lengths, Kruskal-Wallis tests were used to compare radiographic parameters. Significance was determined by  $P < 0.05$  using 2-tail testing. All statistical analyses were performed using SAS software (SAS Institute Inc., Cary, NC, USA).

## RESULTS

Of the 27 patients included in our analysis, 13 (48%) patients were initially treated nonoperatively. The mean age of the operative and nonoperative cohorts was 34 and 31 years, respectively ( $P = 0.538$ ). Additional patient demographics and baseline characteristics are shown in Table 1. The groups did not differ in terms of body mass index, sex, diabetes, or smoking status. The most common mechanism of injury was motor vehicle collision ( $n = 19$ ; 68%), and the remainder were also considered high-energy mechanisms (motorcycle collision, fall from height). The most common location of injury in both cohorts was at the thoracolumbar junction (T12–L1), occurring in 48% of patients (13/27).

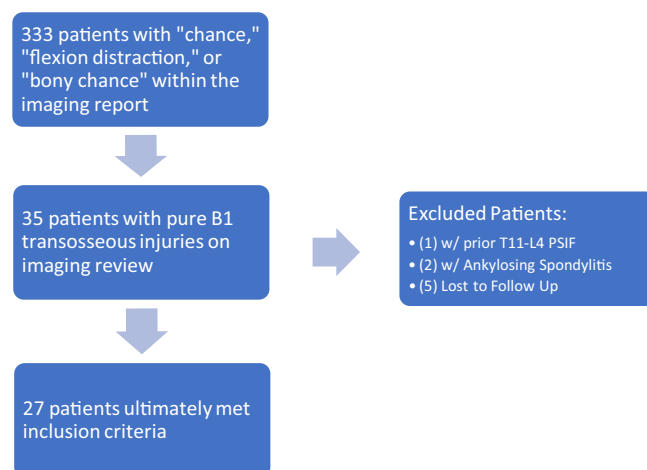


Figure 1. Patient flow chart.

**Table 1.** Comparison of patient, injury, and treatment characteristics by treatment group.

Variable	Operative (n = 14)	Nonoperative (n = 13)	P
Age, y	34.4 (12.7)	31.2 (13.9)	0.538
Body mass index	27.7 (5.6)	27.9 (6)	0.956
Sex			
Men	5 (36%)	3 (23%)	0.678
Women	9 (64%)	10 (77%)	
Tobacco use status <sup>a</sup>			
Nonsmoker	5 (38%)	6 (50%)	0.695
Active smoker	8 (62%)	6 (50%)	
Diabetes	1 (7%)	3 (23%)	0.326
High energy mechanism of injury	14 (100%)	12 (92%)	0.482
Intra-abdominal injury	3 (21%)	2 (15%)	>0.99
Laparotomy	0 (0%)	1 (8%)	0.482
Location			
Mid-thoracic (T6–9)	1 (7%)	0 (0%)	0.206
Low-thoracic (T10–1)	1 (7%)	5 (38%)	
Thoracolumbar junction (T12–L1)	7 (50%)	6 (46%)	
Upper lumbar (L2–3)	2 (14%)	0 (0%)	
Lower lumbar (L4–5)	3 (21%)	2 (15%)	
Concomitant injuries			
Extremity fractures	4 (29%)	3 (23%)	
Axial fractures	8 (57%)	5 (38%)	
Sternal fractures	1 (7%)	1 (7%)	
Head injuries	4 (29%)	6 (46%)	

Note: Data presented as mean (SD) for continuous variables and *n* (%) for categorical variables.

<sup>a</sup>Smoker status was missing for 1 patient in each cohort.

Treatment characteristics and outcomes for both the operative and nonoperative groups are shown in Table 2. Eleven patients (79%) underwent open posterior spinal instrumentation and fusion, and 3 (21%)

**Table 2.** Treatment characteristics and clinical outcomes by treatment group.

Characteristic	Operative (n = 14)	Nonoperative (n = 13)	P
Surgical technique			
Posterior spinal instrumentation and fusion	11 (79%)	-	-
MIS posterior spinal instrumentation	3 (21%)	-	-
Decompression	1 (7%)	-	-
Levels of surgical intervention			
2	9 (64%)	-	
3	1 (7%)	-	
4	4 (29%)	-	
Brace (thoracolumbar-sacral orthosis) prescribed	-	13 (100%)	-
Brace duration, d (n = 10)	-	54.6 (14.4) <sup>a</sup>	-
Complications/unintended reoperations	1 (7%)	0 (0%)	>0.99
Length of stay, d	7.6 (6.2)	4.3 (4.3)	0.12
Return to work, wk	20.5 (15.9) <sup>b</sup>	11.8 (6.8) <sup>c</sup>	0.154
Follow-up duration, wk	43.3 (53.2)	10.8 (6.5)	0.02 <sup>d</sup>

Abbreviation: MIS, minimally invasive surgery.

Note: Data presented as mean (SD) for continuous variables and *n* (%) for categorical variables.

<sup>a</sup>*n* = 10.

<sup>b</sup>*n* = 8.

<sup>c</sup>*n* = 9.

<sup>d</sup>Kruskal-Wallis test used. Statistically significant at *P* < 0.05.

were treated with minimally invasive (MIS) posterior spinal instrumentation. A 2-level surgery, meaning the level above and below the affected vertebrae, was the most performed operation, with 9 patients (64%), followed by 4 patients (29%) undergoing a 4-level operation (2 levels above and 2 levels below). All nonoperative patients were treated with a thoracolumbar-sacral orthosis brace, with a mean usage of 54.6 days (*n* = 10). There were no complications or unintended secondary procedures in the nonoperative group. One patient in the operative group underwent reoperation; however, this was an elective hardware removal to permit their return to active military duty.

The mean length of inpatient hospital stay in the operative vs nonoperative groups was not statistically significant (7.6 vs 4.3, *P* = 0.12). Time to return to work from injury did not differ significantly between the operative vs nonoperative cohorts (20.5 weeks vs 11.8 weeks, *P* = 0.154). The length of follow-up differed significantly between the 2 groups, with a mean of 43.3 weeks in the operative group and a mean of 10.8 weeks in the nonoperative (*P* = 0.02).

## Radiographic Outcomes

Radiographic outcomes are listed and compared in Table 3, where positive values indicate local lordotic alignment and negative values indicate local kyphotic alignment around the fractured vertebrae. There was no significant difference between initial Cobb angles of the operative and nonoperative groups, with a mean Cobb angle of −5 (SD 20.5, range −43.5 to 33) and −13 (SD 13.4, range −31.8 to 14.1), respectively (*P* = 0.225), indicating both groups were initially in local kyphosis after injury.

Length to first follow-up was not significantly different between the operative and nonoperative cohorts (40.7 days vs 39.7 days, *P* = 0.892). At initial follow-up, Cobb angles were significantly different (*P* = 0.015), with the operative cohort on average having 2.6° of lordosis (SD 17, range −15.1 to 42), while the nonoperative group had a mean Cobb value of −13.9° (SD 15, range −34 to 16.8). Likewise, the average change in Cobb angle between presentation and first follow-up was significantly different between the 2 groups, as the operative cohort gained on average 7.6° of lordosis (SD 10.9, interquartile range [IQR] −8.3 to 34.8; *P* = 0.02), while the nonoperative group averaged a −0.9° (SD 5.1, range −13.7 to 6.1; *P* = 0.875) change in Cobb angle.

Second follow-up occurred at, on average, 148.3 days from injury (SD 126, IQR 45–430; *n* = 11) in the operative group and at 86.6 days (SD 49.9, 40–166; *n* = 8) in the nonoperative group (*P* = 0.212). Three patients

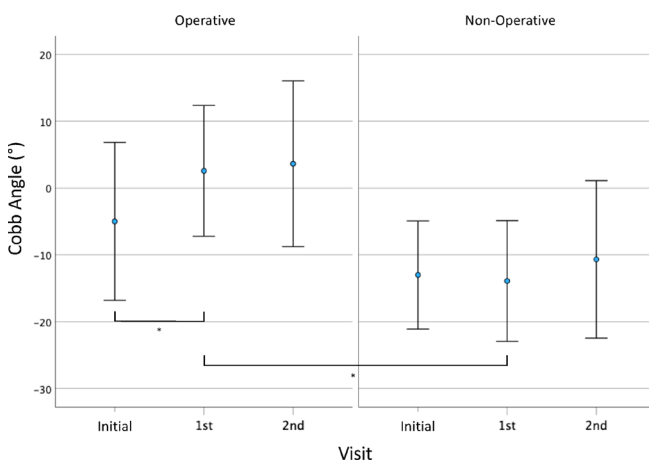
**Table 3.** Comparison of radiographic outcomes.

Variable	Operative (n = 14)	Nonoperative (n = 13)	P
Initial Cobb angle (°)	-5° ± 20.5° (-43.5 to 33)	-13° ± 13.4° (-31.8 to 14.1)	0.225 <sup>a</sup>
First follow-up			
Days at first follow-up	40.7 ± 21.9 (17–97)	39.7 ± 16 (16–64)	0.892
Cobb angle at first follow-up (°)	2.6° ± 17° (-15.1 to 42)	-13.9° ± 15° (-34 to 16.8)	<b>0.015<sup>a</sup></b>
Change in Cobb angle from presentation (°)	7.6° ± 10.9° (-8.3 to 34.8)	-0.9° ± 5.1° (-13.7 to 6.1)	0.029 <sup>a</sup>
Second follow-up			
Patients lost prior to second follow-up	3 (21%)	5 (38.5%)	0.42
Days at second follow-up	148.3 ± 126.6 (45–430)	86.6 ± 49.9 (40–166)	0.212
Cobb angle at second follow-up (°)	3.6° ± 18.4° (-16 to 43)	-12° ± 15.8° (-32.4 to 16.3)	0.07 <sup>a</sup>
Change in Cobb angle from presentation (°)	4.1° ± 8.9° (-14.6 to 12.4)	-1.4° ± 3.1° (-5.1 to 2.8)	0.117 <sup>a</sup>
Change in Cobb angle from first follow-up (°)	-1.2° ± 2.3° (-6.2 to 2.1)	-1.1° ± 2.4° (-4.8 to 2.1)	0.869 <sup>a</sup>

Note: Data presented as mean ± SD (range) or n (%). A negative value and negative change indicates the presence of kyphosis or the addition of kyphosis. Boldface indicates a statistically significant difference.

<sup>a</sup>Kruskal-Wallis test employed; Kyphosis° (kyphosis angle).

(21%) in the operative group and 5 patients (38.5%) in the nonoperative group were lost to follow-up prior to their second postoperative visit ( $P = 0.41$ ). The operative group preserved a slight local lordosis, 3.6° (SD 18.4, range -16 to 43) with an average change of 4.1° (SD 8.9, -14.6 to 12.4;  $P = 0.155$ ) from initial measurements. In contrast, the nonoperative cohort maintained kyphosis at the injured segment, with a mean Cobb angle of -12° (SD 15.8, -32.4 to 16.3) at the second follow-up and an average change of -1.4° (SD 3.1, -2.8 to 5.1;  $P = 0.31$ ) in Cobb angle from the presentation. The difference in Cobb angles between the operative and nonoperative groups approached significance ( $P = 0.07$ ). The results noted, however, are confounded by the high rates of patient drop-out and variability in follow-up between the cohorts. Our radiographic results are summarized in Figure 2.



**Figure 2.** Lumbar Cobb angles following the intervention as measured radiographically (±95% CI). Positive equals local lordosis and negative equals local kyphosis. The asterisk denotes statistical significance at  $P < 0.05$ .

## DISCUSSION

AO Spine B1 flexion-distraction injuries are unique among flexion-distraction injuries due to their purely osseous nature, thus raising the prospect of osseous union with restoration of the posterior tension band complex. Our results raise the viability of nonoperative treatment. We report the successful treatment of 13 flexion-distraction injuries with nonoperative management, and we noted no significant progression of kyphosis and no significant complications compared with surgical management. Our results are corroborated by historical literature. Gumley et al reported in 1982 on a cohort of 20 patients, 10 of whom were treated nonoperatively with either extension casting or Boston bracing along with a 6- to 8-week period of abdominal and paraspinal muscle strengthening. Nine patients in extension casting went on to osseous union, while 1 patient with Boston bracing underwent asymptomatic nonunion.<sup>10</sup> Similarly, Anderson et al reported on the successful nonoperative management of 7 flexion-distraction injuries, with hyperextension casting and bracing for 3 to 6 months. They allowed for immediate ambulation after brace or cast application. Both the operative and conservative cohorts in the study went on to osseous union.<sup>6</sup>

One of the biggest concerns with nonoperative management of B1 injuries is radiographic progression of kyphosis, which could potentiate neurological injury but more commonly is attributed to persistent back pain. Anderson et al reported a 6° kyphotic progression in the nonoperative cohort at the final follow-up.<sup>6</sup> Likewise, Gertzbein and Brown treated 5 patients conservatively and showed a 1.7° kyphotic progression in their nonoperative group at follow-up.<sup>7</sup> Our nonoperative cohort had 1.4° of kyphotic progression at the final follow-up, while our operative cohort experienced 4.1° of lordotic correction attributable to fixation with a



lordosis-inducing rod. In the nonoperative cohort, Cobb angles measured at the first and second follow-ups were not significantly different from their Cobb angles at presentation ( $P = 0.875$  and  $0.263$ , respectively). This indicates a lack of significant kyphotic progression in our nonoperative cohort, which supports the overall stability of nonoperative injuries. This is also reflected in our secondary outcomes as we noted similar rates of resolution of back pain and no significant difference in complications, in particular no neurological injuries, thus demonstrating that B1 fractures can successfully be treated nonoperatively with noninferior outcomes compared with those that were treated operatively.

Anderson et al reported several criteria for nonoperative management, including bony Chance injuries (type B1),  $<10^\circ$  of kyphosis at presentation, and lack of neurological deficits. Surgical management was indicated in patients with  $>15^\circ$  of kyphosis at presentation, neurological deficits, ligamentous injuries, and injuries at multiple levels.<sup>6</sup> In our nonoperative cohort, we noted 7 patients above the  $15^\circ$  threshold proposed for surgical management. This cohort maintained kyphotic stability through follow-up, and all went on to osseous union. Thus, we note that the degree of kyphotic deformity should not serve as a barrier to nonoperative management, as patients with severe kyphotic deformities can still go on to successful union without further collapse, but it certainly should remain as a consideration.

With regard to brace usage, we did not mandate 24/7 bracing as in some previous studies, but we offered bracing for comfort in our nonoperative cohort. We noted a mean of 55 days of brace usage per patient report at follow-up visits but were unable to quantify hours per day spent in the brace. Of note, the literature indicates that brace utilization is not a prerequisite for success in the nonoperative treatment of thoracolumbar fractures; in a systematic review and meta-analysis of randomized controlled trials, Linhares et al found that across 267 patients, there were no differences in outcomes in thoracolumbar fractures treated nonoperatively with thoracolumbar orthosis vs those treated without an orthosis.<sup>11,12</sup> In summary, we are unable to offer any strong recommendations with regard to brace wear; however, we echo the current literature that bracing likely has little impact on outcomes in terms of fracture healing.

Our findings of operative intervention adding corrective lordosis corroborate previously reported outcomes of flexion-distraction injuries.<sup>13</sup> The significant change in Cobb angles seen at the first follow-up, with corrective lordosis, was maintained at the second follow-up. We

noted a significant difference in Cobb angles between the nonoperative and operative cohorts at the first follow-up, as well as a significant difference in change in Cobb angle from presentation to first follow-up between the cohorts. The only reoperation performed was a hardware removal for a patient to return to active military duty. While open posterior spinal instrumentation and fusion was the most common treatment of choice in our study, MIS pedicle screw fixation techniques have recently shown comparable radiographic corrections to open posterior fusion and are now a widely accepted for bony Chance fractures.<sup>14</sup> This trend was reflected within our own cohort, as the 3 patients treated with MIS fusion were all performed in the past 5 years. We did not perform an analysis on these 3 patients due to power limitations—future studies more adequately powered can better examine outcomes following different surgical techniques.

While the length of hospital stay between the 2 groups did not reach statistical significance, on average, the nonoperative cohort spent 3.3 fewer days in the hospital. This likely has a significant clinical difference in terms of the cost and resource utility of the patient's hospitalization. Likewise, time to return to work from date of injury was not statistically significantly different between the 2 cohorts. However, the nonoperative cohort returned to work on average nearly 9 weeks sooner than the operative group, which also was likely clinically significant in terms of reduction of lost wages and maintenance of employment. An all cost-analysis was beyond the scope of this study.

## Limitations

Our study was limited by the rare nature of the injury pattern and, therefore, the small sample size. Chance fractures traditionally occur secondary to spine hyperflexion around a lap seatbelt during a motor vehicle accident.<sup>6</sup> With the advent of shoulder belts as standard automotive equipment, these injuries have become rarer. As a result, we lacked sufficient power to make comparative analysis within cohorts to better understand patient and injury characteristics best suited for nonoperative treatment, such as anatomic region. Additionally, due to the retrospective nature of our study and the inclusion of multiple surgeons, it is likely that the threshold for operative vs nonoperative management was not consistent throughout each cohort. The inclusion of multiple centers with a long-term prospective study may be the only way to accurately profile outcomes in these rare injuries. A final important limitation of our study is the relatively short-term follow-up that frequently occurs in

trauma populations before and after the completion of treatment. As a result, we do not yet know the long-term implications of operative vs nonoperative management in these patients. Specifically, focal segmental kyphosis may have a negative impact on global sagittal balance, and the long-term implications of such have yet to be determined. Until this is better studied, it should be a component of shared decision-making between patient and provider in deciding between operative and nonoperative management of these fractures.

## CONCLUSION

Isolated pure bony B1 Chance fractures without neurological compromise can safely be managed nonoperatively. While our data show that the risk of worsening kyphotic deformity and progression to surgical intervention is minimal, we advocate for each patient to be treated independently and at their surgeon's discretion. These data should be used simply to aid in decision-making. We still agree with the paucity of literature that patients with polytraumatic injuries, poor functional status, multilevel spinal injuries, and neurological deficits should be treated operatively with spinal instrumentation and fusion. The upper limits of kyphotic deformity and whether outcome differences exist based on fracture location for nonoperative treatment still need to be further delineated via higher-powered multicenter studies.

## REFERENCES

1. Reinhold M, Audigé L, Schnake KJ, Bellabarba C, Dai LY, Oner FC. AO Spine injury classification system: a revision proposal for the thoracic and lumbar spine. *Eur Spine J*. 2013;22(10):2184–2201. doi:10.1007/s00586-013-2738-0
2. Schnake KJ, Schroeder GD, Vaccaro AR, Oner C. AO Spine classification systems (subaxial, thoracolumbar). *J Orthop Trauma*. 2017;31 Suppl 4:S14–S23. doi:10.1097/BOT.0000000000000947
3. Chapman JR, Agel J, Jurkovich GJ, Bellabarba C. Thoracolumbar flexion-distraction injuries: associated morbidity and neurological outcomes. *Spine*. 2008;33(6):648–657. doi:10.1097/BRS.0b013e318166df7b
4. Magerl F, Aebi M, Gertzbein SD, Harms J, Nazarian S. A comprehensive classification of thoracic and lumbar injuries. *Eur Spine J*. 1994;3(4):184–201. doi:10.1007/BF02221591
5. Vaccaro AR, Oner C, Kepler CK, et al. AOSpine thoracolumbar spine injury classification system: fracture description, neurological status, and key modifiers. *Spine*. 2013;38(23):2028–2037. doi:10.1097/BRS.0b013e3182a8a381
6. Anderson PA, Henley MB, Rivara FP, Maier RV. Flexion distraction and chance injuries to the thoracolumbar spine. *J Orthop Trauma*. 1991;5(2):153–160. doi:10.1097/00005131-199105020-00006
7. Gertzbein SD, Court-Brown CM. Rationale for the management of flexion-distraction injuries of the thoracolumbar spine based on a new classification. *J Spinal Disord*. 1989;2(3):176–183.
8. Hakozaiki M, Otani K, Kikuchi S, Konno S. Chance fracture of the lumbar spine in an amateur snowboarder: a case report. *J Sports Med Phys Fitness*. 2010;50(2):214–216.
9. Okunlola AI, Adeolu AA. Chance fracture in an unbelted rear seat passenger. *J Neurosci Rural Pract*. 2019;10(1):151–153. doi:10.4103/jnpr.jnpr\_164\_18
10. Gumley G, Taylor TK, Ryan MD. Distraction fractures of the lumbar spine. *J Bone Joint Surg Br*. 1982;64(5):520–525. doi:10.1302/0301-620X.64B5.7142258
11. Linhares D, Pinto BS, Ribeiro da Silva M, Neves N, Fonseca JA. Orthosis in thoracolumbar fractures: a systematic review and meta-analysis of randomized controlled trials. *Spine*. 2020;45(22):E1523–E1531. doi:10.1097/BRS.0000000000003655
12. Linhares D, Sousa-Pinto B, Ribeiro da Silva M, Fonseca JA, Neves N. Use and cost of orthosis in conservative treatment of acute thoracolumbar fractures: a survey of European and North American experts. *Spine*. 2021;46(9):E534–E541. doi:10.1097/BRS.0000000000003769
13. Lopez AJ, Scheer JK, Smith ZA, Dahdaleh NS. Management of flexion distraction injuries to the thoracolumbar spine. *J Clin Neurosci*. 2015;22(12):1853–1856. doi:10.1016/j.jocn.2015.03.062
14. Grossbach AJ, Dahdaleh NS, Abel TJ, Woods GD, Dlouhy BJ, Hitchon PW. Flexion-distraction injuries of the thoracolumbar spine: open fusion versus percutaneous pedicle screw fixation. *Neurosurg Focus*. 2013;35(2):E2. doi:10.3171/2013.6.FOCUS13176

**Funding:** No funding was provided for the present study.

**Declaration of Conflicting Interests:** Sakthivel Rajaram has previously received grant funding from K2M and AO Spine North America and previously received consulting fees from Cerapedics. Steven Thiess has previously received grant funding from AO Spine North America. The remaining authors have nothing to disclose.

**Corresponding Author:** Steven M. Thiess, Department of Orthopaedic Surgery, University of Alabama at Birmingham, 510 20th St South, Faculty Office Tower 960, Birmingham, AL 35294, USA; stheiss@uabmc.edu

Published 15 July 2024

This manuscript is generously published free of charge by ISASS, the International Society for the Advancement of Spine Surgery. Copyright © 2024 ISASS. To see more or order reprints or permissions, see <http://ijssurgery.com>.