

Feasibility of C2 Lamina Screw Placement in a New Zealand Cohort: Computed Tomography Analysis According to Ethnicity and Gender

Richard N. Storey and Joseph F. Baker

Int J Spine Surg 2024, 18 (5) 471-476

doi: <https://doi.org/10.14444/8600>

<https://www.ijssurgery.com/content/18/5/471>

This information is current as of May 5, 2025.

Email Alerts Receive free email-alerts when new articles cite this article. Sign up at:
<http://ijssurgery.com/alerts>

Feasibility of C2 Lamina Screw Placement in a New Zealand Cohort: Computed Tomography Analysis According to Ethnicity and Gender

RICHARD N. STOREY, BMEDSci (Hons), MB ChB, PGDip SEM (Hons), FRACS¹ AND JOSEPH F. BAKER, FRCSI (Tr & ORTH)^{2,3}

¹Department of Orthopaedic Surgery, Christchurch Hospital, Christchurch, New Zealand; ²Department of Orthopedic Surgery, Waikato Hospital, Hamilton, New Zealand; ³Department of Surgery, University of Auckland, Auckland, New Zealand

 JFB, 0000-0002-8518-8780

ABSTRACT

Background: Previous analyses have suggested variations in cervical spine canal morphology according to ethnicity, possibly in part due to variations in the posterior elements. The potential for these variations to affect the placement of instrumentation is uncertain. The aim of this study was to report on the feasibility of C2 lamina screw insertion in a New Zealand cohort including analysis of Māori, the indigenous people of New Zealand.

Methods: A trauma computed tomography database was accessed to identify suitable images. On axial images, where the isthmus was at its widest, the outer diameter (OD) and inner diameter (ID) of the lamina were measured. Screw length was measured from a proposed entry point to the contralateral junction of the lamina and lateral mass. The spinolaminar angle was measured as the angle subtended by the screw trajectory and midsagittal plane. A 5.5-mm OD was accepted as a threshold for the feasibility of lamina screw placement.

Results: One hundred eighty-seven images were assessed: 115 New Zealand European and 72 Māori. The mean age of the cohort was 41.9 years (SD 19.6), and most patients (64%) were men. For the entire cohort, mean OD was 6.6 and 6.8 mm on the right and left, respectively; the mean inner diameter was 3.5 and 3.8 mm; mean screw length was 31.5 and 31.5 mm; and mean spinolaminar angle was 46.0° and 46.1°. C2 lamina screw placement was feasible in a majority of patients. Considering only Māori patients, placement was feasible in 96% of right and 94% of left laminae in men but 72% of right and 72% of left laminae in women.

Conclusions: In a majority of patients, C2 lamina screw placement is feasible. However, advanced imaging must be carefully assessed preoperatively because data suggest that Māori women may not necessarily have optimal anatomy.

Clinical Relevance: Care needs to be taken when assessing and planning surgery in patients of different ethnicities because variations may exist in the morphology of the posterior elements of C2, leading to variation in optimal fixation strategy.

Level of Evidence: 3.

Cervical Spine

Keywords: C2, axis, lamina, ethnicity

INTRODUCTION

Instrumentation involving the C2 vertebra may be indicated for a variety of pathologies including trauma, tumor, and degenerative disease.¹ No matter the underlying disease process, instrumentation may be challenging due to factors such as anomalous anatomy, distortion of normal anatomy by the underlying disease, or vascular anomalies with aberrant vertebral arteries.^{2,3}

A range of techniques may be utilized—both freehand and image-guided techniques, including pars and pedicle screws, are well described.^{1,4–7} However, in some instances where posterior instrumentation of C2

is needed, placement of a pedicle or pars screw is either impossible or poses unacceptable risk. In this situation, lamina screws are a potential alternative with an acceptable biomechanical profile and high levels of accuracy reported.^{1,8} Described by Wright in 2004, they have been widely used since.⁹ Advantages include the ability to place using a freehand technique and a much lower risk of injury to the vertebral artery. Modifications to the original technique, using an in-out-in technique, have been described, resulting in a reduction in the risk of displacement into the canal.¹⁰

With any technique or instrumentation, understanding the feasibility of such is a key element. A small

number of studies have investigated the potential for insertion of C2 lamina screws.^{10–19} A majority of these have studied cohorts from Asian countries, and only one has provided any direct comparison based on ethnicity.^{10–12,14–17,20,21} Typically, these studies have reported mean values of the thickness of the lamina and considered the potential for screw placement of a 3.5-mm diameter screw using an appropriate outer lamina diameter threshold.²²

To our knowledge, no study has been performed with a cohort from New Zealand. New Zealand is a multicultural society and includes the indigenous Māori, who comprise approximately 17% of the population.²³ Previous research has suggested that differences in cervical spine anatomy exist between ethnic groups in New Zealand, including the potential for variation in the posterior elements and therefore potential differences in the ability to safely instrument.²⁴

The aim of the present study was to determine the feasibility of C2 lamina screw placement in a New Zealand cohort of patients and to compare the feasibility between New Zealand European (NZE) and Māori ethnicities.

METHODS

Ethics

This study was approved by the Health and Disabilities Ethics Committee (Ref: 20/STH/143). Written consent was waived given the retrospective nature of the study.

Methods

This study used a preexisting database of computed tomography (CT) images obtained for the purpose of major trauma assessment.²⁵ Age, gender, and ethnicity data were previously collected. Images were excluded if cervical spine anatomy was distorted by prior surgery,

trauma, tumor, or congenital anomaly (eg, block vertebrae). All images were obtained comprising 1-mm thick axial slices. From the original dataset of 200 scans, 187 were available for analysis.

All scans were accessed using IntelliSpace PACS 4.4 Enterprise (Koninklijke Philips N.V.). All measurements were taken on axial plane images. The slice at which the isthmus was widest was selected for measurement of each lamina as has been done in previous studies.²² The PACS inbuilt measurement tools were used. The inner diameter (ID), outer diameter (OD), screw length (SL), and spinolaminar angle (SLA) were recorded (Figure). ID (mm) was measured from the margins of the inner cortices; OD (mm) was measured using the outer margins of the cortices; SL (mm) was measured as the distance from the outer cortex of the lamina to the junction between the lamina and the lateral mass on the opposite side; SLA was measured as the angle subtended by the line used to measure the SL and a line running through the spinous process and middle of the vertebral body.¹³

For determining the feasibility of screw placement, a 5.5 mm OD threshold was selected as a cut-off.²² This allows the placement of a 3.5-mm diameter screw with a 1-mm wall of cortex on either side. A 3.5-mm ID threshold was also recorded, although an ID < 3.5 mm would not necessarily preclude placement of a lamina screw.

All measurements were subject to reliability analysis. Ten images were measured by the authors. Intra-class coefficients determined that all measures had good to excellent reliability: OD 0.843, ID 0.964, SL 0.873, and SLA 0.734.

Statistical Methods

All analyses were performed using XLSTAT (Add-insoft, version 2022.2.1). Results are reported as mean and SD. Comparisons were made between groups based

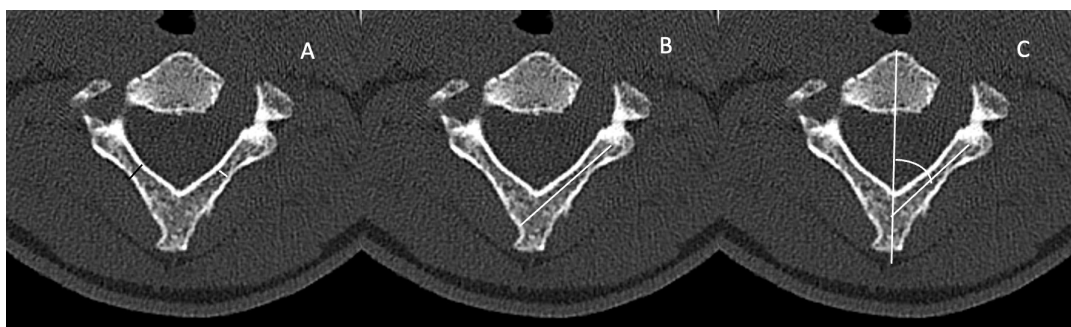


Figure. (A) Measurement of the outer diameter of the right lamina (black solid line) and inner diameter of the left lamina (white solid line). (B) Measurement of the screw length. (C) Measurement of the spinolaminar angle.

Table 1. Mean (SD) values for the outer diameter (OD) and inner diameter (ID).

Cohort	OD Right (mm)	OD Left (mm)	ID Right (mm)	ID Left (mm)
Combined	6.6 (1.3)	6.8 (1.3)	3.5 (1.2)	3.8 (1.3)
New Zealand European	6.5 (1.3)	6.7 (1.3)	3.4 (1.3)	3.7 (1.2)
Māori	6.8 (1.2)	7.0 (1.2)	3.7 (1.2)	4.0 (1.2)
<i>P</i> value	0.09	0.16	0.16	0.12

Note: Statistical analysis by Student *t* test.

on both ethnicity and gender. A power analysis, to detect a 1.0-mm difference in OD, with alpha 0.05 and power 0.9, determined that a minimum of 22 scans would be required for each group.

Means were compared using either Student's *t* test or Mann-Whitney *U* test depending on the normality of the data. *Z* test and χ^2 test were used to compare proportions. One-way analysis of variance was used to assess for differences between multiple groups. Post-hoc comparisons were performed using the Tukey or Games-Howell tests. Statistical significance was accepted at *P* < 0.05.

RESULTS

One hundred eighty-seven patients were included: 115 NZE and 72 Māori. The mean age of the cohort was 41.9 years (SD 19.6), and most patients (64%) were men. There was no significant difference in age (NZE 43.7 years; Māori 39.1 years; *P* = 0.11) or gender (NZE 62% men; Māori 66% men; *P* = 0.68) between the ethnic groups.

Mean (SD) values for the OD and ID of the entire cohort, NZE, and Māori subgroups are shown in Table 1. Mean (SD) values for the SLA and SL of the entire cohort, NZE, and Māori subgroups are shown in Table 2. Significant differences in mean SLA were evident in both right and left laminae between NZE and Māori (*P* = 0.006 and *P* = 0.027, respectively). Significant differences between the right and left were evident for both OD (*P* = 0.01) and ID (*P* = 0.001) but not between SLA (*P* = 0.68) and SL (*P* = 0.68).

Table 2. Mean (SD) values for the spinolaminar angle (SLA) and screw length (SL).

Cohort	SLA Right (°)	SLA Left (°)	SL Right (mm)	SL Left (mm)
Combined	46.0 (4.0)	46.1 (4.3)	31.5 (4.0)	31.5 (3.8)
New Zealand European	45.3 (4.4)	45.6 (4.5)	31.4 (4.2)	31.3 (4.0)
Māori	47.0 (3.1)	46.9 (3.8)	31.8 (3.8)	31.6 (3.6)
<i>P</i> value	0.006	0.027	0.146	0.296

Note: Statistical analysis by Mann-Whitney *U* test (SLA) and Student *t* test (SL). Significant *P* values appear in **bold** type.

Table 3. Percentage of laminae in which lamina screw placement was considered feasible in New Zealand European and Māori patients.

Cohort	OD Right >5.5 mm	OD Left >5.5 mm	ID Right >3.5 mm	ID Left >3.5 mm
New Zealand European	77%	80%	49%	50%
Māori	86%	89%	57%	71%
<i>P</i> value	0.136	0.140	0.340	0.007

Abbreviations: ID, inner diameter; OD, outer diameter.

Note: Proportions were compared using the *z* test for proportions. Significant *P* values appear in **bold** type.

The feasibility of screw placement using thresholds for both the OD and ID is shown in Table 3. A significant difference was seen only between NZE and Māori patients using the ID of the left lamina (*P* = 0.007).

Results from analysis of variance comparing subgroups according to both ethnicity and gender appear in Table 4. Significant differences of OD of both laminae between Māori men and women and Māori men and NZE women were noted. Similarly, significant differences of ID of both laminae between Māori men and women and Māori men and NZE women were noted. SLA differed only between NZE men and Māori men. SL was significantly different between gender subgroups of both ethnicities on the right.

A comparison of the feasibility of C2 lamina screw placement is shown in Table 5. Using the OD of 5.5 mm as a threshold, the only significant difference was between Māori men and NZE women on the right. Using the ID of 3.5 mm as a threshold, significant differences were again evident between Māori men and NZE women on the right with further differences on the left between genders within ethnic groups and between Māori men and NZE women.

Table 4. Mean values for the outer diameter (OD), inner diameter (ID), spinolaminar angle (SLA), and screw length (SL) for subgroups according to ethnicity and gender.

Measure	NZE Men	NZE Women	Māori Men	Māori Women	<i>P</i>
Right OD (mm)	6.5	6.3 ^a	7.1 ^{a, b}	6.2 ^b	0.012
Left OD (mm)	6.8	6.6 ^a	7.3 ^{a, b}	6.4 ^{a, b}	0.008
Right ID (mm)	3.5	3.3 ^a	3.9 ^{a, b}	3.2 ^b	0.034
Left ID (mm)	3.8	3.5 ^a	4.3 ^{a, b}	3.3 ^b	<0.001
Right SLA (°)	44.8 ^c	46.1	47.3 ^c	46.4	0.003
Left SLA (°)	45.0 ^c	46.5	46.8 ^c	47.1	0.045
Right SL (mm)	32.2 ^{d, e}	30.0 ^{a, e}	32.9 ^{a, b}	29.7 ^{b, d}	<0.001
Left SL (mm)	32.3 ^e	29.7 ^{a, e}	32.4 ^a	30.1	<0.001

Abbreviation: NZE, New Zealand European.

Note: Group comparisons were performed using a 1-way analysis of variance. Significant between-group differences are noted by symbols assigned as follows. Significant *P* values appear in **bold** type.

^aNZE women: Māori men

^bMāori men: Māori women

^cNZE men: Māori men

^dNZE men: Māori women

^eNZE men: NZE women

Table 5. The percentage of laminae in which laminae screw placement was considered feasible in subgroups according to ethnicity and gender.

Cohort	OD Right >5.5 mm	OD Left >5.5 mm	ID Right >3.5 mm	ID Left >3.5 mm
NZE men	89%	82%	54%	56% ^a
NZE women	79% ^b	77%	40% ^b	42% ^{a, b}
Māori men	96% ^b	94%	68% ^b	83% ^{b, c}
Māori women	72%	72%	36%	48% ^c
<i>P</i> value	0.007	0.076	0.017	<0.001

Abbreviations: ID, inner diameter; NZE, New Zealand European; OD, outer diameter.

Note: Statistical significance was assessed for using the χ^2 test. Significant *P* values appear in **bold** type.

^aNZE men: NZE women

^bNZE women: Māori men

^cMāori men: Māori women

DISCUSSION

The aim of this study was to report on the feasibility of C2 lamina screw placement in a New Zealand cohort and analyze for differences between NZE and Māori, the indigenous people of New Zealand. While previous studies have considered the feasibility of C2 lamina screw insertion in homogeneous cohorts, few have provided a comparison based on ethnicity.²⁰ The findings of this study are unique in that significant differences in mean values were evident only when the cohort was analyzed according to both ethnicity and gender, and the differences in both ODs and IDs of the C2 lamina between genders were most pronounced within the Māori population.

Cassinelli et al previously performed a cadaveric study of 420 vertebrae.²⁰ Although gender had a significant effect on lamina thickness and SLA, race did not. The mean lamina thickness reported was 5.77 mm, which is somewhat lower than the mean OD established in this study in either ethnic group (NZE 6.5 and 6.7 mm vs Māori 6.8 and 7.0 mm on right and left, respectively). This may reflect a true difference in the cohorts studied or a subtle difference in technique. CT digital measurements have been previously validated against cadaveric measurement using digital calipers, so the latter seems less likely.²⁶ Dissimilar to Cassinelli et al, we failed to find consistent differences between the genders: within the NZE cohort, only SL was significantly different, while within the Māori cohort, differences were most notable in the thickness of the lamina.²⁰ This most likely reflects a true variation according to ethnicity.

The potential for variation between ethnicities was further demonstrated by Nakanishi et al.¹² Using a navigation system to measure the dimensions of the C2 lamina, they reported a mean lamina diameter of 4.1 and 3.5 mm in men and women, respectively. The potential for placement of a 3-mm diameter screw was 80% and

63% for men and women—both values markedly lower in either the NZE (at least 77%) or Māori (at least 86%) groups in the current study that also considered the feasibility of a larger screw. A potential explanation for this is variation in body morphology. Such measures are generally poorly reported in studies; however, Yuwakosol et al, in their study of 270 patients, did not find any correlation between body mass index and size.¹⁷ Furthermore, in a study analyzing more than 2000 magnetic resonance images of the cervical spine, Nell et al found no association between body morphology with either vertebral body or canal morphology, suggesting a low likelihood that body morphology would explain these differences in the lamina dimensions.²⁷

Bhatnager et al studied 50 patients who underwent CT of the cervical spine with or without angiography.²⁸ They found a mean lamina thickness of 5.5 mm and determined that 94% could accept a 3.5-mm diameter screw, although the criteria to determine this are obscure. The high level of feasibility mirrors that which was seen in Māori men; however, it is much higher than that seen in Māori women. The described technique of measuring at the thinnest part of the lamina and utilizing CT obtained with 3-mm slices may contribute to variation in findings.

Consistent with previous studies, there was a persistent difference in mean SL between genders.¹⁷ The technique of translaminar screw insertion requires a more cephalad entry point on 1 side and a more caudad entry point on the spinolaminar junction on the other—the spinous process height as a potential limiting factor in screw placement has been described.¹⁰ In this sense, simply measuring the length of a proposed SL does not reflect the actual possible length achieved in practice but does demonstrate the gender difference. The mean values from the entire cohort, 31.5 mm on both the right and left, respectively, must be noted with caution. Riesenburger et al reported on 50 CT angiograms and noted that while lamina screw insertion was feasible and safe, increased length of screw had the potential to cause injury to the vertebral artery, thus, recommended a maximum length screw of 28 mm.²⁹

Lamina on the left side of the spine was larger in the current study whether analyzed by OD or ID. Side-to-side differences have been noted before with a greater proportion of left lamina suitable for screw placement reported by Chan et al.¹¹ Others have failed to demonstrate a side-to-side difference, while no comparison is made by still others.^{13,17,28} The potential for side-to-side variation is not without basis as there is well-recognized variation in vertebral artery caliber, with the left side most frequently

reported as dominant.³⁰ We hypothesize that the increased lamina size is linked to the need to contain a slightly larger VA, although this is somewhat contradicted by a previous analysis of CT by Yang et al, suggesting that the pedicle size was smaller in the subaxial spine on the side of VA dominance.³¹

Limitations

Limitations of this study include the relatively small cohort size compared with previous reports. However, the study was suitably powered to detect a 1-mm difference in lamina thickness. Feasibility of placement of lamina screws alone was considered—a more comprehensive analysis could include an assessment of the feasibility to place both pars and pedicle screws. Often instrumentation of C2 will be aided by intraoperative navigation, which will aid in pars or pedicle screw placement, while lamina screw insertion can often be performed safely using a freehand technique with a low risk of injury to the vertebral artery. Therefore, we felt that knowledge of the feasibility of this technique alone is of great utility.

CONCLUSION

The present study demonstrated that differences in the dimensions of the C2 lamina were predominantly limited to differences between genders within the Māori population. Reassuringly, a vast majority of Māori men can safely accommodate C2 lamina screw placement. However, the proportion of Māori women who can be safely instrumented is lower, and careful assessment of advanced imaging prior to surgery is mandatory if lamina screw placement is considered a possible mode of fixation at C2.

REFERENCES

1. Bransford RJ, Russo AJ, Freeborn M, et al. Posterior C2 instrumentation: accuracy and complications associated with four techniques. *Spine*. 2011;36(14):E936–E943. doi:10.1097/BRS.0b013e3181fdaf06
2. Neo M, Matsushita M, Iwashita Y, Yasuda T, Sakamoto T, Nakamura T. Atlantoaxial transarticular screw fixation for a high-riding vertebral artery. *Spine*. 2003;28(7):666–670. doi:10.1097/01.BRS.0000051919.14927.57
3. Aoyama T, Yasuda M, Yamahata H, et al. Radiographic measurements of C-2 in patients with atlas assimilation. *J Neurosurg Spine*. 2014;21(5):732–735. doi:10.3171/2014.7.SPINE131087
4. Brooks AL, Jenkins EB. Atlanto-axial arthrodesis by the wedge compression method. *J Bone Joint Surg Am*. 1978;60(3):279–284.
5. Dickman CA, Sonntag VK. Posterior C1-C2 transarticular screw fixation for atlantoaxial arthrodesis. *Neurosurgery*. 1998;43(2):275–280. doi:10.1097/00006123-199808000-00056

6. Farey ID, Nadkarni S, Smith N. Modified gillie technique versus transarticular screw fixation in C1-C2 fusion. *Clin Orthop Relat Res*. 1999;(359):126–135. doi:10.1097/00003086-199902000-00013
7. Harms J, Melcher RP. Posterior C1-C2 fusion with polyaxial screw and rod fixation. *Spine*. 2001;26(22):2467–2471. doi:10.1097/00007632-200111150-00014
8. Gorek J, Acaroglu E, Berven S, Yousef A, Puttlitz CM. Constructs incorporating intralaminar C2 screws provide rigid stability for atlantoaxial fixation. *Spine*. 2005;30(13):1513–1518. doi:10.1097/01.brs.0000167827.84020.49
9. Wright NM. Posterior C2 fixation using bilateral, crossing C2 laminar screws: case series and technical note. *J Spinal Disord Tech*. 2004;17(2):158–162. doi:10.1097/00024720-200404000-00014
10. Ma XY, Yin QS, Wu ZH, Xia H, Riew KD, Liu JF. C2 anatomy and dimensions relative to translaminar screw placement in an Asian population. *Spine*. 2010;35(6):704–708. doi:10.1097/BRS.0b013e3181bb8831
11. Chan AKH, Yusof MI, Abdullah MS. Computed tomographic morphometric analysis of C1 and C2 for lamina cross screw placement in Malay ethnicity. *Asian Spine J*. 2021;15(1):1–8. doi:10.31616/asj.2019.0242
12. Nakanishi K, Tanaka M, Sugimoto Y, et al. Application of laminar screws to posterior fusion of cervical spine: measurement of the cervical vertebral arch diameter with a navigation system. *Spine*. 2008;33(6):620–623. doi:10.1097/BRS.0b013e318166aa76
13. Saetia K, Phankongsab A. C2 anatomy for translaminar screw placement based on computerized tomographic measurements. *Asian Spine J*. 2015;9(2):205–209. doi:10.4184/asj.2015.9.2.205
14. Xin-yu L, Kai Z, Laing-tai G, Yan-ping Z, Jian-min L. The anatomic and radiographic measurement of C2 lamina in Chinese population. *Eur Spine J*. 2011;20(12):2261–2266. doi:10.1007/s00586-011-1876-5
15. Yue B, Kwak DS, Kim MK, Kwon SO, Han SH. Morphometric trajectory analysis for the C2 crossing laminar screw technique. *Eur Spine J*. 2010;19(5):828–832. doi:10.1007/s00586-010-1331-z
16. Yusof MI, Shamsi SSM. Translaminar screw fixation of the cervical spine in Asian population: feasibility and safety consideration based on computerized tomographic measurements. *Surg Radiol Anat*. 2012;34(3):203–207. doi:10.1007/s00276-011-0869-8
17. Yuwakosol P, Oearsakul T, Tunthanathip T. Morphometry of the C2 pedicle and lamina in Thai patients. *Asian J Neurosurg*. 2020;15(1):39–44. doi:10.4103/ajns.AJNS_312_19
18. Sakci Z, Onen MR, Yuce M, Dereli SS, Naderi S. Lamina measurements with computed tomography for C2 translaminar screw fixation in pediatric and adult cases. *Turk Neurosurg*. 2021;31(3):460–465. doi:10.5137/1019-5149.JTN.32230-20.2
19. Senoğlu M, Özbağ D, Gümüşalan Y. C2 intralaminar screw placement: a quantitative anatomical and morphometric evaluation. *Turk Neurosurg*. 2009;19(3):245–248.
20. Cassinelli EH, Lee M, Skalak A, Ahn NU, Wright NM. Anatomic considerations for the placement of C2 laminar screws. *Spine*. 2006;31(24):2767–2771. doi:10.1097/01.brs.0000245869.85276.f4
21. Wang MY. C2 crossing laminar screws: cadaveric morphometric analysis. *Neurosurgery*. 2006;59(1 Suppl 1):S84–S88. doi:10.1227/01.NEU.0000219900.24467.32
22. Meng X, Xu J. The options of C2 fixation for os odontoideum: a radiographic study for the C2 pedicle and lamina

anatomy. *Eur Spine J.* 2011;20(11):1921–1927. doi:10.1007/s00586-011-1893-4

23. Quick stats about population counts for New Zealand (2018 Census) [https://www.stats.govt.nz]

24. Goddard-Hodge DC, Baker JF. Cervical spine canal morphology: a radiological analysis in a New Zealand cohort in: the New Zealand Orthopaedic Association and the Australian Orthopaedic Association (NZOA AOA). *Combined Annual Scientific Meeting: October.* 2022. doi:10.1302/1358-992X.2023.2.055

25. Cook WH, Baker JF. Comparative analysis of lumbar spine vertebral morphology between Maori and New Zealand Europeans: a computed tomography study. *Int J Spine Surg.* 2021;15(6):1072–1081. doi:10.14444/8193

26. Dean CL, Lee MJ, Robbin M, Cassinelli EH. Correlation between computed tomography measurements and direct anatomic measurements of the axis for consideration of C2 laminar screw placement. *Spine J.* 2009;9(3):258–262. doi:10.1016/j.spinee.2008.06.454

27. Nell C, Bülow R, Hosten N, Schmidt CO, Hegenscheid K. Reference values for the cervical spinal canal and the vertebral bodies by MRI in a general population. *PLOS One.* 2019;14(9):e0222682. doi:10.1371/journal.pone.0222682

28. Bhatnagar R, Yu WD, Bergin PF, Matteini LE, O'Brien JR. The anatomic suitability of the C2 vertebra for intralaminar and pedicular fixation: a computed tomography study. *Spine J.* 2010;10(10):896–899. doi:10.1016/j.spinee.2010.06.010

29. Riesenburger RI, Jones GA, Roguski M, Krishnaney AA. Risk to the vertebral artery during C-2 translaminar screw placement: a thin-cut computerized tomography angiogram-based morphometric analysis: clinical article. *J Neurosurg Spine.* 2013;19(2):217–221. doi:10.3171/2013.5.SPINE12790

30. Touboul PJ, Bousser MG, LaPlane D, Castaigne P. Duplex scanning of normal vertebral arteries. *Stroke.* 1986;17(5):921–923. doi:10.1161/01.str.17.5.921

31. Yang J, Li T, Wang Q, et al. Morphological characteristics of subaxial cervical pedicles and surrounding critical structures in patients with vertebral artery dominance - an anatomical study based on computed tomographic imaging. *BMC Musculoskelet Disord.* 2022;23(1):306. doi:10.1186/s12891-022-05264-2

Funding: The authors received no financial support for the research, authorship, and/or publication of this article.

Declaration of Conflicting Interests: The authors report no conflicts of interest in this work.

Disclosures: Joseph Baker reports grants or contracts from Medtronic and Smith and Nephew (paid to institution) and consulting fees from Fisher and Paykel. Richard Storey reports no disclosures.

Ethics Approval: This study was approved by the Health and Disabilities Ethics Committee (Ref:20/STH/143).

Corresponding Author: Richard N. Storey, Department of Orthopaedic Surgery, Christchurch Hospital, Hagley Avenue, Christchurch, New Zealand; Richard.storey2@cdhb.health.nz

Published 26 April 2024

This manuscript is generously published free of charge by ISASS, the International Society for the Advancement of Spine Surgery. Copyright © 2024 ISASS. To see more or order reprints or permissions, see <http://ijssurgery.com>.