

Standalone Anterior Lumbar Interbody Fusion Without Supplementary Posterior Fixation Is Effective for Treatment of Symptomatic Grade 1 Isthmic Spondylolisthesis

James S. Toohey, Charlie R. Faulks, Dean T. Biddau, Matthew H. Claydon, Nigel R. Munday and Gregory M. Malham

Int J Spine Surg 2024, 18 (6) 721-730

doi: <https://doi.org/10.14444/8663>

<https://www.ijssurgery.com/content/18/6/721>

This information is current as of May 3, 2025.

Email Alerts Receive free email-alerts when new articles cite this article. Sign up at:
<http://ijssurgery.com/alerts>

Standalone Anterior Lumbar Interbody Fusion Without Supplementary Posterior Fixation Is Effective for Treatment of Symptomatic Grade 1 Isthmic Spondylolisthesis

JAMES S. TOOHEY, BBioMedSc^{1,2}; CHARLIE R. FAULKES, BSc, BBioMedSc, MD^{1,2}; DEAN T. BIDDAU, BBioMedSc^{1,2,3}; MATTHEW H. CLAYDON, MBBS (Hons), BMedSci (Hons), FRACS^{2,4,5}; NIGEL R. MUNDAY, MBBS, MBA^{1,2}; AND GREGORY M. MALHAM, BSc, MBChB, DMEd, FRACS^{1,2,6,7,8}

¹Department of Neuroscience, Epworth HealthCare, Richmond, VIC, Australia; ²Spine Surgery Research Foundation, Richmond, VIC, Australia; ³School of Biomedical Science, Queensland University of Technology, Brisbane, QLD, Australia; ⁴Department of Vascular Surgery, Epworth Hospital, Melbourne, VIC, Australia; ⁵Department of Vascular Surgery, The Alfred, Melbourne, VIC, Australia; ⁶Department of Surgery, Faculty of Medicine, Dentistry and Health Science, University of Melbourne, Parkville, VIC, Australia; ⁷Department of Health and Biomedical Sciences, Royal Melbourne Institute of Technology University, Melbourne, VIC, Australia; ⁸School of Health Science and Biostatistics, Swinburne University of Technology, Hawthorn, VIC, Australia

ABSTRACT

Background: There is a paucity of data examining anterior lumbar interbody fusion (ALIF) with pedicle-screw fixation (ALIF-PSF) or without (standalone, sa-ALIF) for the treatment of low-grade isthmic spondylolisthesis (IS). Treating pathology with sa-ALIF reduces costs, operative times, and posterior access morbidity. This study aimed to investigate the clinical and radiographic outcomes of sa-ALIF for the management of low-grade IS compared with an ALIF-PSF cohort.

Methods: Retrospective analysis of prospectively collected data. Consecutive patients from 1 senior spine surgeon performing sa-ALIF or ALIF-PSF for management of low-grade IS. Patient-reported outcome measures (PROMs) were collected at baseline, then postoperatively at 6 weeks, 6 months, 12 months, and a final follow-up timepoint. Computed tomography was conducted at 6 months, 12 months, or until interbody fusion was confirmed.

Results: Two cohorts comprised 51 patients (sa-ALIF 22 and ALIF-PSF 29). Both cohorts' PROMs improved from baseline to 12 months postoperatively. There were no significant differences ($P = 0.05$) in PROMs between the 2 cohorts at 6 months postoperatively, 12 months postoperatively, or at a final follow-up timepoint. There were no significant differences in mean fusion rates 12 months postoperatively (sa-ALIF 82% and ALIF-PSF 88%). Compared with preoperative measurements in sa-ALIF and ALIF-PSF cohorts, listhesis and segmental lordosis showed no significant changes, while disc height significantly increased ($P = 0.0001$). There were no significant differences in disc L5/S1 radiographic measurements between the cohorts at 12 months. There were 12 complications (sa-ALIF 2 and ALIF-PSF 10). Only 1 patient in the ALIF-PSF cohort required revision surgery.

Conclusions: In appropriately selected patients with normal bone density, sacral slope $<40^\circ$, and a body mass index <35 , sa-ALIF is a safe and effective treatment option for grade I IS. The additional morbidity and cost of PSF may not be justified given the satisfactory clinical and radiographic outcomes of sa-ALIF for grade I IS.

Clinical Relevance: Clinically, this research continues to suggest that sa-ALIF is a safe and effective method of treatment for low grade IS.

Level of Evidence: 4.

Lumbar Spine

Keywords: standalone anterior lumbar interbody fusion, ALIF, pedicle screw fixation, isthmic spondylolisthesis

INTRODUCTION

Isthmic spondylolisthesis (IS) is an anterior translation of a vertebral body over the subadjacent vertebrae secondary to bilateral defects of the pars interarticularis, with L5/S1 being more common than L4/L5. The majority of IS is asymptomatic with a prevalence of approximately 4.4% to 6%.^{1,2} However, when symptomatic, IS

can lead to severe mechanical low back pain, lumbar radiculopathy, or both.³

The degree of anterolisthesis is categorized by the Meyerding classification system, where a higher grade is associated with increased listhesis.³ This system is used to stratify patients and inform clinical management.⁴

When conservative management for low-grade (I/II) IS is unsuccessful, spinal fusion is indicated.⁵ Fusion

techniques used to manage IS include posterolateral bone graft with or without posterior pedicle-screw/rod fixation (posterior lumbar fusion [PLF]), with or without the addition of interbody cages (posterior lumbar interbody fusion [PLIF]), and anterior column interbody fusion either oblique (oblique lumbar interbody fusion) or direct anterior (anterior lumbar interbody fusion [ALIF]). ALIF is advantageous as it enables the impaction of a wide-footprint lordotic interbody cage with the restoration of disc height and segmental lordosis while indirectly increasing the circumferential diameter of the foramen.^{6,7} ALIF spares posterior musculoligamentous damage and retraction of cauda equina nerve roots.⁸ Supplementary posterior fixation may be added, involving PLF, open or percutaneous pedicle-screw fixation (PSF), or a combination. A recent large multicenter retrospective cohort suggested supplemental posterior fixation to ALIF-enhanced fusion rates without increasing the risk of adjacent segment disease.⁹ This was consistent with prior studies that have shown combined 360° approaches may provide superior fusion rates.^{7,9} However, the cost and morbidity of posterior fixation must be considered. Concerns regarding paraspinal muscle damage induced by iatrogenic denervation caused by posterior fixation remain contentious.^{10–12}

There is a paucity of clinical and radiographic outcomes comparing standalone ALIF (sa-ALIF) without posterior fixation^{9,13–15} to ALIF with PSF for the management of IS. In contrast to ALIF-PSF, treating IS with sa-ALIF reduces costs, operative times, blood loss, and posterior access complications but may risk higher rates of nonunion.

We aimed to investigate the clinical and radiographic outcomes of sa-ALIF for the management of low-grade IS compared with an ALIF-PSF cohort and consider the cost effectiveness of each.

METHODS

Study Design and Patient Population

For the present study, we conducted a retrospective analysis of prospectively collected data of consecutive patients undergoing either sa-ALIF or ALIF with PSF between November 2012 and October 2021. All operations were performed by a senior spinal fellowship-trained neurosurgeon. Treatment groups were not randomized.

The sa-ALIF cohort from 2014 to 2018 comprised a separate cage and buttress plate; then from 2018 to 2022, the sa-ALIF cohort comprised an integrated cage-plate-screw construct. The integrated sa-ALIF was adopted

after 2018 when this construct became commercially available, accounting for the shorter follow-up time.

All patients enrolled in the study reported worsening mechanical low back pain, severe radicular lower extremity pain, or both (not responsive to physical therapy, opiate analgesia, and targeted steroid injections) and/or development of lumbar radiculopathy. Indications for sa-ALIF were symptomatic grade I isthmic anterolisthesis with mechanical low back pain, lumbar radiculopathy, or both. Additional posterior fixation was indicated for (i) grade I isthmic anterolisthesis with reduced bone density and/or high sacral slope ($>40^\circ$) or (ii) grade II isthmic anterolisthesis. Bone density was assessed in high-risk patients.¹⁶ Patients with osteopenia or osteoporosis were referred to a consultant endocrinologist for preoperative optimization. The minimum follow-up period was 12 months. Patient demographics were recorded at baseline. The inclusion criteria were adults aged 18 years or older; patients with IS at L4/L5 or L5/S1 that had not responded to conservative management for a minimum of 6 months; and patients who agreed to attend all follow-up visits and imaging. All patients underwent a focused duplex scan to screen for vascular abnormalities, and if any were detected, they proceeded to computed tomography (CT). Exclusion criteria for surgery were disc disease across 3 or more levels, grades III to IV spondylolisthesis, significant iliac artery or aortic pathology, morbid obesity (body mass index [BMI] $>35 \text{ kg/m}^2$), previous complex/extensive retroperitoneal surgery, and abdominal/pelvic radiotherapy. Prior lumbar spine surgery was not an exclusion criterion.

Clinical Outcomes

Patient self-reported outcome measures (PROMs) were evaluated preoperatively and at 6 weeks, 6 months, 12 months, and final follow-up postoperatively. PROMs included visual analog scale (VAS) back and leg scores, Oswestry Disability Index (ODI) scores, and physical (physical component summary) and mental (mental component summary) 12-Item Short Form Survey (SF-12) scores. Ottawa decision regret scale scores (0–100) were evaluated at the final follow-up, with lower scores indicating higher satisfaction.¹⁷

Radiographic Outcomes

CT was performed on postoperative day 2 for instrumentation positioning, then at 6- or 12-month follow-up for interbody fusion status. If fusion was confirmed, no further CTs were undertaken to reduce patient radiation exposure. CT images were assessed using the Bridwell

Table 1. Meyerding classification system.

Grade	Percent Slippage
Grade 1	0%–25%
Grade 2	25%–50%
Grade 3	50%–75%
Grade 4	75%–100%
Grade 5	>100% (spondyloptosis)

criteria.¹⁸ Fusion was assessed by a third-party radiologist from another institution. Segmental lordosis and disc height were measured, and anterolisthesis was reported using the Meyerding classification system (Table 1).

Adverse Events

Clinical adverse events recorded included persistent mechanical and radicular pain, surgical site infection, and re-operations at the index and adjacent levels. Acute complications were defined as ≤ 6 months, and chronic complications were defined as >6 months post-operatively.

Surgical Technique

The anterior approach by a vascular access surgeon comprises a transverse or longitudinal skin incision, followed by a retroperitoneal dissection with retraction of the visceral structures, and exposure, mobilization, and retraction of the vessels. The target disk was confirmed by image intensifier and then resected, endplates

were curetted/rasped, and sequential trials were used to distract and reduce the slip before a definitive cage was inserted along with a buttress plate (Perimeter, Medtronic PLC, Dublin, Ireland; 2014–2018) or a combined cage with integrated plate-screw fixation (Independence, Globus Medical, PA; 2018–2022; Figure 1). All ALIF cage types were polyetheretherketone. Procedures included were single-level (L4/L5 and L5/S1) or 2-level ALIF (L4/L5 + L5/S1). The interbody cage bone substitute used was recombinant human bone morphogenetic protein 2 (rhBMP-2) from 2012 to 2020. rhBMP-2 (Medtronic PLC, Dublin, Ireland) was delisted by the TGA (Therapeutic Goods Administration—Federal Government Authority and Regulator) in Australia in March 2020;¹⁹ thereafter, a demineralized bone allograft (DBA, Australian Biotechnologies, Sydney, Australia) was used instead. A hybrid procedure consisted of a disc replacement at the superior L4/L5 and corresponding ALIF at inferior L5/S1 level.

Ethical Statement

This study was a review of cases collected under a standard privacy disclosure to patients whose information will be used for ongoing evaluation of outcomes, and their identity will be protected in any publication arising from this. The project was reviewed by an independent expert in Human Research Ethics and classified as a low-risk research project in accordance with section

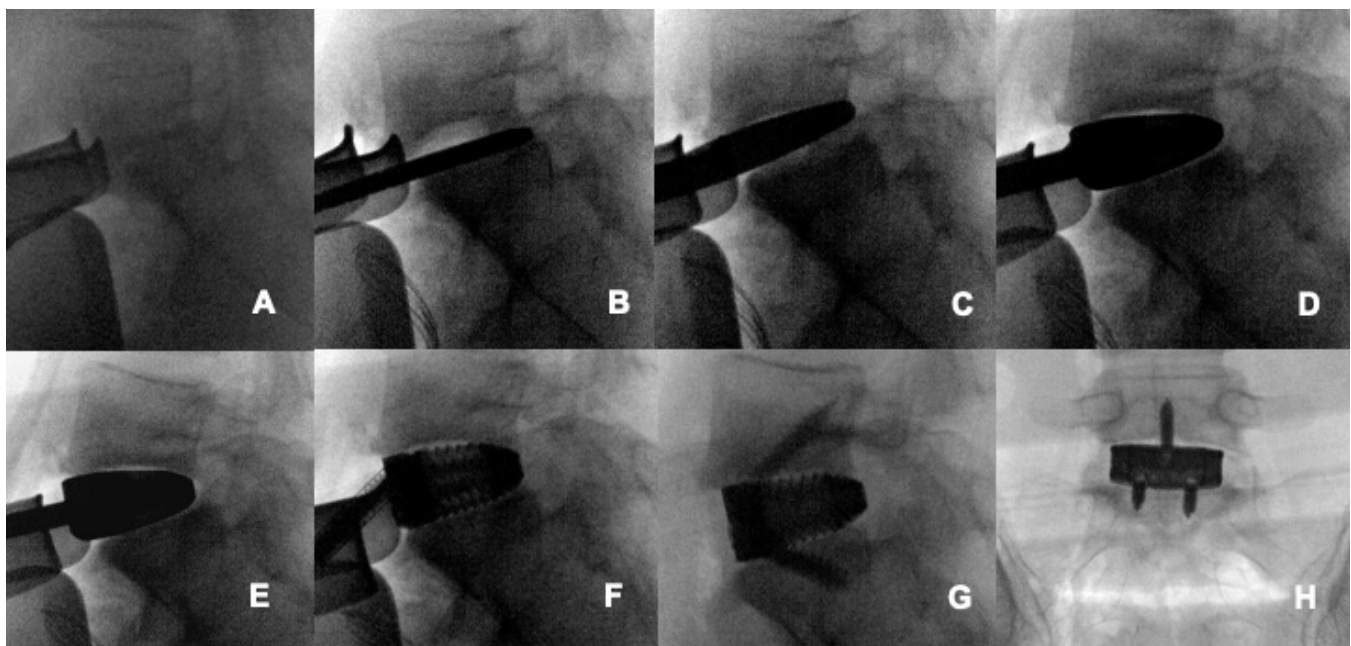


Figure 1. Fluoroscopic images of anterior lumbar interbody fusion. (A) Anterior L5/S1 disc exposure. (B) Seven-millimeter paddle distractor (not rotated) to posterior apophyseal ring. (C) Nine-millimeter paddle distractor (rotated) to posterior apophyseal ring. (D) Large 13 mm, 15° trial. (E) Large 15 mm, 15° trial. (F) Large 15 mm, 15° cage. (G) Cage with screw fixation (lateral). (H) Cage with screw fixation (anteroposterior).

5.1.19 of the National Statement on Ethical Conduct in Human Research (2007). Institutional approval was granted by Epworth HealthCare (EH2024-1153). The authors are accountable for all aspects of the work in ensuring that questions related to the accuracy or integrity of any part of the work are appropriately investigated and resolved.

Statistical Methods

Counts and percentages were reported for categorical data, means, and SDs for continuous data. Proportions tests were used to compare categorical data between both cohorts (sa-ALIF and ALIF-PSF). Normal distribution was checked using Shapiro-Wilk tests. Paired sample *t* tests were used to compare PROMs and radiographic parameters from baseline to final follow-up. Independent *t* tests were used to compare patient demographics, operative statistics, clinical outcomes, and radiographic outcomes between both cohorts (sa-ALIF and ALIF-PSF). Statistical significance was assessed at $P = 0.05$, 2-tailed. Analyses were performed in Stata 18 (Stata Corporation, College Station, Texas).

RESULTS

The cohort consisted of 51 patients (sa-ALIF 22 and ALIF-PSF 29) with similar demographics (Table 2). Mean age and BMI of sa-ALIF were 43.3 ± 14.1 years (54.5% men) and 24.1 ± 2.0 kg/m² vs 48.7 ± 11.4 years (62.1%

men) and 27.9 ± 3.4 kg/m² for the ALIF-PSF cohort. Only 4 patients were current smokers (sa-ALIF $n = 1$). All patients were privately insured (except for 1 patient in the sa-ALIF cohort who received workers' compensation). There were 43 grade I IS (sa-ALIF 22 and ALIF-PSF 21) and 8 grade II IS (ALIF-PSF 8) patients. There were 4 two-level procedures at L4/5 and L5/S1, 2 involving an L4/L5 total disc replacement and L5/S1 ALIF (sa-ALIF 1 and ALIF-PSF 1), and 2 involving a 2-level ALIF at L4/L5 and L5/S1 (sa-ALIF 1 and ALIF-PSF 1).

Only 6 patients (sa-ALIF 1 and ALIF-PSF 5) received an interbody cage with a separate buttress plate, with the remainder receiving integrated cage-plate-screw constructs. rhBMP-2 was used in 22/29 (92%) of the earlier ALIF-PSF cohort but only 4/22 (19%) of the more recent sa-ALIF cohort.

All PROMs significantly improved from baseline to final follow-up in both sa-ALIF and ALIF-PSF except SF-12 MCS (Table 3). Mean VAS leg values were lower in the sa-ALIF cohort preoperatively (sa-ALIF 7.2 vs ALIF-PSF 8.1, $P < 0.05$) and 6 weeks postoperatively (sa-ALIF 2.7 vs ALIF-PSF 4.9, $P < 0.001$), while mean SF-12 physical component summary scores were greater in the sa-ALIF cohort 6 weeks postoperatively (sa-ALIF 39.9 vs ALIF-PSF 36.8, $P < 0.05$). There were no other significant differences ($P < 0.05$) in baseline PROMs and PROMs at all follow-up time points. The decision regret scores were extremely low, indicating low regret in both cohorts.

Table 2. Patient demographics and operative data.

Characteristic	sa-ALIF and ALIF + PSF ($n = 51$)	sa-ALIF ($n = 22$)	ALIF + PSF ($n = 29$)	<i>P</i>
Men, <i>n</i> (%)	30 (58.8)	12 (54.5)	18 (62.1)	NS
Age (mean \pm SD)	46.4 \pm 12.8	43.3 \pm 14.1	48.7 \pm 11.4	NS
Follow-up in years (mean \pm SD)	3.9 \pm 3.2	2.1 \pm 1.8	5.3 \pm 3.4	0.004
BMI kg/m ² (mean \pm SD)	26.6 \pm 4.1	24.1 \pm 2.6	27.9 \pm 4.2	0.02
Smoking status (<i>n</i> , %)				
Yes	4 (7.8)	1 (4.5)	3 (10.3)	NS
Ex	11 (21.6)	1 (4.5)	10 (34.5)	0.0100
No	36 (70.6)	20 (91.0)	16 (55.2)	0.0055
Insurance status				
Private	50	21	29	NS
Worker's compensation	1	1	0	
Grade				
I	43	22	21	0.0073
II	8	0	8	
Operation				
Single level	47	20	27	NS
L4/5 TDR and L5/S1 ALIF	2	1	1	
L4/5 ALIF and L5/S1 ALIF	2	1	1	
Cage type				
Cage + buttress plate	6	1	5	NS
Integrated cage	45	21	24	
Bone substitute				
rhBMP-2	31 (60.8)	5 (22.7)	26 (89.7)	<0.0001
DBA	20 (39.2)	17 (77.3)	3 (10.3)	<0.0001

Abbreviations: ALIF, anterior lumbar interbody fusion; BMI, body mass index; DBA, demineralized bone allograft; NS, not significant; PSF, pedicle-screw fixation; rhBMP-2, recombinant human bone morphogenic protein 2; sa-ALIF, standalone anterior lumbar interbody fusion; TDR, total disc replacement.

Table 3. Clinical outcomes.

Cohort	PROMs at 0 mo			PROMs at 6 wk		
	sa-ALIF	ALIF-PSF	<i>P</i>	sa-ALIF	ALIF-PSF	<i>P</i>
VAS leg	7.2 ± 1.7	8.1 ± 1.5	0.035	2.7 ± 2.2	4.9 ± 1.7	0.0002
VAS back	7.5 ± 1.4	7.2 ± 1.9	NS	4.1 ± 1.4	4.1 ± 2.0	NS
ODI	28.0 ± 5.3	30.9 ± 4.8	NS	18.6 ± 6.2	21.1 ± 5.0	NS
SF-12 PCS	27.9 ± 5.7	26.3 ± 4.1	NS	39.9 ± 6.3	36.8 ± 4.4	0.042
SF-12 MCS	51.2 ± 8.9	51.7 ± 6.2	NS	55.2 ± 5.9	54.4 ± 4.3	NS

Cohort	PROMs at 6 mo			PROMs at 12 mo		
	sa-ALIF	ALIF-PSF	<i>P</i>	sa-ALIF	ALIF-PSF	<i>P</i>
VAS leg	1.7 ± 1.7	2.3 ± 2.0	NS	0.8 ± 1.0	1.8 ± 1.7	NS
VAS back	2.7 ± 1.5	2.4 ± 1.8	NS	2.3 ± 1.7	1.8 ± 2.0	NS
ODI	11.9 ± 5.6	9.5 ± 5.5	NS	8.7 ± 7.0	7.7 ± 6.0	NS
SF-12 PCS	45.9 ± 5.3	48.5 ± 7.1	NS	50.5 ± 6.2	50.4 ± 6.8	NS
SF-12 MCS	54.9 ± 5.7	53.8 ± 4.6	NS	53.4 ± 4.2	54.4 ± 4.1	NS

Cohort	PROMs at Final Follow-Up		
	sa-ALIF (mean follow-up = 2.1 y)	ALIF-PSF (mean follow-up = 5.3 y)	<i>P</i>
VAS leg	0.9 ± 1.1	1.4 ± 1.5	NS
VAS back	2.4 ± 1.4	2.3 ± 2.0	NS
ODI	5.6 ± 3.7	6.9 ± 5.0	NS
SF-12 PCS	52.1 ± 4.4	48.4 ± 6.6	NS
SF-12 MCS	52.6 ± 3.3	52.6 ± 3.9	NS
Decision regret score	5.8 ± 10.4	2.5 ± 11.2	NS

Abbreviations: ALIF, anterior lumbar interbody fusion; MCS, mental component summary; NS, not significant; ODI, Oswestry Disability Index; PCS, physical component summary; PROMs, patient-reported outcome measures; PSF, pedicle-screw fixation; sa-ALIF, standalone anterior lumbar interbody fusion; SF-12, 12-item Short-Form survey; VAS, visual analog scale.

Table 4 shows our radiographic fusion results with example fusion in Figure 2. At 6 months postoperatively, fusion rates (Bridwell interbody fusion grade 1 or 2) were 36.4% and 50.0% in the sa-ALIF and ALIF-PSF cohorts ($P = 0.34$), respectively, increasing to 81.8% and 88.5% 12 months postoperatively ($P = 0.52$). The mean fusion rates were not significantly different between the sa-ALIF cohort and the ALIF-PSF cohort at 6 and 12 months postoperatively. None of the sa-ALIF patients required subsequent supplemental posterior fixation.

There was no significant change ($P > 0.05$) in the degree of anterolisthesis or segmental lordosis in either cohort (sa-ALIF and ALIF-PSF) comparing preoperative to 12-month measurements. Conversely, disc height improved in sa-ALIF ($P = 0.0001$) and ALIF-PSF ($P =$

0.0001) cohorts comparing preoperative to 12-month postoperative scores. The mean disc height in the sa-ALIF cohort was significantly greater than in the ALIF-PSF cohort 6 months postoperatively (sa-ALIF 12.1 mm vs ALIF-PSF 10.4, $P < 0.05$; Table 5). There were no other significant differences in radiographic parameters between both cohorts at baseline, 6 months postoperatively, and 12 months postoperatively.

There were 12 adverse events (Table 6), 2 of which occurred in the acute postoperative period (ALIF-PSF 2) and 10 of which (sa-ALIF 2 and ALIF-PSF 8) were chronic (>6 months). The superficial wound infections were in the ALIF-PSF cohort. Of the 8 patients with persisting back and lower extremity pain, only 1 patient required revision surgery for nerve root decompression. This reoperation was not due to the failure of the ALIF

Table 4. Computed tomography fusion outcomes at 6- and 12-month follow-up.

Cohort	Fusion at 6 mo			Fusion at 12 mo		
	sa-ALIF	ALIF-PSF	<i>P</i>	sa-ALIF	ALIF-PSF	<i>P</i>
Mean ± SD	2.5 ± 0.6	2.6 ± 0.6	0.76	2.1 ± 0.5	2.0 ± 0.6	0.75
Bridwell grade, <i>n</i> (%)	<i>n</i> = 22	<i>n</i> = 26		<i>n</i> = 22	<i>n</i> = 26	
I	1 (4.5)	0		2 (9.1)	3 (11.5)	
II	7 (31.8)	13 (50.0)		16 (72.7)	20 (76.9)	
III	14 (63.6)	12 (46.2)		4 (18.2)	2 (7.7)	
IV	0	1 (3.8)		0	1 (3.8)	
Fused (Bridwell I/II)	8 (36.4)	13 (50.0)	0.34	18 (81.8)	23 (88.5)	0.52

Abbreviations: ALIF, anterior lumbar interbody fusion; PSF, pedicle-screw fixation; sa-ALIF, standalone anterior lumbar interbody fusion.

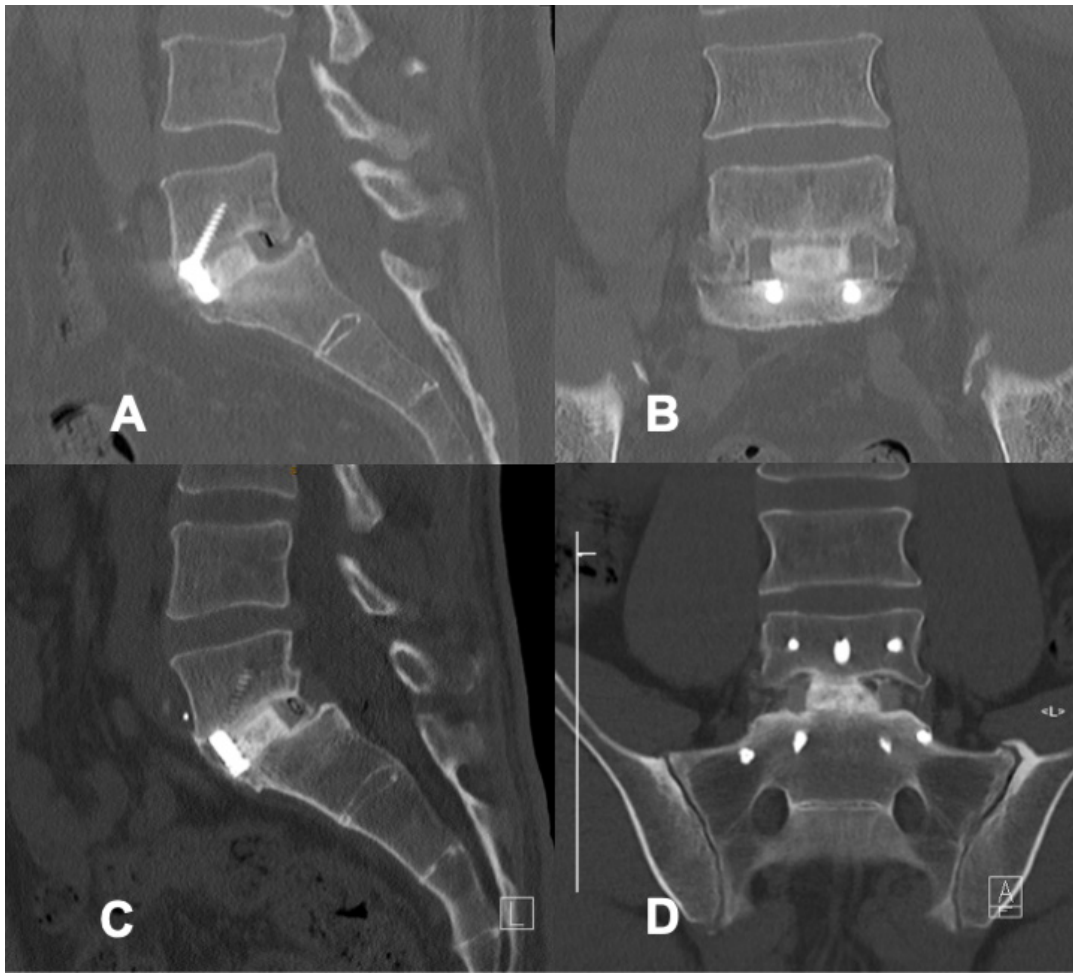


Figure 2. Example fusion on 12-month postoperative computed tomography for standalone anterior lumbar interbody fusion (ALIF) (A) sagittal and (B) coronal view and for ALIF with pedicle screw fixation (C) sagittal and (D) coronal view.

cage. No patients experienced retrograde ejaculation. There were no vascular complications.

DISCUSSION

This retrospective cohort study was conducted over the past decade to evaluate whether sa-ALIF is effective for the treatment of low-grade IS, avoiding the added cost and morbidity of posterior fixation. In our study, we reported a shorter mean follow-up time in the sa-ALIF cohort (2.1 years) vs ALIF-PSF (3.9 years). This was accounted for by the availability of integrated

cage-plate-screw fixation in the sa-ALIF group from 2018 and a change in surgeon preference, away from potentially unnecessary PSF.

The majority of ALIF-PSF patients received rhBMP-2 compared with the sa-ALIF cohort where the majority received DBA. This was accounted for by the regulatory withdrawal of rhBMP-2 in March 2020 in Australia. Despite the difference in biological use between the sa-ALIF and ALIF-PSF, there were no significant differences in CT interbody fusion rates between the 2 cohorts.

Table 5. Radiographic parameters at pre- and postoperative timepoints.

Cohort	Preoperative			6 mo Postoperative			12 mo Postoperative		
	sa-ALIF (n = 6)	ALIF-PSF (n = 11)	P	sa-ALIF (n = 17)	ALIF-PSF (n = 22)	P	sa-ALIF (n = 12)	ALIF-PSF (n = 14)	P
% anterolisthesis	15.4 ± 7.7	17.5 ± 8.3	NS	11.9 ± 6.6	14.6 ± 8.8	NS	13.1 ± 2.2	13.5 ± 2.7	NS
Segmental lordosis, mm	11.7 ± 5.9	10.0 ± 5.9	NS	14.7 ± 1.2	12.9 ± 1.2	NS	13.4 ± 1.1	12.3 ± 1.4	NS
Disc height, mm	7.1 ± 2.6	6.9 ± 2.1	NS	12.1 ± 0.3	10.4 ± 0.6	0.035	11.8 ± 0.4	10.7 ± 0.5	NS

Abbreviations: ALIF, anterior lumbar interbody fusion; NS, not significant; PSF, pedicle-screw fixation; sa-ALIF, standalone anterior lumbar interbody fusion.

Table 6. Adverse events to final follow-up.

Adverse Events	Total (N = 51)	sa-ALIF (n = 22)	ALIF + PSF (n = 29)
Total complications	12	2	10
Acute complications			
Superficial wound infection	3	0	3
Chronic complications			
Persisting mechanical back pain (VAS back >5)	4	1	3
Persisting radicular lower extremity pain (VAS leg >5)	4	1	3
Reoperation			
PSF revision requiring posterior decompression	1	0	1

Abbreviations: ALIF, anterior lumbar interbody fusion; PSF, pedicle-screw fixation; sa-ALIF, standalone anterior lumbar interbody fusion; VAS, visual analog scale.

Clinical Outcomes

In our study, both sa-ALIF and ALIF-PSF had significant improvements in all PROMs from baseline to final follow-up. ALIF with posterior fixation has been reported as effective in improving patients' PROMs.^{6,7,20–23} Few studies have reported PROMs for sa-ALIF.^{13–15}

VAS leg scores were significantly lower in the sa-ALIF cohort both preoperatively and 6 weeks postoperatively. This may be partially attributed to heterogeneity in patient demographics, as the sa-ALIF group had lower BMIs, fewer smokers, and no cases of Meyerding grade II. The added morbidity from posterior fixation may also contribute to the higher VAS leg scores and lower SF-12 physical component summary scores in the ALIF-PSF cohort at 6 weeks postoperatively. No other statistical differences were observed between the 2 cohorts across the recorded timepoints. This suggests, in appropriately selected patients, that sa-ALIF is effective in treating IS and avoiding the associated disadvantages of the additional instrumentation.

Mean decision regret scores were extremely low in both cohorts. This may reflect our study's low number of workers' compensation patients ($n = 1$), who are associated with lower postoperative satisfaction (RR = 2.10) according to a meta-analysis from 2021.²⁴

Sa-ALIF Outcomes

Aunoble et al¹³ presented 20 adults with low-grade spondylolisthesis with a similar mean follow-up (2.2 years) compared with our study (2.1 years). In their study, comparing preoperative PROMs to final follow-up, ODI scores decreased from 57% (28.5) to 21% (10.5), VAS back pain decreased significantly from 6.5 to 2.7, and VAS leg decreased from 6.2 to 3.4. Our study demonstrated superior improvements in VAS leg with similar improvements in ODI and VAS back.

Kim and Lee¹⁴ presented outcomes of 40 patients with low-grade IS (sa-ALIF 20, posterolateral fusion + PSF 20) and conducted from 1977 to 1994 with an average follow-up of 3.6 years. In the sa-ALIF group, 17/20 patients had excellent or good outcomes, supporting the use of sa-ALIF for low-grade IS.

Likewise, a recent study by Jesse et al¹⁵ of 34 patients who received sa-ALIF for low-grade IS at L5/S1 reported 12-month postoperative PROMs (VAS back 1.9, VAS leg 1.7, ODI 10.2) that were similar to our findings.

A systematic review that reported PROMs following sa-ALIF for varying indications showed similar improvements in VAS back (7–2.9) and inferior improvements in VAS leg (5.6–2.3) and ODI (26.1–12.5) postoperatively.²⁵

Our results suggest a clinical benefit of using sa-ALIF in IS, consistent with the positive results previously reported in the literature.

ALIF-PSF Outcomes

Studies comparing ALIF-PSF to T/PLIF for IS have shown that ALIF-PSF is safe and effective for low-grade IS.^{20–23} Ould-Slimane et al²¹ compared ALIF with posterior fixation to posterior approaches (transforaminal lumbar interbody fusion [TLIF]/PLIF). Compared with posterior approaches, circumferential fusion provided greater improvements in VAS leg, VAS back, ODI, and SF-12 physical component score at mean 46-month follow-up. However, a systematic review by Alhamoud et al²⁰ with a total of 397 patients with IS (198 ALIF-PLF, 199 TLIF/PLIF + PLF) found no significant difference in clinical outcomes or fusion rates between combined anterior-posterior approaches and posterior-alone approach.

Likewise, Prost et al²² investigated 89 patients with IS who received ALIF-PSF ($n = 71$) vs TLIF ($n = 18$), and Kim et al²³ reported 78 patients who received circumferential ALIF ($n = 46$) vs TLIF ($n = 32$). Both reported improvements in VAS back and VAS leg comparable to our study.

Adverse Events

Anterior retroperitoneal approaches are associated with complications including incisional hernias, ileus, retrograde ejaculation, and vascular injury,^{26–28} while posterior approaches risk paraspinal muscle denervation, neurological injury, dural tears, hardware failure, and nonunion.^{28–30}

There are concerns regarding the morbidity associated with supplemental posterior fixation in ALIF.

However, a recent multicenter retrospective cohort study of 1377 ALIF patients found no significant difference in adjacent segment disease rates between sa-ALIF and ALIF with posterior fixation.⁹ Our complication rate for sa-ALIF was 9% which is comparable to literature reports, ranging from 10% to 35%.^{14,15,25,31} But our complication rate for ALIF-PSF was 34%, higher than reported rates of 4.2% to 18.6%^{21,22,32} accounted for by our inclusion of persisting mechanical and lower extremity pain, not included in most other studies.

The higher rates of complications seen in our ALIF-PSF cohort may be attributed to morbidity associated with posterior fixation, supporting sa-ALIF for appropriately selected patients. Heterogeneity between the sa-ALIF and ALIF-PSF cohorts may also influence this discrepancy.

Radiographic Outcomes

Reported interbody fusion rates for ALIF-PSF range from 88% to 100%,^{21,23,32,33} higher than sa-ALIF fusion rates, which range from 60% to 95%,^{13–15,34,35} supported by a recent multicenter retrospective review of 1377 IS patients,⁹ reporting nonunion rates of 2.4% for sa-ALIF vs 0.5% for ALIF-PSF.

The nonunion rates in our study were also comparatively low, with high fusion rates in both cohorts with no significant difference between sa-ALIF (81.8%) vs ALIF-PSF (92.0%). No patients in the sa-ALIF group needed subsequent supplemental posterior fixation. The trend to higher and earlier fusion rates found in our ALIF-PSF cohort may be secondary to the added stability of the PSF construct.

Disc height was significantly better at 12-month follow-up in both cohorts, which was not the case for segmental lordosis or the degree of anterolisthesis. It is unclear if these radiological outcomes impact the clinical findings. Studies on IS patients have reported greater increases in segmental lordosis in their sa-ALIF²⁵ and ALIF-PSF cohorts.^{6,22,32} Reasons for this are multifactorial and may include varying surgical techniques, noting that in this study, a 15° lordotic cage was used. The mean increase in disc height postoperatively in our sa-ALIF cohort (4.7 mm) and ALIF-PSF cohort (3.8 mm) is consistent with literature reports on sa-ALIF²⁵ and ALIF-PSF (3–8.7 mm).^{6,22,32,36} In this study, both cohorts experienced a nonsignificant reduction in anterolisthesis. This is consistent with some literature reports^{22,25} and not others.^{6,32,36} This discrepancy may reflect alternate surgical technique or the greater degree of anterolisthesis seen in some cohorts.

At the 12-month final follow-up, there were no significant differences between the cohorts in radiographic scores. This suggests that the addition of pedicle screws to and ALIF construct may not enhance the final radiographic outcomes.

Cost

Our study demonstrates comparable clinical outcomes and fusion rates between sa-ALIF and ALIF-PSF for low-grade IS spondylolisthesis. The avoidance of supplemental posterior fixation reduced patient morbidity and cost. Studies report up to a 22% increase in cost for supplemental posterior fixation with Goz et al reporting the average cost for ALIF as \$75,872 compared with \$92,249 in ALIF with posterior fixation.³⁷ We recently published mean operative charges of AUD\$2500 per hour.³⁸ Quoted in this study, the average cost of our single-level sa-ALIF was AUD\$25,053. The cost of posterior fixation would approximate to AUD\$6644 for the implants and AUD\$3750 for an additional 90 minutes of operative time on average.

The difference in the cost of each bone graft (rhBMP-2 and DBA) is small, with the DBA costing AUD\$6193 per 8.5 mg used and rhBMP-2 costing AUD\$6000 per 8.4 mg used (in 2014).

Strengths and Limitations

This was a retrospective analysis of prospectively collected data with a limited sample size. Cohorts were compared in a nonrandomized fashion. All operations were conducted by a consultant spine surgeon at a single center. These data were collected over a 12-year period, which adds unavoidable heterogeneity to the surgical technique. We note that the sa-ALIF surgeries were performed more recently than the group of ALIF-PLF patients. Additionally, most ALIF-PSF patients received rhBMP-2, while most sa-ALIF patients received DBA due to a regulatory change. It would be prudent to follow up with this DBA cohort long term to assess concerns such as infection risk. Further randomized, controlled, and larger comparisons between sa-ALIF and ALIF-PLF are needed to definitively evaluate the statistical difference in clinical and radiographic outcomes.

CONCLUSION

In appropriately selected patients with normal bone density, sacral slope, and a BMI <35, sa-ALIF is a safe and effective treatment option for grade I IS without the need for supplementary posterior fixation. The additional morbidity and cost of PSF may not be justified

given the satisfactory clinical and radiographic outcomes of sa-ALIF for grade I IS.

REFERENCES

1. Fredrickson BE, Baker D, McHolick WJ, Yuan HA, Lubicky JP. The natural history of spondylolysis and spondylolisthesis. *J Bone Joint Surg.* 1984;66(5):699–707. doi:10.2106/00004623-198466050-00008
2. Beutler WJ, Fredrickson BE, Murtland A, Sweeney CA, Grant WD, Baker D. The natural history of spondylolysis and spondylolisthesis: 45-year follow-up evaluation. *Spine.* 2003;28(10):1027–1035. doi:10.1097/01.BRS.0000061992.98108.AO
3. Meyerding HW. Low backache and sciatic pain associated with spondylolisthesis and protruded intervertebral disc: incidence, significance, and treatment. *JBJS.* 1941;23(2):461–470.
4. Koslosky E, Gendelberg D. Classification in brief: the Meyerding classification system of spondylolisthesis. *Clin Orthop Relat Res.* 2020;478(5):1125–1130. doi:10.1097/CORR.0000000000001153
5. Radcliff KE, Kalantar SB, Reitman CA. Surgical management of spondylolysis and spondylolisthesis in athletes: indications and return to play. *Curr Sports Med Rep.* 2009;8(1):35–40. doi:10.1249/JSR.0b013e318194f89e
6. Lightsey HM, Pisano AJ, Striano BM, et al. ALIF versus TLIF for L5-S1 isthmic spondylolisthesis: ALIF demonstrates superior segmental and regional radiographic outcomes and clinical improvements across more patient-reported outcome measures domains. *Spine.* 2022;47(11):808–816. doi:10.1097/BRS.0000000000004333
7. Wang S-J, Han Y-C, Liu X-M, et al. Fusion techniques for adult isthmic spondylolisthesis: a systematic review. *Arch Orthop Trauma Surg.* 2014;134(6):777–784. doi:10.1007/s00402-014-1985-9
8. Kerolus M, Turel MK, Tan L, Deutsch H. Stand-alone anterior lumbar interbody fusion: indications, techniques, surgical outcomes and complications. *Expert Rev Med Devices.* 2016;13(12):1127–1136. doi:10.1080/17434440.2016.1254039
9. Laiwalla AN, Chang RN, Harary M, et al. Primary anterior lumbar interbody fusion, with and without posterior instrumentation: a 1,377-patient cohort from a multicenter spine registry. *Spine J.* 2024;24(3):496–505. doi:10.1016/j.spinee.2023.10.003
10. Freeman MD, Woodham MA, Woodham AW. The role of the lumbar multifidus in chronic low back pain: a review. *PM R.* 2010;2(2):142–146. doi:10.1016/j.pmrj.2009.11.006
11. Lee JC, Cha JG, Kim Y, Kim YI, Shin BJ. Quantitative analysis of back muscle degeneration in the patients with the degenerative lumbar flat back using a digital image analysis. *Spine.* 2008;33(3):318–325. doi:10.1097/BRS.0b013e318162458f
12. Cho S-M, Kim S-H, Ha S-K, et al. Paraspinal muscle changes after single-level posterior lumbar fusion: volumetric analyses and literature review. *BMC Musculoskelet Disord.* 2020;21(1). doi:10.1186/s12891-020-3104-0
13. Aunoble S, Hoste D, Donkersloot P, Liquois F, Basso Y, Le Huec JC. Video-assisted ALIF with cage and anterior plate fixation for L5-S1 spondylolisthesis. *J Spinal Disord Tech.* 2006;19(7):471–476. doi:10.1097/01.bsd.0000211249.82823.d9
14. Kim NH, Lee JW. Anterior interbody fusion versus posterolateral fusion with transpedicular fixation for isthmic spondylolisthesis in adults: a comparison of clinical results. *Spine.* 1999;24(8):812–816. doi:10.1097/00007632-199904150-00014
15. Jesse CM, Schwarzenbach O, Ulrich CT, Häni L, Raabe A, Schär RT. Safety and efficacy of stand-alone anterior lumbar interbody fusion in low-grade L5-S1 isthmic spondylolisthesis. *Br Sp.* 2022;2. doi:10.1016/j.bas.2022.100861
16. Naik-Panvelkar P, Norman S, Elgebaly Z, et al. Osteoporosis management in Australian general practice: an analysis of current osteoporosis treatment patterns and gaps in practice. *BMC Fam Pract.* 2020;21(1):32. doi:10.1186/s12875-020-01103-2
17. Brehaut JC, O'Connor AM, Wood TJ, et al. Validation of a decision regret scale. *Med Decis Making.* 2003;23(4):281–292. doi:10.1177/0272989X03256005
18. Bridwell KH, Lenke LG, McEnery KW, Baldus C, Blanke K. Anterior fresh frozen structural allografts in the thoracic and lumbar spine. do they work if combined with posterior fusion and instrumentation in adult patients with kyphosis or anterior column defects? *Spine.* 1995;20(12):1410–1418. doi:10.1097/00007632-199520120-00014
19. Malham GM, Louie PK, Brazenor GA, Mobbs RJ, Walsh WR, Sethi RK. Recombinant human bone morphogenetic protein-2 in spine surgery: recommendations for use and alternative bone substitutes—a narrative review. *J Spine Surg.* 2022;8(4):477–490. doi:10.21037/jss-22-23
20. Alhammoud A, Schroeder G, Aldahamsheh O, et al. Functional and radiological outcomes of combined anterior-posterior approach versus posterior alone in management of isthmic spondylolisthesis. A systematic review and meta-analysis. *Int J Spine Surg.* 2019;13(3):230–238. doi:10.14444/6031
21. Ould-Slimane M, Prost S, d'Astorg H, et al. Fusion and clinical outcomes of lumbar interbody fusion for low-grade isthmic spondylolisthesis. *Orthop Traumatol Surg Res.* 2023;109(2). doi:10.1016/j.otsr.2022.103508
22. Prost S, Giorgi H, Ould-Slimane M, et al. Surgical management of isthmic spondylolisthesis: a comparative study of postoperative outcomes between ALIF and TLIF. *Orthop Traumatol Surg Res.* 2023;109(6). doi:10.1016/j.otsr.2023.103560
23. Kim JS, Kim DH, Lee SH. Comparison between instrumented mini-TLIF and instrumented circumferential fusion in adult low-grade lytic spondylolisthesis: can mini-TLIF with PPF replace circumferential fusion? *J Korean Neurosurg Soc.* 2009;45(2):74–80. doi:10.3340/jkns.2009.45.2.74
24. Russo F, De Salvatore S, Ambrosio L, et al. Does workers' compensation status affect outcomes after lumbar spine surgery? A systematic review and meta-analysis. *Int J Environ Res Public Health.* 2021;18(11). doi:10.3390/ijerph18116165
25. Giang G, Mobbs R, Phan S, Tran TM, Phan K. Evaluating outcomes of stand-alone anterior lumbar interbody fusion: a systematic review. *World Neurosurg.* 2017;104:259–271. doi:10.1016/j.wneu.2017.05.011
26. Mobbs RJ, Phan K, Malham G, Seex K, Rao PJ. Lumbar interbody fusion: techniques, indications and comparison of interbody fusion options including PLIF, TLIF, mi-TLIF, OLIF/ATP, LLIF and ALIF. *J Spine Surg.* 2015;1(1):2–18. doi:10.3978/j.issn.2414-469X.2015.10.05
27. Manunga J, Alcalá C, Smith J, et al. Technical approach, outcomes, and exposure-related complications in patients undergoing anterior lumbar interbody fusion. *J Vasc Surg.* 2021;73(3):992–998. doi:10.1016/j.jvs.2020.06.129
28. Lenz M, Mohamud K, Bredow J, Oikonomidis S, Eysel P, Scheyerer MJ. Comparison of different approaches in lumbosacral

spinal fusion surgery: a systematic review and meta-analysis. *Asian Spine J.* 2022;16(1):141–149. doi:10.31616/asj.2020.0405

29. Chrastil J, Patel AA. Complications associated with posterior and transforaminal lumbar interbody fusion. *J Am Acad Orthop Surg.* 2012;20(5):283–291. doi:10.5435/JAAOS-20-05-283

30. De Stefano F, Haddad H, Mayo T, Nouman M, Fiani B. Outcomes of anterior vs. posterior approach to single-level lumbar spinal fusion with interbody device: an analysis of the nationwide inpatient sample. *Clin Neurol Neurosurg.* 2022;212. doi:10.1016/j.clineuro.2021.107061

31. Sharma M, Jain N, Wang D, Ugiliweneza B, Boakye M. Trends of different surgical approaches in patients with single-level lumbar isthmic spondylolisthesis: a national registry analysis. *Cureus.* 2023;15(1). doi:10.7759/cureus.34194

32. Kim J-S, Kim D-H, Lee S-H, et al. Comparison study of the instrumented circumferential fusion with instrumented anterior lumbar interbody fusion as a surgical procedure for adult low-grade isthmic spondylolisthesis. *World Neurosurg.* 2010;73(5):565–571. doi:10.1016/j.wneu.2010.02.057

33. Shim JH, Kim WS, Kim JH, Kim DH, Hwang JH, Park CK. Comparison of instrumented posterolateral fusion versus percutaneous pedicle screw fixation combined with anterior lumbar interbody fusion in elderly patients with L5–S1 isthmic spondylolisthesis and foraminal stenosis. *J Neurosurg Spine.* 2011;15(3):311–319. doi:10.3171/2011.4.SPINE10653

34. Christensen FB, Karlsmose B, Hansen ES, Bünger CE. Radiological and functional outcome after anterior lumbar interbody spinal fusion. *Eur Spine J.* 1996;5(5):293–298. doi:10.1007/BF00304343

35. Moon MS, Kim SS, Sun DH, Moon YW. Anterior spondylodesis for spondylolisthesis: isthmic and degenerative types. *Eur Spine J.* 1994;3(3):172–176. doi:10.1007/BF02190582

36. Kim JS, Lee KY, Lee SH, Lee HY. Which lumbar interbody fusion technique is better in terms of level for the treatment of unstable isthmic spondylolisthesis? *J Neurosurg Spine.* 2010;12(2):171–177. doi:10.3171/2009.9.SPINE09272

37. Goz V, Weinreb JH, Schwab F, Lafage V, Errico TJ. Comparison of complications, costs, and length of stay of three different

lumbar interbody fusion techniques: an analysis of the nationwide inpatient sample database. *Spine J.* 2014;14(9):2019–2027. doi:10.1016/j.spinee.2013.11.050

38. Malham GM, Blecher CM, Munday NR, Hamer RP. Expandable lateral lumbar cages with integrated fixation: a viable option for rostral adjacent segment disease. *Int J Spine Surg.* 2022;16(4):748–759. doi:10.14444/8307

Funding: The authors received no financial support for the research, authorship, and/or publication of this article.

Declaration of Conflicting Interests: The authors report no conflicts of interest in this work.

Disclosures: All authors have completed the ICMJE uniform disclosure form. G.M.M. has disclosures of Globus Medical (consultancy), Device Technologies (travel), Life Healthcare (consultancy, travel), Australian Biotechnology (consultancy), National Surgical (travel), Medtronic (consultancy), and SeaSpine (travel).

Corresponding Author: Gregory M. Malham, Epworth HealthCare, 89 Bridge Rd, Suite 8.3, Danks Tower, Richmond, Melbourne VIC 3121, Australia; gmalham@bigpond.net.au

Published 05 December 2024

This manuscript is generously published free of charge by ISASS, the International Society for the Advancement of Spine Surgery. Copyright © 2024 ISASS. To see more or order reprints or permissions, see <http://ijssurgery.com>.