

## Full Endoscopic Spinal Surgery Techniques: Advancements, Indications, and Outcomes

James J. Yue and William Long

*Int J Spine Surg* 2015, 9 ()

doi: <https://doi.org/10.14444/2017>

<https://www.ijssurgery.com/content/9/17>

This information is current as of May 17, 2025.

---

**Supplementary Material** <https://www.ijssurgery.com/content/suppl/2018/03/29/9.0.17.DC1>

**Email Alerts** Receive free email-alerts when new articles cite this article. Sign up at: <http://ijssurgery.com/alerts>

# Full Endoscopic Spinal Surgery Techniques: Advancements, Indications, and Outcomes

James J. Yue, MD, and William Long, MD

Department of Orthopaedic Surgery, Yale School of Medicine, New Haven, CT

## Abstract

Advancements in both surgical instrumentation and full endoscopic spine techniques have resulted in positive clinical outcomes in the treatment of cervical, thoracic, and lumbar spine pathologies. Endoscopic techniques impart minimal approach related disruption of non-pathologic spinal anatomy and function while concurrently maximizing functional visualization and correction of pathological tissues. An advanced understanding of the applicable functional neuroanatomy, in particular the neuroforamen, is essential for successful outcomes. Additionally, an understanding of the varying types of disc prolapse pathology in relation to the neuroforamen will result in more optimal surgical outcomes. Indications for lumbar endoscopic spine surgery include disc herniations, spinal stenosis, infections, medial branch rhizotomy, and interbody fusion. Limitations are based on both non spine and spine related findings. A high riding iliac wing, a more posteriorly located retroperitoneal cavity, an overly distal or proximally migrated herniated disc are all relative contra-indications to lumbar endoscopic spinal surgery techniques.

Modifications in scope size and visual field of view angulation have enabled both anterior and posterior cervical decompression. Endoscopic burrs, electrocautery, and focused laser technology allow for the least invasive spinal surgical techniques in all age groups and across varying body habitus. Complications include among others, dural tears, dysesthesia, nerve injury, and infection.

KEYWORDS: ENDOSCOPIC SPINE SURGERY, HISTORY, LUMBAR, TECHNIQUES  
VOLUME 9 ARTICLE 17 DOI: 10.14444/2017

## Introduction

Optimal surgical approaches to the spine impart minimal approach related disruption of non-pathologic spinal anatomy and function while concurrently maximizing functional visualization and correction of pathological tissues. Full endoscopic spine surgical approaches to the spine differ from other minimally invasive techniques as a result of the unique technical characteristics of the spinal working endoscope. The use of the spinal endoscope furthers the principles of minimally invasive spinal techniques by permitting the surgeon to visualize spinal contents in an expanded angled field of view (20-90°). This expanded view enhances and facilitates surgical treatment with minimal surgical dissection. Utilizing multiple approaches, the endoscope permits access to all regions of a spinal segment including those regions which are often deemed difficult to access such as the subarticular, far-lateral, and foraminal zones. Additionally, intra-discal endoscopic approaches permit direct visualization of the inner lining/layers of the disc annulus.

Standard endoscopic surgical techniques have traditionally been associated with the treatment of lumbar disc herniations.<sup>1</sup> Recent advances in endoscopic optical technology as well as endoscopic surgical techniques permit the care and treatment of other spinal disorders including decompression of central and foraminal stenosis of the lumbar, thoracic, and cervical spine including anterior cervical decompression.<sup>2-6</sup> An understanding of the history, development, technical specifications, surgical functional anatomy, indications and limitations, techniques, and potential complications is necessary to achieve optimal surgical outcomes. Appropriate surgical training including didactic lectures, hands on cadaveric training, and surgical observation should all be elements of surgical education and instruction.

### History, Development and Technical Specifications of Spinal Endoscopic Surgery

Minimally invasive techniques to address lumbar disc pathology have significantly evolved over the past 40 years. The first concept of spinal decompression through use of an annulotomy was described by

Hult in 1950, approaching the spine through an anterior retroperitoneal corridor.<sup>7</sup> Hijikata described his percutaneous nucleotomy technique 25 years later, incorporating a 2.6mm cannula, currettes, and pituitary rongeur to remove disc through a posterolateral approach.<sup>8</sup> Later, Kambin introduced the use of larger cannulas in the Hijikata disc entry site.<sup>9</sup> The use of an arthroscope was then described in 1983 by Hausmann and Forst, who visualized the contents of the intervertebral disc through a posterior approach necessitating laminectomy for access.<sup>10</sup> Kambin radiographically further defined the safe triangular working zone to the posterolateral annulus between the traversing and exiting nerve roots allowing fluoroscopic localization.<sup>11</sup> This sequential progress ultimately resulted in the first description of endoscopic discectomy in 1988.<sup>11</sup> Since then, technological advancements have given surgeons the ability to safely approach the disc through a percutaneous posterolateral transforaminal approach, endoscopically visualize the herniation, and utilize specialized instruments to remove the offending nucleus.

Early instrumentation consisted of a Craig cannula of various diameters with specialized spinal obturators that allowed safe disc entry. Nucleotomes were utilized for central nucleotomy, thereby indirectly decompressing the disc space. The advent of flexible tip forceps and articulating ends combined with suction allowed for direct excision of herniated disc. The use of the larger diameter cannula allowed for the introduction of the endoscope to assist with visualization. Current endoscopes come in a variety of diameters with multichannels, wide-angle lens, and variable tip angles (Figure 1). Bevel-ended tubular-access cannula offer the surgeon an unobstructed view of the epidural space, the annular wall, and the intradiscal space. These innovations allow for decompression of the nerve root through a single portal under direct visualization. Lastly, radiofrequency bipolar cauterization devices allow for electrocautery in a fluid environment.

## Anatomical Considerations and Indications/Contraindications

### Lumbar: Intra-foraminal Approach

Several endoscopic surgical approaches are employed to treat varying lumbar spinal disorders. The most common approach is the intra-foraminal approach which permits both intra-discal<sup>12,13</sup> and extra-discal<sup>14</sup> approaches. The superior half of the neuroforamen contains the exiting nerve root. The inferior half of the neuro-foramen is defined by intervertebral disc and the articular facet joint complex (Figure 2). The intra-foraminal, in particular the intra-discal approach, exploits a triangular working safe zone of which the floor is the intervertebral disc. The hypotenuse of the triangle is immediately infero-medial to the exiting lumbar nerve root and the inferior aspect of the superior endplate. The roof and medial side of the triangle is located below the facet lateral to the thecal sac. The inferior margin of the triangle is located at superior aspect of the inferior endplate (Figure 3).<sup>11</sup> Due to the normal bulge of the disc, the neuroforamen is narrowest posterior to the disc space in the mid portion of the neuroforamen. The anterior-posterior height of the foramen just posterior to the intervertebral disc is: 5.05 mm L3-4 level, 4.14mm L4-5 level, and 5.43 mm L5-S1. Posterior disc bulging at these same three levels is 1.27mm, 1.84mm, and 1.21mm respectively.<sup>15</sup>

One of the most important concepts in terms of endoscopic spine surgical approaches is understanding the pathologic neuroforaminal anatomy in terms of both disc pathology and facet changes. The intervertebral disc can prolapse in different directions and degrees (Figure 4). The nucleus can bulge with minimal annular disruption. The nucleus can herniate in a contained subligamentous manner or can extrude through the annulus and posterior longitudinal ligament. An extrusion can occur through the mid portion of the annulus or less commonly can occur as a result of a traumatic elevation/separation of the annulus from its posterior insertion to the vertebral body either superiorly or inferiorly. An extrusion that is a result of an elevation/separation at the superior aspect of the annulus may result in compression of the exiting nerve as it passes around its pedicle).

This unusual type of herniation is more than likely not a type of herniation which is endoscopically accessible and should be approached with a traditional posterior approach.

A disc herniation can also result from a deficiency/weakening in the mid portion of the annulus. The herniation can be contained within the confines of the annulus or can extrude through the annulus. A centrally located herniation located in the posterior central aspect of the disc is usually contained. A central herniation can usually be accessed through an intra-discal endoscopic approach. A herniation can also be present in the postero-lateral aspect of the disc space with or without migration inferiorly or superiorly. A direct postero-lateral herniation can be approached using an intra-foraminal extra-discal endoscopic approach as long as the extrusion does not

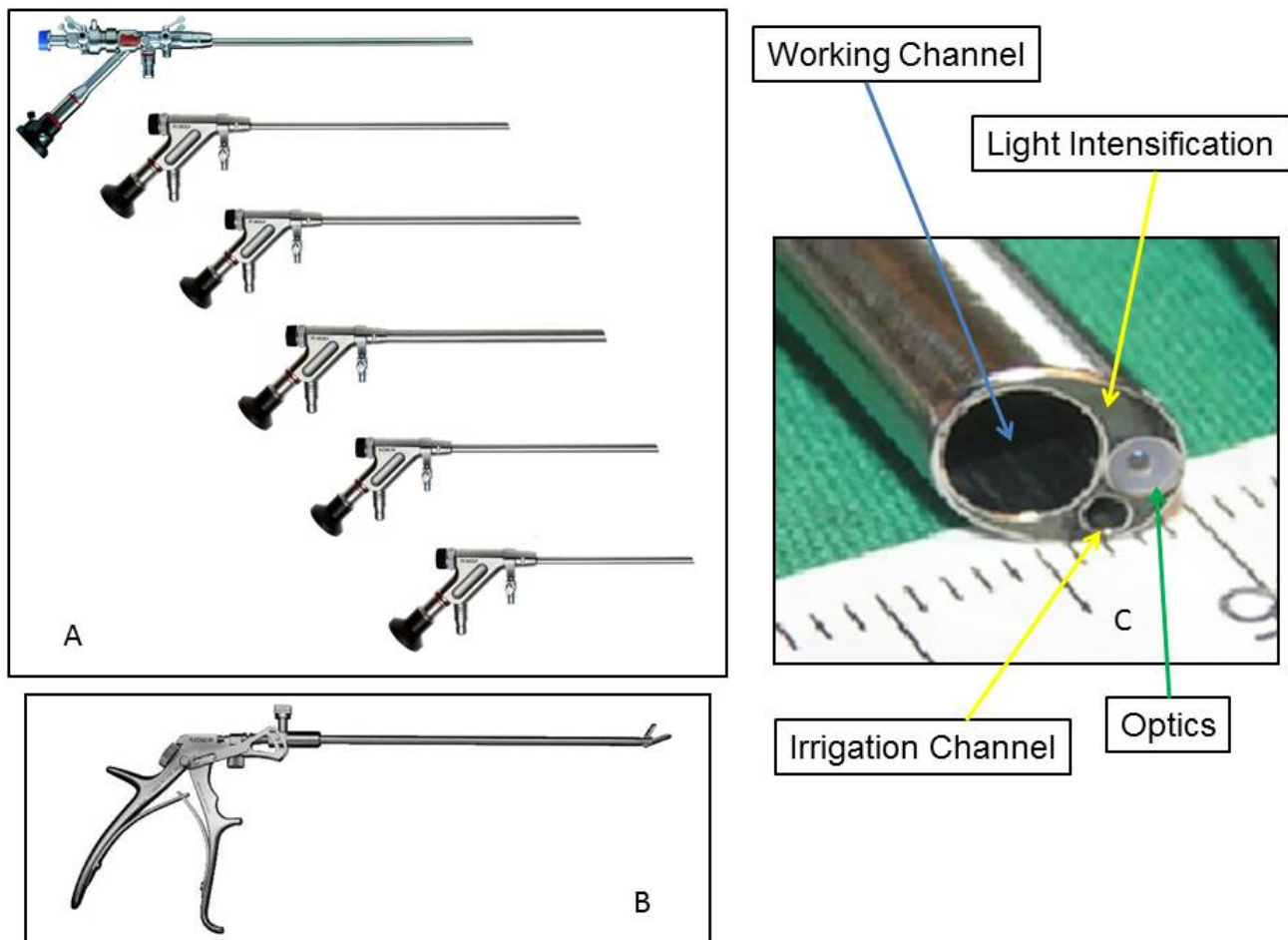
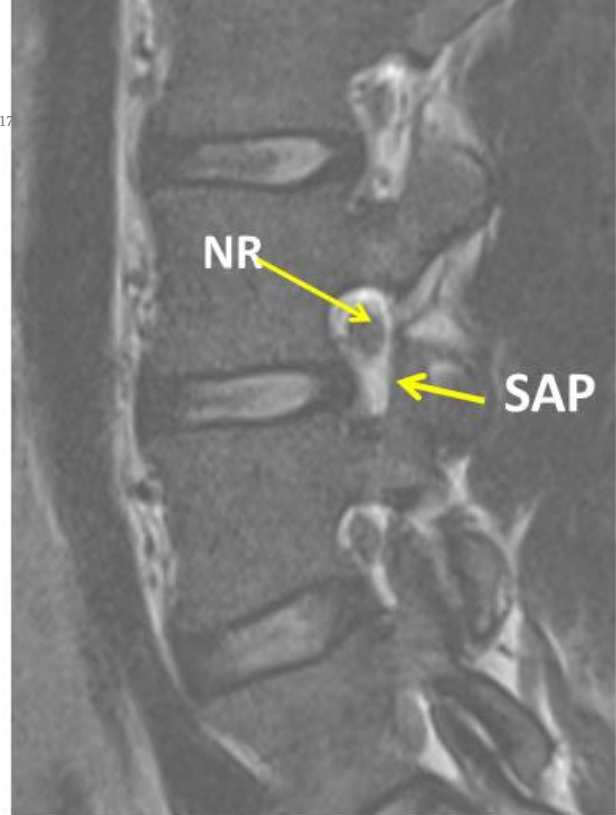


Fig. 1.

extend below the mid pedicle level distally or proximal to the inferior edge of the superior pedicle (Figure 5).

Fig. 2.

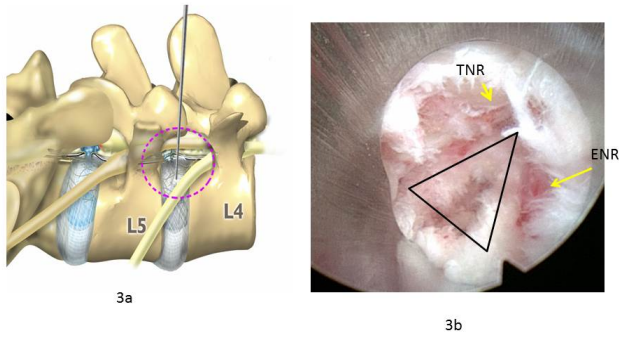


Fig. 3.

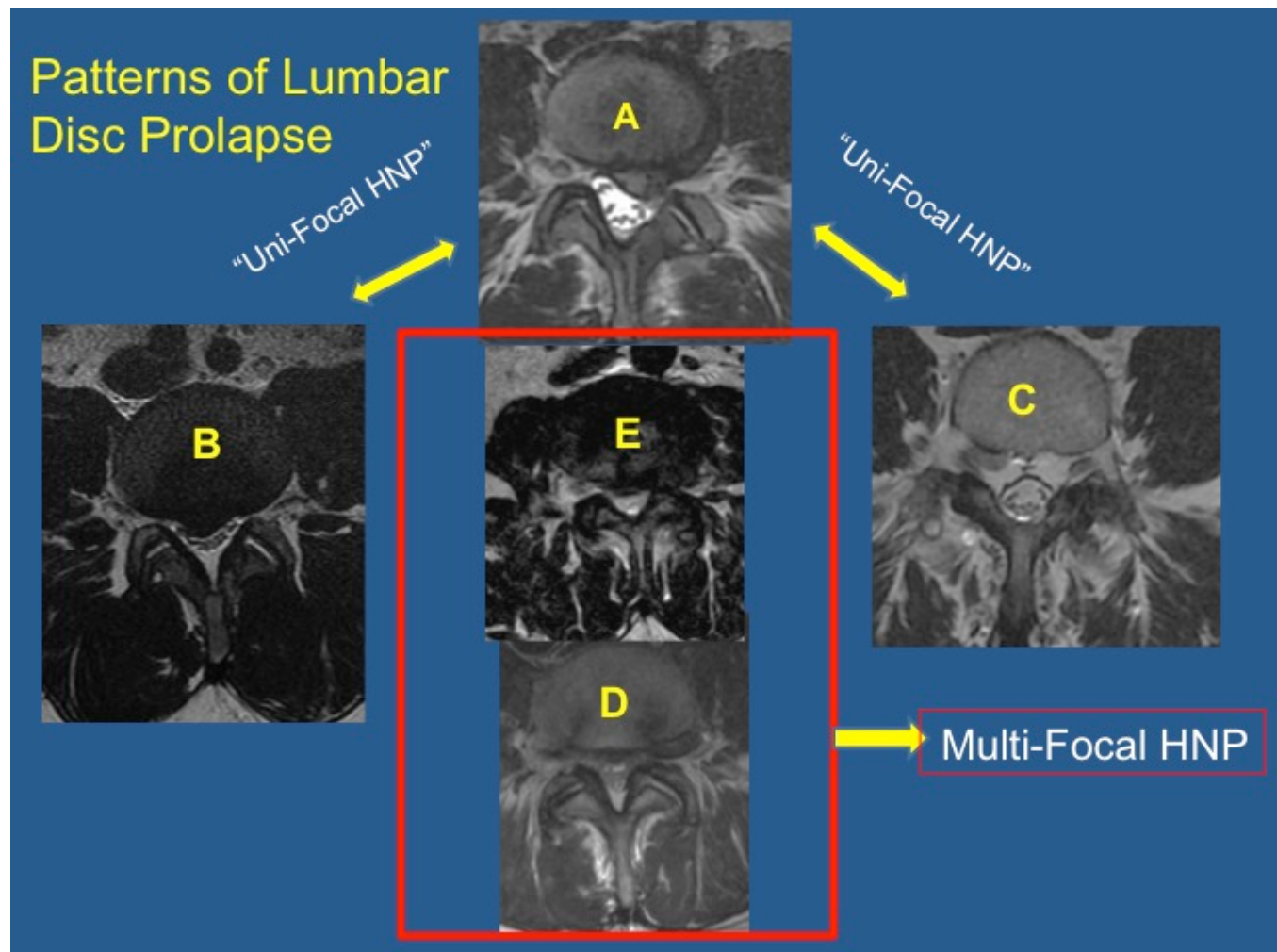
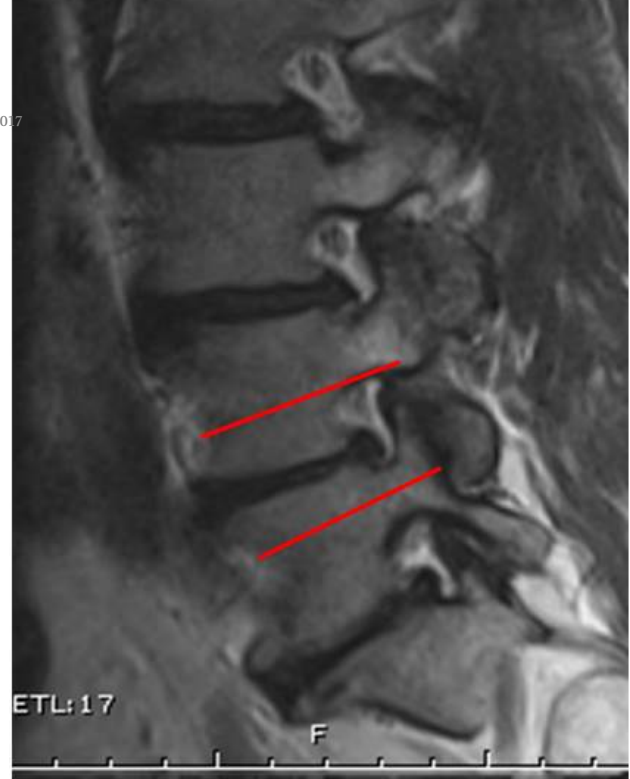

Fig. 4.

The last region where a lumbar herniation can occur is in the lateral aspect of the annulus. A disc bulge that occurs at the 9:30 or 3:30 o'clock position can compress the exiting nerve root in the far lateral zone of the disc. This type of herniation may also be broad based and effect both the traversing nerve root as well as the exiting root. The herniation can be far lateral and/or subarticular. A subarticular bulge can compress the exiting nerve root if the bulge has migrated proximally (Figure 6). The far lateral disc can compress the exiting dorsal root ganglion/nerve root. Although the subarticular and far lateral type of disc herniation is in close proximity to the exiting nerve root, this type of herniation can be approached with endoscopic techniques.<sup>16,17</sup> If a lateral foraminal approach is considered for the L5/S1 level, an intra discal approach under local anesthesia with intra venous sedation may be considered in order to decrease the risk of L5 nerve root injury. The L5/S1 level may or may not be accessible through a lateral transforaminal approach due to the presence of the iliac wing and enlarged superior articular S1 facet. In moderate to advanced cases of spondylosis at any level, an enlarged or superiorly positioned superior articular facet may block placement of the cannula and endoscope.

#### Special Considerations for Intra-foraminal approaches

Apart from the aforementioned limitations relative to disc fragment location, a number of other anatomical impediments exist which always need to be assessed during the pre-operative decision making process. 1.

Fig. 5.

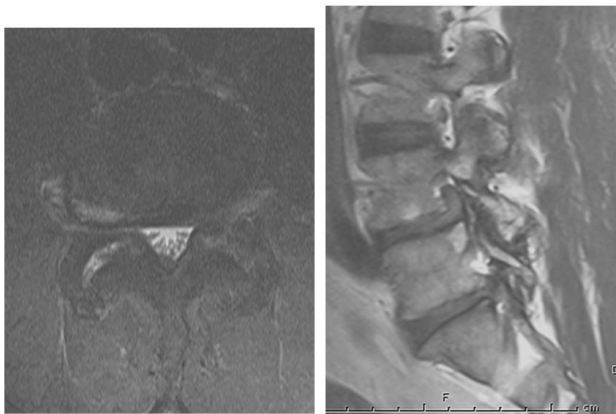


Fig. 6.

The superior aspect of the iliac wing should not be more proximal than the middle of the superior pedicle above the index lumbar disc space on a lateral lumbar radiograph. 2. The herniated fragment cannot extend past the middle of the inferior pedicle or past the inferior margin of the superior pedicle. 3. The farther lateral/anterior from the midline that the skin entry point is placed, the more important the surgeon must be aware of the position of the retroperitoneal space. This contra-indication to a direct lateral endoscopic approach becomes more evident above the L4-5 spinal level. If any question of peritoneal location is present, the surgeon should request a wide field MRI or CT scan through the spinal segment of interest preferably in the prone position (Figure 7). 4. The presence of a segmentation anomaly(ies) is also a relative contra-indication to inter-laminar endoscopic spine surgery techniques. A postero-lateral discectomy may be possible depending iliac wing anatomy and disc location in the presence of segmentation anomalies.

#### Lumbar: Inter-laminar and Posterior Approaches

An alternate approach to the L5-S1 segment is the posterior inter-laminar approach for a postero-lateral disc herniation or a direct posterior approach for a far lateral disc herniation. The inter-laminar approach should be performed after careful assessment of the inter-laminar space using plane radiographs and/or computed technology. The inter-laminar approach is begun medially and the surgical dissection is progressed in a lateral direction. The endoscopic cannula is used to retract the traversing S1 nerve root.

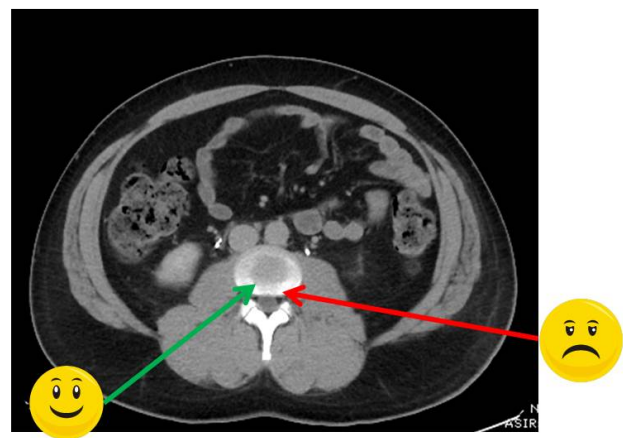


Fig. 7.

Direct posterior endoscopic approaches can also be utilized for posterior central and lateral recess stenosis. Expertise in endoscopic burr techniques is necessary to efficiently and effectively be able to perform an endoscopic posterior lumbar decompression for spinal stenosis.

### Cervical

Similar to lumbar anatomic considerations, understanding relevant functional cervical anatomy is also required to appropriately perform cervical endoscopic spine surgery. The two approaches that are possible with endoscopic techniques are a direct posterior approach to the lamino-foraminal region and an anterior approach to the cervical spine interspace. The posterior approach is utilized to decompress the cervical foramen with or without cervical discectomy. Both radiographic and tactile anatomical landmarks are simultaneously utilized to perform the approach to the medial edge of the facet complex. The anterior approach to the cervical interspace utilizes the same anatomical intervals as that utilized in traditional anterior cervical decompression procedures. Limited evidence based data is available concerning the anterior cervical approach to the disc space. The anterior approach has been reported to be used for unilateral anterior cervical decompression of paracentral/foraminal disc herniations.<sup>2</sup>

## Indications and Evaluation:

### Lumbar

The indications for lumbar endoscopic surgery continue to evolve. The most common indication for endoscopic lumbar surgery is lumbar paracentral disc prolapse either contained or uncontained from L1-S1 with increased prevalence at the L3-4, L4-5, and L5-S1 levels. Central, sub-articular, and far lateral herniations can also be treated very effectively with appropriate experience and training.<sup>16-18</sup> Other pathologies such as symptomatic annular tears with interposed nucleus pulposus, medial branch rhizotomy, infectious discitis decompression/evacuation and Interbody fusion.<sup>19,20</sup> The treatment of ligamentous and/or bony spinal stenosis both central as well as foraminal/subarticular is also currently being evaluated.

All potential candidates should be evaluated with standing AP, lateral, and flexion/extension plain radiographs, magnetic resonance imaging and if any potential disc calcification is suspected a computed tomography scan should be performed.

## Lumbar Surgical Operative Techniques: Intra-foraminal

### Procedure

The patient is positioned in the prone position on a well cushioned and supportive radiolucent frame or gel rolls. In most cases, local anesthesia with IV sedation can be utilized. If general anesthetic is to be used, spinal cord monitoring as well as tactile posterior thigh palpation should be utilized to assess for nerve root impingement by operative intervention.

Two intra-foraminal approaches (intra-discal and extra-discal) are commonly used (Figure 8) When an intra-foraminal extra-discal approach is utilized, three skin markings should be drawn using fluoroscopic imaging.<sup>21</sup> First, in the true AP fluoroscopic view a linear midline marking is made on the patient's skin. Second, on a true orthogonal lateral view, the disc space is marked. The third line to be drawn is the posterior facet line which is also drawn in the lateral fluoroscopic view. The skin entry needle point (#1) for the spinal needle should be no more posterior than the posterior facet line at the intersection of the lateral line and the posterior facet line (Figure 9). The more intra-foraminal position of the scope that is needed, the closer to the posterior facet line the entry point should be for the spinal needle entry. An 18 gauge spinal needle is then positioned on the posterior edge (lateral view) of the disc space and no further medial than the medial pedicle line (AP view) (Figure 10).

When an intra-foraminal intra-discal approach as described by is planned, the same three skin markings are made as in an extra-discal approach and an additional fourth skin marking is made as described by Yeung in his early surgical technique (Figure 11)<sup>22</sup>. The line is determined by positioning the tip of the metal marker in the center of the disc space on the lateral orthogonal view and then making a mark on

the metal marker at approximately where the posteri-

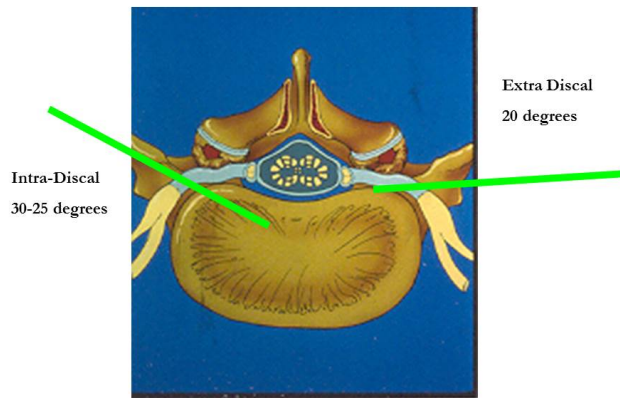


Fig. 8.

or skin arches anterior. That distance is then marked from the midline skin marking and the skin entry point is marked. The spinal needle is then placed in the posterior  $\frac{1}{4}$  of the disc space (lateral view) and in the central disc (AP view). After needle placement is confirmed, a mixture 2ml of indigo carmine and 8 ml of omnipaque is injected as necessary to perform discography and to stain degenerative nucleus material (Figure 12 and Video 1). For multi focal disc herniations, a needle entry point between the intra and extra discal skin entry points and has a distal to proximal inclination is usually preferred. The intra discal discectomy should be performed first followed by extra-foraminal decompression (Video 2).

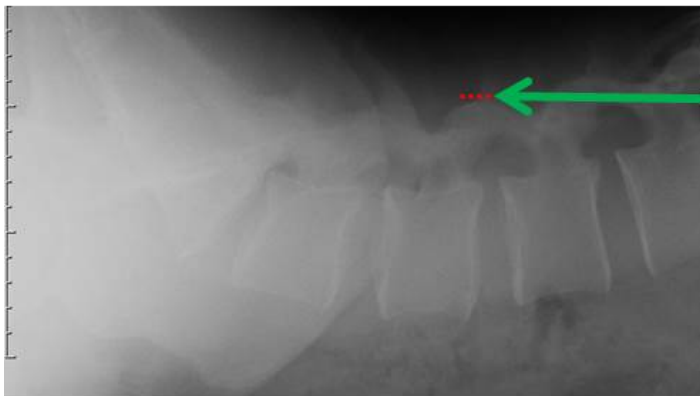
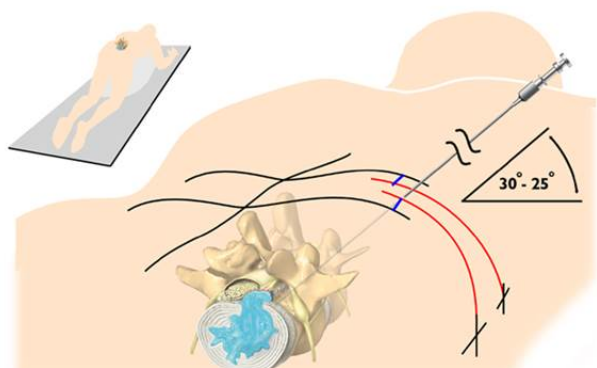
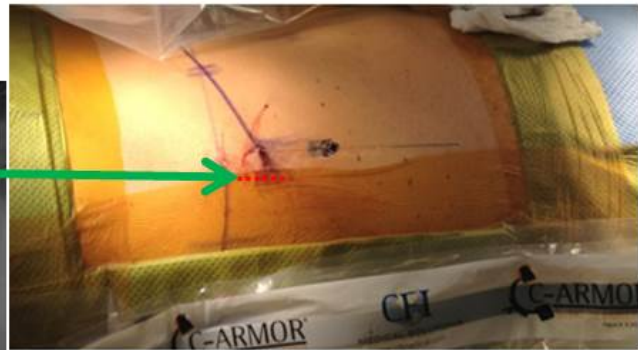


Fig. 9.



**Needle is inserted at entry point toward the target disc at an angle 30 - 25 degrees to the surface skin plane. This trajectory will determine the path of all subsequent instrumentation.**

Courtesy of A. Yeung

Fig. 10.



After spinal needle placement is confirmed, in either the intra or extra discal technique, a 1 mm guide wire is placed through the spinal needle. A 2 hole obturator is then placed over the guide wire followed by working cannula placement (7 mm or 8 mm). Lastly, the endoscope is placed into the working cannula. Appropriate discectomy and post-decompression confirmation of epidural pulsation is performed. Evidence of epidural pulsation confirms spinal content decompression. In most instances, direct visualization of the traversing nerve root is not always necessary to confirm decompression. Withdrawing the working cannula and endoscope into an extra discal position will permit visualization of the exiting nerve root (Figure 13, Video 3). The judicious use of bipolar coagulation, endoscopic burrs, and focused lasers allow for discectomy as well foraminoplasty and in-

tervertebral fusion using expandable cage technology.

## Lumbar Surgical Technique: Inter-Laminar

The posterior inter-laminar approach is utilized predominantly at the L5-S1 level to perform paracentral discectomies. An AP view of the L5-S1 level is performed and a skin marking is made. A second line is made just lateral to the midline. At this intersection a small 4 mm incision is performed and a two hole obturator is placed down to the level of the ligamentum flavum (LF). The working cannula and endoscope is then placed. Note a guide wire is not utilized. Careful dissection through the LF is then performed. The lateral edge of the S1 nerve root is identified by performing a partial facetectomy as needed. The working cannula is then rotated and the S1 nerve is gently retracted. Discectomy can then be performed.

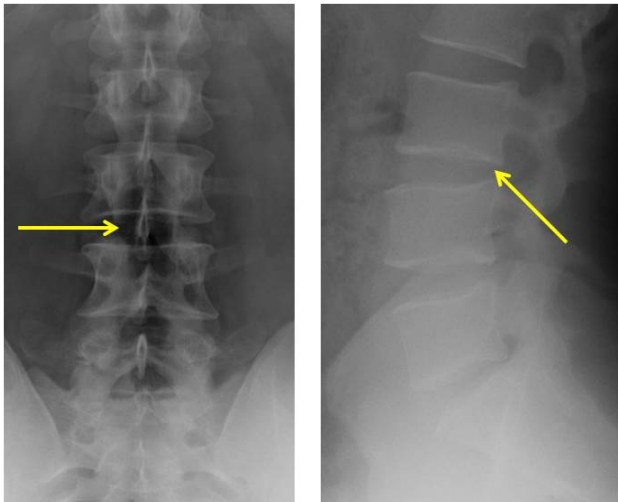


Fig. 11.

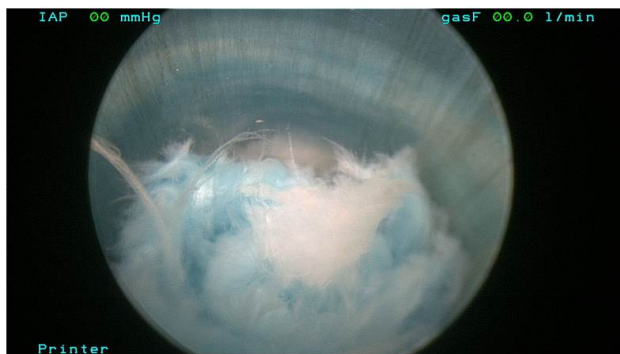

Fig. 12.

## Learning Curve, Complications

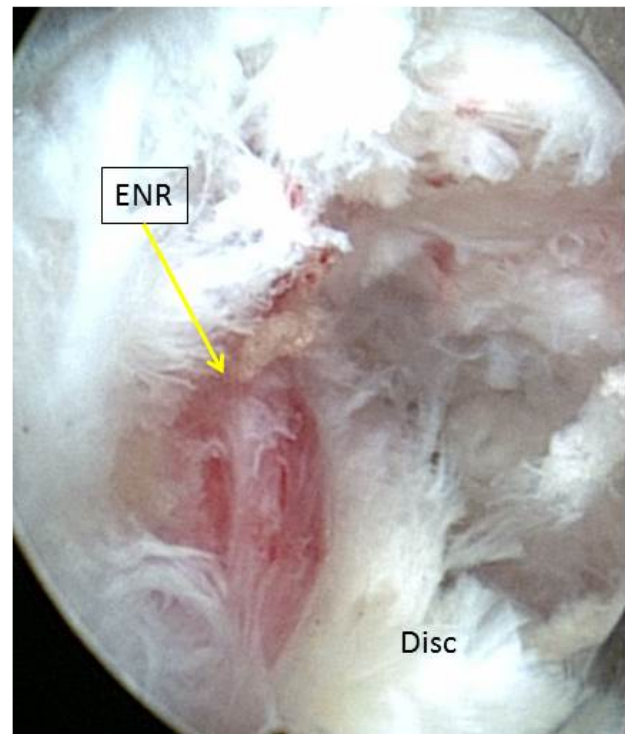


Fig. 13.

## and Post-Operative Care

The learning curve for endoscopic techniques is dependent on several factors. A complete understanding of the surgical anatomy must be thoroughly reviewed. The spinal anatomy as well as associated surgical approach anatomy should be reviewed. A fundamental mastery of open and associated minimally invasive techniques is required. The surgeon should participate in multiple cadaveric sessions during which the major components of the surgical technique are underscored and performed. Lastly, the surgeon should consider attending preceptor cases for additional training purposes. A logical progression for integrating endoscopic techniques into a surgeon's practice is to first perform lumbar transforaminal techniques followed by lumbar inter-laminar and then posterior and/or anterior cervical techniques.

Potential complications include nerve root injury, durotomy, infection, retro-peritoneal cavity injury, cauda equine injury, great vessel injury, muscular hematoma, re-herniation, piriformis syndrome, and/or epidural hematoma.<sup>23-28</sup> Post-operative care includes appropriate wound care and activity limitations. No brace wear is routinely indicated.

## Discussion

In the early 1960s, Lyman Smith injected chymopain into a herniated lumbar disc using what was later to be termed "the safe zone" by Kambin and thus began the era of minimally invasive spine surgery.<sup>29</sup> The first meeting of the International Society for Minimal Intervention of Spine Surgery in April 1990 further defined the term *minimally invasive spine surgery* against the back drop of the additional advances that had been made in endoscopic spine surgery techniques and approaches.

Endoscopic spinal surgery clinical outcomes have been studied for the past 25 years. These outcomes have included prospective randomized clinical trials evaluating the effectiveness of endoscopic techniques versus open posterior microdiscectomy techniques in the treatment of primary and revision lumbar disc herniations.<sup>1,30-34</sup> These trials have revealed equivalency in outcomes amongst the two treatment

groups. Recent non-randomized lumbar studies include a single surgeon evaluation of 400 patients using the translaminar approach for lumbar disc herniations, a study of 300 central and foraminal degenerative spinal stenosis who underwent posterior endoscopic decompression,<sup>4</sup> 50 geriatric patients aged 75 years and older who underwent transforaminal foraminal decompression, and a review of 611 patients and associated complications.<sup>4,25,35</sup> Additional studies include the use of endoscopic techniques in the treatment of spinal infections, thoracic as well as cervical disc herniations<sup>3,5,20</sup>

Recent articles have also explored more advanced indications for endoscopic surgical techniques including single level multi-focal disc excision and foraminal decompression for primary foraminal stenosis as well as failed back syndrome.<sup>17,19</sup> Yeung has described using lumbar foraminal endoscopic approaches which can be utilized to treat enlarged and compressive superior articular facet processes using both mechanical (powered burrs, trephines) and laser technology to perform facet decompression without fusion. Yue et al have described using a combined intradiscal and extra discal approach to treating multi-focal disc herniations causing both central and lateral neurogenic and radicular symptoms.

Although the indications for endoscopic techniques are continuing to evolve, there are limitations of the technology. These include the use of foraminal techniques to treat distally or proximally migrated disc fragments which may be better treated with traditional open micro discectomy methods or more advanced interlaminar endoscopic techniques. Circumferential spinal stenosis as a result of concomitant congenital and acquired stenosis may also be better treated with open decompressive techniques especially if present at multiple levels. Lastly, in those cases where a cauda equine syndrome may be evident or impending, the use of open techniques may be also indicated.

## Conclusion

The treatment of spinal disorders continues to evolve and develop in parallel to technological advances. Improved endoscopic optics and instrumentation

have enabled enhanced visualization of spinal anatomy using an ultra-minimally invasive approach with the least amount of approach related trauma. Careful patient selection considering both location and type of disc pathology as well as approach related limitations (position of iliac wing and retroperitoneal contents) is mandatory to achieve optimal outcomes. A superior understanding of the lumbar neuroforaminal anatomy as well as MRI interpretation with regards to disc pathology is also an essential component of achieving operative success. Central, paracentral, foraminal and far lateral lumbar disc herniations can be treated using endoscopic techniques. Recent endoscopic systems also permit for posterior inter laminar lumbar decompression, anterior and posterior cervical and posterior lateral thoracic decompression. Lastly, the learning curve involved in learning endoscopic techniques can be improved upon through careful cadaveric training as well as surgical mentorship.

## References

- Ruetten S, Komp M, Merk H, Godolias G. Full-endoscopic interlaminar and transforaminal lumbar discectomy versus conventional microsurgical technique: a prospective, randomized, controlled study. *Spine* 2008;33:931-939.
- Hellinger S. The fullendoscopic anterior cervical fusion: a new horizon for selective percutaneous endoscopic cervical decompression. *Acta neurochirurgica Supplement* 2011;108:203-207.
- Deukmedjian AJ, Cianciabella A, Cutright J, Deukmedjian A. Cervical Deuk Laser Disc Repair((R)): A novel, full-endoscopic surgical technique for the treatment of symptomatic cervical disc disease. *Surgical neurology international* 2012;3:142.
- Minamide A, Yoshida M, Yamada H, Nakagawa Y, Kawai M, Maio K, Hashizume H, Iwasaki H, Tsutsui S. Endoscope-assisted spinal decompression surgery for lumbar spinal stenosis. *Journal of neurosurgery Spine* 2013;19:664-671.
- Nie HF, Liu KX. Endoscopic transforaminal thoracic foraminotomy and discectomy for the treatment of thoracic disc herniation. *Minimally invasive surgery* 2013;2013:264105.
- Ruetten S, Komp M, Merk H, Godolias G. A new full-endoscopic technique for cervical posterior foraminotomy in the treatment of lateral disc herniations using 6.9-mm endoscopes: prospective 2-year results of 87 patients. *Minimally invasive neurosurgery: MIN* 2007;50:219-226.
- Hult, L. Retroperitoneal disc fenestration in low back pain and sciatica: A preliminary report. *Acta Orthop Scand* 1950-51;20:342-348.
- Hijikata S YM, Nakayama T, et al. Percutaneous nucleotomy: a new treatment method for lumbar disc herniation. *J Toden Hosp* 1975;5:39.
- Kambin P GH. Percutaneous lateral discectomy of the lumbar spine: a preliminary report. *Clin Orthop* 1983;174:127-132.
- Hausmann B, Forst R. Nucleoscope. Instrumentarium for endoscopy of the intervertebral disc space. *Archives of orthopaedic and trauma surgery* 1983;102:57-59.
- Kambin, P. Percutaneous lumbar discectomy (Triangular Working Zone): Current practice. *Surgical Rounds in Orthopaedics* 1988:31-35.
- Kambin P. Arthroscopic microdiscectomy. *The Mount Sinai journal of medicine, New York* 1991;58:159-164.
- Yeung AT. Minimally Invasive Disc Surgery with the Yeung Endoscopic Spine System (YESS). *Surgical technology international* 1999;8:267-277.
- Ruetten S. Full-endoscopic Operations of the Spine in Disk Herniations and Spinal Stenosis. *Surgical technology international* 2011;XXI:284-298.
- Hasegawa T AH, Haughton VM, Nowicki, B. Lumbar Foraminal Stenosis: Critical Heights of the Intervertebral Disc and Foramina: A Cryomicrotome Study in Cadavera. *JBJS* 1995;77-A:32-38.
- Kitagawa Y, Sairyo K, Shibuya I, Kitahama Y, Kanamori Y, Koga S, Matsumoto H, Sumita T, Yamada A, Dezawa A. Minimally invasive and simultaneous removal of herniated intracanal and extracanal lumbar nucleus pulposus with a percutaneous spinal endoscope. *Asian journal of endoscopic surgery* 2012;5:183-186.
- Yue JJ HX, Scott D, Jacob A. The Treatment of Single Level Multi-Focal Subarticular and Paracentral and/or Far Lateral Lumbar Disc Herniations: The Single Incision Multi Focal Endoscopic Surgery Approach. *IJSS*, 2014.
- Lubbers T, Abuamona R, Elsharkawy AE. Per-

- cutaneous endoscopic treatment of foraminal and extraforaminal disc herniation at the L5-S1 level. *Acta neurochirurgica* 2012;154:1789-1795.
19. Yeung AT, Gore S. In-vivo Endoscopic Visualization of Patho-anatomy in Symptomatic Degenerative Conditions of the Lumbar Spine II: Intradiscal, Foraminal, and Central Canal Decompression. *Surgical technology international* 2011;XXI:299-319.
  20. Yang SC, Chen WJ, Chen HS, Kao YH, Yu SW, Tu YK. Extended indications of percutaneous endoscopic lavage and drainage for the treatment of lumbar infectious spondylitis. *European spine journal : official publication of the European Spine Society, the European Spinal Deformity Society, and the European Section of the Cervical Spine Research Society* 2014.
  21. Ruetten S, Komp M, Merk H, Godolias G. Use of newly developed instruments and endoscopes: full-endoscopic resection of lumbar disc herniations via the interlaminar and lateral transforaminal approach. *Journal of neurosurgery Spine* 2007;6:521-530.
  22. Yeung AT. The evolution of percutaneous spinal endoscopy and discectomy: state of the art. *The Mount Sinai journal of medicine, New York* 2000;67:327-332.
  23. Sairyo K, Sakai T, Higashino K, Inoue M, Yasui N, Dezawa A. Complications of endoscopic lumbar decompression surgery. *Minimally invasive neurosurgery : MIN* 2010;53:175-178.
  24. Kim JE, Kim KH. Piriformis syndrome after percutaneous endoscopic lumbar discectomy via the posterolateral approach. *European spine journal : official publication of the European Spine Society, the European Spinal Deformity Society, and the European Section of the Cervical Spine Research Society* 2011;20:1663-1668.
  25. Kaushal M, Sen R. Posterior endoscopic discectomy: Results in 300 patients. *Indian journal of orthopaedics* 2012;46:81-85.
  26. Martin-Laez R, Martinez-Agueros JA, Suarez-Fernandez D, Montiaga-Nunez F, Vazquez-Barquero A. Complications of endoscopic microdiscectomy using the EASYGO! system: is there any difference with conventional discectomy during the learning-curve period? *Acta neurochirurgica* 2012;154:1023-1032.
  27. Ebata S, Sato H, Orii H, Sasaki S, Ohba T, Haro H. Risk management in posterior spinal endoscopic surgery in lumbar diseases. *Journal of orthopaedic science : official journal of the Japanese Orthopaedic Association* 2013;18:369-373.
  28. Hsu HT, Chang SJ, Yang SS, Chai CL. Learning curve of full-endoscopic lumbar discectomy. *European spine journal : official publication of the European Spine Society, the European Spinal Deformity Society, and the European Section of the Cervical Spine Research Society* 2013;22:727-733.
  29. Smith L GP, Gesler RM, Jennings RB. Enzyme dissolution of the nucleus pulposus. *Nature* 1963;198:1311-1312.
  30. Kambin P, Cohen LF. Arthroscopic microdiscectomy versus nucleotomy techniques. *Clin Sports Med* 1993;12:587-598.
  31. Hermantin FU, Peters T, Quartararo L, Kambin P. A prospective, randomized study comparing the results of open discectomy with those of video-assisted arthroscopic microdiscectomy. *The Journal of bone and joint surgery American volume* 1999;81:958-965.
  32. Hoogland T, van den Brekel-Dijkstra K, Schubert M, Miklitz B. Endoscopic transforaminal discectomy for recurrent lumbar disc herniation: a prospective, cohort evaluation of 262 consecutive cases. *Spine* 2008;33:973-978.
  33. Ruetten S, Komp M, Merk H, Godolias G. Full-endoscopic interlaminar and transforaminal lumbar discectomy versus conventional microsurgical technique: a prospective, randomized, controlled study. *Spine* 2008;33:931-939.
  34. Ruetten S, Komp M, Merk H, Godolias G. Recurrent lumbar disc herniation after conventional discectomy: a prospective, randomized study comparing full-endoscopic interlaminar and transforaminal versus microsurgical revision. *Journal of spinal disorders & techniques* 2009;22:122-129.
  35. Jasper GP, Francisco GM, Telfeian AE. A retrospective evaluation of the clinical success of transforaminal endoscopic discectomy with foraminotomy in geriatric patients. *Pain physician* 2013;16:225-229.

Published 20 May 2015.

This manuscript is generously published free of charge by ISASS, the International Society for the Advancement of Spine Surgery. Copyright © 2015 ISASS. To see more or order reprints or permissions, see <http://ijssurgery.com>.