

## Posterior Grade 4 Osteotomy With Vertebral Shortening Is Effective for the Treatment of Kyphosis Associated With Vertebral Discitis/Osteomyelitis

Barón Zárate-Kalfópulos, Luis Alberto Navarro-Aceves, Hugo Reynoso-Cantú, Alejandro Reyes-Sánchez, Carla Lissette García-Ramos, Fernando Reyes-Tarragó and Armando Alpizar-Aguirre

*Int J Spine Surg* published online 25 June 2020  
<https://www.ijssurgery.com/content/early/2020/06/17/7040>

This information is current as of June 2, 2025.

---

**Email Alerts** Receive free email-alerts when new articles cite this article. Sign up at:  
<http://ijssurgery.com/alerts>

# Posterior Grade 4 Osteotomy With Vertebral Shortening Is Effective for the Treatment of Kyphosis Associated With Vertebral Discitis/Osteomyelitis

BARÓN ZÁRATE-KALFÓPULOS, MD, LUIS ALBERTO NAVARRO-ACEVES, MD, HUGO REYNOSO-CANTÚ, MD, ALEJANDRO REYES-SÁNCHEZ, PhD, CARLA LISSETTE GARCÍA-RAMOS, MD, FERNANDO REYES-TARRAGÓ, MD, ARMANDO ALPÍZAR-AGUIRRE, MD

*Spine Surgery Service, National Institute of Rehabilitation, Mexico City, Mexico*

## ABSTRACT

**Background:** In the retrospective study of a prospectively maintained database, we present a case series of patients with kyphotic deformity secondary to spinal infection treated using a posterior-only approach with 3-column shortening and posterior instrumentation.

**Methods:** This is a case series of patients presenting with postural deformity and sagittal imbalance treated consecutively by 1 surgeon between 2012 and 2014. Clinical assessments and radiographic evaluations were made preoperatively and at 12- and 24-month postoperative follow-ups. All patients underwent computed tomography 24 months after surgery to evaluate spinal fusion.

**Results:** The study included 5 patients with a mean age of 50 years (range, 32–60 years). Three patients had comorbidities. Three patients were classified as American Spinal Injury Association (ASIA) grade C and were not ambulatory; 2 were ASIA grade D. At follow-up, all patients were ambulatory and classified as ASIA grade E. Kyphosis was corrected from a preoperative mean of 32° (range, 15°–58°) to 10° (range, 1°–42°) at the 2-year follow-up. A mean improvement of 22° and 75% reduction in kyphosis was obtained with fixation 2 levels above and below the lesion. Interbody fusion was observed in all patients. No major complications occurred during surgery.

**Conclusions:** Posterior grade 4 osteotomy with vertebral shortening can be performed safely in patients with kyphosis associated with vertebral discitis/osteomyelitis in the thoracolumbar region. The single approach allowed the surgeon to debride the infection, correct the kyphosis, decompress the spinal canal, and stabilize the spine.

**Level of Evidence:** 4

Lumbar Spine

Keywords: spinal osteotomy, spondylodiscitis, kyphosis

## INTRODUCTION

Bacterial spinal infection can involve the intervertebral disc, bone, and/or epidural space. The incidence of vertebral osteomyelitis is estimated to be 2.2 per 100 000 persons.<sup>1</sup> Spinal infection can result in instability and deformity requiring surgical stabilization. In a retrospective cohort study of 48 patients with bacterial spinal infections, Srinivasan et al<sup>2</sup> found that 44% (21 patients) developed spinal deformities: 14 had kyphosis, 5 had spondylolisthesis, and 2 had kyphosis and spondylolisthesis.

Various surgical approaches have been developed to preserve or improve neurological function, control and drain the infection, relieve pain, correct deformity, and maintain stability. These approaches include anterior decompression and fusion, posteri-

or decompression and fusion, and anterior decompression combined with anterior and posterior fusion. Several spinal osteotomy techniques have been developed to treat kyphosis. In 2014, Schwab et al<sup>3</sup> proposed a classification system based on anatomical grades of resection, in which a grade 4 osteotomy included resection of the vertebral body, posterior elements, and the pedicles, as well as resection of 1 portion of the end plate with the adjacent intervertebral disc.

Thus, grade 4 osteotomy has been used to treat spinal infections. In a retrospective study of 5 patients, Halpern et al<sup>4</sup> found that a 3-column shortening osteotomy corrected the kyphosis angle from 36° to 4°, with no major complications reported during surgery. The authors concluded that 3-column shortening osteotomy is a safe and

effective to treatment option for patients with spinal infections associated with kyphosis.

Herein, we present a case series of patients with kyphotic deformity secondary to infection in the spine treated using a single posterior approach with 3-column vertebral shortening and posterior instrumentation.

## MATERIALS AND METHODS

A retrospective case series of clinical and radiographic data was undertaken of 5 patients undergoing posterior grade 4 osteotomy with vertebral shortening. All patients had a previous diagnosis of discitis/osteomyelitis and received medical treatment with antibiotics; however, they evolved with radiographic kyphosis and symptoms attributable to postural deformity that compromised activities of daily living, forcing them to lean forward, and caused rapid fatigue or intractable pain. Patients who underwent surgery between January 2010 and January 2015 were included in the study.

### Surgical Technique

The procedure was performed under general endotracheal anesthesia. Each patient was placed in the prone position on the operating table. The posterior elements were exposed and pedicle screws were inserted 2 levels above and 2 levels below the osteotomy site.

A complete laminectomy and facetectomy were performed. Central decompression is critical to minimize dural impingement and buckling during closure. First, the posterior portion of both pedicles was removed, and then a curette was inserted into the vertebral body through a preparatory hole to remove cancellous bone. The whole pedicle and superior residual disc were removed, and temporal unilateral fixation with rods was used to prevent collapse. The posterior wall of the vertebral body was resected from posterior to anterior using a specialized impactor. The osteotomy was completed by resecting the proximal third of the vertebral body, the superior residual disc, and the cartilage from the distal platform of the superior vertebral body with a curette. The lower portion of the pedicle was left intact to prevent injury to the exiting nerve root.

The osteotomy gap was closed using a combination of correction maneuvers, including rod bending, manual reduction, and compression clamps placed

between pedicle screws. A cross-link was used at the level of osteotomy to improve fixation stability.

Fluoroscopy was used view the kyphosis correction and to confirm bone-to-bone contact. After closing the osteotomy, the posterior elements were reexamined to ensure that the exiting nerve roots were not compressed. Local bone harvested from the posterior spinal elements mixed with a demineralized bone matrix was used to enhance posterolateral fusion (Figure 1).

### Outcome Assessment and Follow-Up

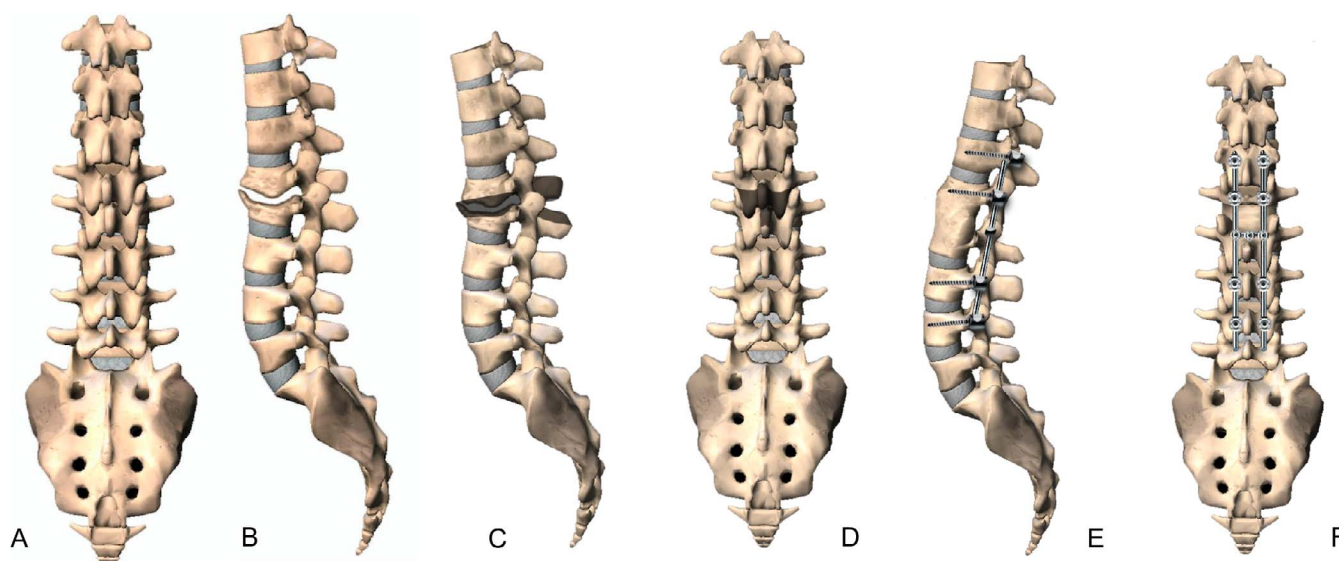
Operative data, including operation time, amount of blood loss, and complications, were collected. The Oswestry Disability Index (ODI), Short Form 36 (SF-36) scale, Roland Morris Disability Questionnaire (RMDQ), and visual analog scale (VAS) were administered preoperatively and postoperatively to assess lumbar pain.

Radiographic measurements were made on standing anteroposterior and lateral radiographs of the whole spine. The x-rays were standardized by full extension of the hips and knees and by gentle placement of both fists on the clavicles with elbow flexion.

Radiographic data were measured as follows: *sagittal vertical axis*, identified by a plumb line dropped from C7 to the sacral end plate; *C7 plumb line*, a vertical line drawn from the vertebral body of C7, which should normally intersect the superior endplate of S1; *focal kyphosis*, the angle between the superior and inferior endplates of the vertebral bodies above and below the level of the injury; *pelvic incidence*, the angle subtended by the perpendicular to the sacral plate at its midpoint and a line from the midpoint of the sacral plate to the center of the femoral head; *pelvic tilt*, the angle between a vertical line originating at the center of the femoral head and a line starting from the center of the femoral head to the midpoint of the endplate of S1; and *sacral slope*, the angle between the superior endplate of S1 and a horizontal axis.

The *deformity correction angle* was defined as the difference between the preoperative and postoperative angles of the superior endplate at the level above the osteotomy.

The *correction angle* was measured at the final follow-up to determine the loss of correction. All patients underwent a control computed tomography (CT) scan to assess spinal fusion. *Complete fusion* was defined as bone continuity at the level of the



**Figure 1.** Digital image of discitis/osteomyelitis with kyphosis associated. (A) Anteroposterior (AP) view. (B) Lateral view. (C) Lateral view of the osteotomy site. (D) AP view of the osteotomy. (E) Lateral view after osteotomy and fixation. (F) AP view after osteotomy and fixation.

osteotomy. All radiographic and CT scans were assessed by 1 independent orthopedic spine surgeon with 11 years of experience and 1 independent neuroradiology specialist.

All statistical tests were conducted using SPSS software version 22.0 (IBM Corp, Armonk, NY). Baseline patient characteristics were expressed as means and standard deviations for continuous variables and as percentages for categorical variables. Comparisons between preoperative and 2-year follow-up clinical data were performed using paired *t* tests. *P* values < .05 were deemed to indicate statistical significance.

Agreement between the values of parameters measured on the x-rays was assessed and quantified using the intraclass correlation coefficient, in which less than .40 indicates poor agreement, .40 to .75 indicates fair-to-good agreement, and values greater than .75 indicate excellent agreement.

## RESULTS

Five patients (3 men and 2 women) with a mean age of 50.4 years (range, 32–60 years) were included in the study. Comorbidities were present in 3 patients: 1 patient had HIV and was receiving antiviral therapy, 1 had renal failure and was undergoing hemodialysis treatment, and 1 had a history of cocaine and alcohol abuse. The 5 patients had late diagnosis and treatment with an average of 21.6 weeks between diagnosis and surgical treatment (range, 20–24 weeks).

## Surgical Data

Grade 4 osteotomies with vertebral shortening were performed at L3 in 3 patients, at T11 in 1 patient, and at L2 in 1 patient.

The average duration of surgery was 354 minutes (range, 240–447 minutes), and mean blood loss was 980 mL (range, 400–1500 mL). No surgical complications were reported. One superficial wound infection was surgically debrided 2 weeks after surgery with adequate recovery (Table).

## Clinical Data

Lumbar pain, measured using a VAS, improved from a median of 7 (range, 5–8) to 2 (range, 1–3) at follow-up (*P* = .0001).

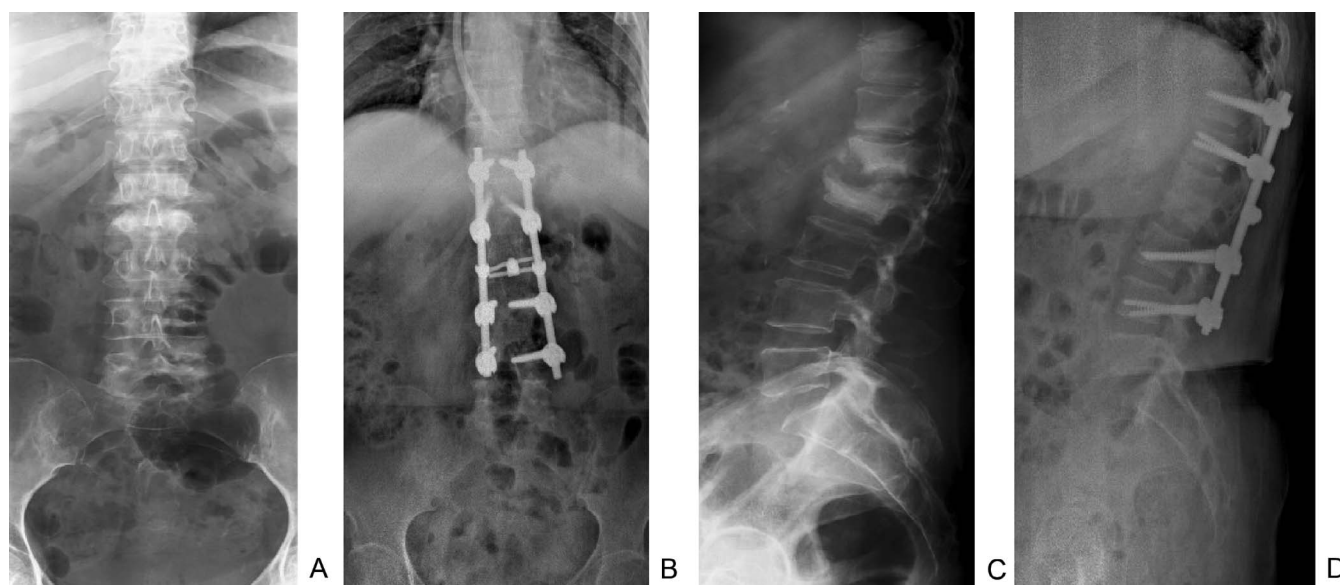
The etiology of the infection was *Mycobacterium tuberculosis* in 3 patients and *Staphylococcus aureus* in 2 patients. The 2 patients with bacterial infection had another organism isolated. All patients received preoperative antibiotic treatment managed by the infectious diseases department. The duration of therapy ranged from 6 weeks to 12 months. At 24 months postoperation, none had a recurrence of infection.

Preoperative functional disability, measured using the ODI, improved from 64% (range, 50%–86%) to 13% (range, 4%–22%; *P* = .0001). The mean preoperative RMDQ of 15 (range, 10–17) improved to 1.4 (range, 0–2) after surgery (*P* = .003).

**Table.** Patient, operative, postoperative, radiographic, and outcome data.

	Case				
	1	2	3	4	5
Patient Data					
Age, y/sex	43/M	59/F	58/F	32/M	60/F
Medical history	HIV	Type 2 diabetes, systemic hypertension, chronic renal failure, hemodialysis	Septic shock secondary to urinary tract infection, complicated by infection by influenza with respiratory sepsis and acute respiratory failure, hospital acquired pneumonia, type 2 diabetes, hypothyroidism	Substance use (crack/cocaine, alcohol, marijuana and tobacco)	Chronic obstructive pulmonary disease, tobacco
Etiology	TB ( <i>Mycobacterium tuberculosis</i> )	Bacterial ( <i>Staphylococcus aureus</i> + <i>Escherichia coli</i> )	Bacterial polymicrobial ( <i>Staphylococcus aureus</i> + <i>Acinetobacter lwoffii</i> )	TB, Bacterial ( <i>Mycobacterium tuberculosis</i> + <i>Acinetobacter lwoffii</i> )	TB ( <i>Mycobacterium tuberculosis</i> )
Preop inpatient stay, d	1	1	1	1	7
Operative data					
Levels involved	L2/L3	L2/L3	L3/L4	T11/T12	L1/L2
UIV/LIV	T12-L1/L4-L5	T11-T12/L3-L4	L1-L2/L4-L5	T9-T10/L1-L2	T11-T12/L3-L4
No. levels fused	6	6	5	6	6
Estimates blood loss, mL	1100	1500	400	1000	900
Operative time, h	7.5	7	5.5	6	4
Postoperative data					
Follow-up time, mo	57	59	37	36	32
Postop hospital stay, d	4	5	4	5	5
Complications		Surgical site infection (2 weeks postop)			
Radiographic data					
Preop focal kyphosis, °	8	13	11	50	25
Postop focal kyphosis, °	26	8	20	32	6
Correction, °	18	5	9	18	19
Preop sagittal vertical axis (SVA), mm	43	84	155	-13	96
Postop SVA, mm	23	12	30	26	10
Correction, mm	20	72	120	39	86
Preop pelvic parameter, °					
PT	4	20	35	26	23
PI	46	55	50	55	35
SS	42	35	15	29	20
LL	39	42	7	78	31
PI-LL	7	13	42	23	4
LL-SS	3	7	8	49	11
Postop pelvic parameter,					
PT	15	24	26	24	13
PI	45	56	46	52	38
SS	30	31	22	27	25
LL	54	59	34	57	53
PI-LL	8	7	12	5	15
LL-SS	24	28	12	30	28
Correction, °					
PT	11	4	9	2	10
PI	1	1	4	3	3
SS	12	4	7	2	5
LL	15	17	27	21	22
PI-LL	1	9	30	18	11
LL-SS	21	21	4	19	17
Outcome analysis					
Preop walk status	Y	Y	Y	Y	Y
Postop walk status	Y	Y	Y	Y	Y
Preop ASIA	C	D	C	C	D
Postop ASIA	E	E	E	E	E
Postoperative					
VAS	2	1	2	2	1
RMDQ	2	2	1	2	2
ODI, %	22	17	4	10	15
SF-36 PCS	50.41	49.53	55.67	53.44	43.86
SF-36 MCS	50.53	51.62	62.75	56.58	64.71

Abbreviations: ASIA, American Spinal Injury Association; LIV, lowest instrumented vertebra; LL, lumbar lordosis; MCS, Mental Component Summary; N, no; ODI, Oswestry Disability Questionnaire; PCS, Physical Component Summary; PI, pelvic incidence; PT, pelvic tilt; RMDQ, Roland Morris Disability Questionnaire; SF-36, Short Form 36 scale; SS, sacral slope; TB, tuberculosis; UIV, upper instrumented vertebra; VAS, visual analog scale; Y, yes.



**Figure 2.** Illustrative case of a patient with kyphosis associated to discitis/osteomyelitis. (A) Preoperative anteroposterior (AP) view. (B) Postoperative AP view. (C) Preoperative lateral view. (D) Postoperative lateral view.

General health was measured using the SF-36 physical (PCS) and mental (MCS) component scores. The mean preoperative PCS was 26.4 (range, 18.9–36.3) and improved to 50.5 (range, 43.8–55.6;  $P = .0001$ ) after surgery, and the MCS improved from 44.6 (range, 33.5–59.6) to 57.2 (range, 50.5–64.7;  $P = .011$ ).

Three patients were ASIA grade C and not ambulatory, and 2 patients were ASIA grade D. At follow-up, all patients were ASIA grade E and ambulatory (Table).

### Radiographic Data

Sagittal balance improved from a mean of 78.7 mm (range, 13.6–155.5 mm) to a mean of 21.88 mm (range, 10.7–40.7 mm) at follow-up ( $P = 0.109$ ; Figure 1).

Segmental kyphosis improved from a preoperative mean of 32° to 10° at the 2-year follow-up, which was a mean improvement of 22° and a 75% reduction in kyphosis ( $P = .006$ ). Furthermore, bone consolidation was observed in all patients. The interobserver reliability was excellent for all parameters, and the overall intraclass correlation coefficient was .86, indicating excellent agreement. Representative cases are shown in Figures 2 and 3.

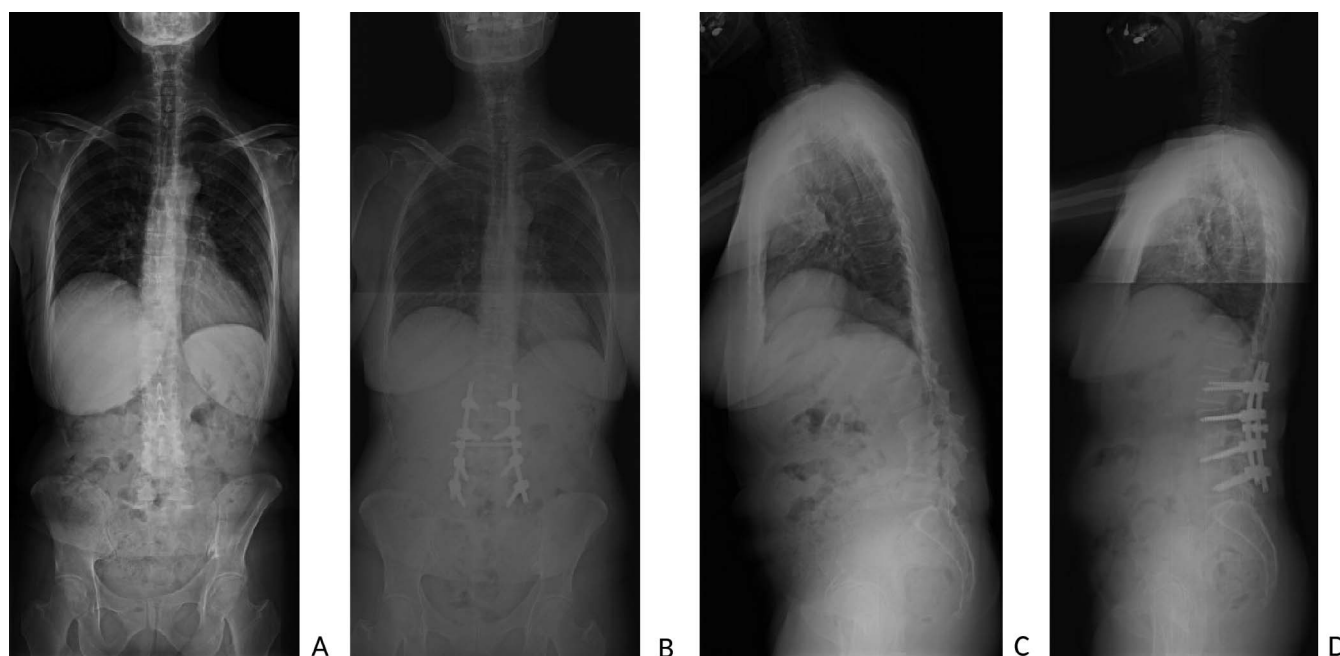
### DISCUSSION

Our findings suggest that a posterior grade 4 osteotomy with vertebral shortening is a safe and

effective treatment for kyphotic deformities associated with spinal infections. The posterior-only surgical approach is effective because the bone-on-bone contact provides anterior stability, eliminating the need for an anterior approach or instrumentation as well as associated morbidities.

The optimal surgical approach for the treatment of kyphosis associated with vertebral discitis/osteomyelitis is controversial. The anterior approach allows direct access to the pathology, adequate debridement, and decompression, and produces less muscle trauma, which allows the use of a larger graft.<sup>5</sup>

However, bone stability may be tenuous after anterior instrumentation due to concomitant osteoporosis associated with infection and because of a potentially large postdebridement defect. Rajasekaran et al<sup>6</sup> found graft failure due to slippage, fracture, absorption, or subsidence in 49 (59%) of 81 patients with large defects (more than 2 disc spaces). Furthermore, the anterior approach is associated with additional morbidity. A previous study<sup>7</sup> of 1233 patients with thoracic and lumbar spinal fusion found incidences of death (0.3%), paraplegia (0.2%), deep wound infection (0.6%), and an overall complication rate of 11.5% attributed directly to anterior spinal surgery. Other complications associated with the anterior approach, including vascular injury, pleural effusion, pneumothorax, decreased pulmonary function, postthoracotomy pain, abdominal hernia, and



**Figure 3.** Illustrative case of a patient with kyphosis associated to discitis/osteomyelitis. (A) Preoperative anteroposterior (AP) view. (B) Postoperative AP view. (C) Preoperative lateral view. (D) Postoperative lateral view.

impotence or retrograde ejaculation, have been reported in up to 36% of patients.<sup>7</sup> We found only 1 superficial wound infection in our series, which was surgically debrided. Combining the anterior and posterior approaches is more effective in preventing graft failure and instability than the anterior approach alone.

Blizzard et al<sup>8</sup> used extreme lateral interbody fusion (XLIF) with percutaneous posterior instrumentation to treat 11 patients with spondylodiscitis and reported that the pain and neurological symptoms improved in all patients. Furthermore, lordosis changed from 23° preoperatively to 34° postoperatively (mean change, 11°). At the final follow-up, inflammatory markers were normalized in all patients, no symptoms of infection were observed, and no patients required repeat surgical treatment for spondylodiscitis. Two patients subsequently developed adjacent-segment disease with junctional kyphosis; however, neither developed related symptoms.

The authors<sup>8</sup> concluded that XLIF with percutaneous posterior instrumentation was a minimally invasive technique with reduced morbidity for lumbar spine fusion. Moreover, they noted that the procedure afforded adequate exposure to the vertebral bodies and discs to allow aggressive debridement of the necrotic and infected tissue. The findings of Blizzard et al<sup>8</sup> suggested that XLIF

is a safe and effective alternative to anterior lumbar interbody fusion for the treatment of spondylodiscitis.

Other authors have studied the posterior approach. Lee et al<sup>9</sup> retrospectively compared the outcomes of transpedicular curettage and drainage with posterior stabilization with those of combined anterior-posterior stabilization. They found no differences in clinical outcomes, suggesting that transpedicular curettage and drainage with posterior stabilization was an effective treatment for patients with severe comorbidities. In contrast, Lin et al<sup>10</sup> retrospectively compared open and percutaneous approaches using a combined anterior-posterior strategy and found no significant differences in outcomes between the approaches, and Linhardt et al<sup>11</sup> compared combined anterior-posterior stabilization with isolated anterior spondylosis and found that the patients reported less pain and the clinical outcomes (SF-36, Oswestry, ODI, and VAS) were significantly better following the anterior-only approach. In another comparative study, Vcelak et al<sup>12</sup> assessed the differences between a combined anterior and posterior approach and an isolated posterior approach. They found no statistically significant differences in reoperation rate, relapse, treatment failure, or mortality.

Although sagittal balance was significantly worse in the isolated posterior approach group, the deficit had no clinical consequences.

In our series of 5 patients, 3 had comorbidities: 1 patient had HIV, another was in renal failure, and the third had a history of drug abuse. Similarly, in a series of 9 patients, Talia et al<sup>13</sup> found that all patients had predisposing conditions for infection, including diabetes (n = 5), chronic kidney disease (n = 3), prior history of tuberculosis (n = 2), and prior splenectomy (n = 1). The fact that patients with discitis/osteomyelitis have associated comorbidities justifies the use of a single posterior approach that limits the extent of surgical intervention.<sup>13</sup>

Previous studies have analyzed the use of posterior approach debridement and stabilization. Gonzalvo et al<sup>14</sup> performed single-level posterior debridement and instrumented interbody fusions in 9 patients and reported that preoperative neurological deficits improved in all patients and all achieved solid bony fusion at 12 months. Similarly, Halpern et al<sup>4</sup> conducted a study in which 5 patients with thoracic discitis/osteomyelitis underwent posterior-only thoracic transdiscal osteotomies and vertebral shortening. The kyphosis was corrected from a preoperative mean of 36° to a mean of 4°, and the mean construct length involved 9 levels. In our series, the bone defect was larger, and patients developed segmental kyphosis, making it necessary to perform the osteotomy with vertebral shortening to correct the kyphosis and provide anterior stability. Solid bone fusion and neurological recovery occurred following the use of this technique, and only 2 levels above and 2 levels below the osteotomy site were necessary to obtain solid bone fusion and correction of kyphosis from a mean of 32° to 10°. The neurological recovery in our patients was consistent with previous studies: Halpern et al<sup>4</sup> reported no neurological deterioration, and 2 patients with Frankel B improved to Frankel D and E; similarly, Talia et al,<sup>13</sup> in a series of 9 patients, reported 7 patients with ASIA E and 2 patients with ASIA D at 12 months follow-up. In our series, 3 of the patients were nonambulatory preoperatively and all 5 patients were ambulatory at follow-up. Adjacent-segment degeneration or proximal junctional kyphosis (PJK) were not observed at follow-up, although instrumentation ended at the thoracolumbar junction in 3 patients, upper instrumented vertebra was T12 in 1 patient, T11 in 1 patient, and L1 in 1 patient. This could be explained

by the fact that when optimal sagittal balance was achieved it changed from a mean of 78.7 mm to a mean of 21.88 mm; other factors that reduced the risk of PJK were the relatively small fixation construct of only 2 levels above and below kyphosis and the average age of patients of 50.1 years. Some of the well-established risk factors for PJK are being older than 55 years and having abnormal postoperative sagittal parameters.<sup>15</sup> Significant limitations of our study are that it was not a comparative study and it was a limited case series of only 5 patients. The small sample size can be explained by the fact that most bone defects associated with vertebral discitis/osteomyelitis are not large, and posterior debridement and stabilization without osteotomy and shortening is enough in most cases. We acknowledge that the use of the ASIA score was not the ideal way to document neurological function in our cohort because the measure was designed to document spinal cord function in patients with spinal cord injuries; however, we felt that it was the most appropriate to apply in our series to expose the neurological function of our patients in a simple and objective way.

## CONCLUSIONS

The present study demonstrates that posterior grade 4 osteotomy with vertebral shortening is a safe and effective treatment for kyphotic deformities associated with spinal infections. The technique reported here uses the posterior-only approach in which bone-on-bone contact provides anterior stability without using the anterior approach or instrumentation. Thus, the single posterior approach stabilizes the spine, corrects the kyphosis deformity, and decompresses the spinal canal.

## ACKNOWLEDGMENTS

The study was approved by the Research Committee of the National Institute of Rehabilitation (DES/SEM/16-10).

## REFERENCES

1. Chen WH, Jiang LS, Dai LY. Surgical treatment of pyogenic vertebral osteomyelitis with spinal instrumentation. *Eur Spine J.* 2007;16:1307–1316.
2. Srinivasan D, Terman SW, Himedan M, Dugo D, La Marca F, Park P. Risk factors for the development of deformity in patients with spinal infection. *Neurosurg Focus.* 2014;37:E2. doi:10.3171/2014.6.FOCUS14143

3. Diebo B, Liu S, Lafage V, Schwab F. Osteotomies in the treatment of spinal deformities: indications, classification, and surgical planning. *Eur J Orthop Surg Traumatol*. 2014;24:11–20.
4. Halpern EM, Bacon SA, Kitagawa T, Lewis SJ. Posterior transdiscal three-column shortening in the surgical treatment of vertebral discitis/osteomyelitis with collapse. *Spine*. 2010;25:1316–1322.
5. Jain AK, Dhammi IK, Prashad B, Sinha S, Mishra P. Simultaneous anterior decompression and posterior instrumentation of the tuberculous spine using an anterolateral extrapleural approach. *J Bone Joint Surg*. 2008;90:1477–1481.
6. Rajasekaran S, Soundarapandian S. Progression of kyphosis in tuberculosis of the spine treated with anterior arthrodesis. *J Bone Joint Surg Am*. 1989; 71:1314–1323.
7. Faciszewski T, Winter RB, Lonstein JE, Denis F, Johnson L. The surgical and medical perioperative complications of anterior spinal fusion surgery in the thoracic and lumbar spine in adults. A review of 1223 procedures. *Spine*. 1995;20:1592–1599.
8. Blizzard DJ, Hills CP, Isaacs RE. Extreme lateral interbody fusion with posterior instrumentation for spondylodiscitis. *J Clin Neurosci*. 2015;22:1758–1761.
9. Moon SH, Lee B, Park JO, Kim HS, Lee HM, Cho BW. Transpedicular curettage and drainage versus combined anterior and posterior surgery in infectious spondylodiscitis. *Indian J Orthop*. 2014;48:74–80.
10. Lin TY, Tsai TT, Lu ML, et al. Comparison of two-stage open versus percutaneous pedicle screw fixation in treating pyogenic spondylodiscitis. *BMC Musculoskelet Disord*. 2014;15:443. doi:10.1186/1471-2474-15-443
11. Linhardt O, Matussek J, Refior HJ, Krödel A. Long-term results of ventro-dorsal versus ventral instrumentation fusion in the treatment of spondylitis. *Int Orthop*. 2007;31:113–119.
12. Vcelak J, Chomiak J, Toth L. Surgical treatment of lumbar spondylodiscitis: a comparison of two methods. *Int Orthop*. 2014;38:1425–1434.
13. Talia AJ, Wong ML, Lau HC, Kaye AH. Safety of instrumentation and fusion at the time of surgical debridement for spinal infection. *J Clin Neurosci*. 2015;22:1111–1116.
14. Gonzalvo A, Abdulla I, Riazi A, De La Harpe D. Single-level/single-stage debridement and posterior instrumented fusion in the treatment of spontaneous pyogenic osteomyelitis/discitis: long-term functional outcome and health-related quality of life. *J Spinal Disord Tech*. 2011;24:110–115.
15. Cho S, Shin J, Kim Y. Proximal junctional kyphosis following adult spinal deformity surgery. *Eur Spine J*. 2014;23:2726–2736.

**Disclosures and COI:** The authors report no conflicts of interest concerning the materials or methods used in this study or the findings reported in this article.

**Corresponding Author:** Barón Zárate-Kalfópulos, MD, Spine Surgery Service, National Institute of Rehabilitation, Calzada Mexico Xochimilco #289, Arenal de Guadalupe, Tlalpan 14389, Mexico City, Mexico. Phone: (+ 52 1) 59 99 10 00 / 12811; Email: bzarate@inr.gob.mx; baronzk@hotmail.com.

Published 0 Month 2020

This manuscript is generously published free of charge by ISASS, the International Society for the Advancement of Spine Surgery. Copyright © 2020 ISASS. To see more or order reprints or permissions, see <http://ijssurgery.com>.