

Expandable Technology Improves Clinical and Radiographic Outcomes of Minimally Invasive Lateral Lumbar Interbody Fusion for Degenerative Disc Disease

Yan Michael Li, Zheng Huang, James Towner, Yan Icy Li, Jessica R. Riggleman and Charles Ledonio

Int J Spine Surg published online 12 February 2021
<https://www.ijssurgery.com/content/early/2021/02/10/8012>

This information is current as of May 7, 2025.

Email Alerts Receive free email-alerts when new articles cite this article. Sign up at:
<http://ijssurgery.com/alerts>

Expandable Technology Improves Clinical and Radiographic Outcomes of Minimally Invasive Lateral Lumbar Interbody Fusion for Degenerative Disc Disease

YAN MICHAEL LI, MD, PHD,¹ ZHENG HUANG, MD, PHD,² JAMES TOWNER, MD,³ YAN ICY LI, PHD,¹ JESSICA R. RIGGLEMAN, BS,⁴ CHARLES LEDONIO, MD, CCRP⁴

¹Department of Neurosurgery and Oncology, University of Rochester Medical Center School of Medicine and Dentistry, Rochester, New York, ²Department of Orthopaedics, Guanghua Hospital Shanghai Shi, China, ³Department of Neurosurgery, University of Rochester Medical Center School of Medicine and Dentistry Rochester, New York, ⁴Musculoskeletal Education and Research Center, A Division of Globus Medical, Inc, Audubon, Pennsylvania

ABSTRACT

Background: Static interbody spacers are standard of care for minimally invasive lateral lumbar interbody fusion (MIS LLIF). However, placement of large static interbody spacers typically requires multiple trialings, endplate preparation, and forceful impaction. A lateral expandable interbody spacer with adjustable lordosis can be inserted at a reduced height, to optimize the endplate-to-endplate fit. This study describes radiographic and clinical outcomes in patients treated using lateral titanium expandable interbody spacers with adjustable lordosis using MIS LLIF.

Methods: This is a single-surgeon, retrospective, institutional review board-exempt chart review of 24 consecutive patients who underwent MIS LLIF at 1–2 contiguous level(s) using expandable spacers with adjustable lordosis. Radiographic and clinical functional outcomes were collected and compared at preoperative and postoperative time points up to 24 months. Parametric and nonparametric tests were used when appropriate. Statistical results were significant if $P < .05$.

Results: Twenty-four consecutive patients were evaluated with an average age of 57.8 ± 12.6 years; 45.8% were female. Visual analog scale for back pain improved by 7.3 ± 1.0 points, whereas Oswestry Disability Index scores improved by a mean of 67.5 ± 11.3 points at 24 months ($P < .001$). Lumbar lordosis improved by a mean of $6.3 \pm 10.1^\circ$ at 24 months ($P < .001$). There were 29 spinal levels, with 41.4% at L4–5 and 34.5% at L3–4. Anterior, middle, and posterior disc height significantly increased at 24 months by means of 4.5 ± 2.9 mm, 4.0 ± 2.8 mm, and 2.6 ± 1.9 mm, respectively ($P < .001$). Neuroforaminal height significantly improved by 3.3 ± 3.9 mm at 24 months ($P < .001$). Segmental lordosis improved by $3.6 \pm 3.0^\circ$ at 24 months.

Conclusions: This study showed significant positive clinical and radiographic outcomes for patients who underwent MIS LLIF using expandable interbody spacers with adjustable lordosis. Correction of sagittal alignment was achieved and maintained up to 2-year follow-up. The use of expandable spacers with adjustable lordosis was shown to be safe and effective in this cohort.

Level of Evidence: X.

Clinical Relevance: XXX.

Minimally Invasive Surgery

Keywords: expandable, fusion, lateral lumbar interbody fusion, minimally invasive

INTRODUCTION

Various surgical techniques allow access to the disc space for lumbar interbody fusion, including transforaminal lumbar interbody fusion, anterior lumbar interbody fusion, and posterior lumbar interbody fusion. First described in 2006, lateral lumbar interbody fusion (LLIF) is an increasingly popular method of treating patients with spinal back and leg pain and may help minimize the risk of complications associated with traditional approaches.^{1–3}

Maintaining and achieving sagittal alignment is a critical component to the success of the LLIF procedure because it is a significant predictor in determining patient outcomes.^{4–6} Therefore, maximizing disc and neuroforaminal height and maintaining proper lumbar and segmental lordosis are essential for adequate indirect decompression. Maintenance of sagittal alignment parameters may minimize adjacent segment degeneration. The development of adjacent segment disease (ASD) can occur by fusion of the lumbar spine in a hypo-



Figure 1. Expandable interbody spacer with adjustable lordosis.

lordotic alignment.^{7,8} Consequently, postoperative sagittal plane abnormalities are correlated with ASD development.⁹

Numerous interbody spacer designs exist, some with built-in lordosis. The effects of increasing anterior lordosis without increasing disc height may have conflicting results. Godde et al¹⁰ describe the effects of interbody spacer design with or without built-in lordosis on segmental lordosis. Hyperlordotic interbody spacer designs could be challenging to insert in a collapsed disc space. One of the advantages of expandable interbody spacers is that the spacer is delivered in a collapsed state and expanded in situ. Developments in expandable technology allow for cages to increase in both height and lordosis through a controlled expansion. Long-term clinical outcome studies are needed to generate evidence of durability, effectiveness, and safety. The objective of this study is to determine the clinical and radiographic outcomes of patients who underwent MIS LLIF using an expandable interbody spacer with an adjustable lordosis.

MATERIAL AND METHODS

This is a retrospective study from a prospectively collected cohort of patients diagnosed with symptomatic degenerative disc disease (DDD) with or without grade 1 spondylolisthesis in 1 or 2 contiguous levels, and who underwent MIS LLIF using a novel titanium expandable interbody spacer with adjustable lordosis with supplemental fixation (RISE-AL, Globus Medical, Inc, Audubon, PA) (Figures 1 and 2). Patient demographics, visual analog scale (VAS) back pain scores, Oswestry Disability Index (ODI) scores, and radiographic parameters were collected at 6 weeks, 3, 6, 12, and 24 months postoperatively.

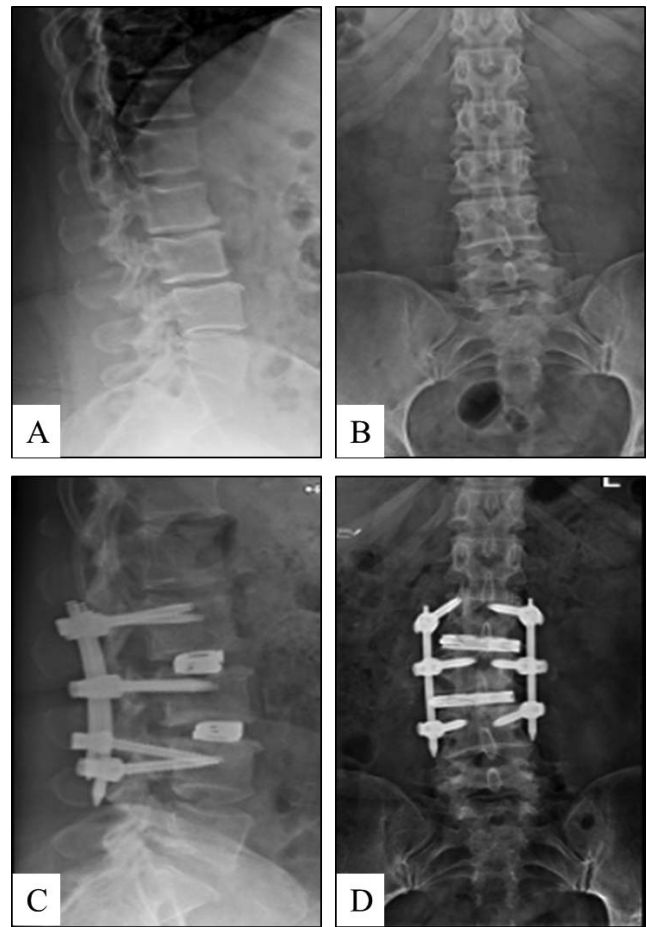


Figure 2. Preoperative lateral (A) and anteroposterior (B) radiographs and postoperative lateral (C) and anteroposterior (D) radiographs of a 2-level MIS LLIF using an adjustable lordotic expandable interbody spacer at L2–L3 and L3–L4. MIS LLIF, minimally invasive lateral lumbar interbody fusion.

Surgical Technique

After the induction of general anesthesia, patients were placed in the lateral decubitus position and secured to the operating table with adhesive medical tape. Under fluoroscopic guidance, an oblique incision was made at the operative disc segment. Blunt dissection was done under direct visualization through the retroperitoneal space. Retroperitoneal fat was mobilized anteriorly, exposing the underlying psoas muscle. The psoas muscle was palpated, and blunt dissection was performed down to the operative intervertebral disc level. After confirmation of the appropriate level via fluoroscopy, a minimally invasive retractor was docked, dilated at the segment, and secured to the table-mounted arm. An annulotomy was then performed, followed by a discectomy. Under fluoroscopic imaging, the endplates were prepared.

An expandable trial was used to allow for gradual distraction of the disc space. An expandable

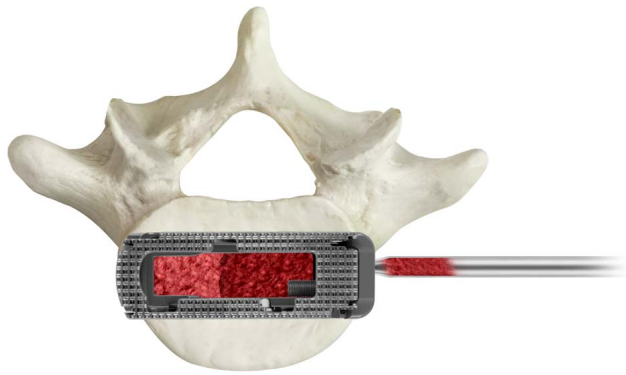


Figure 3. Additional bone graft may be packed into the graft chamber of the implant after expansion.

interbody spacer of appropriate size was selected, packed with autograft, and implanted laterally across the disc space. The spacer was then expanded to the desired height and backfilled with autograft (Figure 3).

The expandable interbody spacer used in this study is manufactured from titanium alloy. The device is inserted at a contracted height and expanded in situ once correctly positioned within the intervertebral space, offering continuous expansion and adjustable lordosis for optimal endplate-to-endplate contact.

Pedicle screws and rods were used for supplemental posterior fixation. Locking caps were set once the rods were in their proper position. Intraoperative fluoroscopy images were taken to verify screw and rod position. Surgical incisions were cleaned and closed in the standard fashion.

Quantitative Measurements

Radiographic lumbosacral parameters were measured on upright lateral radiographs using imaging software (Intellispace PACS 4.4; Koninklijke Philips N.V., Amsterdam, Netherlands) (Figure 4). Measurements included disc heights, neuroforaminal height, segmental lordosis, and lumbar lordosis. Disc height was defined as the distance between the inferior and superior endplates at the anterior, middle, and posterior portions of the vertebral body. Neuroforaminal height refers to the interpedicular height, or the rostral and caudal boundaries of the foramen. Segmental lordosis was measured as the Cobb angle of the superior endplate of the level below the LLIF and the inferior endplate of the level above the LLIF. Lumbar lordosis was measured as the angle between the superior endplate of L1 and the superior endplate of S1. Pseudoar-

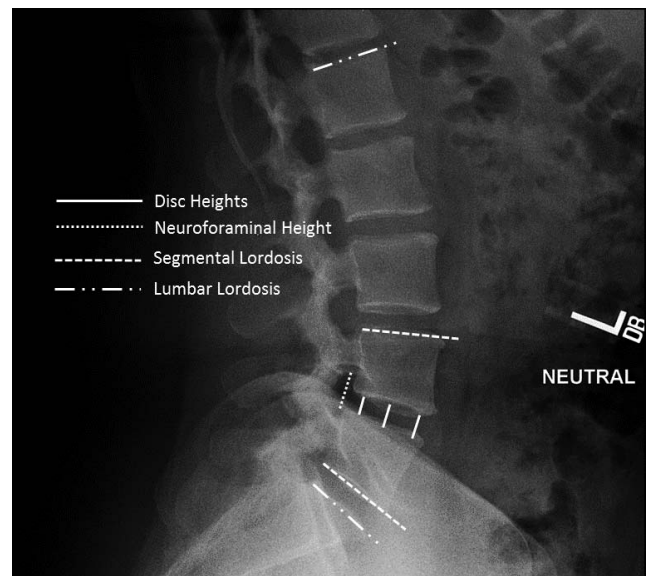


Figure 4. Standing lateral lumbar spine radiograph with superimposed lines displaying the measurements evaluated in this study. Measurements included disc heights, neuroforaminal height, segmental lordosis, and lumbar lordosis.

throsis and subsidence were assessed as previously described.^{11,12}

Statistical Methods

The statistical analysis was performed using IBM SPSS Version 25 (IBM Corp, Armonk, NY). Descriptive statistics are presented as frequencies and percentages. Clinical and radiographic measurements are presented as means and standard deviations. Statistical significance was shown at $P < .05$.

RESULTS

Patient Demographics

From August 2016 to January 2017, 24 consecutive patients underwent MIS LLIF with a titanium expandable interbody spacer with adjustable lordosis. The patients were 45.8% (11/24) female and 54.2% (13/24) male, with an average age of 57.8 ± 12.6 years (range: 21–76 years). The average patients' Charlson Comorbidity Index (CCI) score was 2.6 ± 2.1 (range: 0–8) (Table 1).

Table 1. Baseline characteristics.

Parameter	Overall
Number of patients	24
Sex	
Female, n (%)	11 (45.8)
Male, n (%)	13 (54.2)
Age, mean (SD) (range)	57.8 (12.6) (21–76)
CCI, mean (SD) (range)	2.6 (2.1) (0–8)

Abbreviations: CCI, Charlson Comorbidity Index; SD, standard deviation.

Table 2. MIS LLIF fusion procedure characteristics.

Parameter	Overall
Type of surgery, n (%)	
One-level	19 (79.2)
Two-level	5 (20.8)
Levels treated, n (%)	
L1–L2	2 (6.9)
L2–L3	5 (17.2)
L3–L4	10 (34.5)
L4–L5	12 (41.4)
Mean estimated blood loss, n (SD)	
One-level	18.3 (5.5)
Two-level	31.0 (6.5)
Mean operative time, n (SD)	
One-level	53.9 (14.2)
Two-level	79.2 (23.3)
Mean fluoroscopic time, n (SD)	
One-level	27.5 (12.8)
Two-level	34.8 (14.8)
Mean length of hospital stay, n (SD)	
One-level	3.6 (2.0)
Two-level	6.0 (4.1)

Abbreviations: MIS LLIF, minimally invasive lateral lumbar interbody fusion; SD, standard deviation.

Surgical Data

Of the 24 patients, 79.2% (19/24) underwent 1-level and 20.8% (5/24) underwent 2-level MIS LLIF, for a total of 29 spinal levels treated. Of the 29 levels, 41.4% (12/29) were performed at L4–5 and 34.5% (10/29) at L3–4. The average estimated blood loss was 18.3 ± 5.5 cc for 1-level fusions and 31.0 ± 6.5 cc for 2-level fusions with no blood transfusions. The mean operative time was 53.9 ± 14.2 minutes for 1-level fusions and 79.2 ± 23.3 minutes for 2-level fusions. The mean fluoroscopic time was 27.5 ± 12.8 seconds for 1-level fusions and 34.8 ± 14.8 seconds for 2-level fusions. The mean length of hospital stay was 3.6 ± 2.0 days for 1-level fusions and 6.0 ± 4.1 days for 2-level fusions (Table 2).

Patient-Reported Outcomes (VAS and ODI)

Mean VAS back pain scores significantly improved from baseline by 51.2% (4.3 ± 1.0), 61.9% (5.2 ± 1.1), 72.6% (6.0 ± 1.2), 76.2% (6.4 ± 1.6), and 86.9% (7.3 ± 1.0) at 6 weeks, 3, 6, 12, and 24 months, respectively ($P < .001$) (Figure 5). Mean ODI scores significantly improved from baseline by 38.1% (30.1 ± 13.2), 55.6% (44.0 ± 11.6), 65.7% (52.0 ± 14.6), 75.7% (59.9 ± 16.1), and 85.3% (67.5 ± 11.3) at 6 weeks, 3, 6, 12, and 24 months, respectively ($P < .001$) (Figure 6; Table 3).

Radiographic Parameters

The mean anterior disc height significantly improved from baseline by 85.9% (6.7 ± 3.0 mm),

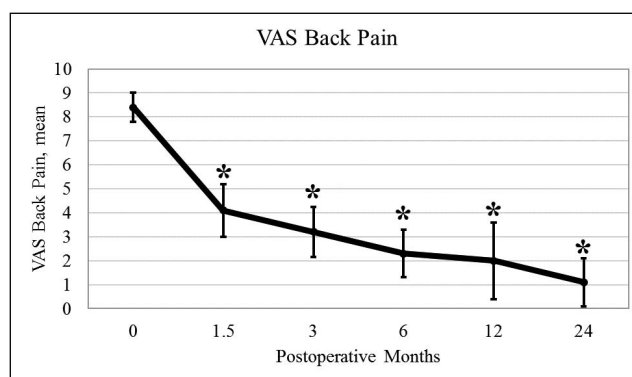


Figure 5. Mean VAS back pain is shown. The results show a significant decrease in VAS back pain scores from baseline and sustained at 1.5, 3, 6, 12, and 24 months. * $P < .05$ compared with baseline. VAS, visual analog scale.

78.2% (6.1 ± 3.0 mm), 70.5% (5.5 ± 3.0 mm), 64.1% (5.0 ± 3.0 mm), and 57.7% (4.5 ± 2.9 mm) at 6 weeks, 3, 6, 12, and 24 months, respectively ($P < .001$). The mean middle disc height significantly improved from baseline by 93.8% (5.9 ± 3.0 mm), 78.1% (5.0 ± 2.9 mm), 73.4% (4.7 ± 2.8 mm), 68.8% (4.4 ± 2.9 mm), 64.1% (4.0 ± 2.8 mm) at 6 weeks, 3, 6, 12, and 24 months, respectively ($P < .001$). The mean posterior disc height significantly improved from baseline by 100.0% (4.4 ± 1.8 mm), 84.1% (3.7 ± 1.8 mm), 75.0% (3.3 ± 1.9 mm), 63.6% (2.8 ± 2.0 mm), and 59.1% (2.6 ± 1.9 mm) at 6 weeks, 3, 6, 12, and 24 months, respectively ($P < .001$). The mean neuroforaminal height significantly improved from baseline by 42.9% (6.3 ± 3.9 mm), 37.4% (5.6 ± 3.9 mm), 30.6% (4.6 ± 4.2 mm), 24.5% (3.6 ± 4.0 mm), and 22.4% (3.3 ± 3.9 mm) at 6 weeks, 3, 6, 12, and 24 months, respectively ($P < .001$). The mean segmental lordosis significantly improved from baseline by 113.6% ($5.0 \pm 3.3^\circ$), 102.3% ($4.4 \pm 3.4^\circ$), 95.5% ($4.2 \pm 3.3^\circ$), 84.1% ($3.6 \pm 3.1^\circ$), and 81.8% ($3.6 \pm 3.1^\circ$) at 6 weeks, 3, 6, 12, and 24 months, respectively ($P < .001$).

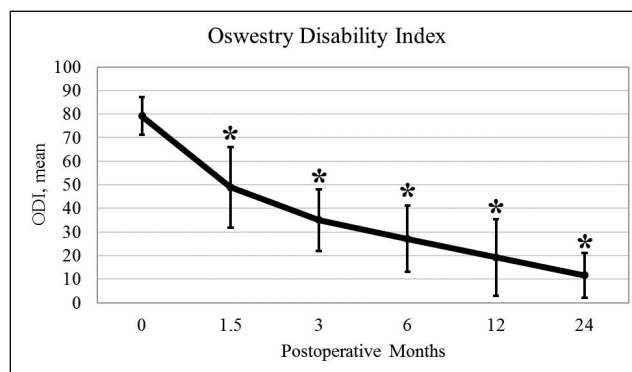


Figure 6. Mean ODI is shown. The results showed a significant decrease in ODI scores from baseline and sustained at 1.5, 3, 6, 12, and 24 months. * $P < .05$ compared with baseline. ODI, Oswestry Disability Index.

Table 3. Mean (standard deviation) values of patient reported outcomes and radiographic parameters.

Parameter	Baseline	6 Weeks	3 Months	6 Months	12 Months	24 Months
VAS back pain	8.4 (0.6)	4.1 (1.1) ^a	3.2 (1.0) ^a	2.3 (1.0) ^a	2.0 (1.6) ^a	1.1 (1.0) ^a
ODI	79.1 (8.0)	49.0 (17.1) ^a	35.1 (13.1) ^a	27.1 (14.1) ^a	19.2 (16.3) ^a	11.6 (9.5) ^a
Anterior disc height, mm	7.8 (3.2)	14.5 (2.6) ^a	13.9 (2.6) ^a	13.3 (2.2) ^a	12.8 (2.0) ^a	12.3 (1.9) ^a
Middle disc height, mm	6.4 (2.5)	12.4 (2.3) ^a	11.4 (2.6) ^a	11.1 (2.3) ^a	10.8 (2.2) ^a	10.5 (2.2) ^a
Posterior disc height, mm	4.4 (1.7)	8.8 (2.0) ^a	8.1 (1.8) ^a	7.7 (1.6) ^a	7.2 (1.8) ^a	7.0 (1.7) ^a
Neuroforaminal height, mm	14.7 (3.1)	21.0 (3.7) ^a	20.2 (3.5) ^a	19.2 (3.3) ^a	18.3 (3.2) ^a	18.0 (3.0) ^a
Segmental lordosis, °	4.4 (3.1)	9.4 (3.1) ^a	8.9 (3.0) ^a	8.6 (2.9) ^a	8.1 (2.3) ^a	8.0 (2.2) ^a
Lumbar lordosis, °	37.8 (10.8)	48.5 (7.4) ^a	47.5 (5.0) ^a	45.5 (5.9) ^a	44.4 (5.6) ^a	44.2 (6.4)

Abbreviations: ODI, Oswestry Disability Index; VAS, visual analog scale.

^a*P* < .05 compared with baseline.

3.0°) at 6 weeks, 3, 6, 12, and 24 months, respectively (*P* < .001). The mean lumbar lordosis significantly improved from baseline by 28.3% (10.7 ± 10.6°), 25.7% (9.7 ± 9.3°), 20.4% (7.6 ± 9.7°), and 17.5% (6.5 ± 9.7°) at 6 weeks, 3, 6, and 12 months, respectively (*P* < .05). The mean lumbar lordosis improved from baseline by 16.9% (6.3 ± 10.1°) at 24 months (*P* > .05) (Table 3).

Complications

There were no reported implant-related complications, radiolucency, or subsidence, and a 0% pseudoarthrosis rate by 24-month follow-up.

DISCUSSION

Long-term radiographic and clinical outcomes are essential to providing evidence that the use of lateral expandable interbody spacers with adjustable lordosis is effective. At 24-month follow-up, radiographic outcomes of this study showed that MIS LLIF using expandable interbody spacers with adjustable lordosis significantly corrected anterior, middle, and posterior disc height, neuroforaminal height, segmental lordosis, and lumbar lordosis by 57.7%, 64.1%, 59.1%, 22.4%, 81.8%, and 16.9%, respectively. At 24-month follow-up, VAS back and leg pain scores and ODI scores improved by 86.9% and 85.3%, respectively.

To the best of the authors' knowledge, this is the first study to describe the long-term clinical and radiographic outcomes of the use of an expandable interbody spacer with an adjustable lordosis in MIS LLIF; therefore, comparison to the literature can be challenging.

In the treatment of DDD with or without spondylolisthesis, the loss of disc height and lumbar lordosis can cause debilitating back pain.^{13–15} Studies have shown that restoration and mainte-

nance of these parameters after spine surgery is associated with improved clinical outcomes.^{3,10,16–18}

Isaacs et al¹⁸ reported on radiographic outcomes of patients who underwent MIS TLIF or MIS LLIF (extreme lateral interbody fusion [XLIF; NuVasive, Inc, San Diego, CA]) with static interbody spacers in the treatment of degenerative spondylolisthesis with stenosis through 2-year follow-up. Disc height was measured as the average of anterior and posterior disc heights. Disc height significantly increased by 2.5 mm (32.9%) and 2.4 mm (35.8%) in the XLIF and MIS TLIF groups from baseline to 24 months, respectively. Lumbar lordosis increased by 0.2° (0.3%) in the XLIF group and decreased by 2.6° (4.4%) in the TLIF group from baseline to 24 months. To directly compare with the current study, anterior and posterior disc height were averaged and resulted in an increase of 3.6 mm (59.0%), whereas lumbar lordosis increased by 6.4° (14.5%) from baseline to 24 months. Expandable titanium interbody spacers with adjustable lordosis may provide greater correction in the lumbar spine due to less endplate destruction and optimal fit after expansion in comparison with static interbody spacers.

Clinical outcomes were reported in a separate manuscript.¹⁷ VAS back pain scores significantly decreased by 5.4 points in the XLIF group and 3.6 points in the TLIF group at 24 months. In the current study, a greater decrease in VAS back pain scores by 7.3 points at 24 months was observed. Titanium expandable interbody spacers with adjustable lordosis for LLIF may provide improved indirect decompression leading to less postoperative pain compared with static interbody spacers in XLIF and TLIF.

The findings on radiographic and clinical outcomes were similarly improved in studies analyzing interbody spacers using MIS LLIF. Kotwal et al³ reported on 118 patients who underwent MIS LLIF with a minimum of 2 years' follow-up. VAS back

pain scores significantly improved by 4.6 points and ODI scores improved by 12.9 points by 24 months. In a recent study, Frisch et al¹⁶ reported on 27 patients who underwent MIS LLIF with a PEEK expandable spacer. VAS back pain scores significantly improved by 3.1 points, whereas ODI scores significantly improved by 19.3 points.

The use of lordotic interbody spacers has been demonstrated in previous studies. In a comparative radiographic analysis of consecutive LLIF procedures using 10° PEEK lordotic and nonlordotic interbody spacers, Sembrano et al¹⁹ found that lordotic cages significantly increased operative level segmental lordosis by 2.8° compared with nonlordotic interbody spacers, with a nonsignificant improvement of 0.6°. In the current study, operative level segmental lordosis significantly improved by 3.6°, suggesting a larger improvement in titanium expandable interbody spacer with adjustable lordosis compared with the static PEEK lordotic spacers with a fixed (10°) lordosis.

In a prospective review, it was determined that minimal clinical important difference (MCID) values are 1.2 points for back pain and 12.8 points for ODI.^{20,21} In the current study, VAS back pain scores significantly improved by 4.3, 5.2, 6.1, 6.4, and 7.3 points at 6 weeks, 3, 6, 12, and 24 months, respectively. ODI scores significantly improved by 30.1, 44, 52, 59.9, and 67.5 points, respectively. This demonstrates a significant clinical benefit, with a mean VAS improvement of 3–6 times the MCID and a mean ODI improvement of 2–5 times the MCID.^{20,21}

Subsidence rates with the use of static interbody spacers have been reported to be relatively high. In a systematic review by Macki et al,²² the pooled subsidence rate with LLIF was 10.3%, with a range of 0% to as high as 30% (n = 141/1362 patients in 14 published articles) and a reoperation rate for subsidence of 2.7% (n = 41/1470 patients in 16 published articles). In this review, the studies with the highest subsidence rates were from Marchi et al,²³ with a rate of 29.7%. Marchi et al,²⁴ Pimenta et al,²⁵ and Le et al²⁶ reported a subsidence rate of 17.2%, 16.6%, and 14.3%, respectively. Static polyetheretherketone spacers of various sizes were used in these studies. In the current study, there was no subsidence reported.

Study Limitations

Although this is a single-surgeon, single-site retrospective study with a small patient population,

the results are consistent with findings from the literature. Comparative studies are needed to determine effectiveness to traditional treatment.

CONCLUSION

LLIF using an expandable titanium interbody spacer with adjustable lordosis is shown to be durable, safe, and effective at improving radiographic and clinical outcomes in this cohort. Anterior and posterior disc height and neuroforaminal height were significantly restored, providing evidence for indirect decompression. Segmental and lumbar lordosis were significantly restored, correcting sagittal alignment. There were no cases of subsidence up to 24-month follow-up.

ACKNOWLEDGMENTS

Funding for this project was provided by the Musculoskeletal Education and Research Center (MERC), a Division of Globus Medical, Inc. The authors thank Mr Howard Whitman and Ms Leigh Ahrendtsen for their hard work.

REFERENCES

1. Ozgur BM, Aryan HE, Pimenta L, Taylor WR. Extreme lateral interbody fusion (XLIF): a novel surgical technique for anterior lumbar interbody fusion. *Spine J*. 2006;6(4):435–443.
2. Lehmen JA, Gerber EJ. MIS lateral spine surgery: a systematic literature review of complications, outcomes, and economics. *Eur Spine J*. 2015;24(suppl 3):287–313.
3. Kotwal S, Kawaguchi S, Lebl D, et al. Minimally invasive lateral lumbar interbody fusion: clinical and radiographic outcome at a minimum 2-year follow-up. *J Spinal Disord Tech*. 2015;28(4):119–125.
4. Glassman SD, Berven S, Bridwell K, Horton W, Dimar JR. Correlation of radiographic parameters and clinical symptoms in adult scoliosis. *Spine (Phila Pa 1976)*. 2005;30(6):682–688.
5. Glassman SD, Bridwell K, Dimar JR, Horton W, Berven S, Schwab F. The impact of positive sagittal balance in adult spinal deformity. *Spine (Phila Pa 1976)*. 2005;30(18):2024–2029.
6. Rodgers JA, Gerber EJ, Lehmen JA, Rodgers BW. Clinical and radiographic outcome in less invasive lumbar fusion: XLIF at two year follow-up. *J Spine Neurosurg*. 2013;2:1–6.
7. Chen WJ, Lai PL, Tai CL, Chen LH, Niu CC. The effect of sagittal alignment on adjacent joint mobility after lumbar instrumentation—a biomechanical study of lumbar vertebrae in a porcine model. *Clin Biomech (Bristol, Avon)*. 2004;19(8):763–768.
8. Djurasovic MO, Carreon LY, Glassman SD, Dimar JR 2nd, Puno RM, Johnson JR. Sagittal alignment as a risk factor for adjacent level degeneration: a case-control study. *Orthopedics*. 2008;31(6):546.
9. Kumar MN, Baklanov A, Chopin D. Correlation between

sagittal plane changes and adjacent segment degeneration following lumbar spine fusion. *Eur Spine J*. 2001;10(4):314–319.

10. Godde S, Fritsch E, Dienst M, Kohn D. Influence of cage geometry on sagittal alignment in instrumented posterior lumbar interbody fusion. *Spine (Phila Pa 1976)*. 2003;28(15):1693–1699.

11. Kanemura T, Matsumoto A, Ishikawa Y, et al. Radiographic changes in patients with pseudarthrosis after posterior lumbar interbody arthrodesis using carbon interbody cages: a prospective five-year study. *J Bone Joint Surg Am*. 2014;96(10):e82.

12. Choi JY, Sung KH. Subsidence after anterior lumbar interbody fusion using paired stand-alone rectangular cages. *Eur Spine J*. 2006;15(1):16–22.

13. Scemama C, Magrino B, Gillet P, Guigui P. Risk of adjacent-segment disease requiring surgery after short lumbar fusion: results of the French Spine Surgery Society Series. *J Neurosurg Spine*. 2016;25(1):46–51.

14. Virk SS, Niedermeier S, Yu E, Khan SN. Adjacent segment disease. *Orthopedics*. 2014;37(8):547–555.

15. Zhu G, Hao Y, Yu L, Cai Y, Yang X. Comparing stand-alone oblique lumbar interbody fusion with posterior lumbar interbody fusion for revision of rostral adjacent segment disease: a STROBE-compliant study. *Medicine*. 2018;97(40):e12680.

16. Frisch RF, Luna IY, Brooks DM, Joshua G, O'Brien JR. Clinical and radiographic analysis of expandable versus static lateral lumbar interbody fusion devices with two-year follow-up. *J Spine Surg*. 2018;4(1):62–71.

17. Sembrano JN, Tohmeh A, Isaacs R. Two-year comparative outcomes of MIS lateral and MIS transforaminal interbody fusion in the treatment of degenerative spondylolisthesis: part I: clinical findings. *Spine (Phila Pa 1976)*. 2016;41(suppl 8):S123–S132.

18. Isaacs RE, Sembrano JN, Tohmeh AG. Two-year comparative outcomes of MIS lateral and MIS transforaminal interbody fusion in the treatment of degenerative spondylolisthesis: part II: radiographic findings. *Spine (Phila Pa 1976)*. 2016;41(suppl 8):S133–S144.

19. Sembrano JN, Horazdovsky RD, Sharma AK, Yson SC, Santos ERG, Polly DW Jr. Do lordotic cages provide better segmental lordosis versus nonlordotic cages in lateral lumbar interbody fusion (LLIF)? *Clin Spine Surg*. 2017;30(4):E338–E343.

20. Copay AG, Glassman SD, Subach BR, Berven S, Schuler TC, Carreon LY. Minimum clinically important difference in lumbar spine surgery patients: a choice of methods using the Oswestry Disability Index, Medical Outcomes Study questionnaire Short Form 36, and pain scales. *Spine J*. 2008;8(6):968–974.

21. Copay AG, Subach BR, Glassman SD, Polly DW Jr,

Schuler TC. Understanding the minimum clinically important difference: a review of concepts and methods. *Spine J*. 2007;7(5):541–546.

22. Macki M, Anand SK, Surapaneni A, Park P, Chang V. Subsidence rates after lateral lumbar interbody fusion: a systematic review. *World Neurosurgery*. 2019;122:599–606.

23. Marchi L, Abdala N, Oliveira L, Amaral R, Coutinho E, Pimenta L. Radiographic and clinical evaluation of cage subsidence after stand-alone lateral interbody fusion. *J Neurosurg Spine*. 2013;19(1):110–118.

24. Marchi L, Abdala N, Oliveira L, Amaral R, Coutinho E, Pimenta L. Stand-alone lateral interbody fusion for the treatment of low-grade degenerative spondylolisthesis. *ScientificWorldJournal*. 2012;2012:456346.

25. Pimenta L, Marchi L, Oliveira L, Coutinho E, Amaral R. A prospective, randomized, controlled trial comparing radiographic and clinical outcomes between stand-alone lateral interbody lumbar fusion with either silicate calcium phosphate or rh-BMP2. *J Neurol Surg A Cent Eur Neurosurg*. 2013;74(6):343–350.

26. Le TV, Baaj AA, Dakwar E, et al. Subsidence of polyetheretherketone intervertebral cages in minimally invasive lateral retroperitoneal transpsoas lumbar interbody fusion. *Spine (Phila Pa 1976)*. 2012;37(14):1268–1273.

Disclosures and COI: Yan Michael Li, Zheng Huang, and Yan Icy Li receive research support from the device company whose technology is examined in the paper. Jessica R. Rigglesman and Charles Ledonio are employees of a company involved in the manufacture of a device examined in this study.

Corresponding Author: Jessica R. Rigglesman, BS, Musculoskeletal Education and Research Center, A Division of Globus Medical, Inc, 2560 General Armistead Ave, Audubon, PA 19403; Phone: 610-930-1800 x2583; Email: jrigglesman@globusmedical.com.

Published 0 Month 2021

This manuscript is generously published free of charge by ISASS, the International Society for the Advancement of Spine Surgery. Copyright © 2021 ISASS. To see more or order reprints or permissions, see <http://ijssurgery.com>.