

Outcomes of Thoracolumbar Fracture-Dislocation Managed by Short-Segment and Long-Segment Posterior Fixation: A Single-Center Retrospective Study

Samarth Mittal, Syed Ifthekar, Kaustubh Ahuja, Bhaskar Sarkar, Gobinder Singh, Arvind Rana and Pankaj Kandwal

Int J Spine Surg published online 18 February 2021
<https://www.ijssurgery.com/content/early/2021/02/16/8006>

This information is current as of May 17, 2025.

Email Alerts Receive free email-alerts when new articles cite this article. Sign up at:
<http://ijssurgery.com/alerts>

Outcomes of Thoracolumbar Fracture-Dislocation Managed by Short-Segment and Long-Segment Posterior Fixation: A Single-Center Retrospective Study

SAMARTH MITTAL, MS, DNB,¹ SYED IFTHEKAR, DNB,¹ KAUSTUBH AHUJA, MS,¹ BHASKAR SARKAR, MS,² GOBINDER SINGH, MS,¹ ARVIND RANA, MS,¹ PANKAJ KANDWAL, MS¹

¹Department of Orthopaedics, AIIMS Rishikesh, Uttarakhand, India, ²Department of Trauma and Emergency, AIIMS Rishikesh, Uttarakhand, India

ABSTRACT

Background: Long-segment posterior fixation has been used as a mainstay treatment of spine fracture-dislocations. Studies using short-segment posterior fixation in cases of thoracolumbar fracture-dislocation are limited. We describe our experience of 26 patients with thoracolumbar fracture-dislocation treated by short-segment or long-segment posterior spinal fixation and fusion.

Methods: This is a single-center retrospective study of 26 patients with thoracolumbar fracture-dislocation treated by long-segment (Group 1, n = 12) and short-segment posterior instrumentation (Group 2, n = 14). Clinical (visual analog scale [VAS], Oswestry Disability Index [ODI]), neurological (American Spinal Injury Association [ASIA] scale), radiological (kyphotic angle, translational percentage, and displacement angle), and surgical (blood loss, operative time) outcomes and complications were recorded with each method. The mean follow-up period was 8.64 months (6–20 months)

Results: The mean duration of surgery was 3.92 ± 0.67 hours in Group 1 and 3.21 ± 0.54 hours in Group 2, and mean blood loss was 583.33 ± 111.5 mL and 478.6 ± 112.2 mL in groups 1 and 2, respectively ($P < .05$). There was no radiologically visible pseudarthrosis, implant failure, or screw breakage in either group at follow up with no statistically significant difference between the 2 groups with regard to the radiological outcome ($P > .05$). Two patients in Group 1 and 6 patients in Group 2 improved after surgery at least 1 ASIA grade. VAS and ODI improved in both groups at the final follow up.

Conclusions: Short-segment fixation can be used for treating fracture-dislocation patients, as it results in less blood loss, decreased intraoperative time, and saves fusion segments with similar radiological and clinical outcomes as long-segment fixation.

Level of Evidence: 3.

Lumbar Spine

Keywords: lumbar spine, fracture-dislocation, posterior instrumentation, index screw

INTRODUCTION

Thoracolumbar fracture-dislocations involve damage to the bony and ligamentous structures that stabilize the spine and are often accompanied by neurological dysfunction.¹ The transition from stiff and kyphotic thoracic spine to mobile and lordotic lumbar spine makes the thoracolumbar region (T10–L2) more susceptible to this mechanism of injury. The treatment goals for fracture-dislocations are to achieve reduction, neural element decompression, immediate stabilization with spine fusion, and early rehabilitation. The literature about segmental instrumentation of thoracolumbar dislocation injuries is extremely limited due to the low

incidence of this type of spinal fracture. Long-segment posterior fixation has been used as a mainstay treatment for fracture-dislocations. Longer constructs (2 levels above and 2 levels below) are more appropriate for a posterior-only approach in the management of these fractures because of their superior rigidity.²

Authors of studies done in the past^{3–5} have shown the advantages of short-segment posterior fixation using screws in fractured vertebrae (index screws) in cases of burst fractures to achieve better correction and to save fusion segments; however, studies using short-segment posterior fixation in cases of thoracolumbar fracture dislocation are limited.^{6,7} We aim to compare short versus long instrumentation in the

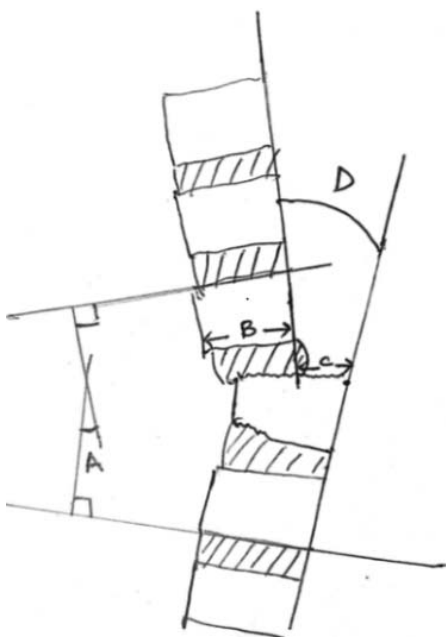


Figure 1. Radiographic parameters: (A) Kyphotic angle: The angle formed between a line drawn parallel to the superior endplate of 1 vertebra above the fracture and a line drawn parallel to the inferior endplate of the vertebra 1 level below the fracture. (B) and (C) Translation percentage: Calculated as $C/B \times 100$, as measured on a lateral plain radiograph. (C) represents the distance between the lines drawn along the posterior borders of the vertebral bodies of the injured motion segment, and (B) represents the measured sagittal diameter of the body of the slipped vertebra. (D) Displacement angle: The angle formed between the lines drawn along the posterior borders of the vertebral bodies of the injured motion segment.

management of thoracolumbar fracture-dislocation. Here, we describe our experience of 26 patients with thoracolumbar fracture-dislocation treated by short-segment and long-segment posterior spinal fixation and fusion.

MATERIAL AND METHODS

We conducted a single-center retrospective study of 26 patients with thoracolumbar fracture-disloca-

tion treated either by short-segment or long-segment posterior instrumentation from January 2018 to October 2019. Patients with single-level fracture-dislocation of the thoracolumbar spine (AO type C) with or without neurological deficit were included in the study. Patients with AO type A, AO type B, and pathological fractures were excluded from the study. Clinical and neurological examination was done to determine neurological deficit as per the American Spinal Injury Association (ASIA) scale. All patients underwent x rays, baseline computed tomography (CT) of the affected region, and magnetic resonance imaging (MRI) for fracture evaluation. Radiological evaluation was done by measuring the kyphotic angle using Cobb's method, translation percentage, and displacement angle (Figure 1). All patients in the study underwent posterior decompression and instrumented posterior/posterolateral fusion. A posterior midline approach was used; length of incision and levels of exposure depended upon treatment group. Subperiosteal dissection was carried out to expose laminae, facets, and transverse processes. Based on the extent of instrumentation, patients were divided into 2 groups: Group 1 included 12 patients treated by long-segment posterior fixation (2 levels above and below the dislocated level) and posterolateral fusion (Figure 2). Group 2 included 14 patients treated by short-segment posterior fixation (fixation less than 2 levels above and below the dislocated level) and posterolateral fusion was performed (Figure 3). Pedicle screws were inserted bilaterally or unilaterally in fractured vertebrae (index screws) along with 1 level above and below the dislocation segment in Group 2. Posterior decompression was carried out by laminectomy in all, and local autograft harvested was

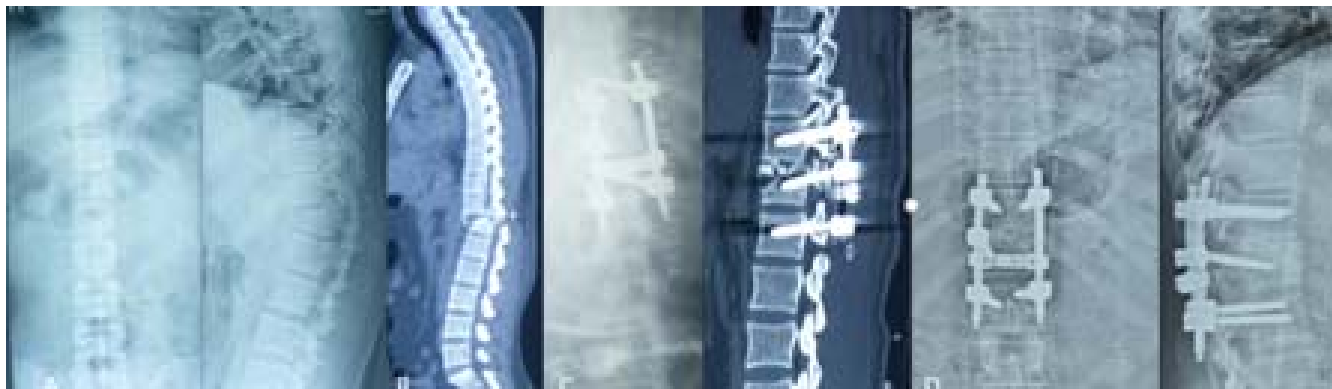

Figure 2. D12–L1 fracture-dislocation in a 41-year-old female. (A) Radiographs anteroposterior and lateral view. (B) Sagittal preoperative computed tomography scan. (C) Postoperative x ray showing reduction of dislocation with long-segment posterior fixation. (D) 6-month follow-up x ray showing well-maintained alignment and fixation.

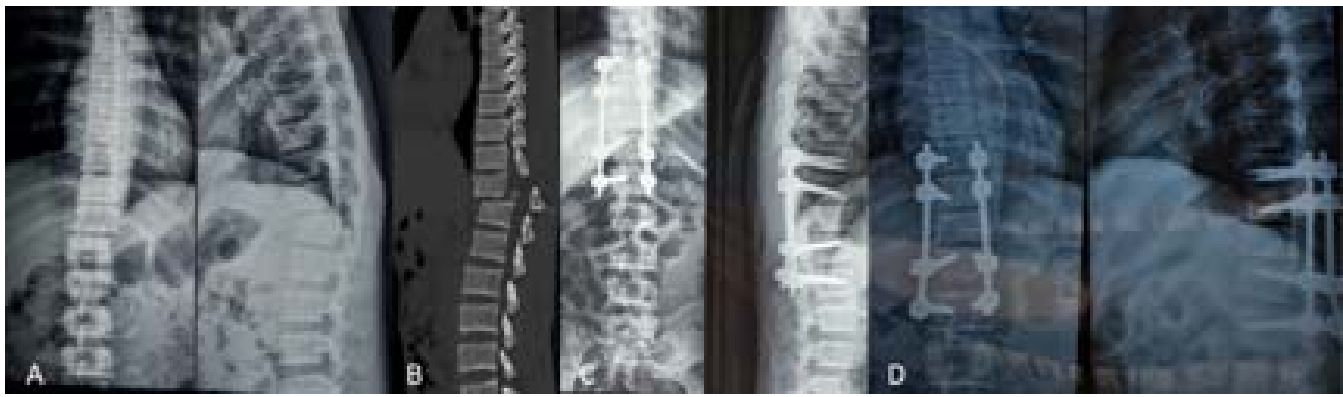

Figure 3. Imaging of a 32-year-old man who had a fall from height. (A) The radiographs (anteroposterior and lateral) and (B) sagittal computed tomography scan show fracture-dislocation at the D12–L1 level. (C) The postoperative radiographs (anteroposterior and lateral) show that the dislocated segment had been realigned to a normal anatomic sequence after short-segment posterior fixation and posterolateral fusion. (D) 16-month follow-up x ray shows no loss of reduction with a good position of the internal fixation.

used for posterior and posterolateral fusion. Patients were mobilized on the second postoperative day and were provided braces for 3 months.

The duration of surgery, intraoperative blood loss, and complications were noted. Patients were followed up for recording neurological, functional, and radiological outcomes. The ASIA scale was used to record the neurological status of each patient at follow up. The functional outcome after surgery was evaluated using the visual analog scale (VAS) and bodily pain of the Oswestry Disability Index (ODI) survey. The radiological outcome was evaluated by measuring the kyphotic angle, translational percentage, and displacement angle in postoperative and final follow-up x rays. Loss of kyphotic correction achieved between postoperative and final follow up was also recorded.

Statistical Methods

Categorical data were expressed as frequency, percentage, proportions and cross-tabulation. Quantitative data were expressed as means \pm standard deviations (SDs). Independent-samples *t* tests were used for operative time, blood loss, and radiological parameters. A $P < .05$ was considered statistically significant, and all the tests were performed by SPSS (version 17.0; SPSS Inc, Chicago, IL).

RESULTS

The mean age of the 26 patients included in our study was 29.8 years (range, 19–50 years). There were 20 males and 6 female patients. In most cases (18, 69.2%), the mode of injury was due to a fall from height, whereas 8 patients sustained injury due to a road traffic accident. Eight patients (30.7%)

sustained associated injuries of head ($n = 4$), chest ($n = 3$), and limb fractures ($n = 1$). Injuries were mainly at the thoracolumbar junction area (T10–L2): 19 cases (73.07%) of the T12–L1 region, and the remaining 7 patients (26.93%) had fracture-dislocation of the T10–11, T11–12, and L1–2 regions. As to neurological evaluation, 16 out of 26 patients (61.5%) presented with complete paraplegia with ASIA A neurology, 8 patients (30.76%) with ASIA C, and 2 patients (7.6%) with ASIA D.

The mean duration of surgery was 3.92 ± 0.67 hours in Group 1 and 3.21 ± 0.54 hours in Group 2, and the mean blood loss was 583.33 ± 111.5 mL and 478.6 ± 112.2 mL in groups 1 and 2, respectively (Table 1). There was a statistically significant difference in surgical outcomes with respect to blood loss and operative time in both groups calculated by independent-samples *t* test ($P < .05$).

Two patients in Group 1 and 6 patients in Group 2 improved after surgery at least 1 ASIA grade. There was neurologic deterioration by 1 grade (from ASIA Grade D to ASIA Grade C) in 1 patient of Group 1 after surgery (Table 2).

The mean follow-up period was 8.64 months (6–20 months). Radiological evaluation was done by kyphotic angle, translation percentage, and displacement angle (Table 3). The kyphosis angle values were as follows: average preoperative =

Table 1. Surgical outcomes.

Group	Duration, mean \pm SD, h	Blood loss, mean \pm SD, mL	<i>P</i> Value
1	3.92 ± 0.67	583.3 ± 111.5	.007
2	3.21 ± 0.54	478.6 ± 112.2	.026

Table 2. Preoperative and postoperative neurological status American Spinal Injury Association (ASIA) scores for Groups 1 and 2.

Score	Preoperative ASIA		Postoperative ASIA										
	1	2	A		B		C		D		E		
			1	2	1	2	1	2	1	2	1	2	
A	9	7	8	7	0	0	1	0	0	0	0	0	0
B	0	0	0	0	0	0	0	0	0	0	0	0	0
C	2	6	0	0	0	0	1	1		3	1	2	2
D	1	1	0	0	0	0	1	0	0	0	0	1	1
E	0	0	0	0	0	0	0	0	0	0	0	0	0

26.17° ± 7.33°, 16.29° ± 7.56°, immediate postoperative = 7.75° ± 5.73°, 6.93° ± 6.22°, and final follow up = 11.58° ± 5.19°, 9.23° ± 7.1° in groups 1 and 2, respectively. Average translation percentage in groups 1 and 2 was preoperative = 26.08 ± 15.2, 23.3 ± 13.43, immediate postoperative = 6.50 ± 3.42, 8.93 ± 6.15, and final follow up = 8.75 ± 3.69, 10.38 ± 6.35, respectively. Average displacement angle recorded was preoperative = 18.58 ± 8.9, 18.57 ± 9.16, immediate postoperative = 7.08 ± 3.02, 7.36 ± 4.6, and final follow up = 8.50 ± 3.20, 9.85 ± 5.95 among groups 1 and 2, respectively. Kyphosis correction loss averaged at the final evaluation was 2.83 ± 1.89 and 3.58 ± 3.260 for groups 1 and 2, respectively. There was no radiologically visible pseudarthrosis, implant failure, or screw breakage in either group at follow up. There was no statistically significant difference in the 2 groups in the radiological outcome (*P* > .05).

Follow-up average VAS score was 2.17 and 2.08 for groups 1 and 2, respectively. Mean ODI score in groups 1 and 2 at final follow up were 65.5 and 54.4, respectively.

Complications found in Group 1 included decubitus ulcer in 2 patients and surgical site infection in 1 patient that required debridement and intravenous antibiotics. One patient in Group 2 developed Grade 2 decubitus ulcer, and 1 patient expired on the second postoperative day due to associated head trauma.

DISCUSSION

Thoracolumbar fracture-dislocations are spinal injuries usually occurring due to high-velocity trauma. According to the AO/ASIF spine fracture classification system,^{8,9} this kind of fracture-dislocation can be categorized as type C. These injuries are highly unstable, as fracture-dislocations are 3-column injuries usually leading to neurological deficit. The mechanism of injury involves a combination of forces, including flexion, extension, shear, torsion, and compression. Treatment of this kind of unstable thoracolumbar fractures is to obtain a reduction of the dislocated segment, restore vertebral body height, decompress the canal, and obtain the most stable fixation.¹⁰⁻¹²

Nonsurgical management of thoracolumbar fractures is often the mainstay of treatment in stable injury patterns. Surgical intervention is often recommended in conditions in which spinal instability is present and this instability may result in loss of acceptable spinal alignment, further neurologic deterioration, or slower mobilization and rehabilitation.¹³ The conservative treatment is not recommended for fracture-dislocations of the spine because there are not only fractures but also various degrees of ligament and disc injury.

The surgical approach for management of fracture-dislocation can be an anterior, combined anterior and posterior, or posterior-alone approach with a short-segment or long-segment construct. The anterior approach is convenient for the

Table 3. Comparison of radiological outcomes between the 2 groups.^a

Radiographic Parameters	Preoperative, mean ± SD,			Postoperative, mean ± SD,			Follow up, mean ± SD,		
	Group 1	Group 2	<i>P</i> Value	Group 1	Group 2	<i>P</i> Value	Group 1	Group 2	<i>P</i> Value
Kyphotic angle	26.17 ± 7.33	16.29 ± 7.56	.3	7.75 ± 5.73	6.93 ± 6.22	.752	11.58 ± 5.19	9.23 ± 7.1	.359
Translation %	26.08 ± 15.2	23.3 ± 13.43	.622	6.50 ± 3.42	8.93 ± 6.15	.237	8.75 ± 3.69	10.38 ± 6.35	.424
Displacement °	18.58 ± 8.9	18.57 ± 9.16	.986	7.08 ± 3.02	7.36 ± 4.6	.868	8.50 ± 3.20	9.85 ± 5.95	.525

^aGroup 1 (n = 12): long-segment posterior instrumentation. Group 2 (n = 14): short-segment posterior instrumentation.

reconstruction of the anterior column, better canal decompression, and intervertebral fusion, but interlocked facet joints in the posterior column cannot be relieved. Additionally, an anterior approach does not provide sufficient longitudinal traction to achieve an adequate reduction.¹⁴ The advantages of a combined anterior and posterior approach are improved sagittal alignment, thorough spinal canal and neural decompression, and easy reduction of dislocation, but it also has difficulties, including more bleeding tissue, trauma, longer operation times, and the need to change position during the surgery.¹⁵ Anterior reconstruction does appear to provide improved resistance to kyphosis compared with posterior stabilization. However, long-segment fixation and the use of index screws in fractured vertebrae have shown improved ability to correct the deformity. No differences in canal decompression and neurologic outcomes have been found between the anterior or posterior approaches. The posterior approach alone has better outcomes for operative time and blood loss.¹⁶

Pedicle screw instrumentation provides 3-column fixation to control axial, translational, and rotational displacements.^{17,18} Simultaneous corrective forces can be applied in axial compression or distraction, flexion or extension, and in rotational, coronal, and sagittal translation.^{3,8,10,13–16,18,19} Long-segment posterior instrumentation was considered the mainstay of surgical treatment of these highly unstable injuries. The main principle behind long-segment fixation (2 levels above and 2 levels below) was to achieve multiple fixation points so as to distribute stress while achieving and maintaining reduction and alignment of the spine.²⁰ However, this procedure causes loss of motion segments. Therefore, to save motion segments, short-segment fixation was tried. Various studies exist in the literature comparing long and short instrumented stabilization for thoracolumbar burst fractures,^{14,21–23} but studies have been limited in cases of fracture-dislocation. Moreover, defining the extent of fixation short or long is also controversial, as fracture-dislocation occurs between 2 levels. In our study, we have considered posterior fixation with pedicle screws 2 levels above and 2 levels below the dislocation level as long-segment fixation and fixation less than 2 levels above or below as short-segment fixation. This is particularly in cases where fracture-dislocation involves posterior elements and pedicles of fractured vertebrae where the placement

of index screws in both the injured vertebrae of the fracture-dislocation level becomes difficult.

Yu et al²⁴ (2002), in a retrospective study on 20 patients of thoracolumbar (n = 14) or lumbar fracture-dislocations (n = 6) treated with short-segment posterior instrumentation, reported a complication rate of 60% with short-segment posterior fixation. Poor initial postoperative alignment due to short-segment fixation mainly in the lumbar spine was considered as the most important factor for failure.

Sodhi et al²⁵ (2017) analyzed 91 patients with thoracolumbar fractures treated with short-segment posterior fixation retrospectively and concluded statistically significant factors contributing to failure included the presence of a burst fracture, a preoperative load-sharing classification score >6, and translation/dislocation.

Chen et al⁷ (2017) compared the outcomes of long-segment (2 levels above and 2 levels below) or short-segment posterior fixation (1 level above and 1 below, and included the fractured vertebra itself) and anterior fusion in both groups in 16 patients of lumbar split fracture-dislocation and reported better outcomes in terms of intraoperative blood loss and operative time for the short-segment group than the long-segment group with no difference in radiological and neurological outcomes between the 2 groups.

Authors of various studies^{3–5} on burst fractures have supported the use of index screws in fractured vertebrae, which provide an additional anchor during the reduction maneuver and help in the correction of deformity through vertebral endplate augmentation. Few studies have reported the use of index screws along with short-segment constructs in cases of fracture-dislocations. Chokshi et al⁶ (2019) treated 50 patients with thoracolumbar fracture-dislocation with short-segment construct and index screws. They concluded that inclusion of the fracture level in short-segment fixation for thoracolumbar fracture-dislocation with McCormack load-sharing score ≤ 6 gives good kyphosis correction and maintenance.

Blood loss in our short-segment group (Group 1; 478.6 ± 112.2 mL) was comparable to Choksi et al⁶ (394.8 mL) and Chen et al⁷ (730 mL; range, 430–950 mL). Similarly, duration of 3.21 ± 0.54 hours was also similar to the previous 2 studies, 1.57 hours and 4 hours (range, 3.33–5 hours) respectively. Blood loss and operative time in our study were less in the

short-segment fixation group than the long-segment fixation group.

In our study, we found that there were no statistically significant differences in radiological outcomes with regard to local kyphosis, translation percentage, and displacement angle by either of the methods of fixation at the final follow up. Choksi et al⁶ and Chen et al⁷ also showed good deformity correction after short-segment fixation. No cases of implant failure, pseudoarthrosis, or screw breakage occurred in either group in our study.

CONCLUSIONS

In our experience, short-segment fixation can be used for treating thoracolumbar fracture-dislocation, as it is associated with less blood loss, decreased intraoperative time, and it further saves fusion segments with similar radiological and clinical outcomes as long-segment fixation. Long-segment fixation can be reserved in cases where inserting pedicle screws in fractured vertebrae (index screws) becomes difficult due to loss of integrity of posterior elements and pedicles at the fracture-dislocation level. A small number of patients in each group and short duration of follow up were limitations of our study.

REFERENCES

- Pasapula C, Wilson-MacDonald J. (ii) Thoraco-lumbar fractures. *Orthop Trauma*. 2004;18(1):17–25. doi:10.1016/j.cuor.2004.02.008
- Wang F, Zhu Y. Treatment of complete fracture-dislocation of thoracolumbar spine. *J Spinal Disord Tech*. 2013;26(8):421–426. doi:10.1097/BSD.0b013e31824e1223
- Güven O, Kocaoglu B, Bezer M, Aydın N, Nalbantoglu U. The use of screw at the fracture level in the treatment of thoracolumbar burst fractures. *J Spinal Disord Tech*. 2009;22(6):417–421. doi:10.1097/BSD.0b013e3181870385
- Dobran M, Nasi D, Brunozzi D, et al. Treatment of unstable thoracolumbar junction fractures: short-segment pedicle fixation with inclusion of the fracture level versus long-segment instrumentation. *Acta Neurochir (Wien)*. 2016;158(10):1883–1889. doi:10.1007/s00701-016-2907-0
- Mahar A, Kim C, Wedemeyer M, et al. Short-segment fixation of lumbar burst fractures using pedicle fixation at the level of the fracture. *Spine*. 2007;32(14):1503–1507. doi:10.1097/BRS.0b013e318067dd24
- Chokshi JJ, Shah M. Outcomes of including fracture level in short-segment fixation for thoracolumbar fracture dislocation. *Asian Spine J*. 2019;13(1):56–60. doi:10.31616/asj.2018.0064
- Chen F, Kang Y, Li H, et al. Treatment of lumbar split fracture-dislocation with short-segment or long-segment posterior fixation and anterior fusion. *Clin Spine Surg*. 2017;30(3):E310–E316. doi:10.1097/BSD.0000000000000182
- Magerl F, Aebi M, Gertzbein SD, Harms J, Nazarian S. A comprehensive classification of thoracic and lumbar injuries. *Eur Spine J*. 1994;3(4):184–201. doi:10.1007/BF02221591
- Aebi M. Classification of thoracolumbar fractures and dislocations. *Eur Spine J*. 2010;19(Suppl 1):2–7. doi:10.1007/s00586-009-1114-6
- Alanay A, Acaroglu E, Yazici M, Ozgur A, Surat A. Short-segment pedicle instrumentation of thoracolumbar burst fractures: does transpedicular intracorporeal grafting prevent early failure? *Spine*. 2001;26(2):213–217. doi:10.1097/00007632-200101150-00017
- Alvine GF, Swain JM, Asher MA, Burton DC. Treatment of thoracolumbar burst fractures with variable screw placement or Isola instrumentation and arthrodesis: case series and literature review. *J Spinal Disord Tech*. 2004;17(4):251–264. doi:10.1097/01.bsd.0000095827.98982.88
- Briem D, Lehmann W, Ruecker AH, Windolf J, Rueger JM, Linhart W. Factors influencing the quality of life after burst fractures of the thoracolumbar transition. *Arch Orthop Trauma Surg*. 2004;124(7):461–468. doi:10.1007/s00402-004-0710-5
- Singh K, Vaccaro AR, Eichenbaum MD, Fitzhenry LN. The surgical management of thoracolumbar injuries. *J Spinal Cord Med*. 2004;27(2):95–101. doi:10.1080/10790268.2004.11753737
- Parker JW, Lane JR, Karaikovic EE, Gaines RW. Successful short-segment instrumentation and fusion for thoracolumbar spine fractures: a consecutive 41/2-year series. *Spine*. 2000;25(9):1157–1170. doi:10.1097/00007632-200005010-00018
- Suk S-I, Kim J-H, Lee S-M, Chung E-R, Lee J-H. Anterior-posterior surgery versus posterior closing wedge osteotomy in posttraumatic kyphosis with neurologic compromised osteoporotic fracture. *Spine*. 2003;28(18):2170–2175. doi:10.1097/01.BRS.0000090889.45158.5A
- Bronson WH, Vaccaro AR. Is there a role for anterior augmentation in thoracolumbar burst fractures? *Indian Spine J*. 2018;1:86–93.
- Luque ER. The anatomic basis and development of segmental spinal instrumentation. *Spine*. 1982;7(3):256–259. doi:10.1097/00007632-198205000-00010
- McAfee PC, Farey ID, Sutterlin CE, Gurr KR, Warden KE, Cunningham BW. 1989 Volvo Award in basic science. Device-related osteoporosis with spinal instrumentation. *Spine*. 1989;14(9):919–926. doi:10.1097/00007632-198909000-00003
- Mikles MR, Stecher RP, Graziano GP. Posterior instrumentation for thoracolumbar fractures. *J Am Acad Orthop Surg*. 2004;12(6):424–435. doi:10.5435/00124635-200411000-00007
- McLain RF. The biomechanics of long versus short fixation for thoracolumbar spine fractures. *Spine*. 2006;31(11 Suppl):S70–79; discussion S104. doi:10.1097/01.brs.0000218221.47230.dd
- Knop C, Bastian L, Lange U, Oeser M, Zdichavsky M, Blauth M. Complications in surgical treatment of thoracolumbar injuries. *Eur Spine J*. 2002;11(3):214–226. doi:10.1007/s00586-001-0382-6
- Tezeren G, Kuru I. Posterior fixation of thoracolumbar burst fracture: short-segment pedicle fixation versus long-segment instrumentation. *J Spinal Disord Tech*. 2005;18(6):485–488. doi:10.1097/01.bsd.0000149874.61397.38
- Altay M, Ozkurt B, Aktekin CN, Ozturk AM, Dogan O,

Tabak AY. Treatment of unstable thoracolumbar junction burst fractures with short- or long-segment posterior fixation in magerl type a fractures. *Eur Spine J.* 2007;16(8):1145–1155. doi:10.1007/s00586-007-0310-5

24. Yu S-W, Fang K-F, Tseng I-C, Chiu Y-L, Chen Y-J, Chen W-J. Surgical outcomes of short-segment fixation for thoracolumbar fracture dislocation. *Chang Gung Med J.* 2002;25(4):253–259.

25. Sodhi HBS, Savardekar AR, Chauhan RB, Patra DP, Singla N, Salunke P. Factors predicting long-term outcome after short-segment posterior fixation for traumatic thoracolumbar fractures. *Surg Neurol Int.* 2017;8:233. doi:10.4103/sni.sni_244_17

Disclosures and COI: The authors received no funding for this study and report no conflicts of interest. We conducted our study after obtaining institutional ethical clearance from the Ethical Committee of AIIMS Rishikesh, India. I certify

that all applicable institutional and governmental regulations concerning the ethical use of human volunteers were followed throughout this research.

Corresponding Author: Pankaj Kandwal, MS, Department of Orthopaedics, AIIMS Rishikesh, Uttarakhand, India 249203. Phone: +918475000282; Fax: +911352462941; Email: pankaj.orth@aiimsrishikesh.edu.in, pankajkandwal27@gmail.com.

Published 0 Month 2021

This manuscript is generously published free of charge by ISASS, the International Society for the Advancement of Spine Surgery. Copyright © 2021 ISASS. To see more or order reprints or permissions, see <http://ijssurgery.com>.