

## Proximal Junctional Spondylodiscitis Following Adult Spinal Deformity Surgery: Case Series and Review of the Literature

Joseph R. Mendelis, Nicole J. Hung, Vedat Deviren, Christopher P. Ames, Aaron J. Clark and Alekos A. Theologis

*Int J Spine Surg* published online 13 July 2022  
<https://www.ijssurgery.com/content/early/2022/07/01/8327>

This information is current as of June 5, 2025.

---

**Email Alerts** Receive free email-alerts when new articles cite this article. Sign up at:  
<http://ijssurgery.com/alerts>

# Proximal Junctional Spondylodiscitis Following Adult Spinal Deformity Surgery: Case Series and Review of the Literature

JOSEPH R. MENDELIS, MD<sup>1\*</sup>; NICOLE J. HUNG, BA<sup>1\*</sup>; VEDAT DEVIREN, MD<sup>1</sup>; CHRISTOPHER P. AMES, MD<sup>2</sup>; AARON J. CLARK, MD, PhD<sup>2</sup>; AND ALEKOS A. THEOLOGIS, MD<sup>1</sup>

<sup>1</sup>Department of Orthopaedic Surgery, University of California San Francisco, San Francisco, California, USA; <sup>2</sup>Department of Neurological Surgery, University of California San Francisco, San Francisco, California, USA

\*Joseph R. Mendelis and Nicole J. Hung contributed equally to the work.

## ABSTRACT

**Background:** Proximal junctional failure (PJF) following multilevel thoracolumbar instrumented to the pelvis for adult spinal deformity (ASD) is relatively uncommon but considerably disabling. While the leading etiology is mechanical, other rarer etiologies can play a role in its development. The purpose of this study was to present a case series of ASD patients who experienced PJF secondary to proximal junctional spondylodiscitis (PJS) after long-segment thoracolumbar posterior instrumented fusions.

**Methods:** Adult patients who underwent posterior instrumented fusions at a single academic center between 2017 and 2020 and subsequently developed PJF were retrospectively reviewed. Patient demographics, operative details, clinical presentation, culture data, and management approach were evaluated.

**Results:** Three patients developed PJF and were included for analysis (mean age 67 years [range, 58–76]; women: 2). Indication for all index operations was symptomatic ASD after failed conservative management. Clinical presentation ranged from mild back pain to severe neurological compromise. Average time to infection and PJF after the index procedure was 11 months (range, 3 months–2 years). All 3 patients were successfully managed with urgent revision surgery including surgical debridement and postoperative antibiotics.

**Conclusion:** PJF is a rare yet potentially devastating complication following long-segment posterior thoracolumbar instrumented fusions for ASD. It is critical that surgeons maintain a high index of suspicion of infection when managing PJF given the potential neurological morbidity of PJF.

**Clinical Relevance:** This report highlights a rare but important cause of PJF following ASD surgery. It is critical that one maintains a high index of suspicion of infection when managing PJF.

**Level of Evidence:** 4.

Complications

Keywords: proximal junctional spondylodiscitis, proximal junctional failure, proximal junctional kyphosis, adult spinal deformity, infection

## INTRODUCTION

Proximal junctional kyphosis (PJK) and proximal junctional failure (PJF) are well-described complications following long thoracolumbar posterior spinal instrumented fusions for treatment of adult spinal deformity (ASD).<sup>1–3</sup> While PJK was originally defined as a radiologic finding, it has more recently been understood as a spectrum of clinical diagnoses that can lead to significant pain and disability.<sup>4–7</sup> Although there is currently no consensus definition of PJF, 2 proposed definitions exist: the first as any case of PJK requiring revision surgery and the second as PJK with structural failure of the posterior osseoligamentous complex and/or vertebral body.<sup>8–10</sup> Commonly identified mechanisms

leading to PJF include trauma, instrumentation pullout, fracture, and soft tissue failure.<sup>3,9–12</sup>

While there is a large body of literature dedicated to PJK and PJF following ASD surgery, there are limited published reports of proximal junctional spondylodiscitis (PJS) leading to PJK/PJF.<sup>12–17</sup> In this study, we present a series of 3 patients diagnosed with PJF following long posterior spinal instrumented fusions for ASD.

## METHODS

The medical records of 3 adult patients who underwent posterior instrumented fusions between 2017 and 2020 and subsequently developed PJF were

**Table.** Demographic and clinical summary of presented cases of proximal junctional spondylodiscitis.

	Case 1	Case 2	Case 3
Age, y	58	68	76
Gender	Female	Male	Female
Comorbidities	Anemia, scoliosis	Anterior cervical discectomy and fusion, asthma, hypertension	Chronic obstructive pulmonary disease, rheumatoid arthritis, PE, chronic deep vein thrombosis
Index operation	ALIF L3-L4, L4-L5, L5-S1 T4-pelvis PSIF, PCOs T6-S1, posterior ligamentous repair T3-T5	ALIF L4-L5, L5-S1 T10-pelvis, PCOs T12-S1, vertebroplasty of T9 and T10, posterior ligamentous repair T9-T11	T11-L5 PSIF and ALIF L5-S1 (performed at outside hospital)
Presenting symptoms	Significant back pain, difficulty with ambulation, bowel/bladder incontinence	Back pain	T10 sensory level, bilateral lower extremity weakness, severe back pain
Preoperative infectious laboratory findings	None	WBC 7.6, platelets 538, erythrocyte sedimentation rate 46, CRP 14.7	WBC 13.5, CRP 71.4
Proximal junctional pathology	Instrumentation pullout proximal junction; increased T2 signal in proximal junctional disc (T3-T4)	Pathologic fracture at UIV +1, epidural abscess	Pathologic fractures at upper instrumented vertebra, UIV +1, incomplete spinal cord injury
Time to infection/proximal junctional failure	3 mo	2 y	6 mo
Microbiology	<i>Staphylococcus aureus</i>	No growth	Methicillin-resistant <i>S aureus</i>

Abbreviations: ALIF, anterior lumbar interbody fusion; CRP, C-reactive protein; PCO, posterior column osteotomy; PE, pulmonary embolism; PJS, proximal junctional spondylodiscitis; PSIF, posterior spinal instrumentation and fusion; UIV +1, unfused adjacent segment; UIV, upper instrumented vertebra; WBC, white blood cell count.

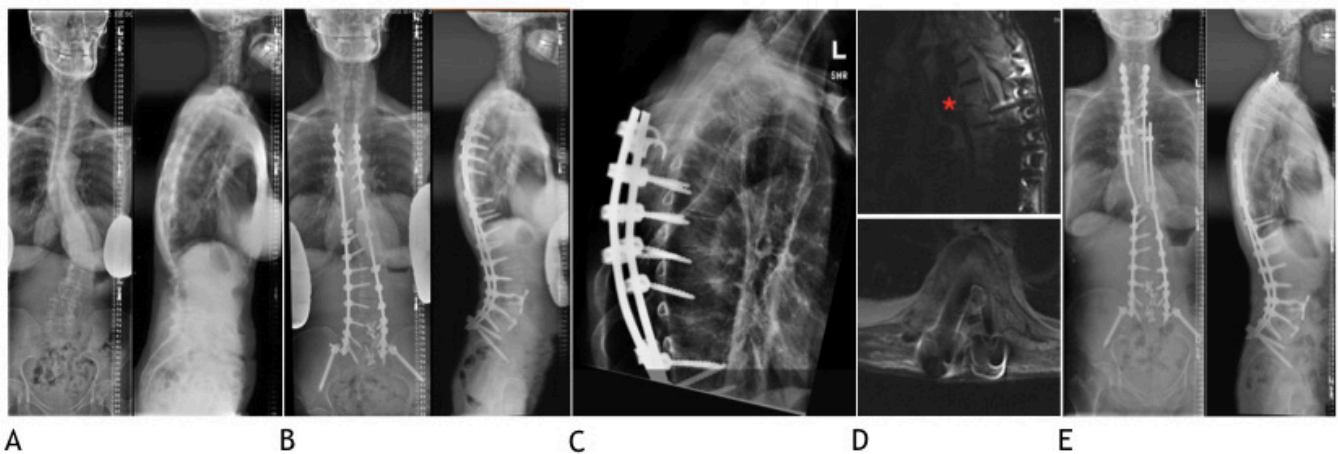
retrospectively reviewed. Indication for all 3 index procedures was symptomatic ASD after failed conservative management. Details of each case are presented below and summarized in the Table.

### Case 1

A 58-year-old woman with a past medical history of anemia and scoliosis presented with chronic, severe worsening back pain and sagittal imbalance secondary to adult idiopathic scoliosis (Figure 1). She underwent anterior lumbar interbody fusion at L3-L4, L4-L5, and L5-S1 followed by a posterior instrumented fusion from T4 to S1 with bilateral iliac fixation, iliac crest autogenous bone graft, posterior column osteotomies from T6 to S1, and a posterior ligamentous repair from T3 to T5 in a staged manner (Figure 1). Her surgical wound was closed by the plastic surgery service with bilateral

paraspinous muscle flap advancements. There were no complications, and her initial postoperative course was uncomplicated. She was discharged home on hospital day 13.

Three months after her index operation, she presented to the emergency room with significant back pain and difficulty with ambulation. This progressed to bilateral lower extremity weakness with episodes of bowel and bladder incontinence. Radiographs and computed tomography imaging at that time were notable for PJK with instrumentation failure (Figure 1), and magnetic resonance imaging (MRI) revealed thoracic spinal cord compression secondary to instrumentation migration (Figure 1). Preoperative laboratory results were notable for a white blood cell count (WBC) of 7.3 (normal range, 3.4–10.0). As infection was not considered at that time, no inflammatory markers were drawn.



**Figure 1.** Preoperative (A) and initial standing postoperative radiographs (B). Follow-up radiographs demonstrating proximal junctional failure (C). T2 magnetic resonance image with metal artifact suppression demonstrating instrumentation failure with pedicle screw in the spinal canal (D). Note increased signal in the proximal junctional disc space (asterisk) (D). Standing radiographs at final follow-up (E).

Due to instrumentation failure causing acute neurologic deficit, urgent revision surgery was indicated. To address the PJK/PJF and neurological symptoms, she underwent removal of instrumentation and extension of fusion to C7.

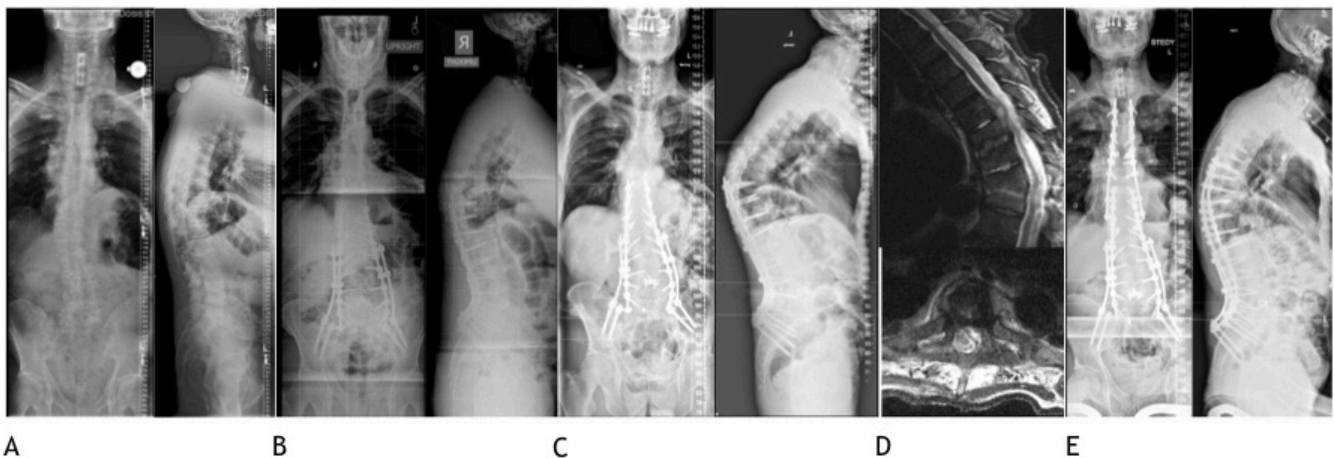
Intraoperatively, after dissection was carried down to bone at the superior aspect of her previously placed instrumentation, gross purulent material was noted and cultures were obtained. The wound was copiously irrigated, and revision instrumentation was placed. The wound was closed with a plan to return to the operating room after a course of antibiotics for a full debridement and definitive closure with the plastic surgery team, as the surgical team was not prepared to definitively manage the incidentally found infection at that time. Retrospective review of the preoperative MRI was notable for increased signal in the T3-T4 disc (Figure 1D). Six days later, the patient was taken back to the operating room for a formal debridement and complex wound closure by plastic surgery. All cultures from the surgical site grew *Staphylococcus aureus*. After consultation with the infectious disease service, she was treated with oral rifampin and 2 weeks of intravenous cefazolin followed by oral ciprofloxacin for a total of 12 weeks. Her final radiographs showed no evidence of instrumentation complication (Figure 1). At 1 year follow-up, she was without recurrence of infection, and her neurological status was normal.

### Case 2

A 68-year-old man with a past medical history of an anterior cervical discectomy and fusion, asthma, and hypertension presented with 1 year of worsening severe back pain, degenerative disc disease, and

degenerative scoliosis that failed conservative management (Figure 2). He underwent a posterior spinal instrumented fusion from T10 to sacrum with bilateral iliac fixation, iliac crest autogenous bone graft, posterior column osteotomies from T12 to S1, vertebroplasty of T9 and T10, and a posterior ligamentous repair from T9 to T11 followed by an anterior lumbar interbody fusion at L4-L5 and L5-S1 in a staged manner (Figure 2). There were no complications. His postoperative course was uneventful, and he was discharged home on the sixth hospital day.

One year before presentation, he reportedly had an infection involving his cervical spine instrumentation requiring admission at an outside hospital, and he was treated with intravenous cefazolin. Approximately 11 months ago, he reported new-onset thoracic back pain that worsened 1 month prior to presentation. He was undergoing medical workup for an aortic aneurysm when T7-T8 endplate irregularity and soft tissue swelling concerning for spondylodiscitis were incidentally found. Radiographs at that time were notable for PJK with a compression fracture at the T9 and T10 levels (Figure 2). MRI was notable for increased T2 signal in the T7-T8, T8-T9, and T9-T10 disc spaces as well as endplate irregularity and T7-T8 concerning for spondylodiscitis (Figure 2). There was additionally a contrast enhancing epidural fluid collection ventrally and to the left of the spinal cord causing mass effect on the spinal cord from T6 to T7 (Figure 2). At the time of imaging at an outside hospital, he was started on antibiotics. He was then transferred to our hospital, at which time he reported midthoracic back pain but denied constitutional and neurologic symptoms. Preoperative laboratory results were notable for the following: WBC was



**Figure 2.** Preoperative (A) and initial standing postoperative radiographs (B). Follow-up radiographs demonstrating proximal junctional failure (C). T2 magnetic resonance image demonstrating T9 and T10 compression fractures and discitis at T7-T8 and T8-T9 with adjacent epidural abscess (D). Standing radiographs at final follow-up (E).

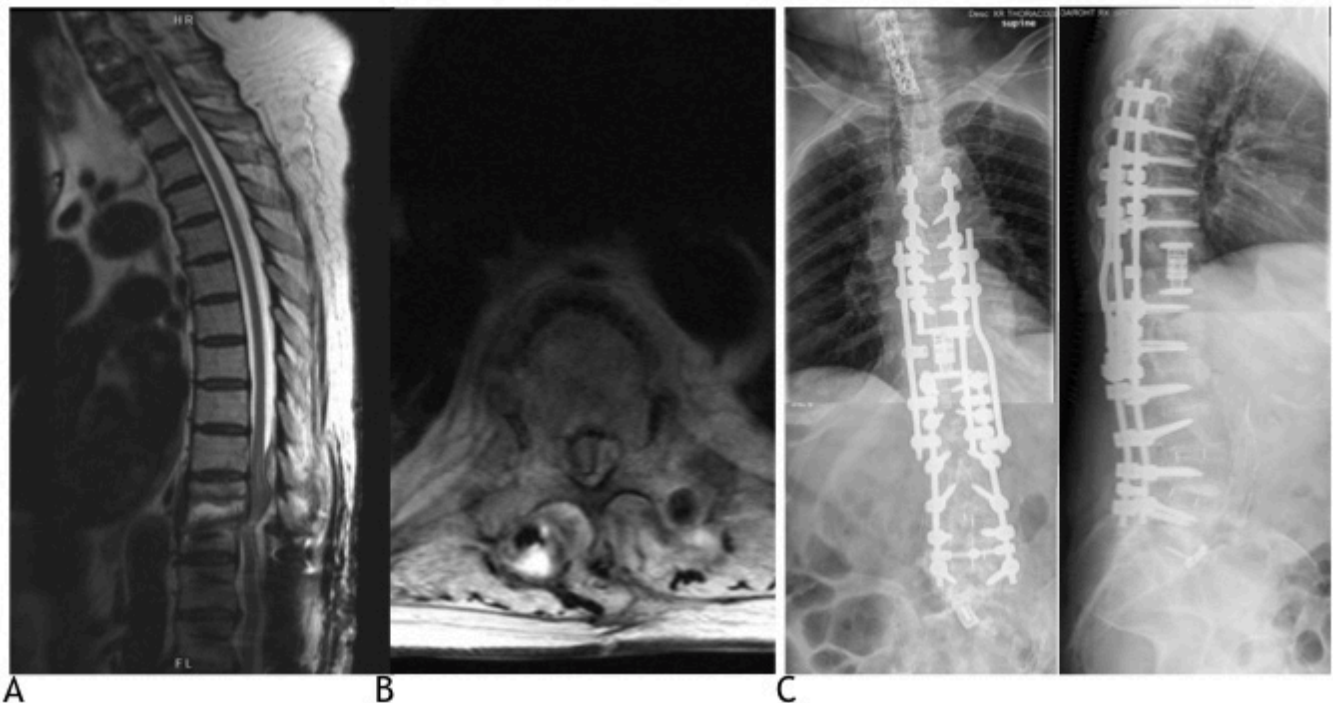


7.6 (normal range, 3.4–10.0); platelets, 538 (normal range, 140–450); erythrocyte sedimentation rate, 46 (normal range, <10); and C-reactive protein (CRP), 14.7 (normal range, <5.1). Blood cultures demonstrated no growth. Revision surgery was indicated, and he was taken to the operating room where he underwent removal of his proximal instrumentation, T6-T10 laminectomy and debridement of abscess, and extension of his spinal fusion to the T4 level with complex wound closure by plastic surgery. His postoperative cultures showed no growth, which was thought to be related to preoperative administration of antibiotics. His postoperative course was notable for the drainage of clear fluid from a portion of his wound that resolved without surgical intervention. Samples of the drainage did not grow any organisms. Despite negative cultures, he was treated empirically with intravenous vancomycin and ceftriaxone for 6 weeks followed by indefinite suppression with minocycline. At 3-month follow-up, he was without back pain, his incision was healed, CRP was normalized (4.0; normal range, <5.1), and radiographs showed no evidence of instrumentation failure (Figure 2).

### Case 3

A 76-year-old woman with a medical history of chronic obstructive pulmonary disease, rheumatoid

arthritis, pulmonary embolism, and chronic right femoral deep vein thrombosis presented as a transfer from an outside hospital. Her surgical history was notable for posterior spinal instrumented fusion from T11 to L5 with an L5-S1 anterior lumbar interbody fusion 6 months prior to presentation. Three months prior to presentation, she reported severe back pain. On arrival, she had severe back pain that was present with sitting upright and relieved when laying down. Presenting laboratory results were notable for the following: WBC was 13.5 (normal range, 3.4–10.0); platelets, 354 (normal range, 140–450); and CRP, 71.4 (normal range, <7.5). Blood cultures demonstrated no growth. MRI demonstrated PJF from vertebral fractures at T10 and T11, T10-T11 disc erosion and increased T2 signal, and dorsal epidural fluid collection from T9 to T12 causing severe epidural spinal cord compression (Figure 3). She had an incomplete spinal cord injury (ASIA B) consisting of a T10 sensory level and profound bilateral lower extremity weakness (0 out of 5 strength in iliopsoas, quadriceps, and toe and foot dorsiflexors and plantarflexors). Given her mechanical instability, need for source control, and incomplete spinal cord injury, she was indicated for revision surgery to include removal of instrumentation from T11 to T12, laminectomy with complete facetectomies from T9 to T12, complete resection of the T10 and T11 vertebral bodies via a lateral



**Figure 3.** Sagittal (A) and axial (B) T2 magnetic resonance images on presentation demonstrating discitis with osteomyelitis and epidural abscess of T10 and T11. Initial postoperative supine radiographs (C).

extracavitary approach, anterior column reconstruction with an expandable titanium cage, and revision posterior fusion to the T5 level (Figure 3). Intraoperative cultures grew methicillin-resistant *S aureus*. Her postoperative course was complicated by the development of a sacral ulcer requiring operative debridement with cultures consistent with a polymicrobial infection. She was treated with intravenous daptomycin and meropenem with oral rifabutin. She was discharged to a skilled nursing facility on hospital day 28. Neurological examination on discharge and during follow-up was stable. Unfortunately, she died approximately 1 year after surgery of cardiac arrest secondary to COVID-19 infection.

## DISCUSSION

PJK and PJF are well-recognized complications following long posterior thoracolumbar fusion with instrumentation for treatment of ASD.<sup>2,4-6</sup> While PJK is a progressive process that captures a spectrum of clinical presentations, acute PJF is a distinct diagnosis that is particularly dangerous given the potential for severe neurological injury. The incidence of PJF following surgical management of ASD ranges from 1.4% to 5.6%.<sup>10,15</sup> Hart et al identified fracture as the most common cause of PJF (56%) followed by soft tissue failure (35%) and screw pullout (9%).<sup>12</sup> Hostin et al found significant associations between fracture and acute PJF in the thoracolumbar region ( $P = 0.00$ ) and soft tissue failure and acute PJF in the upper thoracic region ( $P < 0.02$ ).<sup>10</sup>

Infection has rarely been discussed as a cause of PJF following ASD surgery. Currently, there are 3 published studies that describe PJS leading to PJF: a case report presenting a single patient who developed spondylodiscitis after pedicle subtraction osteotomy for sagittal imbalance, a case series of 2 immunosuppressed patients who developed tuberculous spondylodiscitis leading to PJK, and a case series of 2 patients who presented with PJF accompanied by delayed infection after T10-pelvis posterior instrumented fusions for ASD.<sup>16-18</sup> To our knowledge, our study is the largest case series describing PJF secondary to PJS following long posterior thoracolumbar fusion with instrumentation for management of ASD. Our series, similar to that by Iwami et al,<sup>18</sup> is unique in that all patients were immunocompetent.

Although PJF is considered to be an early postoperative complication, our series suggests that the timing of presentation of PJF secondary to PJS is perhaps more varied. Previous studies noted that PJF was diagnosed

on an average of 3 months after surgery with revision surgery occurring within 7 months after the index operation, if necessary.<sup>10</sup> Yagi et al found that the mean time to revision surgery after PJF was 10 months with 87% of revisions occurring within 2 years postoperatively.<sup>15</sup> In our series, we observed variable timing in the presentation of PJF secondary to PJS, with patients presenting at 3 months, 6 months, and 2 years after their index operations. Despite the delayed presentations, urgent operative intervention occurred after diagnosis of infection in each case. Furthermore, in Mallepally et al's case series of 2 patients with PJF secondary to tuberculous spondylodiscitis, both patients presented 4 months after initial thoracolumbar instrumentation for osteoporotic vertebral fractures.<sup>16</sup> Formica et al reported a more acute presentation of a single patient who presented with spondylodiscitis 6 weeks after an index operation for treatment of ASD.<sup>17</sup> In the case series by Iwami et al, the patients presented 12 and 13 months postoperatively with PJF and associated discitis/osteomyelitis.<sup>18</sup> These combined cases suggest that with an infectious cause of PJF, patients may present in a variable and delayed fashion, but revision surgery may occur in a similar timeframe compared with PJF secondary to more established causes. Additionally, that all our patients' neurological examinations remained stable and/or improved after surgery support an early surgical approach to avoid neurologic deterioration, particularly since the infection is at cord level.

Possible etiologies of PJS include hematogenous seeding, direct infection of instrumentation, and local spread. While we could not determine the exact causes of infection in our series, we observed certain associations. In case 1, PJS was associated with instrumentation infection. Given the intraoperative gross purulence observed adjacent to prior instrumentation, positive surgical site cultures for *S aureus*, and retrospective review of preoperative imaging showing increased signal at the proximal junctional intervertebral disc, it is likely that spondylodiscitis and instrumentation infection existed concomitantly. However, it is unclear whether the instrumentation infection or the proximal junctional intervertebral disc was the primary nidus of infection.

In case 2, PJS was accompanied by an epidural abscess and pathologic fracture of the unfused adjacent segment (UIV +1). Additionally, the patient had a history of cervical spine instrumentation infection the year prior to presentation. The delayed, occult presentation (incidental finding 2 years after index operation) and spondylodiscitis observed are suggestive of latent infection due to hematogenous seeding. Bose discussed

hematogenous seeding of low-virulence organisms as a mechanism of delayed infection following spinal instrumentation particularly with remote history of infection.<sup>19</sup>

In case 3, there were pathological fractures of the upper instrumented vertebra and UIV +1 and spondylodiscitis of the UIV +1 intervertebral disc. UIV +1 fractures are thought to result from increased stress concentration on unfused segments.<sup>1</sup> This stress concentration phenomenon could also explain higher infectious risk through hematogenous seeding, as Formica et al hypothesized that increased biomechanical stresses at the proximal junctional intervertebral disc may lead to hyperemia and thus higher infectious risk.<sup>17</sup> It is possible that this case also resulted from hematogenous seeding.

## CONCLUSIONS

While rare, PJS can be a devastating complication following long posterior instrumented fusions for ASD. PJK and PJF secondary to PJS can present in a delayed and variable fashion that extends beyond the acute postoperative period that typically characterizes PJF. Its presence may be associated with neurologic deficit from pathologic fracture or epidural abscess, which may both require urgent surgical intervention. While infection may become apparent during preoperative workup of PJF, this may not always be the case as imaging findings such as fracture-associated T2 hyperintensity on MRI may make the diagnosis of infection more difficult. Given possible occult presentation and high potential morbidity of PJS, we suggest that surgeons maintain a high level of suspicion for infection when encountering PJF, including obtaining MRI with contrast and infectious markers, as well as taking an early surgical approach to avoid neurologic deterioration.

## REFERENCES

1. Watanabe K, Lenke LG, Bridwell KH, Kim YJ, Koester L, Hensley M. Proximal junctional vertebral fracture in adults after spinal deformity surgery using pedicle screw constructs: analysis of morphological features. *Spine (Phila Pa 1976)*. 2010;35(2):138–145. doi:10.1097/BRS.0b013e3181c8f35d
2. Park P, Garton HJ, Gala VC, Hoff JT, McGillicuddy JE. Adjacent segment disease after lumbar or lumbosacral fusion: review of the literature. *Spine (Phila Pa 1976)*. 2004;29(17):1938–1944. doi:10.1097/01.brs.0000137069.88904.03
3. DeWald CJ, Stanley T. Instrumentation-related complications of multilevel fusions for adult spinal deformity patients over age 65: surgical considerations and treatment options in patients with poor bone quality. *Spine (Phila Pa 1976)*. 2006;31(19 Suppl):S144–S151. doi:10.1097/01.brs.0000236893.65878.39
4. Glattes RC, Bridwell KH, Lenke LG, Kim YJ, Rinella A, Edwards C 2nd. Proximal junctional kyphosis in adult spinal deformity following long instrumented posterior spinal fusion: incidence, outcomes, and risk factor analysis. *Spine (Phila Pa 1976)*. 2005;30(14):1643–1649. doi:10.1097/01.brs.0000169451.76359.49
5. Hassanzadeh H, Gupta S, Jain A, El Dafrawy MH, Skolasky RL, Kebaish KM. Type of anchor at the proximal fusion level has a significant effect on the incidence of proximal junctional kyphosis and outcome in adults after long posterior spinal fusion. *Spine Deform*. 2013;1(4):299–305. doi:10.1016/j.jspd.2013.05.008
6. Kim HJ, Bridwell KH, Lenke LG, et al. Proximal junctional kyphosis results in inferior SRS pain subscores in adult deformity patients. *Spine (Phila Pa 1976)*. 2013;38(11):896–901. doi:10.1097/BRS.0b013e3182815b42
7. Kim HJ, Bridwell KH, Lenke LG, et al. Patients with proximal junctional kyphosis requiring revision surgery have higher postoperative lumbar lordosis and larger sagittal balance corrections. *Spine (Phila Pa 1976)*. 2014;39(9):E576–80. doi:10.1097/BRS.0000000000000246
8. Lau D, Clark AJ, Scheer JK, et al. Proximal junctional kyphosis and failure after spinal deformity surgery: a systematic review of the literature as a background to classification development. *Spine (Phila Pa 1976)*. 2014;39(25):2093–2102. doi:10.1097/BRS.0000000000000627
9. Hart R, McCarthy I, O'Brien M, et al. Identification of decision criteria for revision surgery among patients with proximal junctional failure after surgical treatment of spinal deformity. *Spine (Phila Pa 1976)*. 2013;38(19):E1223–7. doi:10.1097/BRS.0b013e31829fedde
10. Hostin R, McCarthy I, O'Brien M, et al. International spine study group incidence, mode, and location of acute proximal junctional failures after surgical treatment of adult spinal deformity. *Spine (Phila Pa 1976)*. 2013;38(12):1008–1015. doi:10.1097/BRS.0b013e318271319c
11. O'Leary PT, Bridwell KH, Lenke LG, et al. Risk factors and outcomes for catastrophic failures at the top of long pedicle screw constructs: a matched cohort analysis performed at a single center. *Spine (Phila Pa 1976)*. 2009;34(20):2134–2139. doi:10.1097/BRS.0b013e3181b2e17e
12. Hart RA, McCarthy I, Ames CP, Shaffrey CI, Hamilton DK, Hostin R. Proximal junctional kyphosis and proximal junctional failure. *Neurosurg Clin N Am*. 2013;24(2):213–218. doi:10.1016/j.nec.2013.01.001
13. Kim YJ, Bridwell KH, Lenke LG, Glattes CR, Rhim S, Cheh G. Proximal junctional kyphosis in adult spinal deformity after segmental posterior spinal instrumentation and fusion: minimum five-year follow-up. *Spine (Phila Pa 1976)*. 2008;33(20):2179–2184. doi:10.1097/BRS.0b013e31817c0428
14. Kim HJ, Lenke LG, Shaffrey CI, Van Alstyne EM, Skelly AC. Proximal junctional kyphosis as a distinct form of adjacent segment pathology after spinal deformity surgery: a systematic review. *Spine (Phila Pa 1976)*. 2012;37(22 Suppl):S144–64. doi:10.1097/BRS.0b013e31826d611b
15. Yagi M, Rahm M, Gaines R, et al. Characterization and surgical outcomes of proximal junctional failure in surgically treated patients with adult spinal deformity. *Spine (Phila Pa 1976)*. 2014;39(10):E607–14. doi:10.1097/BRS.0000000000000266
16. Mallepally AR, Tandon V, Chhabra HS. Adjacent level tuberculous spondylodiscitis leading to proximal junctional kyphosis: rare

and unusual presentation. *World Neurosurg.* 2020;134:e808–e814. doi:10.1016/j.wneu.2019.11.007

17. Formica M, Cavagnaro L, Zanirato A, Felli L, Formica C. Proximal junctional spondylodiscitis after pedicle subtraction osteotomy. *Spine J.* 2016;16(2):e49-51. doi:10.1016/j.spinee.2015.09.050

18. Iwami T, Yagi M, Okada E, et al. A rare case of proximal junctional failure with delayed infection after adult spinal deformity surgery: A report of two cases. *Case Rep Orthop.* 2020;2020. doi:10.1155/2020/8883828

19. Bose B. Delayed infection after instrumented spine surgery: case reports and review of the literature. *Spine J.* 2003;3(5):394–399. doi:10.1016/s1529-9430(03)00023-8

**Funding:** The authors received no financial support for the research, authorship, and/or publication of this article.

**Declaration of Conflicting Interests:** The authors report no conflicts of interest in this work.

**Disclosures:** Joseph Mendelis and Nicole Hung have nothing to disclose. Vedat Deviren is a consultant for and receives royalties from Alphatec Spine. Christopher Ames receives royalties from Stryker, Zimmer-Biomet, DePuy Synthes, Nuvasive, Next Orthosurgical, K2M, and Medtronic. He also discloses consulting fees from DePuy Synthes, Medtronic, and K2M and receives research support from Titan Spine and Depuy Synthes.

Aaron Clark discloses consulting fees and research support from Nuvasive. Alekos Theologis discloses research support from Stryker/K2M, royalties from Alphatec Spine, consulting fees from Depuy Spine, Alphatec Spine, SpineArt, Stryker/K2M, Surgalign, and Restor3D, as well as being on the surgeon advisory board for Ulrich Medical.

**Ethics Approval:** The study was approved by our institutional review board. The study was performed in accordance with the ethical standards as laid down in the 1964 Declaration of Helsinki and its later amendments or comparable ethical standards.

**Corresponding Author:** Alekos A. Theologis, Department of Orthopedic Surgery, University of California - San Francisco, 500 Parnassus Ave, MUW 3rd Floor, San Francisco, CA 94143, USA; alekos.theologis@ucsf.edu

Published 12 July 2022

This manuscript is generously published free of charge by ISASS, the International Society for the Advancement of Spine Surgery. Copyright © 2022 ISASS. To see more or order reprints or permissions, see <http://ijssurgery.com>.