

Evaluation of Anterior Lumbar Interbody Fusion Performed Using a Stand-Alone, Integrated Fusion Cage

Richard D. Guyer, Jack E. Zigler, Scott L. Blumenthal, Jessica L. Shellock and Donna D. Ohnmeiss

Int J Spine Surg published online 8 August 2022
<http://ijssurgery.com/content/early/2022/08/07/8354>

This information is current as of June 9, 2023.

Email Alerts Receive free email-alerts when new articles cite this article. Sign up at:
<http://ijssurgery.com/alerts>

Evaluation of Anterior Lumbar Interbody Fusion Performed Using a Stand-Alone, Integrated Fusion Cage

RICHARD D. GUYER, MD¹; JACK E. ZIGLER, MD¹; SCOTT L. BLUMENTHAL, MD¹; JESSICA L. SHELLOCK, MD¹; AND DONNA D. OHNMEISS, DrMed^{1,2}

¹Center for Disc Replacement at Texas Back Institute, Plano, TX, USA; ²Texas Back Institute Research Foundation, Plano, TX, USA

ABSTRACT

Background: Anterior lumbar interbody fusion (ALIF) has been performed for many years. Often, posterior supplemental fixation has been used to provide additional stability to the operated segment. Interbody implants have evolved to incorporate unique designs, polyetheretherketone, integrated screws, and surface texture. With these changes, the need for supplemental posterior fixation has been debated. The purpose of this study was to evaluate the clinical outcome of stand-alone ALIF.

Methods: A surgery log was reviewed to identify the consecutive series of 58 patients undergoing ALIF using a STALIF stand-alone cage from March 2011 (first case) to December 2018 (minimum 24 months postoperative) with a mean follow-up of 30.6 months. All patients were treated for symptomatic degenerative conditions. Charts were reviewed to collect general patient information, operative data, and patient-reported outcomes, including the Oswestry Disability Index (ODI), visual analog scales (VAS) separately assessing back pain and leg pain, and re-operations. For patients who were not seen recently in clinic for follow-up, current outcome data were collected through mailings.

Results: The mean operative blood loss was 52.1 mL. There was a statistically significant improvement in mean ODI scores from 41.7 preoperatively to 21.0 at follow-up ($P < 0.01$). There was also significant improvement ($P < 0.01$) in VAS back pain (6.0–2.5) and leg pain (4.1–1.3). Subsequent surgery was performed on 9 patients. Reasons for re-operation were pseudoarthrosis ($n = 3$), progressive cage subsidence ($n = 1$), foraminal stenosis at the index level ($n = 1$), metal allergy reaction ($n = 2$), adjacent segment degeneration ($n = 1$), and ongoing pain ($n = 1$). There were no cases of device failure, vertebral body fracture, or screws backing out of the implant.

Discussion: Stand-alone ALIF was associated with statistically significant improvements in ODI scores, back pain, and leg pain. The re-operation rate for clear pseudoarthrosis or cage subsidence was 6.8%. These results support that stand-alone ALIF produces good outcomes in patients treated for symptomatic disc degeneration while avoiding the use of posterior fixation and its complication risk and cost.

Clinical Relevance: The results of this study support that stand-alone ALIF is a viable procedure for the treatment of symptomatic disc degeneration unresponsive in patients who have failed nonoperative care and who do not have specific indications for supplemental posterior instrumentation.

Level of Evidence: 4.

Lumbar Spine

Keywords: ALIF, stand-alone, clinical outcome, interbody cage, lumbar spine

INTRODUCTION

Anterior lumbar interbody fusion (ALIF) has been performed for many years for the treatment of painful degenerative conditions after the failure of nonoperative care. The primary advantage of the anterior approach is the broad access to the disc space allowing for the implantation of a single large lordotic implant. The primary disadvantage is the potential for vascular injury. Interbody implant options have evolved from bone to threaded cylindrical cages, to metallic cages, cages with integrated screws, and now polyetheretherketone (PEEK) cages with integrated screws and titanium surfaces to facilitate osseointegration.¹ With the changes in interbody cage design, the need for supplemental

posterior fixation for stability has been debated. The posterior procedure may provide greater immediate stability; however, it is not without potential disadvantages such as injury to posterior musculature, neural injury due to malpositioned screws, and the need for subsequent removal of instrumentation related to pain. The posterior procedure certainly increases the costs, not only of the implants but also longer operative time, and possibly the length of hospitalization.

Several biomechanical studies have evaluated the stability of stand-alone cages. A cadaveric study found that stand-alone cages with integrated screws provided stability similar to ALIF with supplemental fixation in lateral bending and axial rotation.² Using a finite-element model, it was found that stand-alone cages



Figure 1. The current design of the STALIF M-Ti device made of polyetheretherketone with texturized titanium surfaces interfacing with the vertebral bodies (courtesy Centinel Spine, LLC, with permission).

provided sufficient stability, reduced stress in adjacent levels compared with a model with the cage and posterior fixation, and shared the loading distribution in a manner similar to an intact spine.³ While these biomechanical results are promising, there are relatively little clinical outcome data available in the literature reporting on the use of stand-alone cages, particularly those of a current design type. While in the past, trials were conducted evaluating shaped allograft cages and paired threaded metallic cages, there is relatively little information on the current cage design with integrated screws. The purpose of the current study was to evaluate the clinical outcome of stand-alone ALIF based on commonly used outcome assessments and re-operations.

METHODS

A surgery log was reviewed to identify all patients undergoing ALIF using a STALIF stand-alone cage with graft during the timeframe between March 2011 and December 2018. This allowed for all patients included to be at least 24 months postoperative. The mean follow-up was 30.6 months. There were 58 such patients in this consecutive series beginning with the first case experience. All patients were treated primarily for persistent symptomatic disc degeneration. They may also have had other related diagnoses such as low-grade spondylolisthesis, stenosis, and/or a history of prior disc surgery. Patients did not undergo stand-alone STALIF if they had greater than Grade I spondylolisthesis, fracture, tumor, or significant instability (including that following prior surgery).

A chart review was conducted to collect general patient information including gender, age, height, weight, and history of prior surgery. Operative data

collected included the level(s) operated and estimated blood loss. Also, data collected from chart review were patient-reported outcomes including the Oswestry Disability Index (ODI), visual analog scales (VAS, 0 to 10 scale) separately assessing back pain and leg pain, and re-operations, including the reason for the re-operation, level(s) involved, time duration from the index surgery, and procedure(s) performed. For patients who were not seen recently in clinic for follow-up, current outcome data were collected through mailings.

In addition to evaluating the mean ODI scores, the percentage of patients achieving minimal clinical important difference (MCID) was also calculated. A change of 15 points was used to define the achievement of MCID based on the ODI scores. This value has been used in multiple trials evaluating fusion and disc replacement.⁴⁻⁷ To avoid a floor effect created by low preoperative ODI scores, only patients with a preoperative score of at least 40 were included in the MCID analysis. This value has been used as a selection criterion in the studies using an MCID of 15 in patients undergoing treatment for symptomatic disc degeneration.⁴⁻⁷

All procedures were performed using a STALIF implant (during the course of the study, 3 designs of the device were used and the STALIF Midline, STALIF M, and the STALIF M-Ti, Centinel Spine, LLC; West Chester, PA). These devices are an interbody fusion cage with integrated screws for anchoring and providing some compression of the vertebral body endplates to the device. The current design of the implant is PEEK with a texturized titanium coating on the endplate surfaces to facilitate osseointegration (Figure 1).

Data Analysis

Comparison of mean pre- to postoperative scores on the ODI and VAS pain scales was made using paired *t* tests. A *P* value of less than 0.05 was accepted as a statistically significant change in the scores.

RESULTS

An overview of the study population is provided in Table 1. All patients were treated for degenerative conditions and often a combination of these including symptomatic disc degeneration, spondylosis with stenosis, recurrent disc herniation, postlaminectomy syndrome, poststem cell injection, and instability. All patients were at least 24 months postoperative with a mean follow-up of 30.6 months. The majority of cases were single-level fusion performed at L5-S1. The mean operative estimated blood loss was 52.1 mL.

Table 1. Description of the study population.

Characteristic	Measure
Age, y, mean (range)	47.8 (20–77)
Body mass index, kg/m ² , mean (range)	28.0 (20.4–40.6)
Gender, <i>n</i> (%)	
Women	30 (51.7%)
Men	28 (48.3%)
Prior lumbar spine surgery, <i>n</i> (%)	25 (43.1%)
Level(s) implanted, <i>n</i> (%)	
L4-L5	11 (19.0%)
L5-S1	44 (75.9%)
L4-L5 and L5-S1	2 (3.4%)
L3-L4 and L5-S1	1 (1.7%)

There was a statistically significant improvement in the mean ODI scores from 41.7 preoperatively to 21.0 at follow-up ($P < 0.01$). MCID of at least a 15-point reduction in ODI score was achieved in 73.3% of patients. As seen in Figure 2, there was a statistically significant improvement in the mean scores on the VAS assessing back and leg pain compared with the preoperative values (both $P < 0.01$) with greater than 50% improvement in each pain score.

Subsequent lumbar spine surgery was performed in 9 patients (15.5%). The re-operation rate specifically for clear pseudoarthrosis or cage subsidence was 6.8%. An overview of the re-operations is provided in Table 2. There were no cases of device failure, vertebral body fracture, or screws backing out of the implant.

DISCUSSION

This study found that stand-alone ALIF performed using a cage with integrated screws was associated with significant improvements in pain and self-reported function as assessed by VAS and ODI scores decreasing 50% or more. The percentage of patients achieving MCID on the ODI was 73.3%. These clinical outcomes were similar to those reported in previous studies involving fusion or disc replacement for the treatment of symptomatic disc degeneration and related conditions.^{4–8} The

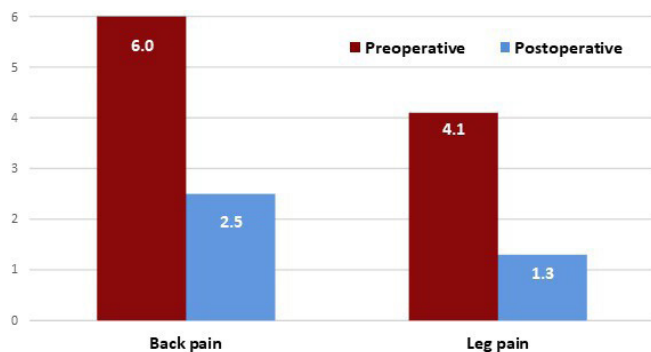


Figure 2. The mean visual analog scales back and leg pain scores improved significantly after stand-alone anterior lumbar interbody fusion ($P < 0.01$).

Table 2. Overview of re-operations in the series.

Reason for Re-operation	<i>n</i> (%)	Time from Index Surgery (mo)
Clear pseudoarthrosis	3 (5.2%)	11, 19, and 27
Progressive cage subsidence	1 (1.7%)	2
Foraminal stenosis at index level	1 (1.7%)	3
Metal allergy reaction	2 (3.4%)	7 and 9
Adjacent segment degeneration	1 (1.7%)	17
Ongoing pain ^a	1 (1.7%)	4
Total	9 (15.5%)	Not applicable

^aNo subsidence or pseudoarthrosis.

overall re-operation rate, which included any return to the operating room for any surgical procedure on the lower lumbar spine, was greater than anticipated and included cases of metal allergy. However, the rate of re-operation for pseudoarthrosis or cage subsidence, conditions which have been a concern with stand-alone cages, was 6.8%. This rate was similar to other studies involving stand-alone ALIF using cages with integrated fixation.^{9,10}

A review study concluded that the literature is supportive of stand-alone ALIF based on clinical outcomes, fusion rates, and disc space height restoration.¹¹ In an additional review combined with preliminary clinical study data comparing stand-alone ALIF to instrumented posterior interbody procedures, the authors reported that stand-alone ALIF was associated with shorter operative time, less blood loss, and more rapid improvement after surgery.¹² Similar conclusions have been reached reporting ALIF using devices with integrated screws was associated with greater fusion rates and better clinical outcomes as well as lower operative time and reduced morbidity compared with other lumbar fusion options and that ALIF with supplemental fixation does not produce better outcomes.^{13,14}

Kuang et al retrospectively compared ALIF using self-anchoring stand-alone cages vs transforaminal lumbar interbody fusion (TLIF).¹⁰ Both groups had significant improvements with no significant differences in clinical or radiographic outcomes. The ALIF group had significantly less blood loss and operative time than TLIF. Cage subsidence was not seen in the TLIF group but occurred in 6% of the ALIF group, none of which were symptomatic. Another study compared stand-alone ALIF, TLIF, and combined anterior/posterior fusion.¹⁵ There were no significant differences in clinical outcomes or fusion rates when comparing the 3 groups. However, ALIF had significantly lower operative time, blood loss, and length of hospital stay than the other 2 groups.

In a study investigating ALIF for indirect decompression, the authors reported good outcomes with no significant difference when comparing patients undergoing

stand-alone ALIF vs those with supplemental posterior fixation.¹⁶ In the group with posterior instrumentation, the most common reason for re-operation was for removal of posterior implants due to pain 7.8%, with an additional 0.9% to address malpositioned posterior screws. In the stand-alone ALIF group, 3.2% of patients had subsequent surgery for instability, subsidence, or pseudoarthrosis, commonly treated with implanting posterior fixation. The authors suggested that stand-alone ALIF is a viable option for indirect decompression in patients not having a specific indication for posterior decompression and/or fixation.

While stand-alone ALIF may be viable for many patients with painful degenerative conditions, there are limitations with respect to indications for stand-alone vs addition of posterior fixation. The primary contraindications are related to anatomy which may not adequately support the implant or compromise its ability to perform as intended. In a series of stand-alone ALIFs using an uncoated PEEK cage, it was reported that factors related to failure were isthmic spondylolisthesis and a high pelvic incidence at L5-S1.¹⁷ Another author reported significant instability as a contraindication.¹⁸ In that series, as in our own, an appreciable number of patients had prior surgery, and this was not considered a contraindication provided the segment was not significantly destabilized from prior surgery. There have been reports of vertebral body fractures related to stand-alone cages with integrated screws.¹⁹⁻²² In these cases, the exact mechanism for the failures was not discerned but most were operated on for spondylolisthesis and another had bilateral spondylolysis not appreciated prior to surgery. One should carefully assess the grade of spondylolisthesis, segmental instability, and the angulation of the disc space to be treated when deciding to perform stand-alone ALIF vs ALIF with posterior fixation.

One of the shortcomings of the current study is the lack of radiographic follow-up. Although this is important information, it would be difficult to ask patients to take the time to return to clinic to have radiographs made when they were not doing so as related to their care. Also, data for this study were collected during the COVID pandemic, introducing a safety concern with returning to the clinic only for research purposes. Due to the lack of radiographic follow-up on all patients, we could not determine the fusion rate or incidence of implant subsidence. Based on chart reviews and follow-up questionnaires completed by the patients, we could derive the re-operation rate and the reasons for re-operation allowing identification of pseudoarthrosis or subsidence severe enough to merit additional surgical intervention, which occurred in 6.8% of patients. Another

potential shortcoming of the study was that multiple variations of the cage design were used through the years. The authors thought it was important to have the long-term follow-up for the early designs rather than to restrict the study to only the current design, limiting the number of patients and shortening the follow-up duration.

When evaluating the literature on stand-alone cages, one must use caution and keep in mind that there has been a wide variety of cage designs and materials described, many of which are no longer on the market and have been replaced with new designs incorporating intricate 3D printed titanium cages or PEEK with titanium endplates. Some devices have integrated screws, others incorporate an exterior-anterior plate attached to the cage, and others have no anchoring screws. Much research is needed to optimize indications for each of these device types and/or compare their outcomes.

CONCLUSIONS

The results of this study found that ALIF performed using a stand-alone fusion cage was associated with significant improvement in pain and self-reported functions reflected by VAS and ODI scores. The re-operation rate for pseudoarthrosis and significant subsidence was reasonable. There were no cases of device failure, vertebral body fracture, or screws backing out of the implant. These results support the findings of other studies that stand-alone ALIF is a viable option for the treatment of painful degenerative spinal conditions in appropriately selected patients.

REFERENCES

1. Phan K, Mobbs RJ. Evolution of design of interbody cages for anterior lumbar interbody fusion. *Orthop Surg.* 2016;8(3):270-277. doi:10.1111/os.12259
2. Kornblum MB, Turner AWL, Cornwall GB, Zatushevsky MA, Phillips FM. Biomechanical evaluation of stand-alone lumbar polyether-ether-ketone interbody cage with integrated screws. *Spine J.* 2013;13(1):77-84. doi:10.1016/j.spinee.2012.11.013
3. Choi K-C, Ryu K-S, Lee S-H, Kim YH, Lee SJ, Park C-K. Biomechanical comparison of anterior lumbar interbody fusion: stand-alone interbody cage versus interbody cage with pedicle screw fixation -- a finite element analysis. *BMC Musculoskelet Disord.* 2013;14:220. doi:10.1186/1471-2474-14-220
4. Synthes Spine. ProDisc-L total disc replacement. Summary of Safety and Effectiveness Data. 2005.
5. Zigler J, Delamarter R, Spivak JM, et al. Results of the prospective, randomized, multicenter food and drug administration investigational device exemption study of the prodisc-L total disc replacement versus circumferential fusion for the

treatment of 1-level degenerative disc disease. *Spine (Phila Pa 1976)*. 2007;32(11):1155–1162. doi:10.1097/BRS.0b013e318054e377

6. Garcia R, Yue JJ, Blumenthal S, et al. Lumbar total disc replacement for discogenic low back pain: two-year outcomes of the activl multicenter randomized controlled IDE clinical trial. *Spine (Phila Pa 1976)*. 2015;40(24):1873–1881. doi:10.1097/BRS.0000000000001245

7. Guyer RD, Pettine K, Roh JS, et al. Comparison of 2 lumbar total disc replacements: results of a prospective, randomized, controlled, multicenter food and drug administration trial with 24-month follow-up. *Spine (Phila Pa 1976)*. 2014;39(12):925–931. doi:10.1097/BRS.0000000000000319

8. Glassman S, Gornet MF, Branch C, et al. MOS short form 36 and Oswestry disability index outcomes in lumbar fusion: a multicenter experience. *Spine J*. 2006;6(1):21–26. doi:10.1016/j.spinee.2005.09.004

9. Behrbalk E, Uri O, Parks RM, Musson R, Soh RCC, Boszczyk BM. Fusion and subsidence rate of stand alone anterior lumbar interbody fusion using peek cage with recombinant human bone morphogenetic protein-2. *Eur Spine J*. 2013;22(12):2869–2875. doi:10.1007/s00586-013-2948-5

10. Kuang L, Wang B, Lü G. Transforaminal lumbar interbody fusion versus mini-open anterior lumbar interbody fusion with oblique self-anchored stand-alone cages for the treatment of lumbar disc herniation: a retrospective study with 2-year follow-up. *Spine (Phila Pa 1976)*. 2017;42(21):E1259–E1265. doi:10.1097/BRS.0000000000002145

11. Giang G, Mobbs R, Phan S, Tran TM, Phan K. Evaluating outcomes of stand-alone anterior lumbar interbody fusion: a systematic review. *World Neurosurg*. 2017;104:259–271. doi:10.1016/j.wneu.2017.05.011

12. Udby PM, Bech-Azeddine R. Clinical outcome of stand-alone alif compared to posterior instrumentation for degenerative disc disease: a pilot study and A literature review. *Clin Neurol Neurosurg*. 2015;133:64–69. doi:10.1016/j.clineuro.2015.03.008

13. Kerolus M, Turel MK, Tan L, Deutsch H. Stand-alone anterior lumbar interbody fusion: indications, techniques, surgical outcomes and complications. *Expert Rev Med Devices*. 2016;13(12):1127–1136. doi:10.1080/17434440.2016.1254039

14. Zhang J, Poffyn B, Sys G, Uyttendaele D. Are stand-alone cages sufficient for anterior lumbar interbody fusion? *Orthop Surg*. 2012;4(1):11–14. doi:10.1111/j.1757-7861.2011.00164.x

15. Bozzio AE, Johnson CR, Fattor JA, et al. Stand-alone anterior lumbar interbody, transforaminal lumbar interbody, and anterior/posterior fusion: analysis of fusion outcomes and costs. *Orthopedics*. 2018;41(5):e655–e662. doi:10.3928/01477447-20180711-06

16. Derman PB, Ohnmeiss DD, Lauderback A, Guyer RD. Indirect decompression for the treatment of degenerative lumbar stenosis. *Int J Spine Surg*. 2021;15(6):1066–1071. doi:10.14444/8192

17. Jaeger A, Giber D, Bastard C, et al. Risk factors of instrumentation failure and pseudarthrosis after stand-alone L5-S1 anterior lumbar interbody fusion: a retrospective cohort study. *J Neurosurg Spine*. 2019;31(3):338–346. doi:10.3171/2019.3.SPINE181476

18. Kashlan O, Frerich JM, Malcolm JG, Gary MF, Rodts GE, Refai D. Safety profile and radiographic and clinical outcomes of stand-alone 2-level anterior lumbar interbody fusion: a case series of

41 consecutive patients. *Cureus*. 2020;12(11):e11684. doi:10.7759/cureus.11684

19. Kwon Y-K, Jang J-H, Lee C-D, Lee S-H. Fracture of the L-4 vertebral body after use of a stand-alone interbody fusion device in degenerative spondylolisthesis for anterior L3-4 fixation. *J Neurosurg Spine*. 2014;20(6):653–656. doi:10.3171/2014.3.SPINE121018

20. Lastfogel JF, Altstadt TJ, Rodgers RB, Horn EM. Sacral fractures following stand-alone L5-S1 anterior lumbar interbody fusion for isthmic spondylolisthesis. *J Neurosurg Spine*. 2010;13(2):288–293. doi:10.3171/2010.3.SPINE09366

21. Phan K, Mobbs RJ. Sacrum fracture following L5-S1 stand-alone interbody fusion for isthmic spondylolisthesis. *J Clin Neurosci*. 2015;22(11):1837–1839. doi:10.1016/j.jocn.2015.03.055

22. Strube P, Hoff E, Hartwig T, Perka CF, Gross C, Putzier M. Stand-alone anterior versus anteroposterior lumbar interbody single-level fusion after a mean follow-up of 41 months. *J Spinal Disord Tech*. 2012;25(7):362–369. doi:10.1097/BSD.0b013e3182263d91

Funding: This study was supported by Centinel Spine (paid to institution).

Conflicts and Disclosures: Richard Guyer reports consulting fees from Centinel, Aesculap, NuVasive, and Orthofix, and stock or stock options for Alphatec and Stryker Spine. Jack Zigler reports consulting fees from Centinel Spine, Aesculap Spine, NuVasive, and Orthofix; leadership or fiduciary role for AO Spine Technical Committee; and stock options in VBIC. Scott Blumenthal reports royalties or licenses from Aesculap; consulting fees from Orthofix, Aesculap, NeospineCen, Bayless Medical, DeGen, Centinel, and Zimmer; payment or honoraria from Bayless Medical, NuVasive, and Aesculap; stock or stock options from Centinel Spine and Fziomed; and other financial or nonfinancial interests in Aesculap and Fziomed (Scientific Advisory Board) and Aesculap (Device or biologic distribution group—physician-owned distribution). Jessica Shellock reports consulting fees and payment or honoraria from Centinel Spine for educational activities. Donna Ohnmeiss reports no disclosures.

Corresponding Author: Richard D. Guyer, Center for Disc Replacement at Texas Back Institute, 6020 W Parker Rd #200, Plano, TX 75093, USA; rguyer@texasback.com

This manuscript is generously published free of charge by ISASS, the International Society for the Advancement of Spine Surgery. Copyright © 2022 ISASS. To see more or order reprints or permissions, see <http://ijssurgery.com>.