

Validity and Reliability of Spinopelvic Parameters Measured on Computed Tomography

Ahmet Celal Iplikçioğlu and Hamza Karabag

Int J Spine Surg published online 25 August 2022
<https://www.ijssurgery.com/content/early/2022/08/23/8344>

This information is current as of May 17, 2025.

Email Alerts Receive free email-alerts when new articles cite this article. Sign up at:
<http://ijssurgery.com/alerts>

Validity and Reliability of Spinopelvic Parameters Measured on Computed Tomography

AHMET CELAL İPLİKÇIOĞLU, MD¹ AND HAMZA KARABAĞ, MD²

¹Department of Neurosurgery, BHT Clinic Istanbul Tema Hastanesi, Istanbul, Turkey; ²Department of Neurosurgery, Harran University, Şanlıurfa, Turkey

ABSTRACT

Background: This study aimed to measure pelvic incidence (PI) and other spinopelvic sagittal parameters on supine computed tomography (CT) and to assess the validity and reliability of measurements from supine CT images when compared with standing x-ray images. Difficulties in superimposition of femur heads and obtaining the perfect midsagittal view of the sacral endplate may cause relatively low intra- and interobserver agreements. Some authors reported that PI values measured by CT had higher reliability, but both validity and reliability of CT measurement of spinopelvic parameters compared with standing x-ray imaging methods have not been reported previously.

Methods: PI, pelvic tilt (PT), and sacral slope (SS) were measured on standing lateral x-ray and spinopelvic supine CT images of 33 asymptomatic volunteers.

Results: The mean PI, PT, and SS in standing x-ray images were 45.2°, 10°, and 35.3°, respectively, whereas those in supine CT images were 44.5°, 8.2°, and 36.2°, respectively. No significant differences were found in each parameter. Excellent correlations were found between each parameter obtained from x-ray and CT images. Intra- and interobserver reliabilities were excellent in both x-ray and CT image measurements, although those from CT images were higher.

Conclusion: Spinopelvic sagittal parameters could be measured on supine CT by using a simple method with high reliability and validity; thus, CT could be a good alternative to standing x-ray imaging. In the supine position, PI does not change but PT decreases by a small amount and SS increases almost by the same amount because of the mathematical relationship between PT and SS ($PI = PT + SS$).

Clinical Relevance: Supine CT is an efficient diagnostic tool for the reliable extraction of spinopelvic sagittal parameters.

Level of Evidence: 4.

Lumbar Spine

Keywords: pelvic incidence, pelvic tilt, sacral slope, computed tomography, X-ray

INTRODUCTION

Pelvic incidence (PI) is a unique morphological and the most important spinopelvic parameter that defines the position of the sacrum within the pelvis. It is a constant parameter specific to every individual and does not change with body position.^{1,2} Studies evaluating PI showed its association with spinal disorders, pain, disability, and health-related quality of life.^{3–6} It is also used for surgical planning to restore ideal lordosis.⁷

Classically, PI is measured on sagittal standing x-ray images. However, both femoral heads were superimposed due to the projection effect of x-ray imaging, and perfect midsagittal appearance of the sacral endplate could not be provided. This disadvantage of plain x-ray imaging causes large intra- or interobserver variations.^{8–10}

Some authors reported PI values measured by computed tomography (CT) with higher reliability.^{8,11,12} However, in most studies, sophisticated and complicated methods were used to measure PI in 3-dimensional

(3D) models without control groups. Others were performed to investigate the association of PI with hip surgery or to evaluate the difference in spinopelvic alignment between supine and standing position in patients with adult spinal deformity or lumbar degenerative disease.^{13,14}

This study aimed to measure PI and other spinopelvic sagittal parameters (pelvic tilt [PT], sacral slope [SS]) on supine CT and to assess their validity and reliability compared with those measured on standing x-ray imaging.

MATERIALS AND METHODS

This study was conducted at the neurosurgery departments of Harran University, Şanlıurfa, Turkey. Thirty-three asymptomatic participants were recruited with study approval by the local ethics committee in agreement with the second Helsinki Declaration. Written informed consent was obtained from all participants. Inclusion criteria were as follows:

1. Age between 18 and 60 years
2. No history of spinal disease, back pain, trauma, hip disease, or surgery
3. Body mass index between 18.5 and 40 kg/m²

Standing lateral lumbosacral plain x-ray images of the femoral heads and sacropelvic CT images of all participants were obtained using x-ray (XGEOGC80 Samsung, Korea) and CT (Revolution GSI 256 MSCT General Electric Company, USA) imaging machines.

Lateral x-ray images were obtained with the participants standing. The distance between the participant and the beam source was 1.5 m, and the beam was focused on the L5-S1 level. Supine CT was obtained with the participants lying on their backs and extending their knees.

Measurements

PI, PT, and SS from standing x-ray and supine CT were measured twice by 2 surgeons who were the authors of the study (A.C.Í. and H.K.). Time interval between the measurements was 2 weeks. The methods used in the measurement were as follows.

1. PI: The angle between the line perpendicular to the superior sacral endplate at its midpoint and the line connecting this point to the midpoint of the axis of the femoral heads.
2. PT: The angle between a line from the midpoint of the sacral endplate to the midpoint of the axis of femoral heads and vertical plumb line.
3. SS: The angle between the line parallel to the endplate of the sacrum and a horizontal line (Figure 1).

There is a mathematical relationship between these parameters: $PI = PT + SS$.¹⁵ CT measurements were performed on ClearCanvas Workstation system (Synaptive Medical, Canada) using sagittal slice images. First, the coordinates of the right femoral head on the sagittal slices on which the head appeared as the largest circle were identified using the coordinate system of ClearCanvas Viewer (x_1, y_1). Second, the coordinates of the left femoral head were found in the same manner (x_2, y_2). The mean X and Y values $(x_1 + x_2)/2$, $(y_1 + y_2)/2$ were calculated as the midpoint of the hip axis and found on the midsagittal images. Based on this point, PI and PT were measured (Figures 2a–c and 3). However, on the other sagittal slices on which the femoral head appeared as smaller circles, centers of the circles have the same coordinates because femoral heads are

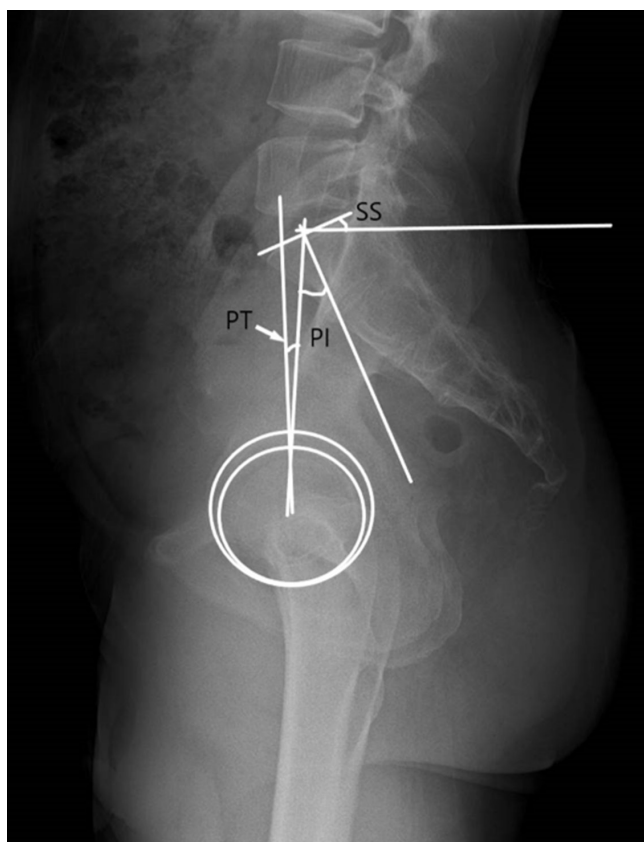


Figure 1. Lateral x-ray image of a 48-year-old man showing spinopelvic parameters: pelvic incidence (PI), pelvic tilt (PT), and sacral slope (SS).

considered as perfect spheres and the sagittal slices are parallel to each other.

Statistical Analysis

Paired *t* test was used to determine the statistical differences between the values obtained from different modalities, and the mean absolute difference (MAD) with SD was also calculated. The agreement between the parameters obtained from x-ray and computed tomography was determined using Pearson correlation coefficient. Significance level was set at $P < 0.05$.

The interclass correlation coefficient was used to assess intra- and interobserver reliability of the measurements. Values of 0.60 to 0.74 and 0.75 to 1.00 were considered good and excellent, respectively.

Statistical analysis was performed by using SPSS 26.0 (IBM Corporation, Armonk, NY, USA).

RESULTS

Of the participants, there were 18 men and 15 women, with a mean age of 33 years. The mean PIs in men and women were 44.7° and 45.9°, respectively. No

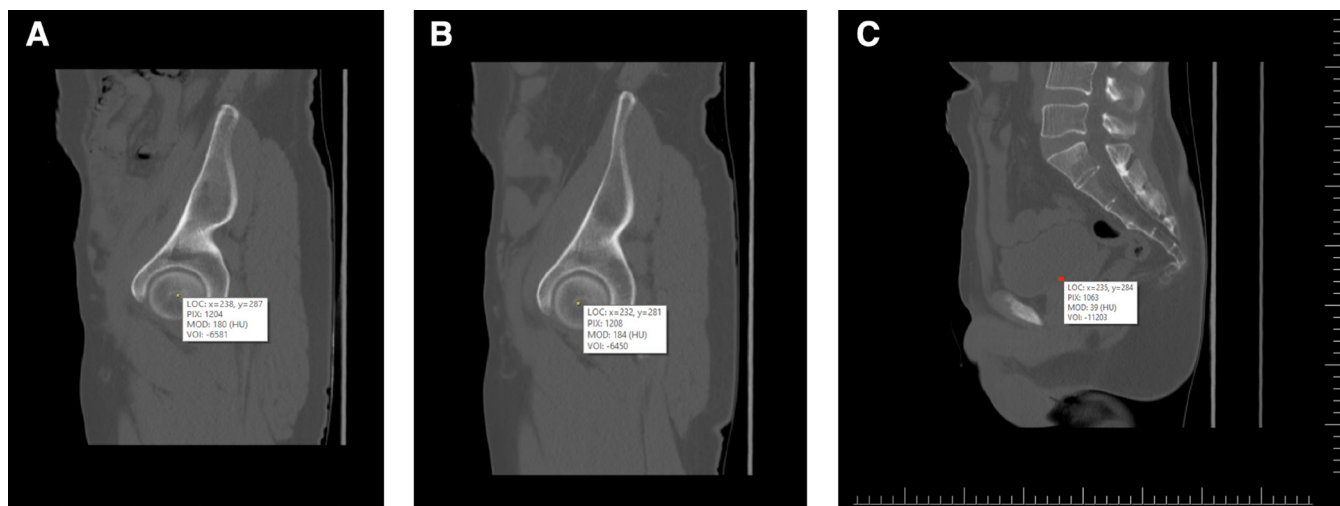


Figure 2. (A) Sagittal slice of pelvic computed tomography (CT) image of the same patient showing coordinates of the right femoral heads. (B) Sagittal slice of pelvic CT with coordinates of the left femoral head. (C) (Changed) Midsagittal CT slice of the patient. The point with average coordinates of the femoral head center determines the midpoint of the hip axis.

statistical difference was found between the mean ages and mean PIs of male and female participants.

Reliability

Intra- and interobserver reliabilities were excellent in both modalities, although interclass correlation coefficients of CT were higher (Table 1).

Validity

Table 2 shows the results of paired *t* test. The mean PI on standing x-ray and supine CT was 45.24° and

44.46°, respectively. There was no statistically significant difference between the parameters obtained from x-ray imaging and CT. MAD of PI was 0.9° with a 1.2° SD. Pearson correlation analysis disclosed very high correlations between the PIs, PTs, and SSs measured on x-ray imaging and CT (0.99, 0.912, and 0.932, respectively). Table 3 shows the results of Pearson correlation analyses. According to the results, CT is a good reliable alternative to x-ray imaging to measure spinopelvic parameters.

DISCUSSION

PI was first described by Legaye et al.¹ It increases during childhood and is regarded as a constant morphological parameter after bone maturity. It defines the sacral position within the pelvis. The spine and pelvis should be in accordance to provide a globally balanced spine to minimize energy consumption. This harmony is considered as spinopelvic alignment and evaluated by parameters, including PI, PT, and SS, which affect the spinal regional curvatures of lumbar lordosis and thoracic kyphosis.^{2,15–18}

PI is the sum of PT and SS. Strong correlations are found between PI, PT, and SS, although PI has a

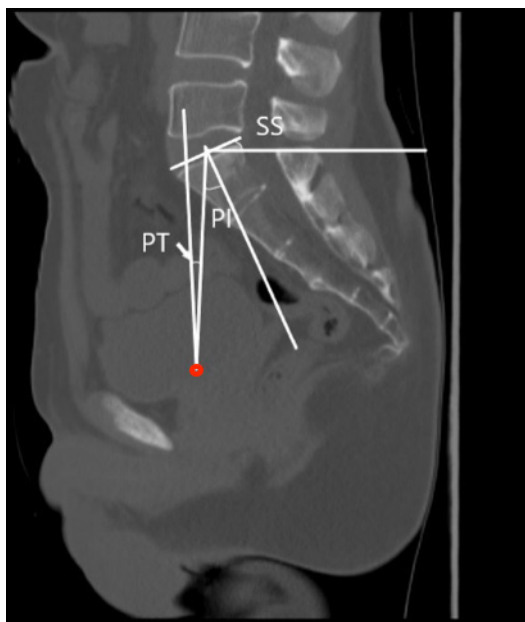


Figure 3. According to the midpoint of the hip axis spinopelvic parameters: pelvic incidence (PI), pelvic tilt (PT), and sacral slope (SS).

Table 1. Intra- and interobserver reliability of spinopelvic parameters measured on x-ray and CT images.

Parameter	Intraobserver	Interobserver
PI x-ray	0.90	0.85
PI CT	0.99	0.98
PT x-ray	0.89	0.87
PT CT	0.99	0.98

Abbreviations: CT, computed tomography; PI, pelvic incidence; PT, pelvic tilt.

Table 2. Results of paired *t* test: comparison of spinopelvic parameters measured on x-ray and CT images.

Spinopelvic Parameters	X-ray		CT		P Value
	Mean	SD	Mean	SD	
Pelvic incidence	45.2	13.8	44.5	13.3	0.86
Pelvic tilt	10	6.7	8.2	5.7	0.52
Sacral slope	35.3	9.7	36.2	9.9	0.9

Abbreviation: CT, computed tomography.

wide range (35°–85°). In participants with large PI, the sacrum is less vertical; hence, lumbar lordosis should become larger. By contrast, participants with low PI have a more vertical sacrum and smaller lumbar lordosis.

Studies have shown strong correlations between PI and some spinal pathologies, such as scoliosis, spondylolisthesis, disc degeneration, and adjacent segment degeneration.^{16–18} PI is also related to pain, disability, and health-related quality of life.^{5,6} Some authors developed a formula that determines the ideal lumbar lordosis for surgical planning.^{3,7}

PI is measured on sagittal x-ray images in patients with standing position. However, projection effect of x-ray beam causes some problems. Superimpositions of the femoral heads and true sagittal appearance of the sacral endplate cannot be achieved. The iliac wings can also obscure the sacral endplate. Due to the disadvantages of plain x-ray images, intra- and interobserver agreement rates were 0.79 to 0.84, and the variability was between 3° and 6°.^{8–10}

Recent studies showed that CT was more reliable than x-ray imaging for measuring some spinal sagittal parameters because anatomical landmarks are better visible on CT.¹⁹

Measurement of PI on CT has been described mostly by recent studies (Table 4).^{8,11–14,20–23} Of 9 CT studies, 7 were retrospective, and all included patients, whose abdominopelvic CT images were obtained, were admitted to emergency services with nonorthopedic or nonspinal complaints, such as acute abdominal disease, trauma, and urological problems. The purpose of their study was data collection (normal PI values,

Table 3. Pearson correlation analysis of spinopelvic parameters from x-ray and CT images.

Spinopelvic Parameters	CT		
	PI	PT	SS
X-ray			
PI	0.99	0.745	0.924
PT	0.83	0.912	0.613
SS	0.884	0.474	0.932

Abbreviations: CT, computed tomography; PI, pelvic incidence; PT, pelvic tilt; SS, sacral slope.

relationship with age and sex) in 3, determination of relationship between PI and acetabular impingement or orientation in 3, and evaluation of sacral orientation in 1. All studies showed that sacropelvic parameters other than PI were not measured, and no control group, with standing x-ray was included. Two prospective studies investigated spinopelvic parameter changes in standing and supine position.^{13,14} The subjects were women with adult spinal deformity and patients with lumbar degenerative disease. Therefore, both validity and reliability studies of CT measurements of spinopelvic parameters compared with standard standing x-ray imaging methods have not been performed previously.

In our study, CT was clearly shown as a good alternative to standing x-ray imaging for the measurement of spinopelvic parameters. A very strong correlation was found between the spinopelvic parameters. For PI, the MAD was <1°. Although CT measurements were reported with high reliability because of better visible anatomic landmarks, a positional effect may be present. Park et al reported that higher PI could decrease in the supine position due to sacroiliac joint pathology, and spinopelvic parameters might be overestimated by up to 5° in x-ray imaging in patients with lumbar degenerative disease.¹³ Hasegeva et al also found that PI decreased in the supine position in women with adult spinal deformity.¹⁹ In these series, the mean age was 69.4 and 60.1 years, respectively. In 2 large series of PI measured on supine CT without x-ray (control group), the mean PI values were 45° and 47°, respectively, although normal PI values were considered at approximately 52° in PI studies using classic x-ray imaging methods. The average values reported in this study are similar to literature-reported averages.

However, PT and SS are positional parameters. In studies comparing pelvic parameters using x-ray in the standing and supine position, Phillippot et al found no significant difference between PI, PT, and SS values in 67 patients with coxarthrosis without spinal problem.²⁴ Chevolette et al reported that PI did not change from standing to supine, whereas PT decreased significantly and SS increased in 15 asymptomatic volunteers.²⁵ In our study, PT decreased by 1.8° from standing to supine, whereas SS increased by 1°. These results were insignificant statistically. The MAD of PI was 0.9° in our series. Thus, we believe that PI does not change with position, whereas PT slightly decreases, and SS increases almost the same amount in the supine position.

In most studies, 3D CT images were used because the anatomical points could be easily identified.^{8–12}

Table 4. Pelvic incidence measurements on CT images.

Author	Y	N	CT	Mean Age, y	Pelvic Incidence	Participants	Purpose	Comparison
Peleg ²¹	2007	20	3D	NA	57	Asymptomatic	Search for sacral orientation	None
Vrtovec ¹²	2012	370	3D	45.3	47.1	Emergency	Data collection	None
Radcliff ²⁰	2013	164	2D	59	55	Nonorthopedic emergency	Search for acetabular impingement	None
Weinberg ²³	2016	27	2D	59	56.1	Asymptomatic	Search for acetabular impingement	None
Park ¹³	2017	104	3D	62.8	57.7	Lumbar degenerative disease	Search for position effect	X-ray
Sautet ²²	2018	150	2D	65.4	58.6	Nonorthopedic patients	Search for acetabular orientation	None
Hasegawa ¹⁴	2018	24	3D	60.1	57.7	Women with adult spinal deformity	Search for position effect	X-ray
Chen ⁷	2019	320	3D	46.2	45	Patients with acute abdominal disease	Data collection	None
Baker ¹⁰	2020	177	2D	50.1	49.1	Trauma	Data collection	None
Present study	2020	33	2D	36	44.5	Asymptomatic volunteers	Reliability validity	X-ray

Abbreviations: CT, computed tomography; 2D, 2-dimensional; 3D, 3-dimensional; NA, not available.

These studies also used complicated image processing systems and different computerized methods requiring 1 to 2 journal article pages and 5 to 6 figures for explanation. Chen et al reported that the sacral endplate shape affects PI in 3D CT reconstruction, but the major disadvantage of CT models is time-consuming.⁸ However, our method is similar to other 2-dimensional CT measurements of PI models, which is simple and can be used routinely.¹¹

The first limitation of our study was the small number of participants, which did not allow us to investigate the relationships of PI values with age and sex. Second, the participants were relatively young, with a narrow age range (mean age was 33 years). In older patients and those with lumbar degenerative disease, PI measured on CT may change due to sacroiliac joint dysfunction; hence, our study results may not reflect those that would be obtained from these groups.

CONCLUSION

Spinopelvic sagittal parameters could be measured on supine 2-dimensional CT using a simple method with high reliability and validity; hence, CT is a good alternative to standing x-ray imaging. In the supine position, PI does not change while PT decreases by a small amount, and SS increases almost by the same amount because of the mathematical relationship between PT and SS ($PI = PT + SS$). The differences are not statistically significant.

ACKNOWLEDGMENTS

The authors acknowledge Suat Barış İplikçioğlu for his assistance.

REFERENCES

- Legaye J, Duval-Beaupère G, Hecquet J, Marty C. Pelvic incidence: a fundamental pelvic parameter for three-dimensional regulation of spinal sagittal curves. *Eur Spine J.* 1998;7(2):99–103. doi:10.1007/s005860050038
- Mac-Thiong J-M, Labelle H, Charlebois M, Huot M-P, de Guise JA. Sagittal plane analysis of the spine and pelvis in adolescent idiopathic scoliosis according to the coronal curve type. *Spine (Phila Pa 1976).* 2003;28(13):1404–1409. doi:10.1097/01.BRS.0000067118.60199.D1
- Lafage V, Schwab F, Patel A, Hawkinson N, Farcy J-P. Pelvic tilt and truncal inclination: two key radiographic parameters in the setting of adults with spinal deformity. *Spine (Phila Pa 1976).* 2009;34(17):E599–606. doi:10.1097/BRS.0b013e3181aad219
- Hong J-Y, Suh S-W, Modi HN, Hur C-Y, Yang J-H, Song H-R. Correlation of pelvic orientation with adult scoliosis. *J Spinal Disord Tech.* 2010;23(7):461–466. doi:10.1097/BSD.0b013e3181bf1a85
- Takemoto M, Boissière L, Vital J-M, et al. Are sagittal spinopelvic radiographic parameters significantly associated with quality of life of adult spinal deformity patients? multivariate linear regression analyses for pre-operative and short-term post-operative health-related quality of life. *Eur Spine J.* 2017;26(8):2176–2186. doi:10.1007/s00586-016-4872-y
- Kyrölä K, Repo J, Mecklin J-P, Ylinen J, Kautiainen H, Häkkinen A. Spinopelvic changes based on the simplified SRS-schwab adult spinal deformity classification: relationships with disability and health-related quality of life in adult patients with prolonged degenerative spinal disorders. *Spine (Phila Pa 1976).* 2018;43(7):497–502. doi:10.1097/BRS.0000000000002370
- Chen HF, Mi J, Zhang HH, Zhao CQ. Pelvic incidence measurement using a computed tomography data-based three-dimensional pelvic model. *J Orthop Surg Res.* 2019;14(1):13. doi:10.1186/s13018-018-1050-4
- Yamada K, Aota Y, Higashi T, Ishida K, Nimura T, Saito T. Accuracies in measuring spinopelvic parameters in full-spine lateral standing radiograph. *Spine (Phila Pa 1976).* 2015;40(11):E640–E66. doi:10.1097/BRS.0000000000000904
- Lazennec JY, Ramaré S, Arafati N, et al. Sagittal alignment in lumbosacral fusion: relations between radiological parameters and pain. *Eur Spine J.* 2000;9(1):47–55. doi:10.1007/s005860050008

10. Baker JF, Don AS, Robertson PA. Pelvic incidence: computed tomography study evaluating correlation with sagittal sacropelvic parameters. *Clin Anat*. 2020;33(2):237–244. doi:10.1002/ca.23478
11. Schwab FJ, Blondel B, Bess S, et al. Radiographical spinopelvic parameters and disability in the setting of adult spinal deformity: a prospective multicenter analysis. *Spine (Phila Pa 1976)*. 2013;38(13):E803–E812. doi:10.1097/BRS.0b013e318292b7b9
12. Vrtovec T, Janssen MMA, Pernuš F, Castelein RM, Viergever MA. Analysis of pelvic incidence from 3-dimensional images of a normal population. *Spine (Phila Pa 1976)*. 2012;37(8):E479–E485. doi:10.1097/BRS.0b013e31823770af
13. Park SA, Kwak DS, Cho HJ, Min DU. Changes of spinopelvic parameters in different positions. *Arch Orthop Trauma Surg*. 2017;137(9):1223–1232. doi:10.1007/s00402-017-2757-0
14. Hasegawa K, Okamoto M, Hatsushikano S, Caseiro G, Watanabe K. Difference in whole spinal alignment between supine and standing positions in patients with adult spinal deformity using a new comparison method with slot-scanning three-dimensional X-ray imager and computed tomography through digital reconstructed radiography. *BMC Musculoskelet Disord*. 2018;19(1):437–447. doi:10.1186/s12891-018-2355-5
15. Le Huec JC, Aunoble S, Philippe L, Nicolas P. Pelvic parameters: origin and significance. *Eur Spine J*. 2011;20(Suppl 5):564–571. doi:10.1007/s00586-011-1940-1
16. Labelle H, Roussouly P, Berthonnaud E, et al. Spondylolisthesis, pelvic incidence, and spinopelvic balance: a correlation study. *Spine (Phila Pa 1976)*. 2004;29(18):2049–2054. doi:10.1097/01.brs.0000138279.53439.cc
17. Vaz G, Roussouly P, Berthonnaud E, Dimnet J. Sagittal morphology and equilibrium of pelvis and spine. *Eur Spine J*. 2002;11(1):80–87. doi:10.1007/s005860000224
18. Roussouly P, Gollogly S, Berthonnaud E, Dimnet J. Classification of the normal variation in the sagittal alignment of the human lumbar spine and pelvis in the standing position. *Spine (Phila Pa 1976)*. 2005;30(3):346–353. doi:10.1097/01.brs.0000152379.54463.65
19. Lee HD, Jeon CH, Chung NS, Kwon HJ. Comparative analysis of three imaging modalities for evaluation of cervical sagittal alignment parameters: a validity and reliability study. *Spine (Phila Pa 1976)*. 2017;42(24):1901–1907. doi:10.1097/BRS.0000000000002256
20. Radcliff KE, Kepler CK, Hellman M, et al. Does spinal alignment influence acetabular orientation: a study of spinopelvic variables and sagittal acetabular version. *Orthop Surg*. 2014;6(1):15–22. doi:10.1111/os.12090
21. Peleg S, Dar G, Steinberg N, Peled N, Hershkovitz I, Masharawi Y. Sacral orientation revisited. *Spine (Phila Pa 1976)*. 2007;32(15):E397–E404. doi:10.1097/BRS.0b013e318074d676
22. Sautet P, Giorgi H, Chabrand P, et al. Is anatomic acetabular orientation related to pelvic morphology? CT analysis of 150 healthy pelvises. *Orthop Traumatol Surg Res*. 2018;104(3):347–351. doi:10.1016/j.otsr.2017.10.006
23. Weinberg DS, Gebhart JJ, Liu RW, Salata MJ. Radiographic signs of femoroacetabular impingement are associated with decreased pelvic incidence. *Arthroscopy*. 2016;32(5):806–813. doi:10.1016/j.arthro.2015.11.047
24. Philippot R, Wegrzyn J, Farizon F, Fessy MH. Pelvic balance in sagittal and lewinnek reference planes in the standing, supine and sitting positions. *Orthop Traumatol Surg Res*. 2009;95(1):70–76. doi:10.1016/j.otsr.2008.01.001
25. Chevillotte T, Coudert P, Cawley D, et al. Corrigendum to “influence of posture on relationships between pelvic parameters and lumbar lordosis: comparison of the standing, seated, and supine positions. A preliminary study” [Orthop. Traumatol. Surg. Res. 104 (2018) 565-568]. *Orthop Traumatol Surg Res*. 2019;105(1):197. doi:10.1016/j.otsr.2018.11.009

Funding: The authors received no financial support for the research, authorship, and/or publication of this article.

Declaration of Conflicting Interests: The authors report no conflicts of interest in this work.

Disclosures: The authors received no funding for the study and report no conflicts of interest.

Corresponding Author: Ahmet Celal İplikçioğlu, BHT Clinic Istanbul Tema Hastanesi, Atakent Mahallesi 4. Cadde No: 36 Pk: 34307 Küçükçekmece, Istanbul, Turkey; acelal@doctor.com

Published 24 August 2022

This manuscript is generously published free of charge by ISASS, the International Society for the Advancement of Spine Surgery. Copyright © 2022 ISASS. To see more or order reprints or permissions, see <http://ijssurgery.com>.