INTERNATIONAL JOURNAL of SPINE SURGERY

Minimally Invasive Surgery for Thoracolumbar Spinal Fractures in Patients With Ankylosing Spondylitis

Johan Wänman, Fabian Burmeister, David Thorell, Tobias Kyrk, Simon Blixt, Paul Gerdhem, Sebastian Mukka and Lukas Bobinski

Int J Spine Surg published online 2 June 2023
https://www.ijssurgery.com/content/early/2023/05/31/8478

This information is current as of October 12, 2024.

Email Alerts Receive free email-alerts when new articles cite this article. Sign up at: http://ijssurgery.com/alerts

The International Journal of Spine Surgery
2397 Waterbury Circle, Suite 1,
Aurora, IL 60504, Phone: +1-630-375-1432
© 2023 ISASS. All Rights Reserved.
Downloaded from https://www.ijssurgery.com/ by guest on October 12, 2024

International Journal of Spine Surgery Publish Ahead of Print, published on June 2, 2023 as doi:10.14444/8478

International Journal of Spine Surgery, Vol. 00, No. 0, 2023, pp. 1–8
https://doi.org/10.14444/8478
© International Society for the Advancement of Spine Surgery

Minimally Invasive Surgery for Thoracolumbar Spinal Fractures in Patients With Ankylosing Spondylitis

JOHAN WÄNMAN, MD, PHD[1]; FABIAN BURMEISTER, MD[1]; DAVID THORELL, MD[1]; TOBIAS KYRK, MD[1]; SIMON BLIXT, MD[2]; PAUL GERDHEM, MD, PHD[2,3,4]; SEBASTIAN MUKKA, MD, PHD[1]; AND LUKAS BOBINSKI, MD, PHD[1]

[1]*Department of Surgical and Perioperative Sciences (Orthopedics), Umeå University, Umeå, Sweden;* [2]*Department of Clinical Science Intervention and Technology, Karolinska Institutet, Sweden;* [3]*Department of Hand Surgery and Orthopaedics, Uppsala University Hospital, Sweden;* [4]*Department of Surgical Sciences, Uppsala University, Sweden*

ABSTRACT

Background: Patients with ankylosing spondylitis (AS) are prone to spinal fractures even after low-energy trauma. Posterior fusion through open surgery has been the standard procedure for spinal fractures in patients with AS. Minimally invasive surgery (MIS) has been proposed as an alternative treatment option. There are few literature reports regarding patients with AS being treated for spinal fractures with MIS. This study aims to present the clinical outcome of a series of patients with AS treated with MIS for spinal fractures.

Methods: We included a consecutive series of patients with AS who underwent MIS for thoracolumbar fractures between 2014 and 2021. The median follow-up was 38 (12–75) months. Medical records and radiographs were reviewed, and data on surgery, reoperations, complications, fracture healing, and mortality were recorded.

Results: Forty-three patients (39 [91%] men) were included with a median (range) age of 73 (38–89) years. All patients underwent image-guided MIS with screws and rods. Three patients underwent reoperations, all due to wound infections. One patient (2%) died within 30 days and 7 (16%) died within the first year after surgery. Most patients with a radiographic follow-up of 12 months or more (29/30) healed with a bony fusion on computed tomography (97%).

Conclusion: Patients with AS and a spinal fracture are at risk of reoperation and have significant mortality during the first year. MIS provides adequate surgical stability for fracture healing with an acceptable number of complications and is an adequate choice in treating AS-related spinal fractures.

Level of Evidence: 4

Minimally Invasive Surgery

Keywords: ankylosing spondylitis, minimally invasive surgery, thoracolumbar fractures

INTRODUCTION

Ankylosing spondylitis (AS) is a chronic, seronegative, and systemic inflammatory disease with progressive enthesopathy causing erosion of the joints, discs, and ligaments of the spinal column followed by ossification and autofusion of the spine.[1,2] Patients with AS have a high prevalence of extra-articular manifestations (eg, lung fibrosis, emphysema, psoriasis, and osteoporosis) and cardiovascular pathologies.[3–6] The prevalence of AS in Sweden has been estimated to be 0.18% to 0.24%, with the highest prevalence in the Northern region.[7–9] Autofusion of the spine, in conjunction with secondary osteopenia, leaves patients with AS susceptible to fractures.[2,10,11] The fractures are usually unstable because of a long lever arm, and surgical treatment with long constructs is often required to withstand shearing forces across the fracture site.[12,13]

Posterior fusion through open surgery has been the standard procedure for spinal fractures in patients with AS.[13–15] Minimally invasive surgery (MIS) has been proposed as an alternative treatment option that could limit bone fusion because of the absence of bone grafting. There are few literature reports on patients with AS treated for spinal fractures with MIS.[16–23] Therefore, this study aims to present clinical outcomes in a series of patients with AS treated with MIS for thoracolumbar spinal fractures.

MATERIALS AND METHODS

Study Design and Setting

This study is a retrospective cohort study that includes patients with thoracolumbar fractures and AS. The study was conducted at the Department of Orthopedics at Umeå University Hospital between January 2014 and December 2021. Umeå University Hospital is a level 1 trauma center affiliated with Umeå University

Downloaded from https://www.ijssurgery.com/ by guest on October 12, 2024

Copyright 2023 by International Society for the Advancement of Spine Surgery.

and has a catchment area for spinal trauma surgery of approximately 900,000 inhabitants.

Data Collection and Follow-Up

We included a consecutive series of patients older than 18 years who underwent surgery for unstable thoracolumbar fractures due to AS. Patients with type A fractures, treated with open surgery, pathological fractures, osteoporosis, or diffuse idiopathic skeletal hyperostosis (DISH) were excluded.[24] For the exclusion of patients with DISH, we used the criteria from Resnick et al that state at least 2 to 3 adjacent vertebrae have to show bony bridges with nearly normal intervertebral discs and without sacroiliac or apophyseal joint fusion.[25] Additionally, all patients without previous AS diagnosis, regardless of the presence of ankylosis in the spine, were investigated using New York criteria with radiological evaluation of sacroiliac joints for the presence of ankylosis.[26] Patients without a previously documented diagnosis of AS and/or radiological signs of ankylosis of the sacroiliac joints were excluded from the study because of suspicion of DISH changes falsely diagnosed as AS. A flowchart of the selection process is provided in Figure 1.

We used the unique personal identification number given to all permanent residents of Sweden to collect data, including a review of medical records. Patient data included age, sex, American Society of Anesthesiologists classification, cognitive impairment, initial treatment, pre- and postoperative neurological function according to the American Spine Injury Association (ASIA),[27] comorbidity, reoperation, and date of death. Reoperation and mortality were recorded until October 2022.

Radiographic Assessment

Anatomical level and fracture classification according to the AO Spine thoracolumbar classification system were obtained through preoperative computed tomography (CT). Magnetic resonance imaging was performed to evaluate the posterior column, intraspinal traumatic compression (hematoma), and instability. Postoperative bone fusion was assessed with CT at the last postoperative follow-up. Fusion was defined as visible bone-bridging callus across the fracture.

Outcome Measurements

Reoperation was defined as undergoing a secondary surgical procedure (eg, failure of fixation with subsequent implant loosening, surgical debridement, antibiotics, and implant retention due to deep postoperative infection). Minor reoperation was defined as the removal of an implant after subsequent healing of the fracture. Bony fusion was defined as visible bridging trabeculations with or without bony remodeling and callus formation across the fracture.

Medical complications were defined according to Lebude et al.[28] Neurological deficits were determined using the ASIA score, where only clinically significant sensory and motor deficits were regarded as neurological deficits.[27] Significant motor deficits were defined as a reduced function of 1 or more myotomes with an ASIA score of 3/5 or less. Significant sensory deficits were defined as an ASIA score of 1/2 or less in 2 or more dermatomes.

Implant and Surgery

Surgeries were performed under general anesthesia in a prone position on a Jackson table. The chest roll, iliac crest, and thigh support in different shapes and sizes accommodated the kyphotic deformity. Patients with severe thoracolumbar deformities were also positioned on the Jackson table, however, without thigh support with legs hanging in the hammock to adjust for the curvature to minimize the risk of additional extension and translation across the fracture. Antibiotic prophylaxis was given in 3 doses of 2 g of cloxacillin (Ekvacillin, Meda, Sweden) at 0.5 hours before and 2 and 6 hours after the start of surgery. Clindamycin (Dalacin, Pfizer AB, Sweden) was used in patients with anaphylaxis to penicillin in 3 doses of 600 mg at the beginning of surgery and then at 8-hour intervals. In 6 patients, 1 preoperative dose of broad-spectrum antibiotics, either cefuroxime or cefotaxim, was used (Zinacef, GlaxoSmithKline, Sweden and Claforan, Sanofi AB, Sweden) because of suspected pneumonia. Therapy continued with 1 dose every 8 hours daily for 10 days. Thromboprophylaxis with subcutaneous low molecular weight heparin (Fragmin, Pfizer AB, Sweden or Innohep, LEO Pharma, Denmark) was given for 10 days. Under the supervision of a physiotherapist, all ambulatory (ASIA E, D) patients were mobilized to full weight bearing on the first postoperative day. Patients with a neurological deficit (ASIA A, B, C) were referred for neurorehabilitation. Passive mobilization to a sitting position was initiated on the first postoperative day to prevent postoperative complications. All surgeries were performed by a consultant orthopedic surgeon or neurosurgeon specialized in spine surgery.

Downloaded from https://www.ijssurgery.com/ by guest on October 12, 2024

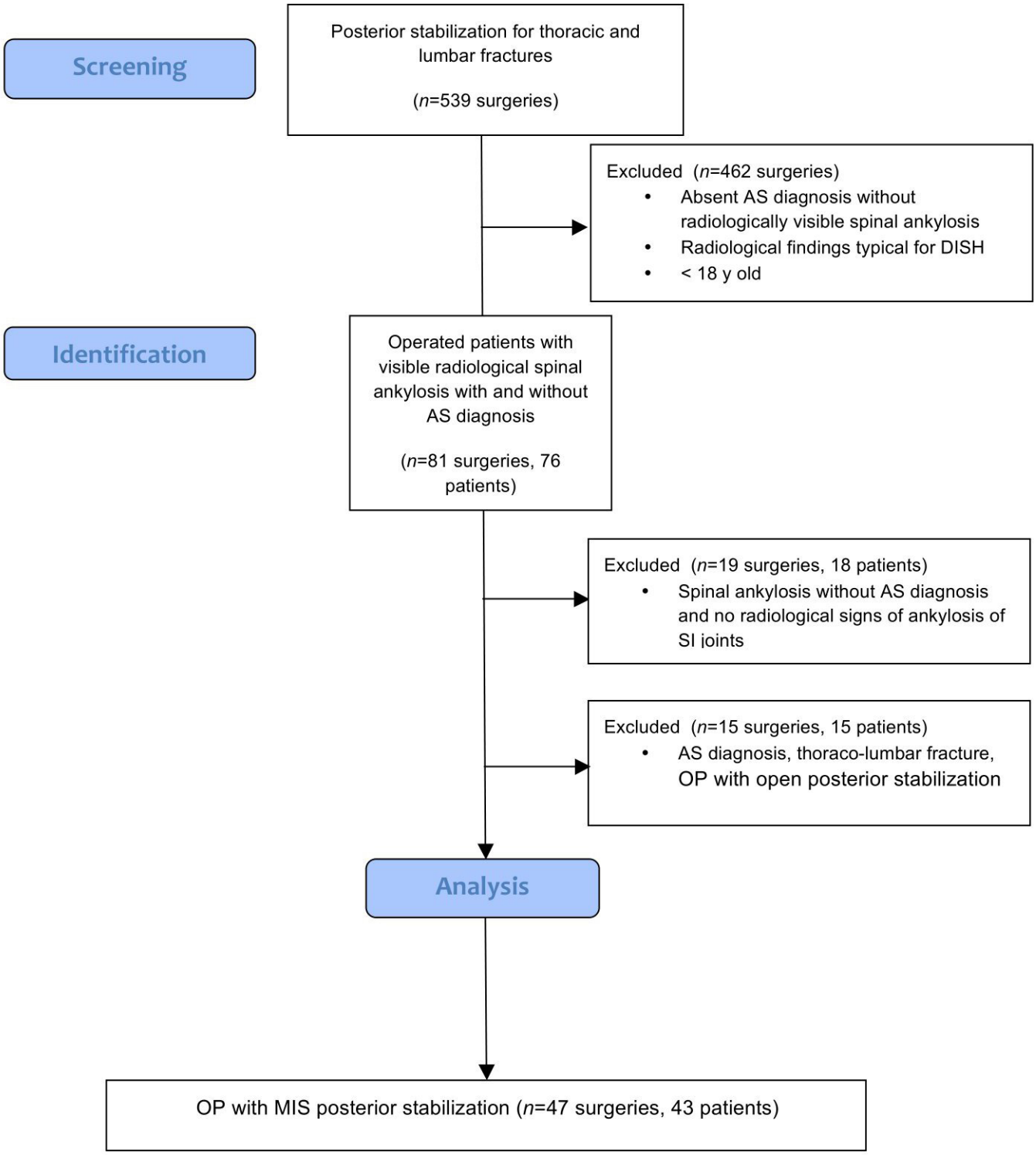

Figure 1. Flowchart of patients. AS, ankylosing spondylitis; DISH, diffuse idiopathic skeletal hyperostosis; MIS, minimally invasive surgery; SI, sacroiliac.

Minimally Invasive Surgery

For MIS procedures, either Everest (K2M, Leesburg, VA, USA, $N = 14$) or Longitude II (Medtronic, Minneapolis, MN, USA, $N = 29$) was used. The first step of the procedure was the attachment of the reference frame to the spinal process at the most caudal vertebrae included in instrumentation. In case instrumentation extended over more than 5 segments, double registration was required. After that, cannulated polyaxial screws were implanted percutaneously with the assistance of guide

Downloaded from https://www.ijssurgery.com/ by guest on October 12, 2024

wires using navigated instruments in combination with O-arm connected to StealthStation (Medtronic, Sofamor Danek, Memphis, TN, USA) in all cases. Intraoperative image acquisition was performed to control the position of the implanted screws. The rods were placed bilaterally, inserted subfascially, and locked. A central decompression was performed in 1 patient with ASIA C. After hemostasis and wound washout, stabs ($N = 19$) or midline incisions ($N = 24$) were closed in layers in a watertight fashion. Decortication, bone harvesting, and implantation were not performed in any cases.

Statistics

Descriptive statistics for continuous variables are presented as medians with ranges and categorical data as numbers and percentages. Postoperative survival was estimated using the Kaplan-Meier method with death as an event. The statistical package SPSS for Mac (version 26.0; IBM Corp., Armonk, NY, USA) was applied for statistical analyses.

Ethics

The study complied with the ethical principles of the Helsinki declaration and was approved by the Swedish Ethical Review Authority (DNR 2019-01068 and 2021-06873-02).

RESULTS

Patients and Descriptive Data

In all, 43 patients (39 men and 4 women) were included and 495 were excluded (Figure 1). The median age at the time of surgery was 73 (38–89) years (Table 1). Three patients (7%) presented with neurological deficits; 1 of them suffered from paraplegia years before the trauma. Two patients were classified as ASIA A and 1 as ASIA C but with a Brown-Sequard pattern with a motor deficit in the right leg. The 2 patients with ASIA A did not recover after surgery, whereas the patient with ASIA C recovered completely to ASIA E. The trauma mechanism was low energy in 33 patients and high energy in 10 (Table 2). Median follow-up was 38 (12–75) months. One patient (2%) died within 30 days and 7 (16%) died within the first year after surgery.

Table 1. Clinical characteristics of patients undergoing minimally invasive surgery for ankylosing spondylitis.

Characteristics	*n*
Age at surgery, y, median (range)	73 (38–89)
Sex, male	39
American Society of Anesthesiologists classification	
1–2	17
3–4	26
Comorbidity	
Hypertension	23
Diabetes mellitus	10
Coronary artery disease	10
Lung disease	8
Asthma	5
Chronic obstructive pulmonary disease	3
Malignancy	7
Neurological disease	
Cerebellar ataxia	1
Dementia	2
Cerebrovascular disease	2
Alcohol abuse	4

Note: Data presented as n unless otherwise noted.

Table 2. Details on surgery, levels of fixation, and trauma ($N = 43$).

Operative Details	*n*
Surgery duration, min, median (range)	140 (80–300)
Perioperative blood loss, mL, median (range)	100 (50–410)
AO/OTA	
B2	2
B3	41
Level of fixation	
≤5	24
6	15
≥7	4
Trauma mechanism	
Low energy	33
High energy	10

Abbreviation: OTA, Orthopaedic Trauma Association.
Note: Data presented as *n* unless otherwise noted.

Fracture Classification

The proximal level of the fracture was most commonly located in the thoracic spine ($n = 36$); 7 fractures were located only in the lumbar ($n = 6$) or the lumbar and sacral spine ($n = 1$). Two patients had a fracture classified as B2; all the other fractures were classified as B3 according to AO/Orthopaedic Trauma Association classification. The most common fracture site was between T9 and L1 vertebrae ($n = 31$). Two patients (4%) sustained more than 1 fracture.

Surgical Treatment

All patients underwent a posterior approach with pedicle screws and fixation with rods. Three patients underwent more than 1 surgery (2 patients were operated on twice and 1 patient 3 times) because of repetitive trauma and adjacent fractures. The median (range) surgical duration was 140 (80–300) minutes and blood loss was 100 (50–410) mL (Table 2).

Radiographic Assessment

Fusion at 12 months or more with follow-up CT examinations (Figure 2) could be seen in 29 of 30 patients

Downloaded from https://www.ijssurgery.com/ by guest on October 12, 2024

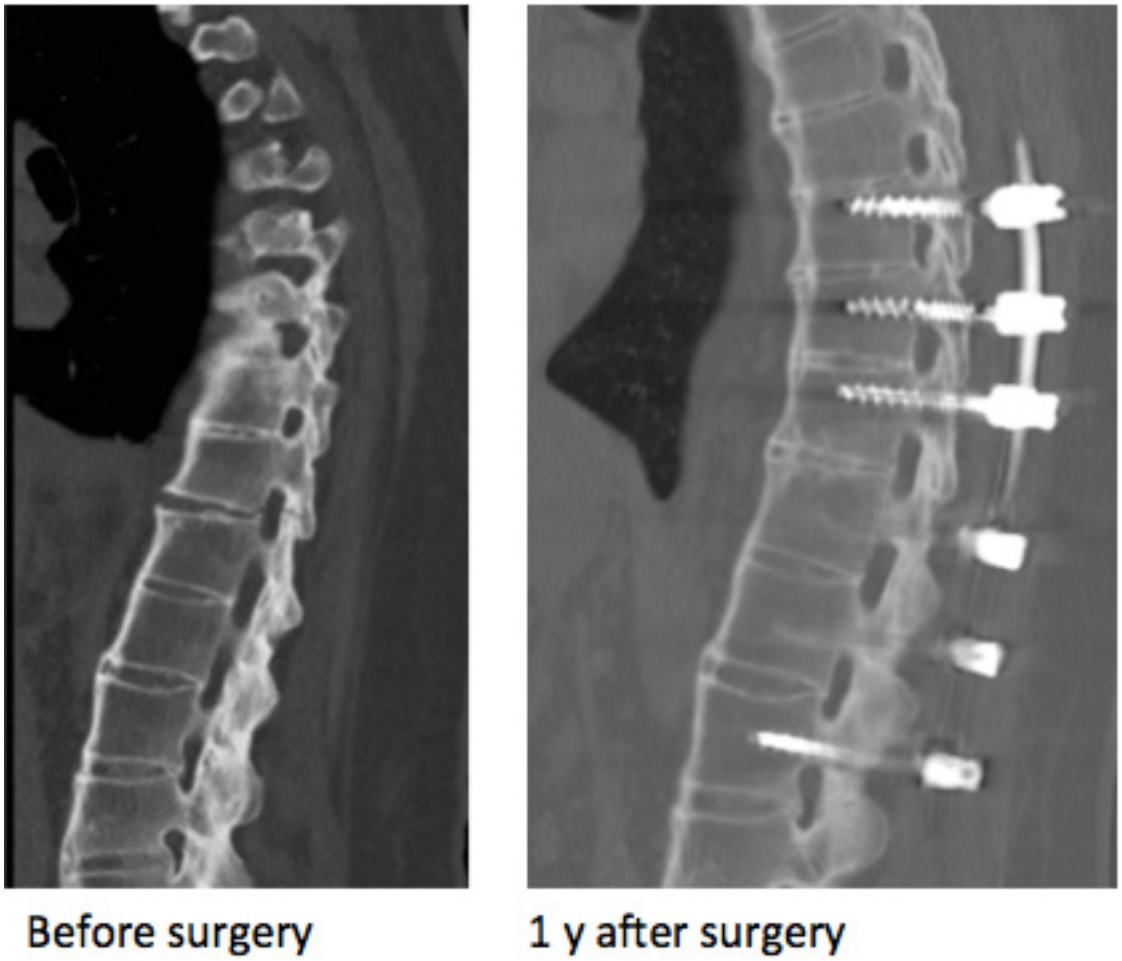

Figure 2. Preoperative and 1 y postoperative computed tomographic images.

(97%). Only 1 patient showed no visible fusion. This patient had a partial fusion but did not require revision. Four patients canceled the 1-year follow-up CT examination due to no pain, 7 patients died, and 2 patients did not return at the 1-year follow-up.

Reoperations

Three patients underwent reoperations because of wound infections (1 superficial and 2 deep infections). Loosening of 2 proximal screws was encountered in 2 patients. Loosening was discovered during the revision of deep wound infection.

Complications

Complications were seen in 11 patients (26%). Systemic postoperative complications occurred in 7 patients (16%), whereas postoperative surgical complications were detected in 4 patients (9%) (Table 3). Five of 7 patients (71%) with systemic complications and 2 of 4 patients (50%) with postoperative surgical complications were classified as having major complications.

DISCUSSION

AS patients with a spinal fracture are at risk of reoperation and significant mortality during the first year. We found that MIS is a good choice with adequate surgical stability for fracture healing in the present population.

Table 3. Medical and surgical complications.

Complication	*n*
Medical complications	
Pneumonia	2
Pulmonary embolism	1
Paralytic ileus	1[b]
Heart failure	2[a,b]
Kidney failure	2[a,b]
Deep venous thrombosis	1
Delirium	1
Surgical complications	
Superficial wound infection	1
Deep infection with screw loosening and revision	2
Mechanical failure	0
Pressure ulcer	1
Nonfusion at 1 y	1

[a]Paralytic ileus with cardiac arrest; died days after surgery.
[b]Patient with both heart and kidney failure after surgery.

Downloaded from https://www.ijssurgery.com/ by guest on October 12, 2024

The literature on surgical treatment in AS patients is sparse, with limited studies on MIS in AS patients with a thoracolumbar fracture.[16–23,29,30] Most of these studies are case series, including patients with DISH. We excluded all patients with DISH due to different prevalence, pathology, demographic, and mechanical features to focus solely on AS patients.[31–36]

The combination of a rigid spinal column and osteopenia results in a 10× increased risk of spinal fractures and a higher incidence of neurological deficits compared with non-AS patients.[37] Therefore, surgical stabilization with long posterior constructs with screws and rods is recommended to maintain mechanical stability, prevent secondary injury, and enable bony fusion.[12,13]

The overall complication rate after surgery for spinal fractures in patients with AS varies between 30% and 90%.[12,15,38–41] Patients with AS have a high prevalence of cardiovascular pathologies with a significantly increased risk of cardiac-related mortality compared with the general population.[4,5,12] Puvanesarajah et al reported significantly higher surgical site infection, transfusion rate, respiratory failure, pneumonia, and acute renal failure in AS patients compared with proportion-matched groups without AS.[39] Open surgery is considered a standard procedure for AS patients with thoracolumbar fractures but is associated with significant postoperative morbidity.[12,40,42] Open surgery requires considerable exposure and extensive dissection of fascia and muscles, causing injury to the small vessels and nerves surrounding the spinal column.[15] Prolonged surgery in a prone position in patients with a high prevalence of comorbidities could adversely affect the risk of postoperative complications.[3,6] The rationale for using MIS is that a shorter surgical duration with lesser surgical soft tissue trauma and perioperative blood loss would minimize postoperative pain and facilitate mobilization and fracture healing. The skepticism in using MIS stabilization to treat fractures in AS patients is usually related to 3 issues: radiation exposure, screw misplacement, and risk of pseudarthrosis. MIS fixation in patients with high body index and/or advanced deformity, especially in upper thoracic region, can be technically demanding without the use of navigation. However, all consecutive patients in our study underwent operations with an image-guided technique that provides higher precision of screw placement in spinal surgery and limits exposure to radiation for the surgeon and the operating team.[43–45] Recent evidence suggests that MIS provides sufficient fracture stabilization with reduced risk of complications compared with open surgery.[17,22]

The use of MIS in AS patients seems promising, but previous studies were of level 3 or 4 evidence with a few cases or included a mix of patients with DISH and AS.[16,17,23,30] Most patients in our study who underwent radiological follow-up developed bony fusion, despite being treated without bone grafting. The pathophysiology of AS facilitates autofusion by osteoproliferation and ankylosis.[1] Several studies support our findings of the high fusion rate in AS patients despite using MIS.[17,18] Few of our patients suffered from spinal cord injuries because of the fracture, which is consistent with findings reported by Lukasiewicz et al.[38] However, other reports found higher incidences of spinal cord injuries (up to 33%–50%) in cases with AS and thoracic and thoracolumbar fractures.[37,40,46,47] We found a 30-day mortality rate of 2% and a 1-year mortality rate of 16%. The 1-year mortality rate has been reported to be between 17% and 56%,[12,15,23,41] with in-hospital mortality between 6% and 7%,[13,38,40] though mortality rates up to 28% have also been presented.[46]

Strengths and Limitations

The main limitation of this study relates to the inherited flaws of the retrospective design. Another limitation is the small sample size that prevents statistical analysis from identifying covariates associated with the outcome. Additionally, some clinical factors and details could not be assessed from the medical records and limited completeness of radiologic follow-up with a high rate of loss to follow-up. Despite these limitations, our study is the largest consecutive single-center cohort of patients with AS treated for thoracolumbar fractures with navigated MIS. We investigated a highly selected cohort by excluding all patients with potential DISH to provide reliable data without confounding conditions with possible differences in prevalence, etiology, pathophysiology, skeletal changes, and biomechanics.

CONCLUSION

Patients with a spinal fracture due to AS are at risk of reoperation and have significant mortality during the first year after injury. Our study shows that MIS provides adequate surgical stability for fracture healing and is a viable alternative to open surgery with less risk of soft tissue injury.

REFERENCES

1. Lories RJ. Advances in understanding the pathophysiology of spondyloarthritis. *Best Practice & Research Clinical Rheumatology*. 2018;32(3):331–341. doi:10.1016/j.berh.2018.12.001

Downloaded from https://www.ijssurgery.com/ by guest on October 12, 2024

2. Maas F, Spoorenberg A, van der Slik BPG, et al. Clinical risk factors for the presence and development of vertebral fractures in patients with Ankylosing Spondylitis. *Arthritis Care Res (Hoboken)*. 2017;69(5):694–702. doi:10.1002/acr.22980

3. El Maghraoui A. Extra-articular manifestations of ankylosing spondylitis: prevalence, characteristics and therapeutic implications. *Eur J Intern Med*. 2011;22(6):554–560. doi:10.1016/j.ejim.2011.06.006

4. Roldan CA. Valvular and coronary heart disease in systemic inflammatory diseases: systemic disorders in heart disease. *Heart*. 2008;94(8):1089–1101. doi:10.1136/hrt.2007.132787

5. Liew JW, Ramiro S, Gensler LS. Cardiovascular morbidity and mortality in ankylosing spondylitis and psoriatic arthritis. *Best Practice & Research Clinical Rheumatology*. 2018;32(3):369–389. doi:10.1016/j.berh.2019.01.002

6. Quismorio FP. Pulmonary involvement in ankylosing spondylitis. *Curr Opin Pulm Med*. 2006;12(5):342–345. doi:10.1097/01.mcp.0000239551.47702.f4

7. Exarchou S, Lindström U, Askling J, et al. The prevalence of clinically diagnosed Ankylosing Spondylitis and its clinical manifestations: a nationwide register study. *Arthritis Res Ther*. 2015;17(1):118. doi:10.1186/s13075-015-0627-0

8. Braun J, Sieper J. Ankylosing spondylitis. *Lancet*. 2007;369(9570):1379–1390. doi:10.1016/S0140-6736(07)60635-7

9. Haglund E, Bremander AB, Petersson IF, et al. Prevalence of spondyloarthritis and its subtypes in southern Sweden. *Ann Rheum Dis*. 2011;70(6):943–948. doi:10.1136/ard.2010.141598

10. Feldtkeller E, Vosse D, Geusens P, van der Linden S. Prevalence and annual incidence of vertebral fractures in patients with ankylosing spondylitis. *Rheumatol Int*. 2006;26(3):234–239. doi:10.1007/s00296-004-0556-8

11. van der Weijden MAC, Claushuis TAM, Nazari T, Lems WF, Dijkmans BAC, van der Horst-Bruinsma IE. High prevalence of low bone mineral density in patients within 10 years of onset of ankylosing spondylitis: a systematic review. *Clin Rheumatol*. 2012;31(11):1529–1535. doi:10.1007/s10067-012-2018-0

12. Caron T, Bransford R, Nguyen Q, Agel J, Chapman J, Bellabarba C. Spine fractures in patients with ankylosing spinal disorders. *Spine (Phila Pa 1976)*. 2010;35(11):E458–64. doi:10.1097/BRS.0b013e3181cc764f

13. Westerveld LA, Verlaan JJ, Oner FC. Spinal fractures in patients with ankylosing spinal disorders: A systematic review of the literature on treatment, neurological status and complications. *Eur Spine J*. 2009;18(2):145–156. doi:10.1007/s00586-008-0764-0

14. Robinson Y, Sandén B, Olerud C. Increased occurrence of spinal fractures related to ankylosing spondylitis: a prospective 22-year cohort study in 17,764 patients from a national registry in Sweden. *Patient Saf Surg*. 2013;7(1):2. doi:10.1186/1754-9493-7-2

15. Rustagi T, Drazin D, Oner C, et al. Fractures in spinal ankylosing disorders: a narrative review of disease and injury types, treatment techniques, and outcomes. *J Orthop Trauma*. 2017;31 Suppl 4:S57–S74. doi:10.1097/BOT.0000000000000953

16. Yeoh D, Moffatt T, Karmani S. Good outcomes of percutaneous fixation of spinal fractures in Ankylosing spinal disorders. *Injury*. 2014;45(10):1534–1538. doi:10.1016/j.injury.2014.03.020

17. Moussallem CD, McCutcheon BA, Clarke MJ, et al. Perioperative complications in open versus percutaneous treatment of spinal fractures in patients with an Ankylosed spine. *J Clin Neurosci*. 2016;30:88–92. doi:10.1016/j.jocn.2016.01.020

18. Bredin S, Fabre-Aubrespy M, Blondel B, et al. Percutaneous surgery for thoraco-lumbar fractures in Ankylosing Spondylitis: Study of 31 patients. *Orthop Traumatol Surg Res*. 2017;103(8):1235–1239. doi:10.1016/j.otsr.2017.07.023

19. Buxbaum RE, Shani A, Mulla H, Rod A, Rahamimov N. Percutaneous, PMMA-augmented, pedicle screw instrumentation of thoracolumbar ankylotic spine fractures. *J Orthop Surg Res*. 2021;16(1):317. doi:10.1186/s13018-021-02420-7

20. Trungu S, Ricciardi L, Forcato S, Miscusi M, Raco A. Percutaneous instrumentation with cement augmentation for traumatic Hyperextension Thoracic and lumbar fractures in Ankylosing Spondylitis: A single-institution experience. *Neurosurg Focus*. 2021;51(4):2021.7.FOCUS21308. doi:10.3171/2021.7.FOCUS21308

21. Brooks F, Rackham M, Williams B, Roy D, Lee YC, Selby M. Minimally invasive stabilization of the fractured ankylosed spine: a comparative case series study. *J Spine Surg*. 2018;4(2):168–172. doi:10.21037/jss.2018.05.01

22. Krüger A, Frink M, Oberkircher L, El-Zayat BF, Ruchholtz S, Lechler P. Percutaneous dorsal instrumentation for Thoracolumbar extension-distraction fractures in patients with Ankylosing spinal disorders: A case series. *The Spine Journal*. 2014;14(12):2897–2904. doi:10.1016/j.spinee.2014.04.018

23. Schwendner M, Seule M, Meyer B, Krieg SM. Management of spine fractures in Ankylosing Spondylitis and diffuse idiopathic Skeletal Hyperostosis: A challenge. *Neurosurg Focus*. 2021;51(4):2021.7.FOCUS21330. doi:10.3171/2021.7.FOCUS21330

24. Forestier J, Rotes-querol J. Senile ankylosing hyperostosis of the spine. *Ann Rheum Dis*. 1950;9(4):321–330. doi:10.1136/ard.9.4.321

25. Resnick D, Niwayama G. Radiographic and pathologic features of spinal involvement in diffuse idiopathic skeletal hyperostosis (DISH). *Radiology*. 1976;119(3):559–568. doi:10.1148/119.3.559

26. Feldtkeller E, Khan MA, van der Heijde D, van der Linden S, Braun J. Age at disease Onset and diagnosis delay in HLA-B27 negative vs. positive patients with ankylosing spondylitis. *Rheumatol Int*. 2003;23(2):61–66. doi:10.1007/s00296-002-0237-4

27. Maynard FM Jr, Bracken MB, Creasey G, et al. International standards for neurological and functional classification of spinal cord injury. *Spinal Cord*. 1997;35(5):266–274. doi:10.1038/sj.sc.3100432

28. Lebude B, Yadla S, Albert T, et al. Defining "complications" in spine surgery: neurosurgery and orthopedic spine surgeons' survey. *J Spinal Disord Tech*. 2010;23(8):493–500. doi:10.1097/BSD.0b013e3181c11f89

29. Sedney CL, Daffner SD, Obafemi-Afolabi A, et al. A comparison of open and percutaneous techniques in the operative fixation of spinal fractures associated with ankylosing spinal disorders. *Int J Spine Surg*. 2016;10:23. doi:10.14444/3023

30. Nayak NR, Pisapia JM, Abdullah KG, Schuster JM. Minimally invasive surgery for traumatic fractures in ankylosing spinal diseases. *Global Spine Journal*. 2015;5(4):266–273. doi:10.1055/s-0034-1397341

31. Olivieri I, D'Angelo S, Palazzi C, Padula A, Mader R, Khan MA. Diffuse idiopathic Skeletal Hyperostosis: Differentiation from Ankylosing Spondylitis. *Curr Rheumatol Rep*. 2009;11(5):321–328. doi:10.1007/s11926-009-0046-9

32. Shah NG, Keraliya A, Harris MB, Bono CM, Khurana B. Spinal trauma in DISH and AS: Is MRI essential following the detection of vertebral fractures on CT? *Spine J*. 2021;21(4):618–626. doi:10.1016/j.spinee.2020.10.027

Downloaded from https://www.ijssurgery.com/ by guest on October 12, 2024

33. Weinfeld RM, Olson PN, Maki DD, Griffiths HJ. The prevalence of diffuse idiopathic Skeletal Hyperostosis (DISH) in two large American Midwest metropolitan hospital populations. *Skeletal Radiol*. 1997;26(4):222–225. doi:10.1007/s002560050225

34. Westerveld LA, van Ufford HMEQ, Verlaan J-J, Oner FC. The prevalence of diffuse idiopathic skeletal hyperostosis in an outpatient population in the Netherlands. *J Rheumatol*. 2008;35(8):1635–1638.

35. Mader R, Verlaan JJ, Buskila D. Diffuse idiopathic skeletal hyperostosis: Clinical features and pathogenic mechanisms. *Nat Rev Rheumatol*. 2013;9(12):741–750. doi:10.1038/nrrheum.2013.165

36. Kuperus JS, Mohamed Hoesein FAA, de Jong PA, Verlaan JJ. Diffuse idiopathic Skeletal Hyperostosis: Etiology and clinical relevance. *Best Pract Res Clin Rheumatol*. 2020;34(3):101527. doi:10.1016/j.berh.2020.101527

37. Alaranta H, Luoto S, Konttinen YT. Traumatic spinal cord injury as a complication to Ankylosing Spondylitis. An extended report. *Clin Exp Rheumatol*. 2002;20(1):66–68.

38. Lukasiewicz AM, Bohl DD, Varthi AG, et al. Spinal fracture in patients with ankylosing spondylitis: cohort definition, distribution of injuries, and hospital outcomes. *Spine (Phila Pa 1976)*. 2016;41(3):191–196. doi:10.1097/BRS.0000000000001190

39. Puvanesarajah V, Cancienne JM, Shimer AL, Shen FH, Hassanzadeh H. Complications after fusion for thoracolumbar fractures in patients with ankylosing spondylitis. *Global Spine J*. 2017;7(1):28–32. doi:10.1055/s-0036-1583175

40. Westerveld LA, van Bemmel JC, Dhert WJA, Oner FC, Verlaan JJ. Clinical outcome after traumatic spinal fractures in patients with Ankylosing spinal disorders compared with control patients. *Spine J*. 2014;14(5):729–740. doi:10.1016/j.spinee.2013.06.038

41. Sharma M, Jain N, Wang D, Ugiliweneza B, Boakye M, Drazin D. Impact of age on mortality and complications in patients with ankylosing spondylitis spine fractures. *J Clin Neurosci*. 2022;95:188–197. doi:10.1016/j.jocn.2021.11.035

42. Ishak B, Frieler S, Rustagi T, et al. Rates of early complications and mortality in patients older than 80 years of age after surgical treatment of acute traumatic spinal fractures: Ankylosing Spondylitis versus osteoporosis. *Neurosurg Focus*. 2021;51(4):2021.7.FOCUS21150. doi:10.3171/2021.7.FOCUS21150

43. Van de Kelft E, Costa F, Van der Planken D, Schils F. A prospective multicenter Registry on the accuracy of Pedicle screw placement in the Thoracic, lumbar, and sacral levels with the use of the O-arm imaging system and Stealthstation navigation. spine (Phila PA 1976). *Spine*. 2012;37(25):E1580–E1587. doi:10.1097/BRS.0b013e318271b1fa

44. Silbermann J, Riese F, Allam Y, Reichert T, Koeppert H, Gutberlet M. Computer tomography assessment of Pedicle screw placement in lumbar and sacral spine: Comparison between free-hand and O-arm based navigation techniques. *Eur Spine J*. 2011;20(6):875–881. doi:10.1007/s00586-010-1683-4

45. Chang CC, Chang HK, Wu JC, Tu TH, Cheng H, Huang WC. Comparison of radiation exposure between O-arm Navigated and C-arm guided screw placement in minimally invasive Transforaminal lumbar Interbody fusion. *World Neurosurgery*. 2020;139:e489–e495. doi:10.1016/j.wneu.2020.04.052

46. Teunissen FR, Verbeek BM, Cha TD, Schwab JH. Spinal cord injury after traumatic spine fracture in patients with Ankylosing spinal disorders. *J Neurosurg Spine*. 2017;27(6):2017.5.SPINE1722):709–716:. doi:10.3171/2017.5.SPINE1722

47. Jacobs WB, Fehlings MG. Ankylosing Spondylitis and spinal cord injury: Origin, incidence, management, and avoidance. *Neurosurg Focus*. 2008;24(1):E12. doi:10.3171/FOC/2008/24/1/E12

Funding: The authors received no financial support for the research, authorship, and/or publication of this article.

Declaration of Conflicting Interests: The authors report no conflicts of interest in this work.

Corresponding Author: Johan Wänman, Department of Surgical and Perioperative Sciences (Orthopedics), Umeå University, Umeå, Sweden; johan.wanman@umu.se

This manuscript is generously published free of charge by ISASS, the International Society for the Advancement of Spine Surgery. Copyright © 2023 ISASS. To see more or order reprints or permissions, see http://ijssurgery.com.

Downloaded from https://www.ijssurgery.com/ by guest on October 12, 2024