

## Defining Clinically Relevant Proximal Junctional Kyphosis

Jeffrey Hills and Michael P. Kelly

*Int J Spine Surg* published online 13 September 2023  
<https://www.ijssurgery.com/content/early/2023/09/11/8516>

This information is current as of May 7, 2025.

---

**Email Alerts** Receive free email-alerts when new articles cite this article. Sign up at:  
<http://ijssurgery.com/alerts>

# Defining Clinically Relevant Proximal Junctional Kyphosis

JEFFREY HILLS, MD<sup>1</sup> AND MICHAEL P. KELLY, MD<sup>2</sup>

<sup>1</sup>Orthopedic Surgery, University of Texas, San Antonio, TX, USA; <sup>2</sup>Rady Children's Hospital, University of California, San Diego, CA, USA

## ABSTRACT

Proximal junctional kyphosis and failure are not infrequent complications of adult spinal deformity reconstructions. Efforts to define proximal junctional kyphosis have ranged from expert opinions to statistical analyses of large databases. These approaches fail to recognize that proximal junctional kyphosis/failure/breakdown is likely a spectrum of manifestations secondary to spinal fusions and spinal alignment. The dichotomization (clinically irrelevant vs clinically relevant) of continuous measures will lead to misclassification and misdiagnosis. As adult spinal deformity moves to a precision-medicine-based approach (also known as personalized medicine), work is required to develop probabilistic models to inform patients and surgeons about the likely survivorship of a proximal junctional failure. As such, it is likely better to call proximal junctional segment kyphosis without symptoms “asymptomatic proximal junctional kyphosis” rather than to determine thresholds for “symptomatic” or “clinically relevant.”

Focus Issue Article

Keywords: proximal junctional kyphosis, failure, complication, glattes

## INTRODUCTION

Proximal junctional kyphosis (PJK) is a vexing complication of adult spinal deformity. The presentation of PJK varies widely, from asymptomatic radiographic changes to dislocation with acute paraplegia. This variety of presentations leads to a variety of different terms for proximal junctional failure (PJF), which are often categorized by radiographic severity: adjacent segment degeneration (ASD), PJK, and PJF. While clinicians appreciate categorization of disease states, it is important to understand that categorization of continuous variables leads to misclassification and erroneous conclusions. To that end, it is important to appreciate that failures of the proximal segment, both “small” and “large,” may have a common origin. The clinical manifestation of PJF may vary from patient to patient based on particular patient characteristics despite similar surgical techniques and alignment. For example, a flat sagittal plane may lead to early adjacent disc breakdown in one patient vs a compression fracture of the adjacent segment in another. If we are to rely on categorization of these 2 problems: “mild” ASD vs PJF, one can then see how analyses investigating (1) factors associated with the event and (2) the clinical relevance of the event may be misleading. It is easier to define and consider clinically irrelevant PJK. This would be segmental kyphosis beyond that which is normally expected in that patient (for a patient of similar pelvic incidence) that has no immediate effect on health-related quality of life and no effect on reoperation rates for progressive deformity or neurological deficit. In that sense, symptomatic PJK may be viewed as analogous to segmental

instability: an inability to bear physiological load without pain, progressive deformity, or new neurological deficit.

## HISTORY OF PROXIMAL FAILURE DEFINITIONS

PJK was first described and defined by Glattes et al.<sup>1</sup> These authors proposed a sagittal measurement of at least 10° between the upper instrumented vertebra and the suprajacent segment and a preoperative to postoperative change of 10° in this angle. Using these criteria, rates of PJK are as high as 60%. Revision rates for proximal failure after adult spinal deformity reconstructions are far lower than 60%, which led to appropriate criticisms of this definition, including by the authors themselves, who noted that PJK may be a radiographic phenomenon of no clinical relevance in many cases. Yagi et al proposed a comprehensive scheme that classified PJK by 3 characteristics<sup>2</sup>:

1. Location of failure
  - Type 1: Disc or ligament failure.
  - Type 2: Bony failure.
  - Type 3: Implant/bone interface failure.
2. Grade
  - A: Increase in proximal junctional angle from 10° to 19°.
  - B: Increase in proximal junctional angle from 20° to 29°.
  - C: Increase in proximal junctional angle greater than or equal to 30°.

**Table.** Hart-International Spine Study Group proximal junctional kyphosis severity scale.

Characteristic	Points
Neurological deficit	
None	0
Radicular pain	2
Myelopathy/motor deficit	4
Focal pain	
None	0
VAS $\leq 4$	1
VAS $\geq 5$	3
Instrumentation problem	
None	0
Partial fixation loss	1
Prominence	1
Complete fixation loss	2
Change in kyphosis/PLC integrity	
0° to 10°	0
10° to 20°	1
>20°	2
PLC failure	2
Upper instrumented vertebra/adjacent vertebra fracture	
None	0
Compression	1
Burst/chance fracture	2
Translation	3
Level of upper instrumented vertebra	
Thoracolumbar junction	0
Upper thoracic spine	1

Abbreviation: PLC, posterior ligamentous complex.

### 3. Spondylolisthesis

- N: No spondylolisthesis.
- S: Spondylolisthesis above the upper instrumented vertebra.

This classification provides descriptives beyond the Glattes classification but lacks clinical relevance. Hart et al provided a severity score to offer some clinical relevance to the incident PJK, though it is complicated by the classification of continuous data and the use of subjective measures<sup>3</sup> (Table). For example, implant failure is described as “partial loss” or “prominence” or “complete loss of fixation.” Once fixation is lost (eg, screws are loosened), it is lost, and there is no such situation as “partial loss of fixation.” The change from “partial loss” to “complete loss” involves the continued ventral displacement/movement of the spinal column from the instrumentation. In such a situation, the classification may measure the time from fixation loss, rather than something intrinsically related to the PJK.

## DEFINING CLINICAL RELEVANCE

Clinical relevance is difficult to define given 2 major factors: (1) the subjective nature of pain and patient-reported outcome measures and (2) the effect of time on the unfused segments. As previously noted, early reports describing PJK questioned whether it was a radiographic finding of rare clinical relevance. As any spine surgeons

knows, it is not infrequent for one patient to complain of pain in a setting where another has none, such as lumbar spinal stenosis.<sup>4</sup> Furthermore, considering the breadth of pain reports with similar problems, it is difficult to create thresholds for “clinically relevant.” What is a “clinically relevant” pain complaint? If one could define this, then some angular measurement will be chosen to balance sensitivity and specificity of this threshold. That is, the threshold chosen will still balance correct classifications with incorrect classifications in a manner considered appropriate by the clinician/researcher. While potentially useful for hypothesis generation, this broad approach to defining clinical relevance moves us further from a precision-medicine (also known as personalized) approach to spinal deformity care, where probabilities for any given situation will guide decision-making.

It is tempting for any spine surgeon to conclude that a complication is not clinically relevant.<sup>5</sup> The psychological advantage to us is clear as this absolves us of any harm to the patient. We have seen that clinical relevance can be time-dependent, as is the case with pseudarthrosis, with PJK progressing beyond 2 years of follow-up.<sup>6,7</sup> In our opinion, it is likely that any PJK in the form of an adjacent segment spondylolisthesis or fracture resulting in pedicle screws intruding into the adjacent disc space will lead to patient symptoms or complaints given sufficient time. It is possible that an adjacent fracture without screw intrusion will heal and become stable, as this is the situation that leads to the conclusion that PJK is a radiographic change. We are not confident that any single angular change of 10° to 15° to 20° at an adjacent segment will not remain asymptomatic given sufficient time. The amount of tolerable angular change may be related to the distance from the cranial center of mass as a longer distance will lead to (1) initially more ventral displacement of the cranial center of mass until (2) compensatory mechanisms are employed. It is not surprising then that PJK in the lower thoracic spine has a different history than PJK in the upper thoracic spine.<sup>8</sup> The PJK may be the result of and cause of deranged forces across the adjacent segment disc.<sup>9</sup> It is logical to believe that persistence of these deranged forces will lead to disc degeneration and, ultimately, a clinically relevant (detrimental) situation.

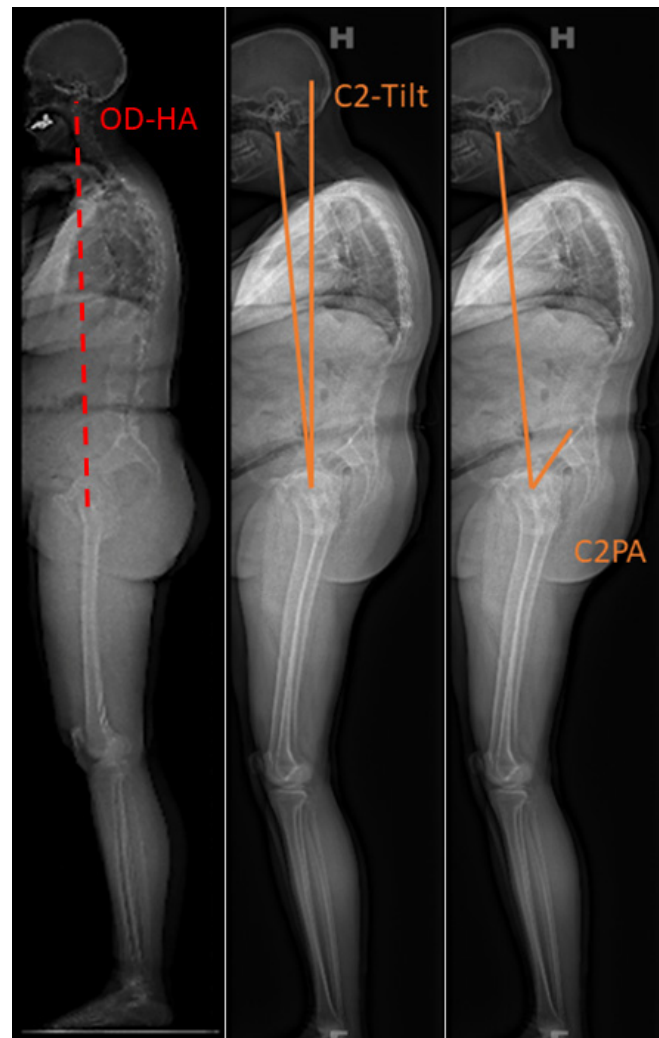
## EVOLVING UNDERSTANDING OF ALIGNMENT

While historical work has relied on measures of lumbar lordosis and thoracic kyphosis magnitude only, for example, pelvic incidence and lumbar lordosis mismatch, more recent work has shown the distribution

of kyphosis and lordosis to matter as well. The Global Alignment and Proportion Score found a higher risk of PJK and pseudarthrosis for cases with inappropriate measures of magnitude or distribution.<sup>10</sup> Rousouly described 4 spinal shapes based on sacral slope, where the sagittal curvatures increase in magnitude with increasing pelvic incidence.<sup>11</sup> Failure to restore these shapes to normal results in a higher risk of PJK. Analyses of normal (nondegenerated and nondeformed spines) confirmed the associations between spinal shape and pelvic incidence, though there are global alignment measures that are fairly consistent across pelvic incidence values.<sup>12</sup> One such measure is C2-tilt (angle subtended by a plumb line through the femoral heads and a line from the centroid of C2 to the femoral heads), also known as the “odontoid-hip-axis” (OD-HA). In normal posture, the C2-tilt and OD-HA are often  $-3^\circ$  to  $+1^\circ$ . With spinal malalignment, the C2-pelvic angle increases, resulting in increased pelvic tilt and, if severe, an increase in C2-tilt (Figure).

Recognition of these consistencies is important as we seek to define clinically relevant PJK. Perhaps mild, “clinically irrelevant” PJK exists to normalize the OD-HA. If the OD-HA stabilizes and the fracture heals, then a patient may possibly do well. However, if the fracture worsens and the OD-HA overcorrects, then PJK will continue to worsen and may be associated with increase in pain complaints and/or a neurological deficit and/or a bothersome spinal deformity. As we noted above, the shape of the spine required to achieve a consistent OD-HA will vary with pelvic incidence, which makes it unlikely that we will find any particular PJK angle with perfect sensitivity and specificity. Instead, we will find that relevant PJK angles are determined both by pelvic incidence, fused spine shape, and instrumentation levels. We believe it is likely that PJK that results in increasing pelvic tilt and an increasing C2-pelvic angle will result in a decline in health-related quality of life.

If we allow for clinically “silent” PJK as defined above and we acknowledge that screw intrusion into the disc space will result in a poor result in a majority of cases, then we will see that there is an upper limit to this angle. This angle will be defined by the dimensions of the vertebral body and by the technique used for pedicle screw trajectory. Anatomic placement of thoracic pedicle screws (rostral to caudal direction within the vertebral body) will maximize the distance of potentially tolerable vertebral body collapse. Straight ahead screws will allow for less collapse of the anterior column prior to screw intrusion. Screws angled from caudal to rostral may place the screw



**Figure.** Left: Well-aligned adult with a normal C2-tilt, equal to the odontoid-hip-axis (OD-HA) of approximately  $0^\circ$ . Middle: Adult with ankylosing spondylitis and subsequent thoracic hyperkyphosis leading to an increase in C2-tilt. Right: Adult with ankylosing spondylitis and subsequent lumbar hypolordosis, increase in pelvic tilt, and increase in the C2-pelvic angle.

tip immediately below the endplate, and this is likely the least tolerant screw trajectory. These propositions are supported by data showing reduced PJK rates with anatomic placement and data suggesting that an upward angulation (caudal to rostral) is associated with higher rates of PJK.<sup>13,14</sup> Kyphotic angles greater than  $30^\circ$  are associated with worse outcomes in post-traumatic deformity, and it is reasonable to think that a clinically “silent” PJK angle should be less than or equal to this value.<sup>15</sup> It is likely that tolerable PJK angles will vary with locations in the spine, much like the sagittal index as proposed by the sagittal index as a measure of burst fracture stability.<sup>16</sup> Hooks are an alternative to screws for fixation. Whether hooks reduce the risk of PJK is not clear; however, the use of hooks does remove the risk of fracture with screw intrusion to the adjacent segment disc



and offer the opportunity for greater kyphotic fracture with the possibility of “silence” and clinical irrelevance.<sup>17</sup>

## EFFORTS TO DEFINE CLINICAL RELEVANCE

As previously noted, the Glattes criteria comprised the first effort to define clinically relevant proximally junctional kyphosis.<sup>1</sup> They defined the proximal junction as the caudal endplate of the upper instrumented vertebra to the caudal endplate of the vertebra two above. Criteria for pathologic PJK were a proximal junctional angle of at least 10° and a change of at least 10° from the preoperative position. The C7-sagittal vertical axis (C7SVA) was measured to assess the effect of the junctional change on overall sagittal alignment. As we now know, the C7SVA is not a good measure of sagittal alignment because one can retrovert the pelvis and maintain the C7SVA despite sagittal plane imbalance.

Lovecchio et al sought to improve on expert opinion values to define PJK, noting that patient-reported outcome measures are a complex outcome and that revision for PJK is a clinically relevant and objective outcome measure.<sup>18</sup> This group used decision curve analyses to examine sensitivity, positive predictive value, and the F1 metric (harmonic mean of precision [positive predictive value] and sensitivity) to determine thresholds for proximal junctional angles that put patients at highest risk for PJF and subsequent surgery. They found that an absolute magnitude of proximal junctional angle of at least 28° and a change in the proximal junctional angle of at least 22° offered the best performance and were superior thresholds to those offered by Glattes et al. It is important to note, however, that the F1 score for these values was 34.1%, likely well below a useful clinical decision-making value (F1 scores range from 0 to 1, where 1 is a perfect prediction model). This result underscores the difficulty with choosing absolute values, thereby dichotomizing a continuous measure. It will result in misclassification too frequently to be of clinical utility.

## DEFINING NORMAL SEGMENTAL ALIGNMENT

A shortcoming of the Glattes criteria is that it overestimated the rate of PJK by neglecting change from compensatory hyperextension to normal segmental alignment. Thoracic extension is a well-known mechanism of compensation for the loss of lumbar lordosis. Restoration of normal lumbar alignment is associated with relaxation of thoracic compensation, and as a result, a 10° change in segmental alignment may normalize the spine and not be a pathologic change. Normalization

of the segment should not be termed PJK. Normal segmental alignments are needed to differentiate between pathologic kyphosis and normal segment alignment. There is substantial variation in both magnitude of sagittal curvatures and distribution of sagittal curvatures (which define the shape). Analyses from asymptomatic volunteers, without spinal degeneration, in the Multiethnic Alignment Normative Study showed that segmental alignment varies with pelvic incidence, and there is substantial interindividual variation in segmental alignment.<sup>12</sup> As such, we believe it is unlikely that useful segmental values at a patient- or pelvic incidence-specific level can be defined.

## CONCLUSION

Clinical care and academic pursuits both desire a definition for PJK related to decline in health-related quality of life or increased risk of reoperation or both, termed “clinically relevant” PJK. Most of the work in this area has used a variety of categories to define PJK, including PJF, to determine risk factors for adjacent failures. We must be careful as we compile these risk factors. PJK is a spectrum of adjacent segment failures, ranging from adjacent degeneration and stenosis to fracture with acute instability. Analysis of these different types of failures as categories, rather than one and the same, may lead to misclassification and conflicting results, leaving the clinician confused and the research led astray.

In summary, PJK is most reasonably defined as segmental kyphosis beyond that which is normal for the proximal, adjacent segments. PJK is represented by a spectrum of manifestations. The most benign is commonly referred to as “clinically irrelevant” followed by ASD. Kyphotic fractures and subluxations represent the more extreme spectrum of PJK with clear clinical implications. It is natural for us to hope that there is such a phenomenon as “clinically irrelevant” PJK, as it would absolve surgeons of the sin of harming a patient. It is difficult to assign clinical relevance at any single point in time, as sufficient follow-up may reveal that a junctional kyphosis leads to a negative outcome, as is the case for pseudarthrosis. It seems most reasonable to believe that PJK is an acceptable finding when it matches the kyphotic alignment of a normal adult, with a similar pelvic incidence. In the absence of clinical symptoms, it is likely acceptable to term the radiographic finding “asymptomatic PJK,” but the patient should be followed, and we should avoid the pursuit of defining “clinically relevant” PJK.

## REFERENCES

- Glattes RC, Bridwell KH, Lenke LG, Kim YJ, Rinella A, Edwards C. Proximal junctional kyphosis in adult spinal deformity following long instrumented posterior spinal fusion: incidence, outcomes, and risk factor analysis. *Spine (Phila Pa 1976)*. 2005;30(14):1643–1649. doi:10.1097/01.brs.0000169451.76359.49
- Yagi M, Akilah KB, Boachie-Adjei O. Incidence, risk factors and classification of proximal junctional kyphosis: surgical outcomes review of adult idiopathic scoliosis. *Spine (Phila Pa 1976)*. 2011;36(1):E60–E68. doi:10.1097/BRS.0b013e3181eeae2
- Hart R, McCarthy I, O'Brien M, et al. Identification of decision criteria for revision surgery among patients with proximal junctional failure after surgical treatment of spinal deformity. *Spine (Phila Pa 1976)*. 2013;38(19):E1223–E1227. doi:10.1097/BRS.0b013e31829fedde
- Boden SD, McCowin PR, Davis DO, Dina TS, Mark AS, Wiesel S. Abnormal magnetic-resonance scans of the cervical spine in asymptomatic subjects. A prospective investigation. *J Bone Joint Surg Am*. 1990;72(8):1178–1184.
- Richburg CE, Dossett LA, Hughes TM. Cognitive bias and dissonance in surgical practice: a narrative review. *Surg Clin North Am*. 2023;103(2):271–285. doi:10.1016/j.suc.2022.11.003
- Kim YJ, Bridwell KH, Lenke LG, Glattes CR, Rhim S, Cheh G. Proximal junctional kyphosis in adult spinal deformity after segmental posterior spinal instrumentation and fusion: minimum five-year follow-up. *Spine (Phila Pa 1976)*. 2008;33(20):2179–2184. doi:10.1097/BRS.0b013e31817c0428
- Fischgrund JS. The argument for instrumented decompressive posterolateral fusion for patients with degenerative spondylolisthesis and spinal stenosis. *Spine (Phila Pa 1976)*. 2004;29(2):173–174. doi:10.1097/01.BRS.0000111142.76601.1A
- Luo M, Wang P, Wang W, Shen M, Xu G, Xia L. Upper thoracic versus lower thoracic as site of upper instrumented vertebrae for long fusion surgery in adult spinal deformity: a meta-analysis of proximal junctional kyphosis. *World Neurosurg*. 2017;102:200–208. doi:10.1016/j.wneu.2017.02.126
- Cho W, Wang W, Bucklen B. The role of sagittal alignment in predicting major failure of lumbopelvic instrumentation: a biomechanical validation of lumbopelvic failure classification. *Spine Deform*. 2020;8(4):561–568. doi:10.1007/s43390-020-00052-1
- Yilgor C, Sogunmez N, Boissiere L, et al. Global alignment and proportion (GAP) score: development and validation of a new method of analyzing spinopelvic alignment to predict mechanical complications after adult spinal deformity surgery. *J Bone Joint Surg Am*. 2017;99(19):1661–1672. doi:10.2106/JBJS.16.01594
- Roussouly P, Gollogly S, Berthonnaud E, Dimnet J. Classification of the normal variation in the sagittal alignment of the human lumbar spine and pelvis in the standing position. *Spine (Phila Pa 1976)*. 2005;30(3):346–353. doi:10.1097/01.brs.0000152379.54463.65
- Hills J, Lenke LG, Sardar ZM, et al. The T4-L1-hip axis: defining a normal sagittal spinal alignment. *Spine (Phila Pa 1976)*. 2022;47(19):1399–1406. doi:10.1097/BRS.0000000000004414
- Harris AB, Kebaish FN, Puvanesarajah V, et al. Caudally directed upper-Instrumented vertebra pedicle screws associated with minimized risk of proximal junctional failure in patients with long posterior spinal fusion for adult spinal deformity. *Spine J*. 2021;21(7):1072–1079. doi:10.1016/j.spinee.2021.03.009
- Chen JW, Longo M, Chanbour H, et al. Cranially directed upper instrumented vertebrae screw angles are associated with proximal junctional kyphosis in adult spinal deformity surgery. *Spine (Phila Pa 1976)*. 2023;48(10):710–719. doi:10.1097/BRS.0000000000004573
- Gertzbein SD. Scoliosis research society. multicenter spine fracture study. *Spine (Phila Pa 1976)*. 1992;17(5):528–540. doi:10.1097/00007632-199205000-00010
- Farcy JP, Weidenbaum M, Glassman SD. Sagittal index in management of thoracolumbar burst fractures. *Spine (Phila Pa 1976)*. 1990;15(9):958–965. doi:10.1097/00007632-199009000-00022
- Hassanzadeh H, Gupta S, Jain A, El Dafrawy MH, Skolasky RL, Kebaish KM. Type of anchor at the proximal fusion level has a significant effect on the incidence of proximal junctional kyphosis and outcome in adults after long posterior spinal fusion. *Spine Deform*. 2013;1(4):299–305. doi:10.1016/j.jspd.2013.05.008
- Lovecchio F, Lafage R, Line B, et al. Optimizing the definition of proximal junctional kyphosis: a sensitivity analysis. *Spine (Phila Pa 1976)*. 2023;48(6):414–420. doi:10.1097/BRS.0000000000004564

**Funding:** Dr. Kelly discloses that he has received honoraria from Wolters Kluwer and has received travel support from AO Spine and Broadwater. Dr. Hills has no disclosures.

**Declaration of Conflicting Interests:** The authors report no conflicts of interest in this work.

**Corresponding Author:** Michael P. Kelly, Rady Children's Hospital, University of California, 3020 Children's Way, MC 5062, San Diego, CA 92123, USA; Mkelly5@rchsd.org

This manuscript is generously published free of charge by ISASS, the International Society for the Advancement of Spine Surgery. Copyright © 2023 ISASS. To see more or order reprints or permissions, see <http://ijssurgery.com>.