

When Would Minimally Invasive Spinal Surgery Not Be Preferable for Metastatic Spine Disease?

Si Jian Hui, Jiong Hao Tan, Sahil Athia, Priyambada Kumar, Renick Lee, Shahid Ali, Seok Woo Kim and Naresh Kumar

Int J Spine Surg published online 15 November 2024
<https://www.ijssurgery.com/content/early/2024/11/15/8658>

This information is current as of December 9, 2024.

Email Alerts Receive free email-alerts when new articles cite this article. Sign up at:
<http://ijssurgery.com/alerts>

When Would Minimally Invasive Spinal Surgery Not Be Preferable for Metastatic Spine Disease?

SI JIAN HUI, MBBS, MRCS (EDIN)¹; JIONG HAO TAN, MBBS, MRCS (EDIN), MMed (ORTH), FRCS (ORTH)¹; SAHIL ATHIA²; PRIYAMBADA KUMAR, MBBS, MS (Orth), FISS¹; RENICK LEE, BEng¹; SHAHID ALI, MBBS, FCPS (ORTHO)³; SEOK WOO KIM, MD⁴; AND NARESH KUMAR, MBBS (AIIMS); MS ORTH.(AIIMS); DNB ORTH.FRCS Ed.FRCS (ORTH & Trauma); DM (ORTH Spinal Surgery)^{1,5}

¹Department of Orthopedic Surgery, University Spine Center, National University Health System, Singapore, Singapore; ²Royal College of Surgeons in Ireland, Dublin, Ireland; ³King Edward Medical University, Lahore Pakistan, Chowk, Pakistan; ⁴Spine Center, Hallym University Sacred Heart Hospital, Anyang-si, South Korea; ⁵AO Technical Commission Spine Expert Group, Clavadelerstrasse, Switzerland

ABSTRACT

Background: Metastatic spine tumor surgery (MSTS) is an important treatment modality of metastatic spinal disease (MSD). Open spine surgery (OSS) was previously the gold standard of treatment till the early 2010s. However, advancements in MSTS in recent years have led to the advent of minimally invasive spinal surgery (MISS) techniques for the treatment of MSD. The clear benefits of MISS have resulted in a current paradigm shift toward today's gold standard of MISS and early adjuvant radiotherapy in treating MSD patients. Nonetheless, despite improvements in surgical techniques and the rise of literature supporting MISS for MSD, there are still certain situations whereby MISS is not desirable or even suitable. There has also yet to be any literature describing the considerations of not using MISS in MSD in today's clinical context.

Methods: A narrative review was conducted for this manuscript. All studies related to OSS and MISS in MSTS were included.

Results: A total of 54 studies were included in this review. These studies discussed various advantages of MISS for MSD in today's clinical context, including the patient profile, location of vertebrae involved with metastasis requiring treatment, tumor characteristics, as well as equipment availability.

Conclusion: This study establishes situations in which MISS can be less applicable despite the advantages it may confer over traditional OSS. MSTS should be individualized, depending on the experience of the surgeon. OSS is a time-tested approach that still holds weight in MSTS and should be readily utilized depending on the clinical situation.

Level of Evidence: 4.

Minimally Invasive Surgery

Keywords: metastasis, spine, tumor, open surgery, minimally invasive surgery

INTRODUCTION

Surgery has been an established modality of treatment for metastatic spinal disease (MSD), with open spine surgery (OSS) the gold standard till around the early 2010s.¹ The indications for surgery are cord compression, spinal instability, pathological fractures, and intractable pain.^{1,2} These have been constant since the early 1980s when treatment of metastatic spine disease evolved and established surgery as a dependable treatment option.^{1,3,4} However, OSS is usually associated with extensive soft tissue dissection, which leads to excessive blood loss, increased hospital length of stay, and complication rates.^{5–8}

In recent years, advancements in metastatic spine tumor surgery (MSTS) have led to the advent of minimally invasive spinal surgery (MISS) techniques for the treatment of MSD. MISS has shown benefits in

reducing mortality, morbidity, and hospital length of stay, as well as allowing earlier introduction of adjuvant radiotherapy (RT) and chemotherapy.^{6,9,10} The clear benefits of MISS have resulted in a current paradigm shift toward today's "gold standard" of MISS followed by early adjuvant RT in treating MSD patients.¹ Nonetheless, even with the advantages of MISS as described above, the functional and neurological outcomes of patients undergoing MISS as compared with OSS have been showed in several studies to be similar.^{11–14} Hence, it still remains to be seen if the advantages accorded by MISS do translate to clinical improvements in MSD patients in the long run.

The aim of MISS in MSD is to achieve the same surgical goals of decompression of neural structures for improvement of neurological function, stabilization of the spine, and allowing for postoperative safe adjuvant RT and local tumor control with the minimization of

surgical approach related morbidity.¹⁵ This effectively translates to less blood loss, operative time, and post-operative morbidity.^{12,16,17} MISS includes the use of percutaneous pedicle screw fixation as well as mini-open techniques to perform tumor decompression and corpectomy to achieve the outcomes mentioned above. The recently described separation surgery also allows the creation of separation between tumor tissue and the neural structures to allow safe adjuvant RT and local tumor control.¹⁸ Patients who undergo MISS have a shorter length of hospital stay than those of OSS, likely due to the lower invasiveness of surgery.^{19,20} Hence, they are able to ambulate faster and be discharged earlier. MISS also negates the risk of potential dead space or tissue necrosis formation due to extensive dissection in OSS,^{21,22} allowing for faster wound healing times due to smaller incisions. This enables earlier initiation of adjuvant therapy for these patients,^{10,11} overall improving the management of MSD for them.

Despite the improvements in surgical techniques and the rise of literature supporting MISS for MSD,^{6,11,15} there are still certain situations whereby MISS is not desirable or even suitable. There has also yet to be any literature describing the considerations for not using MISS in MSD in today's clinical context. In this manuscript, we aim to review the literature and highlight personal experiences from our senior authors, regarding the various situations whereby MISS may not be suitable in MSD.

METHODS

This narrative review was conducted using PubMed, Medical Literature Analysis and Retrieval System Online (MEDLINE), The Cochrane Library, and Scopus databases through 31 July 2024. The keywords used were (minimally invasive surgery OR MIS OR MISS OR mini-open spine surgery OR open spine surgery) AND (spine OR vertebra OR vertebrae OR spinal) AND (metastasis OR bone neoplasm OR bone tumor OR spine neoplasm OR spine tumor OR metastatic epidural spinal cord compression).

The inclusion criteria for the review were studies with a discussion on the type of surgery in MSTs. All studies that had no description regarding the surgical procedure performed were excluded. The articles were selected in 2 stages (Figure 1). First, the abstracts identified by the above searches were downloaded, and the list was screened using the relevant inclusion and exclusion criterias (non-human studies, no full text, not in English and duplicates). Next, the full texts of this short-listed list were downloaded and assessed for eligibility.

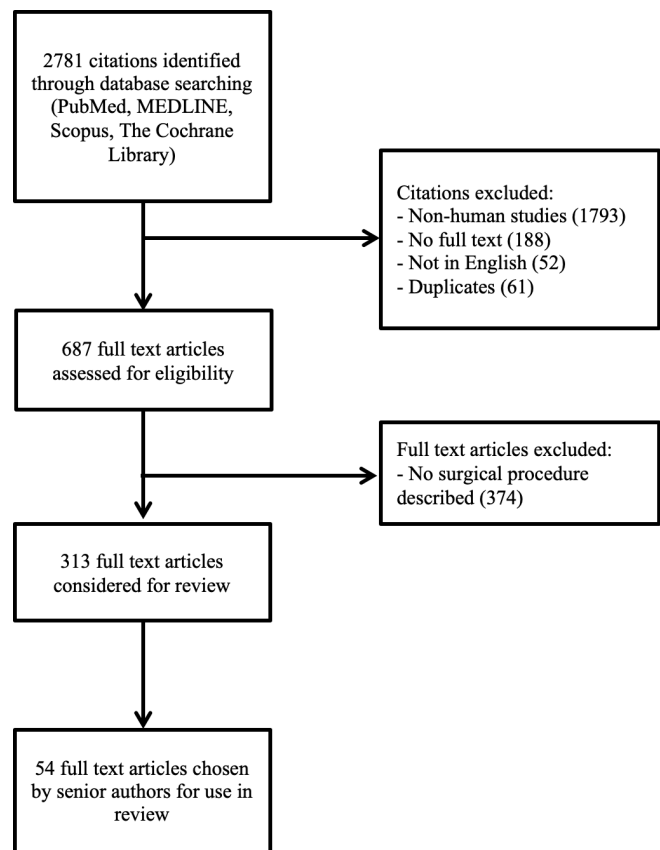


Figure 1. Flow diagram of the review and selection of cases.

All articles that did not have any surgical procedure described were excluded at this stage. The reference lists of the publications were then hand-searched for additional relevant studies. This process was repeated twice by our senior authors independently.

RESULTS

MISS for MSD has recently gained traction and demonstrated its ability in various studies to treat MSD patients of varying severity. Kumar et al¹⁸ demonstrated the utility of MISS techniques in treating patients with spinal instability secondary to spinal metastases and metastatic spinal cord compression, with significantly decreased blood loss and length of stay. In a meta-analysis by Pranata et al²³ which compared MISS with instrumented fusion with conventional OSS instrumented fusion for the treatment of MSD, MISS was associated with decreased blood loss and lower blood transfusion rates, as well as lower rate of complications and duration of stay. There were also comparable rates of neurological improvement and duration of surgery. Similar findings of decreased blood loss, transfusion rates, complication rates, and duration of hospital stay have also been found in meta-analyses done by Lu et

al, Perna et al, and Pennington et al.^{16,24,25} Despite this, OSS has also shown potential benefits to be kept in the MSTs armamentarium. Colangeli et al²⁶ showed in their retrospective review that OSS was more a more suitable treatment choice when tumor debulking was central to the local control plan. Studies have also shown that patients with substantial posterior involvement of spinal elements, such as the facet joints, are unlikely to get pain relief from minimally invasive procedures alone.^{27,28} Thus, it is important to consider the various situations in which MISS is less suitable. In situations where MISS is unable to access the area of the lesion, OSS is an important fallback to allow access and stabilization.

SITUATIONS WHERE MISS MAY NOT BE AS SUITABLE

Tumor Characteristics

The type of tumor is an important decision-making factor for MSTs surgeons. In patients with hypersclerotic lesions such as those with prostate and certain breast metastases,²⁹ the vertebrae can be very difficult to cannulate with MIS probes. The introduction of the guide wire into the vertebrae body can also be difficult in patients with hypersclerotic tumors, and bending or breaking of the wire has been reported when the wire is inserted.³⁰ As such, they are best operated by open technique to allow for adequate dissection and location of entry point for pedicle screw insertion. In our experience, intraoperative image intensifier-guided delineation of vertebrae landmarks is also not easy in hypersclerotic tumors.

MISS is also less feasible in patients with hypervascular tumors, such as renal cell, thyroid, and hepatocellular carcinoma,³¹ due to reduced ability to control intraoperative bleeding. An open technique will confer easier control of bleeding intraoperatively. In the same vein, hypervascular tumors where preoperative embolization has failed will logically require open techniques to allow for adequate intraoperative control of bleeding.

Extent of Surgery

In order to decide whether to elect MISS or OSS, the extent of planned surgery must also be taken into account. Indications for undertaking MSTs are disease-related cord compression, spinal instability, pathological fractures, and intractable pain.^{1,2,32} In certain scenarios, surgical resection of the tumor or decompression of the spine can involve total en-bloc corpectomy (Figure 2). This is usually considered in isolated metastatic lesions of slow-growing malignancy (ie, oligometastatic breast cancer), patients

with an expected survival of more than 2 years, and an acceptable functional status of the patient due to the high surgical morbidity.^{10,33} Barzilay et al also noted the relative indication for en-bloc resection of spinal metastasis where stereotactic RT may not be available.³⁴ In the cases above where reconstruction of the anterior column is required³³ after undertaking extensive decompression surgery, it can be technically challenging to achieve the reconstruction and fusion with an MIS technique. Likewise in young patients where extensive decompression has been done (eg, corpectomy and hemivertebrectomy) and reconstruction of the spine is required, it will be easier to perform fusion through an open technique. This allows for direct visualization of the fusion bed and control of any potential bleeding, as these patients undergoing corpectomy are also known to have increased intraoperative bleeding and total transfusion requirement.³⁵

In cases where there is significant posterior column involvement with the tumor and decompression of that level is required, MISS may not be as suitable (Figure 3). Tan et al³⁶ showed in their study that posterior facet visualization is more challenging with MISS as compared with OSS. The ability of OSS to provide visualization during decompression is important and also allows instrumentation if required. This is an important consideration in MSTs where stabilization of the spine in the most efficient manner is important.

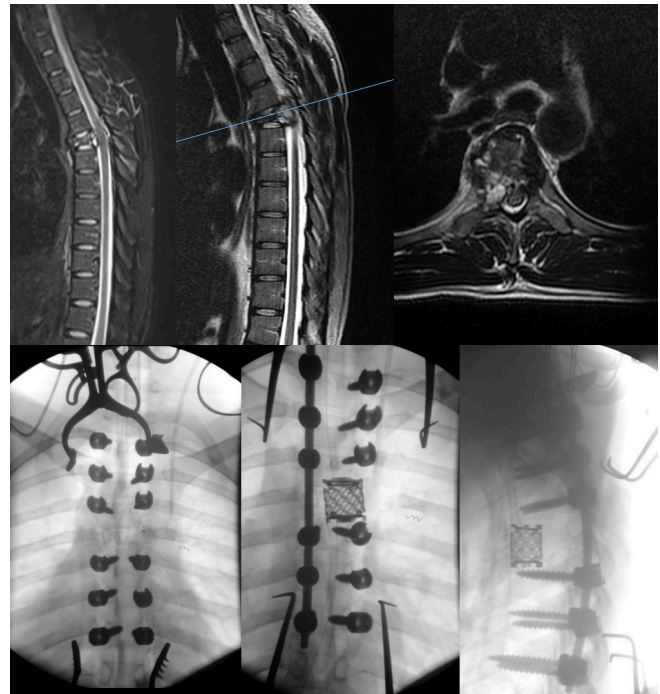


Figure 2. Example of patient with oligometastasis undergoing metastectomy and requiring open spine surgery.

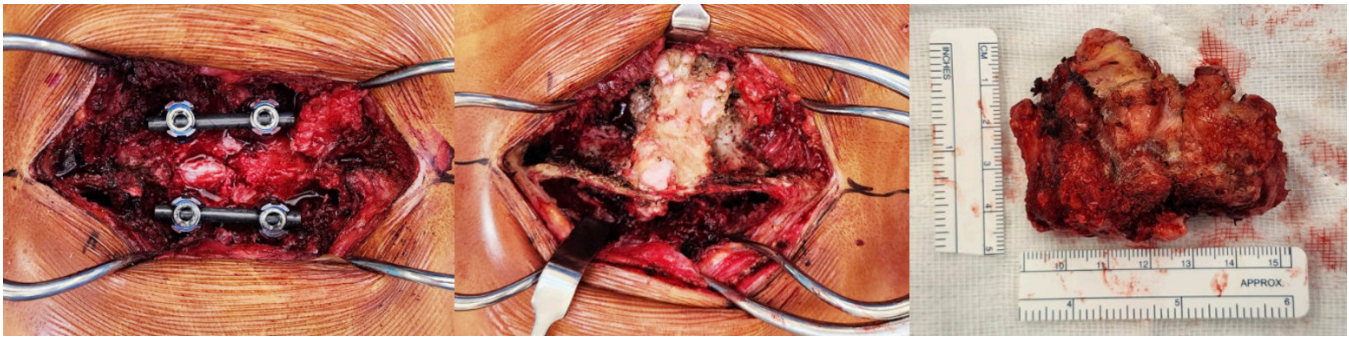


Figure 3. Example of open spine surgery having good access to posterior elements allowing thorough decompression and metastectomy.

Previous Operation at the Level of Surgery

In cases where previous surgery at the affected level has been done, there may be extensive scarring, and landmarks may not be easily identified, making MISS a more daunting undertaking. This is an important consideration in cases of MSD where patients may have various comorbidities;^{29,30} hence, surgical duration should be kept to the minimum to avoid potential complications from prolonged surgery or anesthesia. The development of computer-guided navigation techniques in recent years has also allowed for more accurate localization of levels and screw positioning.^{31,32} Morgan et al showed in their single-center randomized controlled trial that MISS was associated with a significantly longer operating time compared with OSS.³⁷ It is notable that navigation techniques can potentially be more technically demanding and thus result in increased operating times or not be available beyond tertiary centers. In our experience, if navigation systems are not available or prior surgery at the affected level has been done, OSS should be considered for MSD patients.

Location of Tumor

The most common location for spinal metastasis in the vertebrae is in the thoracic spine (60%–80%), followed by the lumbar spine (15%–30%), and lastly the cervical spine (<10%).^{38,39} MISS is currently well developed for the thoracic, thoracolumbar, and lumbar spine due to the ease of imaging in these areas with a gentler change in the sagittal profile of patients. In cases where the site of metastasis is in the occipitocervical or cervicothoracic region, MISS may not be as suitable since intraoperative localization of levels with imaging intensifier may be difficult.³⁸ In these cases, intraoperative navigation with the O-arm or robot-assisted pedicle screw placement has been described,^{32,40,41} but this specialized equipment involves significant costs^{42,43} and training that may not be available in less specialized centers.⁴⁴ In our opinion, for locations such as the

occipitocervical and cervicothoracic regions, MISS may be less suitable due to inherent challenges with imaging these regions.

Profile of MSD Patients

The profile of MSD patients also plays an important role in deciding whether MISS is a feasible treatment plan for MSD. In the pediatric group, MISS instruments have not been well developed for use in this group of patients. Recent use of MISS in the pediatric population has been limited to small case series for scoliosis and discectomy.^{36,45,46} Likewise, small-statured patients similar to the pediatric population would require open technique as the landmarks of 2 continuous vertebrae will be very close to each other, which limits the use of multiple small incisions for pedicle screw insertion.

Miscellaneous

MISS is commonly augmented with specialized equipment intraoperatively such as navigation and robotic systems to increase the accuracy of instrumentation.^{47–50} Hence, a trained team adept in using such equipment is needed, which leads to a further increase in overhead. More often than not, MISS is incorporated with early stereotactic RT postoperatively, which results in the requirement for such facilities to be present to maximize the advantages of MISS.³⁴ The relative novelty of MISS technique also poses a high barrier of entry toward incorporating MISS in one's practice. This can be significant especially for less developed countries or for young surgeons who are just starting out in their own clinical practice.

THE ROLE OF MISS IN MSTs TODAY

Notwithstanding the previously discussed points, MISS techniques should still be considered for the appropriate MSTs patient. Clinical studies of MISS done in thoracolumbar MSTs have shown benefits

Table. Considerations in which MISS/OSS may be more feasible for MSD patients.

Considerations When Undertaking MISS	OSS More Feasible	MISS More Feasible
Tumor characteristics	<ul style="list-style-type: none"> • Hypersclerotic • Hypervascular 	<ul style="list-style-type: none"> • Normal bone quality (based on CT findings) • Good hemostasis achieved through preoperative blood management (ie, angioembolization)
Extent of surgery	<ul style="list-style-type: none"> • Metastectomy planned • Reconstruction procedures required 	<ul style="list-style-type: none"> • Standard posterior instrumentation and separation surgery • No major reconstruction planned
Location of tumor	<ul style="list-style-type: none"> • Significant involvement of posterior column • Occipitocervical • Cervicothoracic • Lumbosacral and sacral 	<ul style="list-style-type: none"> • Thoracolumbar
Profile of MSD patients	<ul style="list-style-type: none"> • Previous surgery at level of operation • Pediatric and young patients • Short stature 	<ul style="list-style-type: none"> • Adult patients • Normal body habitus
Miscellaneous	<ul style="list-style-type: none"> • Lack of availability of specialized equipment/team • Lack of postoperative RT 	<ul style="list-style-type: none"> • Availability of specialized equipment and team

Abbreviations: CT, computed tomography; MISS, minimally invasive spinal surgery; MSD, metastatic spinal disease; OSS, open spine surgery; RT, radiotherapy.

in reducing blood loss and overall hospital length of stay.^{14,18} MISS has also shown benefits to be utilized as part of “separation surgery,”^{15,18} where the surgical goal is not for metastectomy but rather to achieve circumferential tumor debulking and decompression and facilitate improved adjuvant RT postoperatively.

The development of Enhanced Recovery After Surgery pathways⁵¹ around the world, coupled with the increase in patient blood management strategies,^{52,53} has also reduced the invasiveness in MSTs and positively impacted the outcomes of patients undergoing MSTs. With the trend toward MISS, together with robotic and navigation technology in recent years, it is ever so important to understand when MISS or OSS should be utilized, depending on the surgical goal (Table).

LIMITATIONS

To our knowledge, this study is the first to highlight the utility of OSS in today’s clinical practice, but it also faces some limitations. First, this study is conducted as a narrative review, and there is currently a lack of established guidelines and opinion on this topic. The varying types of MSD in patients also result in heterogeneity in the review, and the multitude of different surgical techniques in MSTs precludes the conduct of a direct comparative study between the 2 surgical approaches. Our team recognizes the clinical benefit of MISS over OSS shown in literature, but as discussed above, either technique should not be a universal fit for all MSTs patients. The rapid advancement of MISS has also seen the introduction of robotic and navigation techniques to further enhance the potential of MISS. These are viewed as adjuncts for improving the execution of MISS and are not explicitly discussed in our manuscript.

Our manuscript thus provides clarity into the direct utility of OSS vs MISS in MSTs and allows MSTs surgeons to have more deliberate surgical planning considering the factors listed above to benefit patients undergoing MSTs. With the publication of this manuscript, higher-powered comparative studies can be performed between the 2 approaches to further highlight the benefits of either approach in clinical practice.

CONCLUSION

MISS is becoming increasingly prevalent in the treatment of MSD, and surgical techniques are constantly evolving to benefit patients. However, it is important to understand the limitations of MISS in various clinical context as highlighted in this manuscript. MSTs should be individualized to the patient, depending also on the experience of the surgeon. OSS is still a time-tested approach that holds weight in MSTs and should be readily utilized depending on the clinical situation. This highlights the importance of keeping OSS in the armamentarium despite the trend toward MISS in recent years.

ACKNOWLEDGMENTS

1. We acknowledge the AO Technological Commission Spine Expert Group for the discussions of Metastatic Spine Tumour Surgery management which have led to the formulation and submission of this manuscript.
2. We also acknowledge Dr Aye Sander Zaw for her help in proofreading the manuscript and submission of the manuscript for publication.

REFERENCES

1. Kumar N, Malhotra R, Zaw AS, et al. Evolution in treatment strategy for metastatic spine disease: presently evolving modalities. *Eur J Surg Oncol.* 2017;43(9):1784–1801. doi:10.1016/j.ejso.2017.05.006
2. Bartels R, van der Linden YM, van der Graaf WTA. Spinal extradural metastasis: review of current treatment options. *CA Cancer J Clin.* 2008;58(4):245–259. doi:10.3322/CA.2007.0016
3. Harel R, Angelov L. Spine metastases: current treatments and future directions. *Eur J Cancer.* 2010;46(15):2696–2707. doi:10.1016/j.ejca.2010.04.025
4. Cole JS, Patchell RA. Metastatic epidural spinal cord compression. *Lancet Neurol.* 2008;7(5):459–466. doi:10.1016/S1474-4422(08)70089-9
5. McClelland S, Goldstein JA. Minimally invasive versus open spine surgery: what does the best evidence tell us? *J Neurosci Rural Pract.* 2017;8(2):194–198. doi:10.4103/jnpr.jnpr_472_16
6. Kumar N, Zaw AS, Khine HE, et al. Blood loss and transfusion requirements in metastatic spinal tumor surgery: evaluation of influencing factors. *Ann Surg Oncol.* 2016;23(6):2079–2086. doi:10.1245/s10434-016-5092-8
7. Chen Y, Tai BC, Nayak D, et al. Blood loss in spinal tumour surgery and surgery for metastatic spinal disease: a meta-analysis. *Bone Joint J.* 2013;95-B(5):683–688. doi:10.1302/0301-620X.95B5.31270
8. Overley SC, Cho SK, Mehta AI, Arnold PM. Navigation and robotics in spinal surgery: where are we now? *Neurosurgery.* 2017;80(3S):S86–S99. doi:10.1093/neuros/nyw077
9. Flynn SC, Eli IM, Ghogawala Z, Yew AY. Minimally invasive surgery for spinal metastasis: a review. *World Neurosurg.* 2022;159:e32–e39. doi:10.1016/j.wneu.2021.11.097
10. Hong SH, Chang B-S, Kim H, Kang D-H, Chang SY. An updated review on the treatment strategy for spinal metastasis from the spine surgeon's perspective. *Asian Spine J.* 2022;16(5):799–811. doi:10.31616/asj.2022.0367
11. Kumar N, Malhotra R, Maharajan K, et al. Metastatic spine tumor surgery: a comparative study of minimally invasive approach using percutaneous pedicle screws fixation versus open approach. *Clin Spine Surg.* 2017;30(8):E1015–E1021. doi:10.1097/BSD.0000000000000400
12. Hansen-Algenstaedt N, Kwan MK, Algenstaedt P, et al. Comparison between minimally invasive surgery and conventional open surgery for patients with spinal metastasis. *Spine.* 2017;42(10):789–797. doi:10.1097/BRS.0000000000001893
13. Yang Z, Yang Y, Zhang Y, et al. Minimal access versus open spine surgery in treating painful spine metastasis: a systematic review. *World J Surg Oncol.* 2015;13(1). doi:10.1186/s12957-015-0468-y
14. Hinojosa-Gonzalez DE, Roblesgil-Medrano A, Villarreal-Espinosa JB, et al. Minimally invasive versus open surgery for spinal metastasis: a systematic review and meta-analysis. *Asian Spine J.* 2022;16(4):583–597. doi:10.31616/asj.2020.0637
15. Barzilai O, Bilsky MH, Laufer I. The role of minimal access surgery in the treatment of spinal metastatic tumors. *Glob Spine J.* 2020;10(2 Suppl):79S–87S. doi:10.1177/2192568219895265
16. Pennington Z, Ahmed AK, Molina CA, Ehresman J, Laufer I, Sciubba DM. Minimally invasive versus conventional spine surgery for vertebral metastases: a systematic review of the evidence. *Ann Transl Med.* 2018;6(6). doi:10.21037/atm.2018.01.28
17. Miscusi M, Polli FM, Forcato S, et al. Comparison of minimally invasive surgery with standard open surgery for vertebral thoracic metastases causing acute myelopathy in patients with short- or mid-term life expectancy: surgical technique and early clinical results. *J Neurosurg Spine.* 2015;22(5):518–525. doi:10.3171/2014.10.SPINE131201
18. Kumar N, Tan JH, Thomas AC, et al. The utility of “minimal access and separation surgery” in the management of metastatic spine disease. *Glob Spine J.* 2023;13(7):1793–1802. doi:10.1177/21925682211049803
19. Kumar N, Ramos MRD, Patel R, et al. The “spinal metastasis invasiveness index”: a novel scoring system to assess surgical invasiveness. *Spine.* 2021;46(7):478–485. doi:10.1097/BRS.0000000000003823
20. Mirza SK, Deyo RA, Heagerty PJ, et al. Development of an index to characterize the “invasiveness” of spine surgery: validation by comparison to blood loss and operative time. *Spine.* 2008;33(24):2651–2661. doi:10.1097/BRS.0b013e31818dad07
21. Fessler RG, O'Toole JE, Eichholz KM, Perez-Cruet MJ. The development of minimally invasive spine surgery. *Neurosurg Clin N Am.* 2006;17(4):401–409. doi:10.1016/j.nec.2006.06.007
22. Kulkarni AG, Patel RS, Dutta S. Does minimally invasive spine surgery minimize surgical site infections? *Asian Spine J.* 2016;10(6):1000–1006. doi:10.4184/asj.2016.10.6.1000
23. Pranata R, Lim MA, Vania R, Bagus Mahadewa TG. Minimal invasive surgery instrumented fusion versus conventional open surgical instrumented fusion for the treatment of spinal metastases: a systematic review and meta-analysis. *World Neurosurg.* 2021;148:e264–e274. doi:10.1016/j.wneu.2020.12.130
24. Lu VM, Alvi MA, Goyal A, Kerezoudis P, Bydon M. The potential of minimally invasive surgery to treat metastatic spinal disease versus open surgery: a systematic review and meta-analysis. *World Neurosurg.* 2018;112:e859–e868. doi:10.1016/j.wneu.2018.01.176
25. Perna A, Smakaj A, Vitiello R, et al. Posterior percutaneous pedicle screws fixation versus open surgical instrumented fusion for thoraco-lumbar spinal metastases palliative management: a systematic review and meta-analysis. *Front Oncol.* 2022;12. doi:10.3389/fonc.2022.884928
26. Colangeli S, Capanna R, Bandiera S, et al. Is minimally-invasive spinal surgery a reliable treatment option in symptomatic spinal metastasis? *Eur Rev Med Pharmacol Sci.* 2020;24(12):6526–6532. doi:10.26355/eurrev_202006_21636
27. Rajah G, Altshuler D, Sadiq O, Nyame VK, Eltahawy H, Szerlip N. Predictors of delayed failure of structural kyphoplasty for pathological compression fractures in cancer patients. *J Neurosurg Spine.* 2015;23(2):228–232. doi:10.3171/2014.11.SPINE14909
28. Moussazadeh N, Rubin DG, McLaughlin L, Lis E, Bilsky MH, Laufer I. Short-segment percutaneous pedicle screw fixation with cement augmentation for tumor-induced spinal instability. *Spine J.* 2015;15(7):1609–1617. doi:10.1016/j.spinee.2015.03.037
29. Macedo F, Ladeira K, Pinho F, et al. Bone metastases: an overview. *Oncol Rev.* 2017;11(1). doi:10.4081/oncol.2017.321
30. Landriel F, Guiroy A, Ciancio AM, et al. 20 tips to avoid and handle problems in the placement of percutaneous pedicle screws. *World Neurosurg.* 2021;149:15–25. doi:10.1016/j.wneu.2021.01.149
31. Pazonis TJC, Papanastassiou ID, Maybody M, Healey JH. Embolization of hypervascular bone metastases reduces intra-operative blood loss: a case-control study. *Clin Orthop Relat Res.* 2014;472(10):3179–3187. doi:10.1007/s11999-014-3734-3

32. Kwan MK, Lee CK, Chan CYW. Minimally invasive spinal stabilization using fluoroscopic-guided percutaneous screws as a form of palliative surgery in patients with spinal metastasis. *Asian Spine J.* 2016;10(1):99–110. doi:10.4184/asj.2016.10.1.99
33. Kato S, Demura S, Shinmura K, et al. Surgical metastasectomy in the spine: a review article. *Oncol.* 2021;26(10):e1833–e1843. doi:10.1002/onco.13840
34. Barzilai O, Boriani S, Fisher CG, et al. Essential concepts for the management of metastatic spine disease: what the surgeon should know and practice. *Glob Spine J.* 2019;9(1 Suppl):98S–107S. doi:10.1177/2192568219830323
35. Yoo S-L, Kim Y-H, Park H-Y, et al. Clinical significance of preoperative embolization for non-hypervascular metastatic spine tumors. *J Korean Neurosurg Soc.* 2019;62(1):106–113. doi:10.3340/jkns.2018.0073
36. Tan JH, Wong H-K. Minimally invasive options in adolescent idiopathic scoliosis. *Ind Spine J.* 2020;3(2). doi:10.4103/isj.isj_63_19
37. Morgen SS, Hansen LV, Karbo T, Svardal-stelmer R, Gehrchen M, Dahl B. Minimal access vs. open spine surgery in patients with metastatic spinal cord compression - a one-center randomized controlled trial. *Anticancer Res.* 2020;40(10):5673–5678. doi:10.21873/anticancer.114581
38. Beaufort Q, Terrier L-M, Dubory A, et al. Spine metastasis in elderly. *Spine.* 2021;46(11):751–759. doi:10.1097/BRS.0000000000003881
39. Kanda Y, Kakutani K, Sakai Y, et al. Prospective cohort study of surgical outcome for spinal metastases in patients aged 70 years or older. *Bone Joint J.* 2020;102-B(12):1709–1716. doi:10.1302/0301-620X.102B12.BJJ-2020-0566.R1
40. Tjardes T, Shafizadeh S, Rixen D, et al. Image-guided spine surgery: state of the art and future directions. *Eur Spine J.* 2010;19(1):25–45. doi:10.1007/s00586-009-1091-9
41. Tian NF, Xu HZ. Image-guided pedicle screw insertion accuracy: a meta-analysis. *Int Orthop.* 2009;33(4):895–903. doi:10.1007/s00264-009-0792-3
42. Mossa-Basha M, Gerszten PC, Myrehaug S, et al. Spinal metastasis: diagnosis, management and follow-up. *Br J Radiol.* 2019;92(1103). doi:10.1259/bjr.20190211
43. Ziu E, Mesfin FB. *cancer, spinal metastasis.* In: *StatPearls.* Treasure Island: StatPearls Publishing; 2019.
44. Judy BF, Pennington Z, Botros D, et al. Spine image guidance and robotics: exposure, education, training, and the learning curve. *Int J Spine Surg.* 2021;15(s2):S28–S37. doi:10.14444/8138
45. Menger R, Hefner MI, Savardekar AR, Nanda A, Sin A. Minimally invasive spine surgery in the pediatric and adolescent population: a case series. *Surg Neurol Int.* 2018;9. doi:10.4103/sni.sni_417_17
46. Ahmad AA. Minimal invasive surgery techniques for patients with adolescent idiopathic and early onset scoliosis. *J Clin Orthop Trauma.* 2021;11(5):830–838. doi:10.1016/j.jcot.2020.07.011
47. Hussain I, Schmidt FA, Kirnaz S, Wipplinger C, Schwartz TH, Härtl R. MIS approaches in the cervical spine. *J Spine Surg.* 2019;5(Suppl 1):S74–S83. doi:10.21037/jss.2019.04.21
48. Malham GM, Wells-Quinn T. What should my hospital buy next?—guidelines for the acquisition and application of imaging, navigation, and robotics for spine surgery. *J Spine Surg.* 2019;5(1):155–165. doi:10.21037/jss.2019.02.04
49. Menger RP, Savardekar AR, Farokhi F, Sin A. A cost-effectiveness analysis of the integration of robotic spine technology in spine surgery. *Neurospine.* 2018;15(3):216–224. doi:10.14245/ns.1836082.041
50. Virk S, Qureshi S. Navigation in minimally invasive spine surgery. *J Spine Surg.* 2019;5(Suppl 1):S25–S30. doi:10.21037/jss.2019.04.23
51. Chakravarthy VB, Laufer I, Amin AG, et al. Patient outcomes following implementation of an enhanced recovery after surgery pathway for patients with metastatic spine tumors. *Cancer.* 2022;128(23):4109–4118. doi:10.1002/cncr.34484
52. Motov S, Stengel F, Ringel F, Bozinov O, Stienen MN. Current state of preoperative embolization for spinal metastasis - a survey by the EANS spine section. *Br Sp.* 2023;3. doi:10.1016/j.bas.2023.102712
53. Jonathan L, Tan JH, Ashokka B. Does patient blood management affect outcomes in metastatic spine tumour surgery? A review of current concepts. *Glob Spine J.* Epub March 7, 2024. doi:10.1177/21925682231167096

Funding: The authors received no financial support for the research, authorship, and/or publication of this article.

Declaration of Conflicting Interests: The authors report no conflicts of interest in this work.

Corresponding Author: Naresh Kumar, Department of Orthopaedic Surgery, University Spine Centre, National University Health System, Level 11, 1E, Lower Kent Ridge Road, 119228, Singapore; dosksn@nus.edu.sg

This manuscript is generously published free of charge by ISASS, the International Society for the Advancement of Spine Surgery. Copyright © 2024 ISASS. To see more or order reprints or permissions, see <http://ijssurgery.com>.