

Master Techniques in Minimally Invasive Spine Surgery: Lumbar Endoscopic Spine Surgery

Choll W. Kim

Int J Spine Surg published online 11 February 2025
<https://www.ijssurgery.com/content/early/2025/02/10/8715>


This information is current as of May 10, 2025.

Email Alerts Receive free email-alerts when new articles cite this article. Sign up at:
<http://ijssurgery.com/alerts>

Master Techniques in Minimally Invasive Spine Surgery: Lumbar Endoscopic Spine Surgery

CHOLL W. KIM, MD, PhD¹

¹*Excel Spine Center, University of California Medical Center, East Campus, San Diego, CA, USA*

 CWK, 0000-0002-6543-3312

ABSTRACT

The difficult learning curve remains the major obstacle to adoption of lumbar endoscopic spine surgery (LESS) techniques. Detailed, step-by-step techniques are described for the uniportal transforaminal technique, as well as uniportal and biportal interlaminar approaches. Special emphasis is placed on specific areas of the learning curve that pose obvious challenges to the completion of successful surgery. Logistical challenges of the first case are addressed with electronic checklists with interactive photographs of key instruments and equipment for easy identification by staff, interactive animations of the room set-up, and interactive animations of the surgical anatomy. This technique guide is part of a comprehensive training program with the goal to “make the first case go well.”

Minimally Invasive Surgery

Keywords: endoscopy, Intervertebral disc, Stenosis, Learning curve, Adoption, Surgical training

INTRODUCTION

Endoscopic spine surgery represents a transformative shift in spine surgery care, providing patients with a minimally invasive alternative that significantly reduces tissue disruption, speeds recovery, and enhances surgical outcomes.¹ However, despite its advantages, the adoption of endoscopic techniques in spine surgery has faced resistance, primarily due to a difficult learning curve and the fundamental shift required from traditional surgical practices.

This challenge is not unique to spine surgery. Other surgical specialties, such as orthopedics, general surgery, and gynecology, have faced similar hurdles during their transitions to endoscopic techniques. For example, the adoption of arthroscopic surgery in orthopedics and laparoscopic procedures in general surgery initially met skepticism due to the technical demands of operating within confined, 2-dimensional visual fields and the need for specialized instruments. Surgeons had to reimagine workflows, redefine anatomical landmarks, and invest significant time in mastering new skills. However, these fields have since embraced endoscopy, driven by its undeniable benefits for patients, including reduced morbidity, shorter recovery times, and improved outcomes.

Spine surgeons now find themselves at a similar crossroads. Transitioning from open or mini-open

techniques to endoscopic approaches requires an entirely different surgical mindset. Unlike traditional methods that provide direct, 3-dimensional visualization of anatomy, endoscopic techniques rely on indirect visualization through high-resolution cameras and monitors that surround the surgical field. This necessitates not only technical dexterity but also a shift in how surgeons conceptualize and navigate complex spinal anatomy. Unlike traditional open surgery, endoscopic spine surgery requires mastering an entirely new skill set. Surgeons accustomed to the direct, 3-dimensional visualization of open procedures must adapt to working within a confined, 2-dimensional operative field, relying heavily on advanced imaging techniques and precise instrumentation. This transition can be daunting, requiring a high degree of manual dexterity, spatial awareness, and familiarity with interventional radiology principles.

Furthermore, the initial investment in specialized equipment, the need for team training, and the increased procedural time during the early learning phase pose additional barriers.

Despite these obstacles, the long-term benefits of endoscopic techniques—minimized patient morbidity, reduced recovery time, and the potential for outpatient procedures—make the effort worthwhile. This manuscript aims to provide a detailed, step-by-step guide to managing the learning curve of lumbar endoscopic

spine surgery (LESS). Particular attention is given to preparation and checklists, emphasis of key milestone steps, avoiding common learning curve pitfalls, and the importance of cadaveric practice, simulation training, and mentorship from experienced endoscopic surgeons.

TRANSFORAMINAL UNIPORTAL APPROACH

The classic description of LESS is for the transforaminal approach as described by Parviz Kambin, Anthony Yeung, and others.² This well-described approach allows for unimpeded, percutaneous access to the spinal canal. It is the most utilized endoscopic technique to treat posterolateral intervertebral disc herniations, foraminal stenosis, and symptomatic annular tears. Access to the canal up to the midline can be readily achieved from L1 to L2 to L4 to L5 disc herniations. The unique features of the L5 to S1 level make transforaminal approaches limited to foraminal stenosis or foraminal, far lateral disc herniations. Most posterolateral disc herniations at L5 to S1 are better treated via the interlaminar approach.

Preoperative Preparation

The key to improving the learning curve is excessive preparation of all equipment, room setup, and familiarization of the surgical team with a new procedure. As expounded by Dr. Atul Gwande in the Checklist Manifesto, the use of the checklist remains the cornerstone of preoperative preparation. Initially, the checklist will be vast, but as experience grows, the “LESS Surgery Checklist” is gradually simplified to focus on

items above and beyond the basic spine set (Figure 1). Modern, electronic checklist systems will continue to ease this burden.

Room Setup, Patient Positioning, and Marking of the Surgical Sites

The endoscopic spine room will need to be large, as it needs to accommodate the C-arm, the endoscopic tower, a neuromonitoring station, and sometimes a navigation system. Thoughtful placement of the equipment greatly diminishes the stress and anxiety of the learning curve. In addition, ergonomic placement of the endoscopic monitor and foot pedals can avoid awkward positions that can lead to early fatigue.

The patient is placed in the prone position using the Wilson bow frame, ensuring that the abdomen is not compressed, and on a radiolucent table, such as the Jackson frame (Figure 2). The location of the endoscopic tower, endoscopic monitor, C-arm and display, along with the placement of the power units for the radiofrequency probe, drills, laser generator, and any other equipment, is thoughtfully positioned in ergonomic locations (Figure 2B and C). All obstructions to C-arm imaging should be cleared to facilitate high-resolution intraoperative imaging. The C-arm must have a dedicated space in the operating room with an unimpeded route to immediately bring it back into the surgical field. This will facilitate confirmatory imaging needed intermittently throughout the case.

The patient can be awake using conscious sedation and generous local anesthetic, or the patient can be under light general anesthesia using continuous, free-run electromyography (EMG) neuromonitoring. If the patient is under anesthesia, every burst and spike of free-run EMG activity is announced throughout the procedure. The draping of the patient utilizes pouches to catch overflowing irrigation and drapes to accommodate frequent C-arm repositioning from anteroposterior (AP) and lateral directions (Figure 1).

Percutaneous Targeting and Approach

The key to safe and effective endoscopic spine surgery is meticulous intraoperative imaging with C-arm. Navigation can decrease the need for real-time C-arm imaging, but the precise demands of anatomic localization relative to the exiting nerve root and dorsal root ganglion (DRG) require the use of real-time C-arm imaging during the initial docking and reaming phase. First, a “perfect AP” image of the surgical target level is obtained. The C-arm is rainbowd to the neutral position, straight up and down relative to the floor. The patient is




Figure 1. (A) Photo of the checklist printed prior to each case ensures that all items, instruments, and equipment are available. (B) The electronic version of the checklist that can be used on a computer, tablet, or handheld device. The electronic checklist moves checked items to the bottom of each sublist, making missing equipment obvious at the top of the sublist. Furthermore, the electronic version contains pictures of key items, along with notes, storage, and ordering information. These are modified and optimized on an ongoing basis by each surgical team. Checklists are available at <https://bhanimd.com/master-checklist-home>.

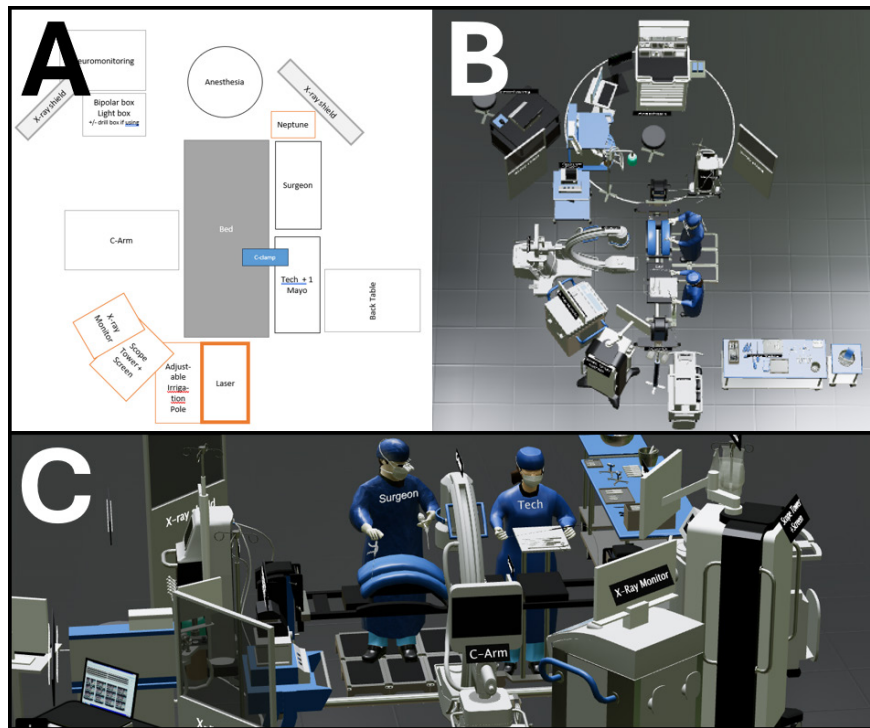


Figure 2. (A) Schematic stick figure diagram of room setup. (B and C) Electronic version of room setup for use on a computer, tablet, or handheld device. The electronic room setup diagram is interactive, allowing for viewing in multiple angles and zooming in and out. The virtual model is available at <https://bhanimd.com/room-setup>.

then rotated on the table until the best AP image of the target level is obtained. The best AP image of the target level is obtained by rotating, or “airplane-ing,” the bed through a series of positions until the “least imperfect” image is obtained. This requires one to airplane past the intended “best AP” to confirm that the next position is less perfect, then go back to the normal position (Figures 3A, B, and C). Then, the C-arm is brought under to the lateral position. A true lateral image can be assured by turning the C-arm left or right while it is parallel to the floor. The perfect lateral image is again the “least imperfect” lateral image, with the pedicles and endplates of the level above and below the target disc space overlapping as best as possible (Figure 3).

The landmarks to the spine are drawn on the skin (Figure 3). The midline is drawn by palpating the spinous processes. With the C-arm kept in the perfect lateral position, a blunt radiopaque probe is used to mark the optimal entry point of the surgical corridor. Depending on the level and any unique features of the pathology, the entry point on the skin is usually 10 to 15 cm lateral to the midline and about 2 to 3 cm cephalad to the disc space line, allowing for a slightly cephalad to caudad trajectory into the disc space (Figure 3). A long 18-g spinal needle with a slight curve is then used to anesthetize the surgical corridor prior to making the incision. The needle is taken all the way to the lateral

aspect of the target facet joint, injecting anesthetic along the way. The lateral aspect of the facet joint is then liberally anesthetized. The tip of the needle is used to palpate the bony surfaces of the facet joint. Using the needle trajectory, adjustments can be made for the optimal entry point.

The incision is small, usually made with a stabbing maneuver with a size 10 scalpel. The precise location of the incision can be adjusted according to the information obtained during the injection with anesthetic. The thin initial dilator is used to create the surgical corridor (Figure 4). Using lateral C-arm imaging, the initial probe is gently inserted through the paraspinal muscles, aiming for the lateral aspect of the facet joint (Figure 4). Once docked on the bony surface, the tip is walked anteriorly using palpation and lateral C-arm imaging. As the tip of the initial dilator enters the neuroforamen, a distinct release of the intertransverse membrane can be appreciated, followed by the empty space of the neuroforamen. From this point, an extreme degree of care and vigilance is needed to avoid irritation of the exiting nerve root. As the initial dilator enters the canal, any nerve activity, alerted by pain if the patient is awake or free-run EMG activity if the patient is under general anesthesia, is noted and any necessary adjustments are made to avoid any threat of nerve irritation. Aiming more caudadly toward the superior, lateral edge of the

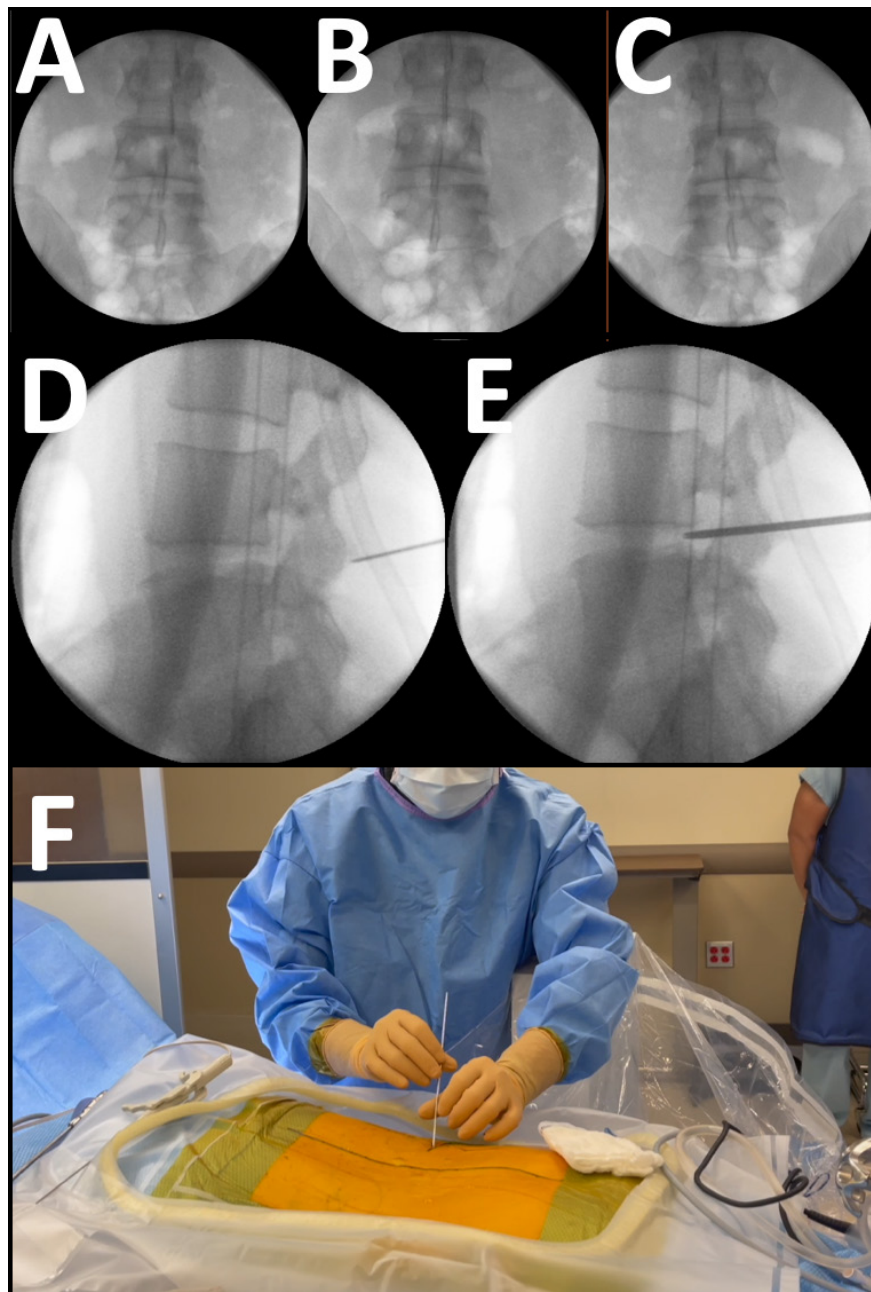


Figure 3. Intraoperative anteroposterior (AP) C-arm image to find the “perfect AP.” The AP view is obtained for each level of surgery. The perfect AP view is obtained with the C-arm straight up, perpendicular to the floor. The patient is then rotated on the bed until the best AP image can be obtained. The perfect AP view is actually the “least imperfect” view, which is obtained by rotating the bed back and forth from imperfect (A), to perfect (B), then beyond to imperfect again (C), then back to perfect (B). The patient is now square relative to the floor. The C-arm is then brought under the table, parallel to the floor, for a lateral view. Wagging the C-arm side to side then aligns the endplates and pedicles. Again, the least imperfect view is chosen. With the best lateral image, the spinal needle is used to anesthetize the surgical corridor, including the lateral aspect of the facet joint (D). The needle also serves to fine-tune the location of the incision for optimal trajectory of the initial dilator (E). Depending on the pathology to be addressed, the transforaminal approach is usually 10 to 15 cm from the midline about 2 to 3 cm cephalad to the disc space line. The initial dilator lands on the facet joint, which is then walked down the superior articular process (F). The intertransverse membrane is then penetrated using a controlled back-and-forth twisting motion. A release can usually be appreciated.

caudal pedicle serves to move away from the exiting nerve root.

The initial dilator is advanced until it is docked on the surface of the disc within Kambin’s triangle, the clear space bordered by the exiting nerve root, the traversing nerve root, and the caudal pedicle (Figure 4C).²

The tip of the initial dilator is aimed with a bias toward the caudal pedicle, making it as far away from the DRG of the exiting nerve root as possible. Once docked on the Kambin’s triangle, the probe is gently wanded back and forth to palpate the surface of the disc to confirm its texture and shape. All the while, neuromonitoring is

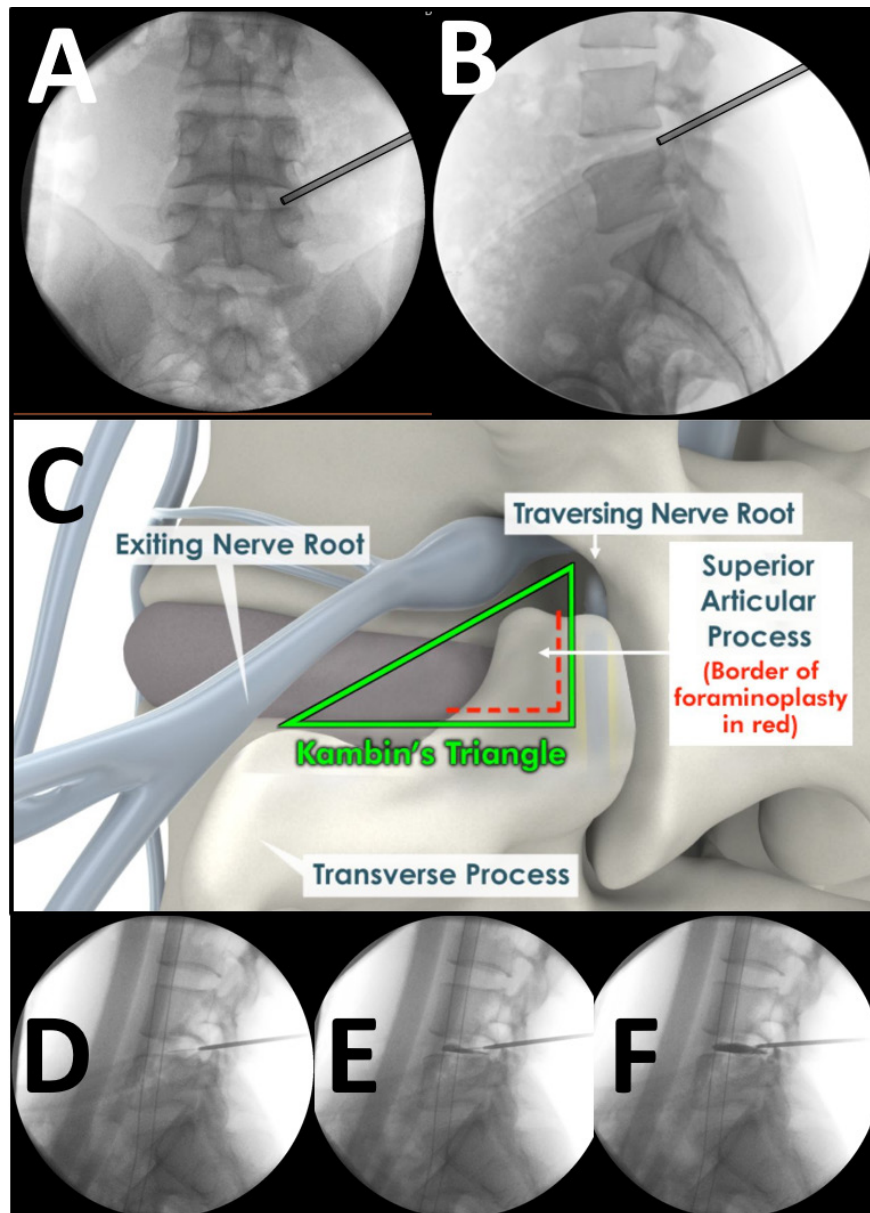


Figure 4. The initial dilator should be lateral to the medial border of the pedicle on anteroposterior (AP) imaging (A), at the posterior vertebral body line on the lateral image (B), and angulated slightly cephalad to caudad, which allows the initial dilator to enter the neuroforamen from a more medially. The tip is then directed to Kambin's triangle, bordered laterally by the exiting nerve root and medially by the traversing nerve root (C).² The initial dilator is then wanded back and forth to palpate and clear the disc. A long 22-gauge spinal needle is then inserted through the initial dilator and into the nucleus of the disc. A chromatodiscograph is performed using a combination of dye (either methylene blue or Indigo Carmine) and preservative-free contrast media. The C-arm is kept in the lateral position, and serial images are obtained to outline the annular defect (D, E, and F). The injection is halted when contrast media can be seen leaking posteriorly (F).

carefully observed for undue activity. On the AP image, the probe should be lateral to the medial wall of the pedicle, while the lateral image shows the probe to be at the posterior vertebral body line, well away from the neuroforamen (Figure 4A and B).

Chromatodiscogram, Dilation, and Foraminal Reaming

Once the initial dilator is docked safely on Kambin's triangle, a long 22-g spinal needle is inserted through

the initial dilator into the nucleus. As with every maneuver, every percutaneous maneuver is preceded by careful attention to the feel of the disc and lack of free-run EMG neural activity. A gentle tapping motion as a test is frequently utilized. If the needle does not feel like it is docking on the disc, or there is excessive neural activity, then the maneuver is paused until a full assessment of the situation is completed. Often, an AP image is obtained to confirm the desired position of the instrument (Figure 4). Once the needle is safely inserted

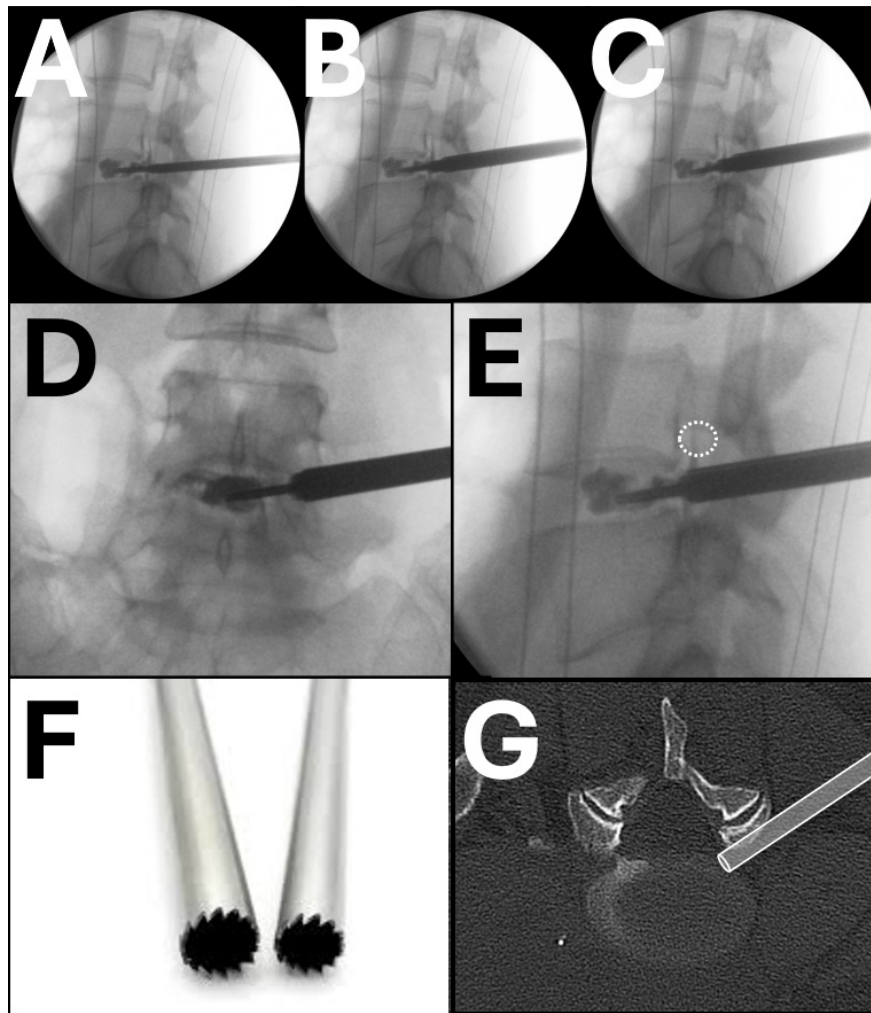


Figure 5. The initial dilator is tamped into the disc and used as an anchor for the dilation and reaming. Sequential dilators and reamers are used to expand the surgical corridor. Again, the C-arm is kept in the lateral position to monitor the position of the instruments. Each reamer should be controlled with 2 hands. The left hand rests on the patient and pinches the reamer while the right hand rotates the reamer back and forth while applying gentle downward pressure with both the right and left hands, thus maintaining exquisite control of the reamer. The surgeon should appreciate the dorsolumbar fascia, the scrapping along the superior articular process (SAP) bone, penetration of the intertransverse membrane, and the rubberlike feel of the disc as the reamer passes along the various anatomic landmarks (D and E). The end-cutting reamers are needed to remove the anterior edge of the SAP bone, but more importantly, it releases the facet joint capsule and ligamentum flavum, which often blocks the canal from view (F and G). The teeth of the reamers are asymmetric, with the cutting edge employed with a clockwise rotation, and the more blunt edge used with a counterclockwise rotation (F).

into the disc, a chromatodiscogram is performed using a mixture of methylene blue and contrast media (Figure 1). The injection is performed with careful, serial C-arm imaging to assess the fill pattern of the discogram. The injection is halted when a leakage through the posterior annular defect is appreciated (Figure 4). Extreme care is taken to avoid an intrathecal injection.

The needle is then withdrawn, and the initial dilator is tamped into the disc, serving as an anchor for the dilation and creation of the surgical corridor. Over the initial dilator, a series of sequentially larger dilators are inserted to expand the corridor (Figure 5). At each dilation step, end-cutting crown reamers are used to release the ligamentous attachments of the facet joint capsule

and remove any bony obstruction into the neuroforamen. The end-cutting reamers are used with extreme care, using a controlled reciprocating, back-and-forth rotating motion with both hands. One hand rests on the patient and grasps the reamer shaft with the fingertips, allowing for fine control and tactile feedback. The other hand grasps the handle to rotate and push down on the reamer. Meticulous assessment of nerve irritation is pursued, either with the patient awake and able to communicate any undue pain or with free-run EMG neuromonitoring.

The direction of the teeth is such that a clockwise rotation confers a cutting function to the reamer, while a counterclockwise rotation allows for more blunt dissection (Figure 5F). Once docked on the disc, the

end-cutting reamer is rotated counterclockwise to release any epidural adhesions that could capture dural tissue during the dilator maneuver. The working cannula is inserted over the final dilator, and the endoscope is inserted to visualize the surgical field for the first time. Throughout these steps, the C-arm is kept in the lateral position for frequent confirmation of anatomic landmarks. Once the endoscope is inserted into the cannula, the C-arm is removed from the lateral position.

A wide, open-mouth cannula, 8 mm in outer diameter, is used with a 30° angle spinal endoscope. The spinal endoscope is incorporated with a 3.2-mm diameter working channel for all the endoscopic instruments, such as the radiofrequency probe, the yttrium aluminum garnet-holmium laser probe, endoscopic drill, endoscopic ultrasonic bone scalpel, endoscopic rongeurs, and various probes (Figure 1). The entire unit also contains the irrigation inflow and outflow channels, the optical lens, and the light source.

Exposure of the Surgical Target Site

The initial appearance of the surgical field is limited, with abundant blood vessels, epidural fat, reticular, frayed strands of facet joint capsule, and ligamentum flavum floating about the surgical corridor (Figure 6). Using a radiofrequency probe with a deployable curved tip (Figure 1), the surgical target site is exposed, starting with the bony landmarks of the superior articular process (SAP). The working cannula is maneuvered dorsally while using the radiofrequency probe to palpate and clear the surgical field until the bone surface is appreciated. A key technical skill is needed to maneuver the curved tip probe. Because the surgical corridor is locked within a tight compartment, it is very difficult to sweep the working cannula side to side. To reach the periphery of the surgical corridor, the curve probe is pushed out of the metal sleeve to varying extents. The more it is pushed out, the greater the displacement from the central axis (Figure 6). To sweep along the periphery of the surgical target site, instrument is rotated, rather than angulated, to sweep along the outer circumference of the surgical target site (Figure 7). Practicing this awkward maneuver *ex vivo* prior greatly improves the learning curve.

The exposure is then directed caudally and anteriorly, walking down the caudal pedicle. A bony arch can be appreciated, made up of the lateral edge of the SAP, which angles down to become the upper margin of the pedicle (Figure 8). Often called “Wagner’s arch,” as described to me by German spine surgeon Ralf Wagner, this is a reliable bony landmark, unaffected by degenerative changes,

furthest from the exiting nerve root. The base of this arch leads the surgeon into the disc space within Kambin’s triangle. The ball tip probe is then used to clear the entry-way into the canal by passing the probe’s medial border of the pedicle. An AP C-arm image showing the probe medial and inferior to the pedicle verifies that the anterior aspect of the spinal canal is accessible (Figure 8B). In addition, articulating instruments, such as the articulating curettes, are used to continue the dissection of key structures away from the dural tube and neural elements (Figure 9).

The working cannula is then maneuvered toward the foramen, and the exiting nerve root is identified. It is not necessary, or desirable in most cases, to expose the exiting nerve root. Rather, the bony ridge of the endplate is identified and used as a guide to the anterior aspect of the neuroforamen. A curved probe is then passed superiorly, beneath the exiting nerve root. Another AP C-arm image verifies the anatomic location of the probe (Figure 9). Usually, the edge of the exiting nerve root can be appreciated. The exiting nerve root is treated with great care, avoiding unnecessary exposure and manipulation. Once Wagner’s arch is exposed, including the tip of the SAP, the disc within Kambin’s triangle is identified, and with the exiting nerve root protected from the surgical field, the canal can be entered. Pathologic tissue, such as herniated disc material, osteophytes, hypertrophic ligamentum flavum, hypertrophic facet joint capsule, and/or facet cysts, is removed using the most appropriate and effective tools, such as endoscopic Pituitary and Kerrison rongeurs, punches, drills, curettes, ultrasonic bone resectors, and the YAG-Holmium laser.

Uniportal Transforaminal Endoscopic Discectomy

Annular tears and herniated disc material can be readily seen from the dye of the chromatodiscogram (Figure 10). Depending on the pathologic lesion, the endoscope is maneuvered into position to accomplish the goals of the surgery. Typically, extruded disc material within the canal, along with loose, pathologic fragments, is retrieved with endoscopic graspers and rongeurs. The edges of the torn annulus are treated with the radiofrequency probe and/or the YAG-Holmium laser probe to initiate a new healing reaction. Epidural adhesions are released, and the dural tube is mobilized to allow for the natural sliding of the neural elements during everyday activities. Articulating curettes, both upgoing and downgoing, are used to further release and decompress the neural elements.

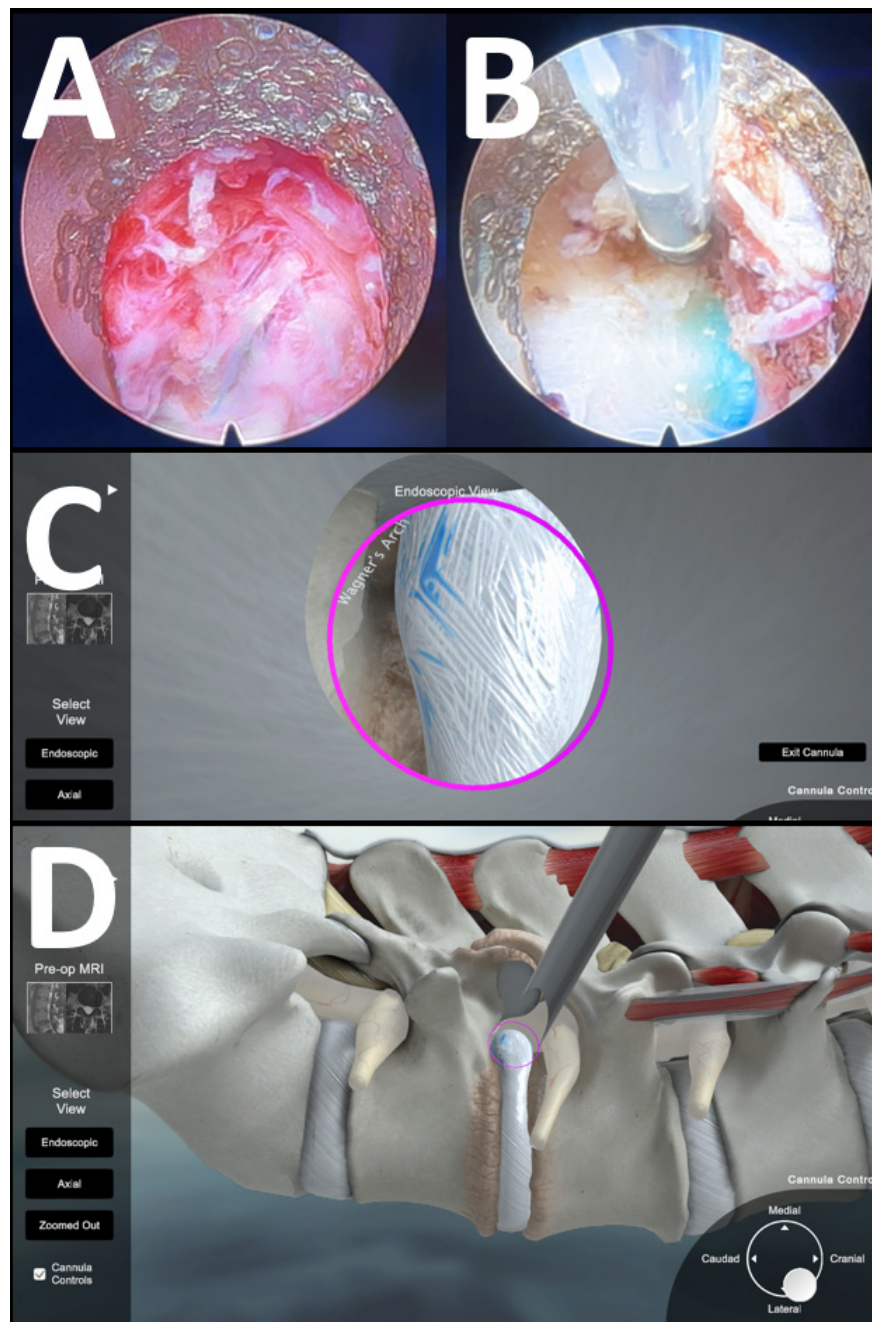


Figure 6. Initial endoscopy view of surgical target site at Kambin's triangle obscured by numerous blood vessels, epidural fat, and frayed remnants of facet joint capsule and ligamentum flavum after reaming (A). The area is carefully approached once the location of the cannula is known by intraoperative imaging. The bevel of the cannula is rotated, and a curved probe is used to palpate and clear the surgical target site. The elastic feel of the disc can be well appreciated. Using bipolar electrocautery and radiofrequency probes, the blood vessels and reticular tissue can be ablated and swept away. The curved probe is fully deployed to reach the periphery of the surgical target site. By rotating the curved probe, rather than angling, the tip of the curved probe will sweep along the circumference of the endoscopic surgical site, acting as a blunt dissector as well as a feeler (B). A great degree of tactile feel is utilized. If a chromatodiscogram was performed, a blue hue may be appreciated at the site of an annular defect, further confirming the location of the disc, which may otherwise resemble a nerve. A guiding principle is that "everything is a nerve until proven otherwise." Pictures of an interactive simulation are shown within the cannula, mimicking the endoscopic view (C) and the virtual view, zoomed out showing the surrounding anatomy (D). Virtual model is available at <https://bhanimd.com/observer-transforaminal>.

Hemostasis

The neurolysis procedure can lead to inconvenient epidural bleeding. Such bleeding is usually readily controlled with gentle electrocautery while temporarily increasing the hydrostatic pressure of the irrigation system. Rarely,

the surgery may be paused to perform gentle compression and tamponade with hemostatic agents. In such circumstances, the endoscope is removed, and the remaining irrigation fluid is evacuated. Using a long tip, 1 to 2 cc of a flowable hemostatic agent (such as collagen foam with




Figure 7. An exercise module for practicing the rotation maneuver to reach out to the periphery of the endoscopic corridor and sweep from side to side without bending the instrument. To allow for a 180° rotation of the probe, the grip of the probe must be such that only fingertips are used to control the instrument (A and B). The radius from the center of the endoscopic corridor is controlled by the amount of the tip that is deployed from its housing, together with the depth of the entire probe relative to the endoscope. The exercise is to paint the entirety of the circle with the tip of the probe while using it through an endoscope rigidly fixed in space (C).

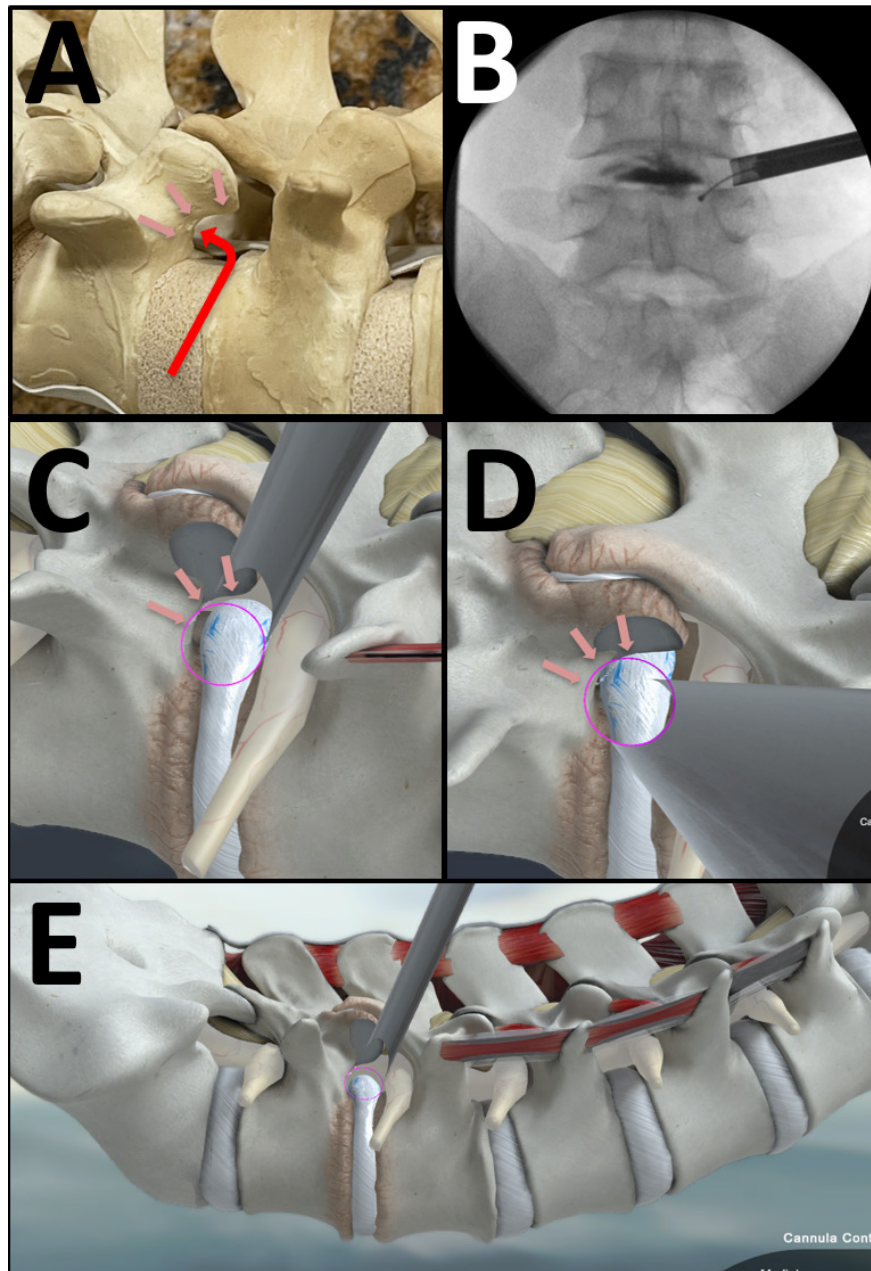


Figure 8. A key anatomic landmark is Wagner's arch, the bony surface is composed of the caudal pedicle as it rises up and meets the superior articular process. It is resistant to degenerative changes and furthest away from the neuroforamen (A). It is readily identified by both palpation and intraoperative imaging (B). Using a curved bipolar probe, the bony surface can be palpated and then swept clear of epidural soft tissue. The base of the arch leads to the inferior edge of the disc space, which then leads to the neuroforamen and canal. Using a blunt probe such as a curved ball-tip feeler, the dural tube can be elevated away from the disc and posterior longitudinal ligament. The blunt probe is then passed over and caudal to the disc space. An expeditious AP image showing the probe caudal to the disc space confirms its location in 3-dimensional space (B). The position of the cannula in relation to Wagner's arch is pictured in multiple angles (C, D, and E) using an interactive virtual model (<https://bhanimd.com/observer-transforaminal>).

thrombin) is injected into the cannula, and the blunt end of the pencil dilator is inserted to gently push down the flowable hemostatic agent. The cannula and probe are then removed, and gentle compression is applied manually for 3 minutes. The pencil dilator is then reinserted into the wound, followed by the working cannula and then the endoscope. The surgical field is then re-exposed, and the bleeding is further addressed if needed. Often, a decrease

in bleeding rates facilitates successful electrocautery of the vessel.

Assessing Completion of Surgery

One of the challenges of endoscopic spine surgery is assessing the decompression and confirming that the goals of the surgery have been achieved. In the setting

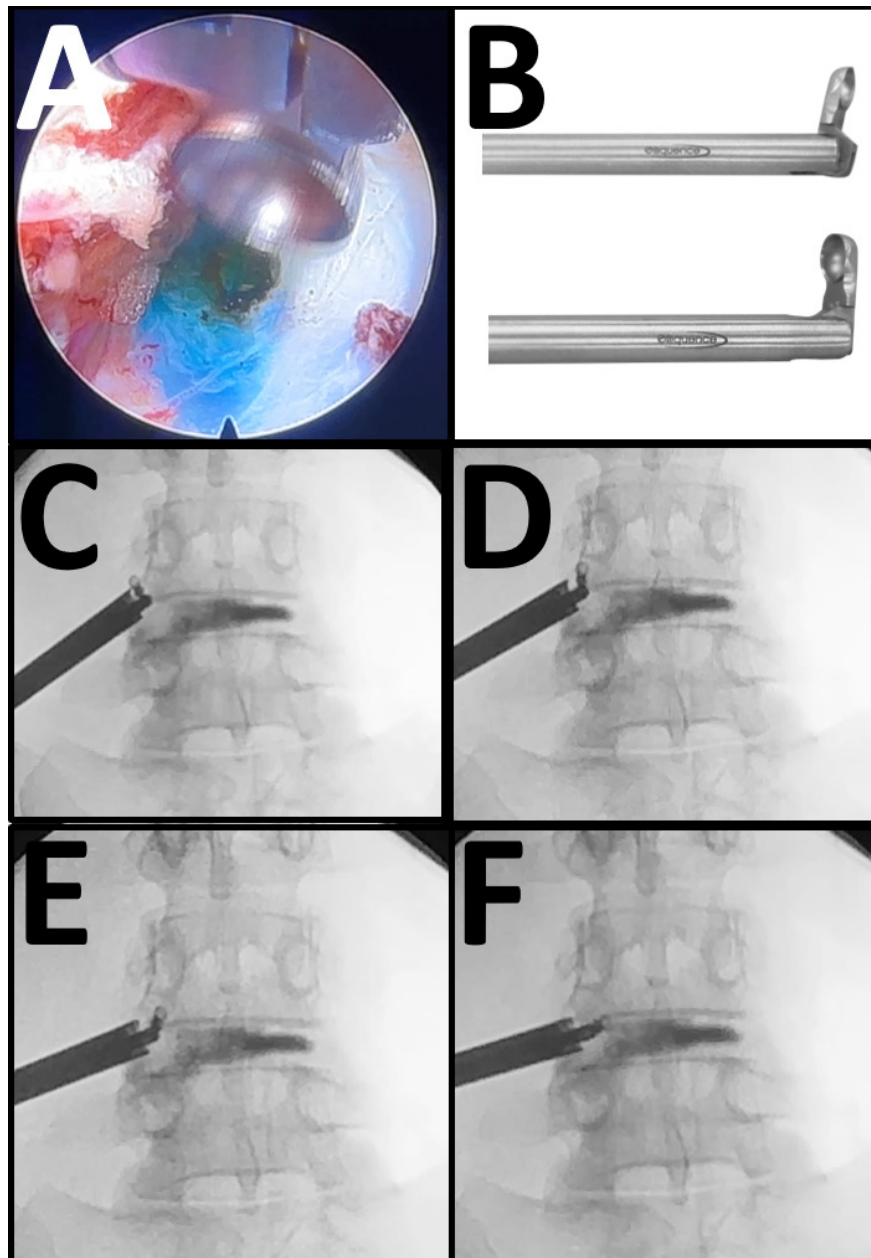


Figure 9. The ability to dissect and sweep tissues about the endoscopic surgical fields is paramount to successful endoscopic surgery. After using the bevel of the cannula to rotate and sweep open the surgical target site, tissues continue to creep into the surgical field. Using various tools, including both curved and articulating instruments, tissue planes can be developed as needed, structures can be nudged over for better visualization, epidural adhesions can be released, and ligamentum flavum and osteophytes can be separated from the dural membrane (A and B). Similar to open surgery techniques, the decompression can be assessed by passing an angled instrument above and below the nerve root. In endoscopic surgery, those instruments must be articulated, with rotation as the main means of sweeping and spanning the surgical site. The tactile feel of the decompression can be readily appreciated. Expedient AP imaging of the probe at various anatomic locations can further confirm the extent of the decompression (C, D, E, and F).

of herniated discs, confirming that all disc material is removed and the neural elements are adequately decompressed may be difficult because it is not possible to visualize the entire surgical corridor at once. With traditional open techniques, the benefit of direct, 3-dimensional visualization makes it straightforward. However, the 2-dimensional nature of the endoscopic image, along with the limited field of view, can lead to much insecurity. To address this limitation, a combination of direct

endoscopic visualization, together with palpation and intraoperative imaging, is used to confirm that surgery is completed. Using the C-arm, the ball tip is passed along the areas of concern. It should be easily passed along the path of the exiting nerve root, down the ipsilateral lateral recess, and across the disc space, without any undue impediment (Figure 10). There should be no impediment to passing the ball-tip probe along the pathology areas.

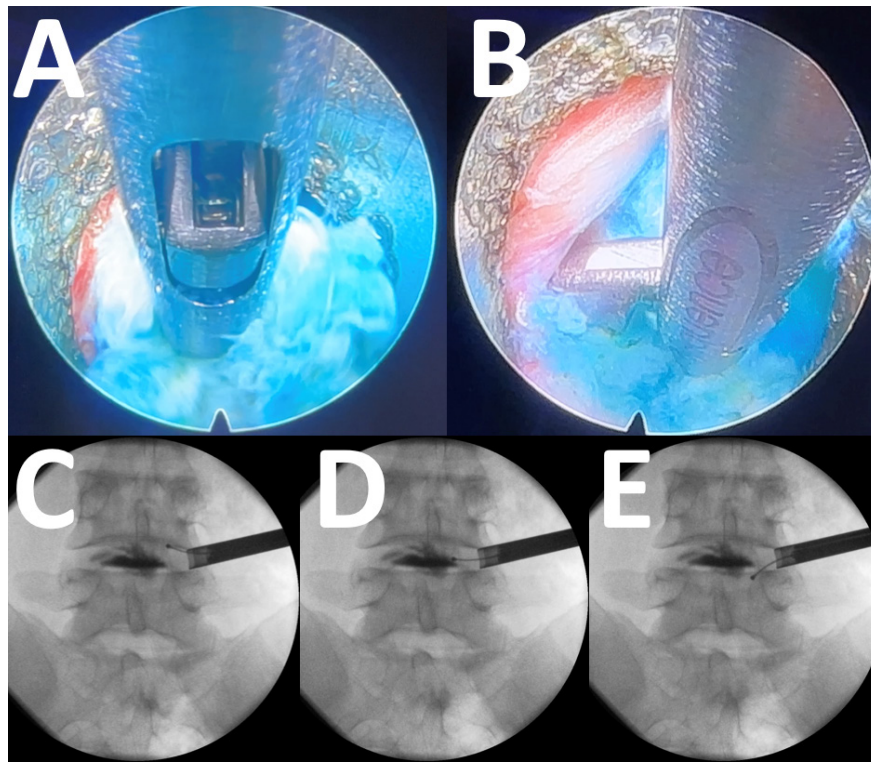


Figure 10. Once the cannula is optimally positioned and the surrounding epidural adhesions are released, endoscopic graspers and baskets can be used to mechanically remove loose disc fragments (A and B). In panel B, the caudal edge of the exiting nerve root can be seen in the upper left corner. When the exiting nerve root is in the surgical corridor, extreme care must be taken to avoid undue friction or compression of the dorsal root ganglion. The bevel of the cannula is rotated to isolate disc fragments and bring them within the surgical field until a thorough decompression is appreciated. A curved probe should readily pass along the anatomic location of the disc herniation, which can be readily confirmed by intraoperative imaging (C, D, and E).

Uniportal Transforaminal Endoscopic Foraminotomy

If there is neuroforaminal stenosis from the SAP, the cannula is maneuvered from Wagner's arch up to the SAP and carefully walked cephalad to the tip of the SAP, which usually protrudes into the sulcus of the neuroforamen occupied by the exiting nerve root. The bony edge of the SAP is then carefully exposed using a combination of the radiofrequency probe and articulating curettes. The limit of the exiting nerve root is confirmed by the location of the probe on intraoperative C-arm imaging (Figure 11). The endoscopic drill or ultrasonic bone resector, together with endoscopic Kerrison rongeurs, is used to remove any material encroaching into the neuroforamen.

INTERLAMINAR APPROACHES—UNIportal AND BIportal

Both the uniportal and biportal techniques usually begin with a uniportal interlaminar approach, centered on the surgical target site, with exposure taken as far as conveniently possible through the uniportal approach. Once the landmarks to the target site are exposed, namely the ligamentum flavum, the base of

the cephalad spinous process, the inferior edge of the cephalad lamina, and the medial edge of the facet joint at the lateral corner of the interlaminar window, a second port can be created 3 to 4 cm either cephalad or caudad to the first port (Figure 12). The second port is created via a stab incision followed by dilation and blunt dissection, analogous to the creation of the first port. A blunt probe is placed through the first port and becomes the lamppost to guide the creation of the corridor of the second port. This stepwise strategy takes advantage of the uniportal technique, including the working channel within the endoscope, thus decreasing the size of the submuscular pocket while allowing for 2 separate working ports that can be used simultaneously.

Room Setup, Patient Positioning, and Marking of the Surgical Sites

The room setup, patient positioning, and draping are analogous to the transforaminal technique (Figure 2). Again, intraoperative imaging is used to rotate the patient to a true AP position relative to the floor. C-arm imaging, which can be combined with navigation, is used to mark the landmarks to the spine. Once the

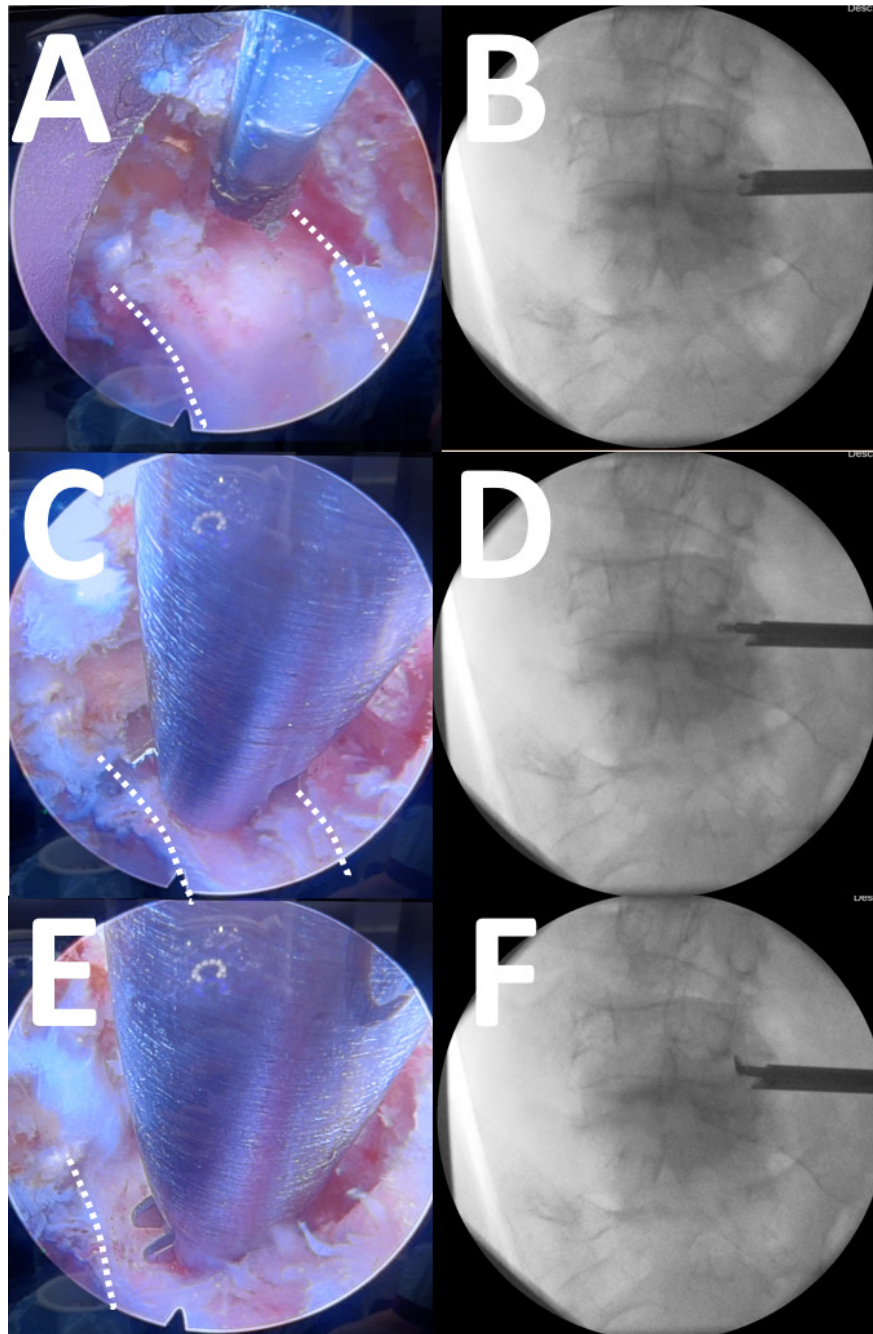


Figure 11. Endoscopic images with their corresponding anteroposterior (AP) C-arm image are shown for this right L4 to L5 foraminotomy. The exiting nerve root is outlined with dotted white lines (A). The curved radiofrequency probe can be seen entering the surgical field from above with the corresponding AP image confirming its anatomic location (B). An articulating curette is deployed between the exiting nerve root and the tip of the superior articular process (C and D). Rotating the articulating instrument sweep the dissection back and forth, identifying any residual areas of stenosis (E and F). Again, intraoperative AP imaging further confirms the anatomic location of the dissection.

patient is positioned in a true AP position relative to the level of the surgery, the lateral image is used to identify the bull's eye of the incision site. The first port is positioned in the optimum approach trajectory for the task at hand. Usually, the first port, through which most of the work will be performed, is slightly caudad to the disc space and slightly lateral to the midline (Figure 12).

Starting With the Uniportal Interlaminar Approach

A small stab incision about 1 to 2 cm lateral to the midline is made with a size 10 scalpel, followed by serial dilation through the fascia and multifidus muscle. Using the final dilator as a blunt dissector, the base of the cephalad spinous process is

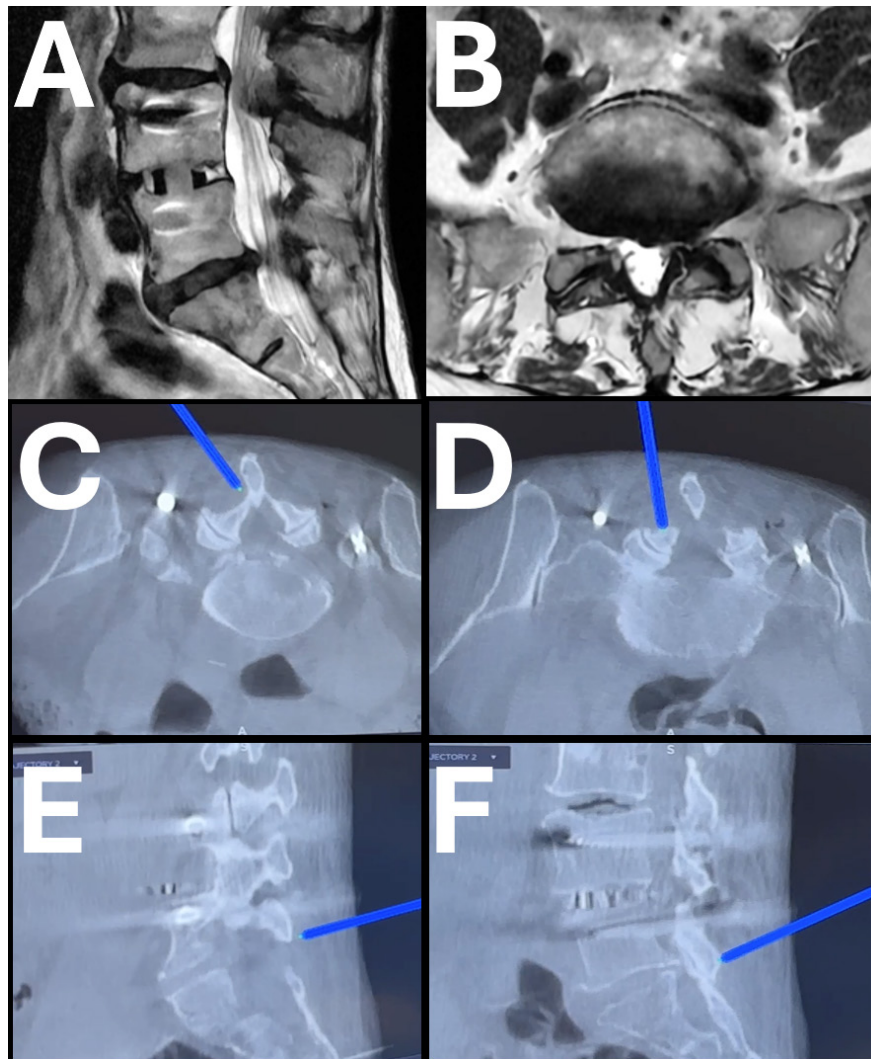


Figure 12. The interlaminar approach is best suited for L5 to S1 disc herniations, facet cysts, and stenosis, especially when adjacent to previous fusion (A and B). Using intraoperative imaging, including image guidance, the initial approach is through a small stab incision 1 to 2 cm from the midline along the path most appropriate to treat the pathology. For most disc herniation and stenosis, the disc space line is used. The initial dilator is first aimed at the base of the cephalad spinous process (C) where there is a relatively clear space to start the submuscular pocket. Sequential dilators are used to rapidly expand the surgical corridor. Using a sweeping and wandering motion, the dilators further clear the interlaminar window, the superior edge of the cephalad lamina, and the medial border of the facet joint (D, E, and F). Tactile feel, together with intraoperative imaging, is used to guide the initial dissection.

palpated and confirmed with intraoperative imaging (Figure 12). Using a wandering technique, the “clear space” is bluntly dissected to detach the thin, reticular muscle attachments to the periosteum. The blunt dissection is then carried laterally, walking along the inferior edge of the cephalad lamina, bluntly dissecting it free from the muscle attachments, and then dropping it into the interlaminar window. Again, a wandering technique is used to clear the interlaminar window. The elastic texture of the ligamentum flavum can be appreciated by palpation. The lateral corner of the interlaminar window, formed by the intersection of the cephalad and caudad lamina as they transition into the inferior and superior articular processes, is also appreciated by palpating with

the dilators. The bony edges of the caudad lamina can sometimes be appreciated, but there is no “bony ledge” since the ligamentum flavum attaches to the caudad lamina along the dorsal surface. The C-arm image is kept in the lateral position to ensure precise localization. The interlaminar working cannula is then inserted, followed by the 15° spinal endoscope, and the surgical corridor is finally visualized. Typically, dense multifidus muscle fibers fill the surgical field (Figure 13).

The curved radiofrequency probe is used to clear the surgical target site. Using a combination of palpation, C-arm imaging, and direct endoscopic visualization, the surgical target site is exposed. Within the uniportal window, the base of the cephalad

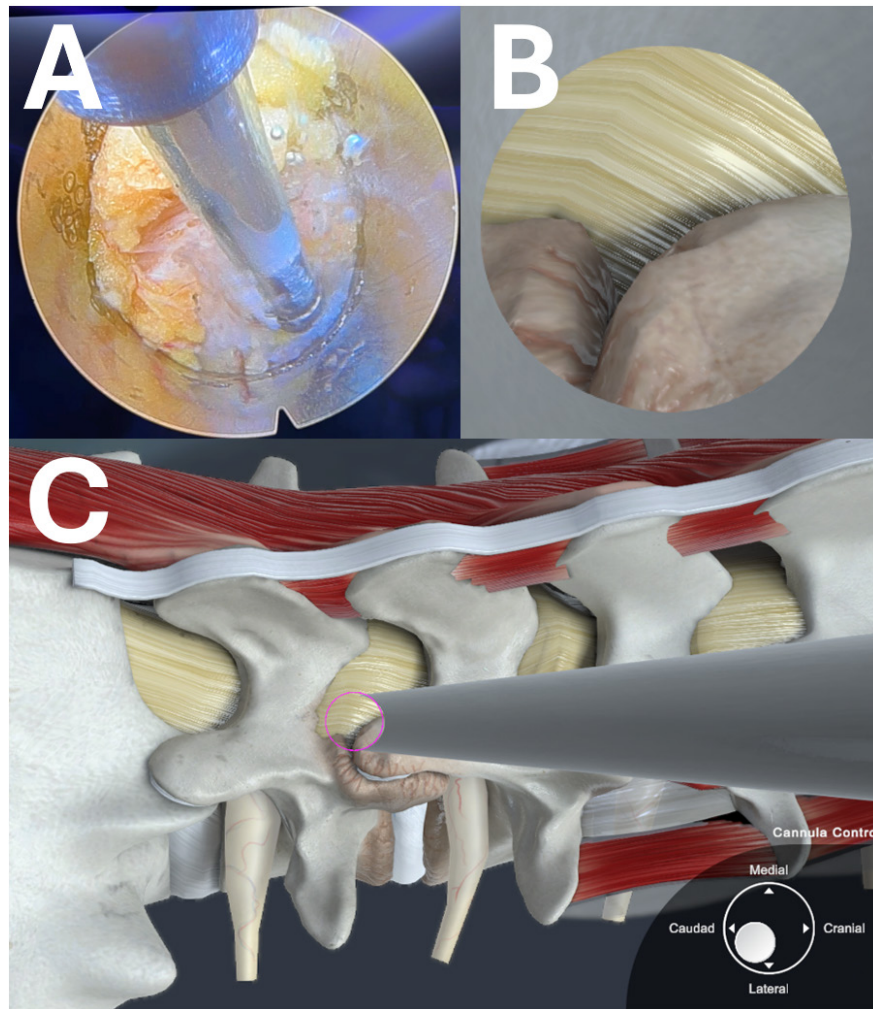


Figure 13. The initial endoscopic view is obscured by dense muscle fibers and epidural fat (A). Using a combination of intraoperative imaging and tactile feel, the bony edge of the cephalad lamina and corner of the interlaminar window is exposed. A picture of the virtual model from the endoscope (B) as well as the zoomed-out view (C) shows the position of the surgical corridor (<https://bhanimd.com/observer-interlaminar>).

spinous process and inferior edge of the lamina, the ligamentum flavum, and sometimes the edge of the caudad lamina should be clearly exposed and readily visualized. Depending on the specific pathology and any unique anatomic characteristics of the patient, the limits of the laminotomy window are marked with the endoscopic drill or ultrasonic bone scalpel (Figure 14). The desired bony resection is completed, along with debridement of the superficial layer of the ligamentum flavum.

To treat an ipsilateral disc herniation or unilateral stenosis (such as from a facet cyst), the canal is entered by splitting the ligamentum flavum longitudinally along its fibers. The lateral margin of the ligamentum flavum is thinned until the rotation of the endoscopic cannula splits open the ligament along its longitudinal fibers (Figure 14). Kerrison rongeurs can then be used to expand the opening and the ball

tip probe used to release any epidural adhesions. The endoscopic cannula is then carefully advanced along the lateral aspect of the canal, moving past the dural tube. A curved ball-tip probe is often used to release and mobilize the dural tube. The leading edge of the cannula is rotated to sweep the dural tube away from the disc (Figure 15). Minute, gentle sweeping motions further release the dural tube from its epidural adhesions and mobilize it away from the disc herniation. Once the disc herniation is isolated within the confines of the cannula, a combination of probes, rongeurs, and graspers is used to resect loose disc fragments. If needed, a small annulotomy window is created to retrieve loose fragments within the disc. The radiofrequency probe is used to ablate pathologic inflammatory tissue, smooth torn edges of annulus, and maintain hemostasis. If necessary, the

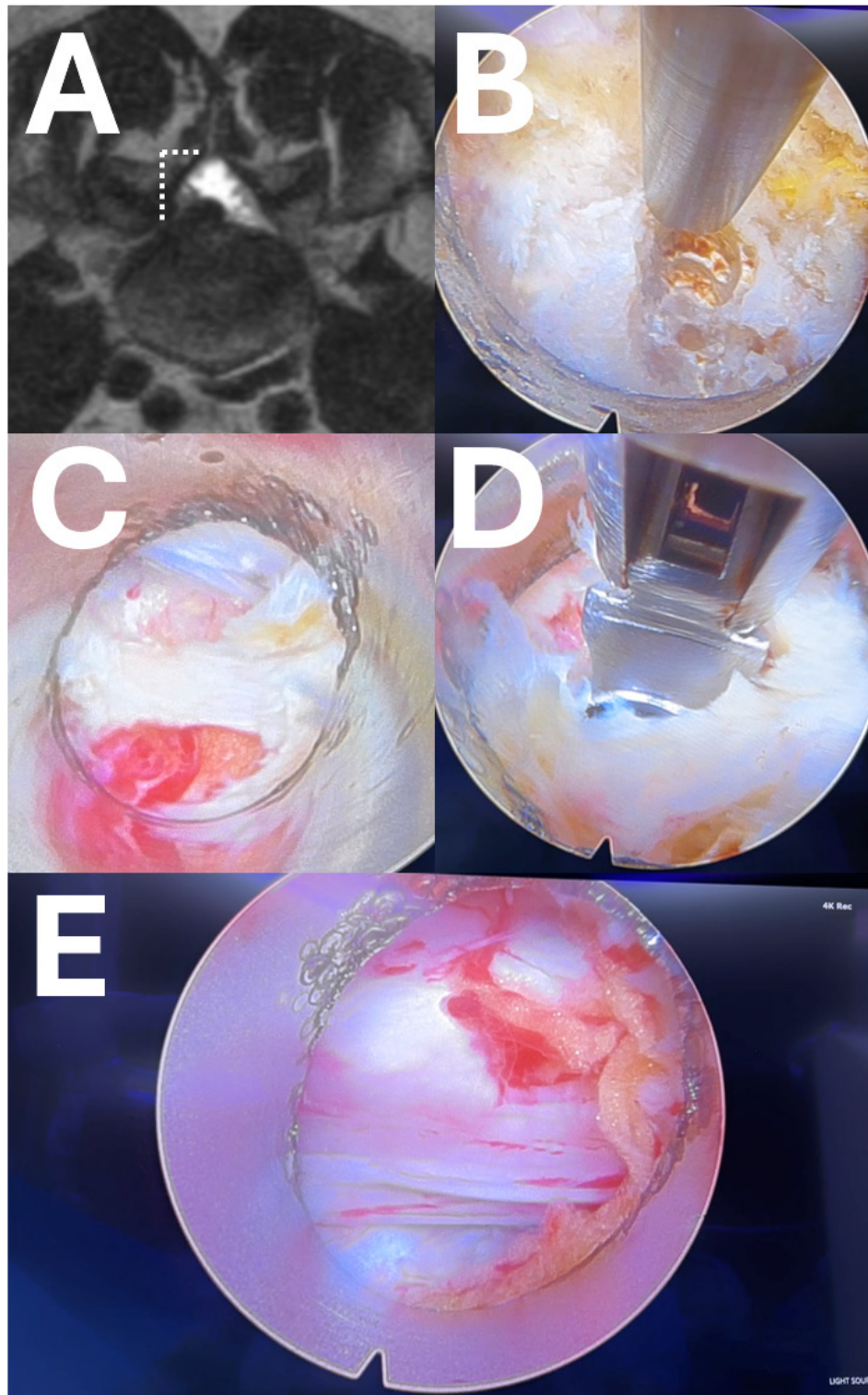


Figure 14. Once the bony landmarks of the laminotomy window is exposed, the appropriate window is created using a combination of the endoscopic diamond burr, the ultrasonic bone resector, and/or Kerrison rongeurs (A and B). Panel B shows the endoscopic ultrasonic bone resector delineating the margins of the laminotomy window. The ligamentum flavum is thinned using graspers, baskets, and rongeurs. Once thin, the bevel tip of the cannula is rotated until a rent in the longitudinal fibers of the ligamentum flavum creates an opening into the canal, which often reveals epidural fat (C). Using various probes, including the articulating curette, epidural adhesions are released, and the dural tube is mobilized (D). The dorsal aspect of the dural tube and the lateral margin of the traversing nerve root can then be exposed (E). The disc can be seen with a blue hue at the inferior margin of the endoscopic window (E).

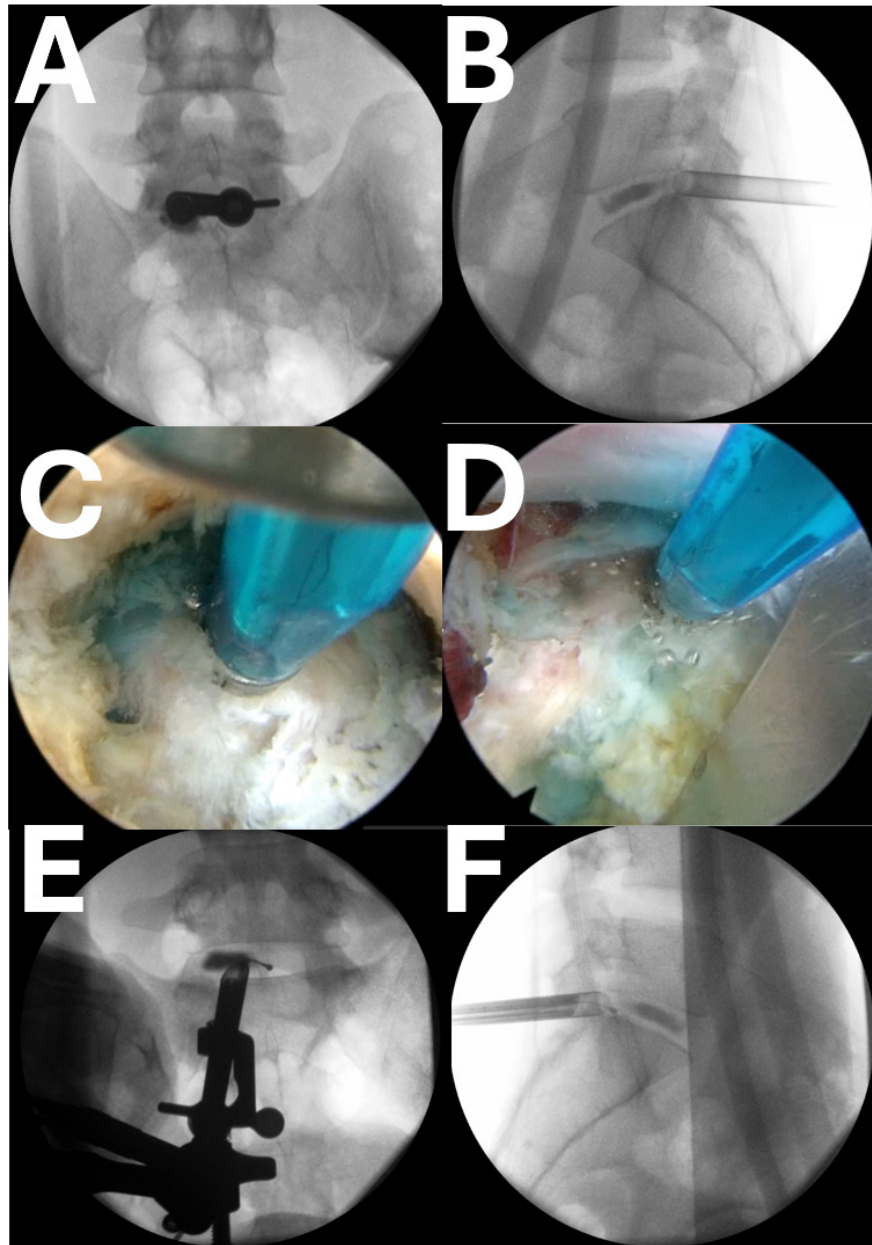


Figure 15. The cannula is carefully advanced aiming lateral and toward the pathology (A and B). By gently rotating the cannula, the dural tube can be mobilized and isolated away from the surgical site (C and D). A curved probe is usually needed to nudge the edge of the dura away from the edge of the cannula. Once the neural structures are protected, a discectomy and decompression are performed with various endoscopic instruments. The decompression is assessed by a combination of direct endoscopic visualization, palpation with curved instruments, and verification by intraoperative imaging (E and F). The probe should readily pass along all the areas of pathology.

ipsilateral recess and foramen can be decompressed through the endoscopic working channel.

Transitioning to the Biportal Approach

Depending on the specific pathology and goals of the surgery, a second port can be created 3 to 4 cm from the first port. A blunt probe is then inserted into the second port and the surgical corridor is further expanded (Figure 16). Through this “open port,” larger instruments, including standard Kerrisons, curettes,

and drills, can be deployed. If needed, the ports can be swapped to facilitate a desired angle or trajectory for the instrument. In rare cases, a third port can be created to accomplish any particularly unique goals of the surgery. In this manner, the versatility of the endoscopic approach is greatly expanded, allowing for more extensive surgeries, including interbody reconstruction and fusion procedures.

In the case of bilateral stenosis, the bone resection is carried to the contralateral side, working above the

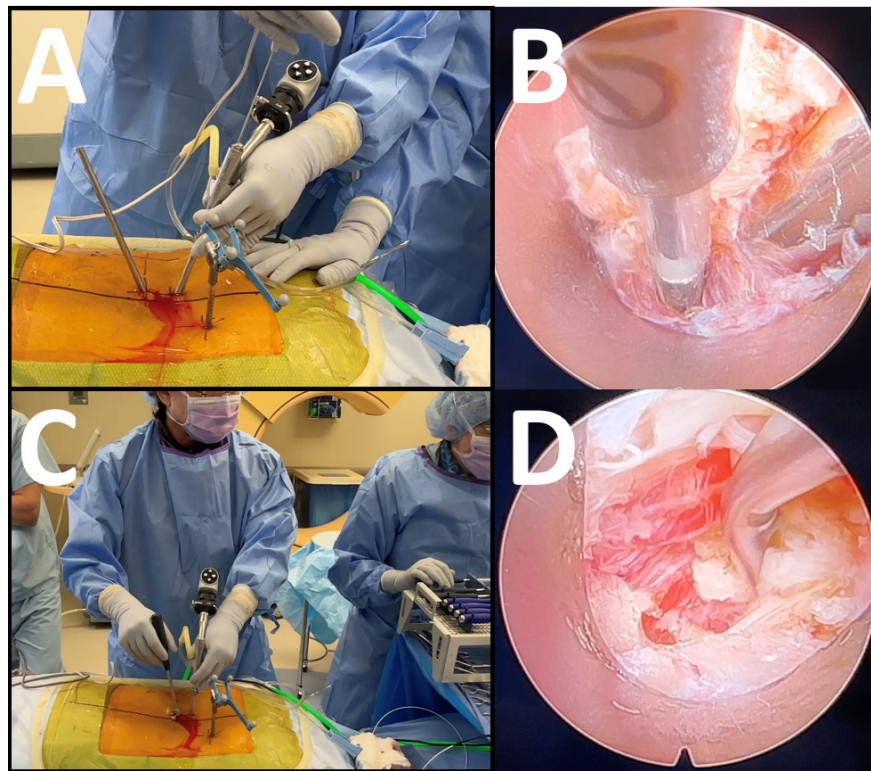


Figure 16. The biportal approach is simply an extension of the uniportal, interlaminar approach. After a reasonable amount of work is completed with the uniportal technique, a second incision is made at the desirable location, and a blunt dilator is inserted (A). The blunt dilator is then exposed under direct endoscopic view. This second port is then used for larger instruments entering from a different trajectory. As needed, the endoscope port and the instrument port can be swapped. Both the endoscopic port and the instrument port can accommodate working instruments such as a curette (C and D).

ligamentum flavum. The ligamentum flavum is left in place to protect the dural tube. Once the majority of the bone resection is accomplished, the ligamentum flavum can be resected in large pieces, using a combination of biting baskets, pituitary and Kerrison rongeurs, and YAG-Holmium side-firing laser probe (Figure 17). A curved ball-tip probe is used to release the dural membrane dorsally and then all the way to the contralateral recess. The extent of the decompression is confirmed through direct endoscopic visualization combined with confirmatory intraoperative imaging (Figure 17).

TIPS, TRICKS, AND OTHER PEARLS

One of the major obstacles to the adoption of endoscopic techniques is the difficult learning curve.^{3,4} To transition from mini-open techniques to endoscopic techniques, a number of challenges must be overcome. First, the surgical corridor must be created using percutaneous techniques. The entry point, angle, and direction of the surgical corridor must be precise. As traditional spine surgeons, we are accustomed to direct 3-dimensional visualization of the surrounding anatomy. As an endoscopic surgeon, I must become an interventional radiologist with the ability to use

intraoperative C-arm imaging for anatomic localization. Both C-arm imaging and endoscopic visualization are limited to 2 dimensions. The endoscopic surgeon must take 2-dimensional information and convert it to accommodate a 3-dimensional world. All this is made worse with limited instruments in a small, restricted space. It is not surprising that endoscopic spine surgery has suffered from a very slow adoption rate. However, once the learning is conquered, the benefits of endoscopic surgery usually make the endoscopic surgeon an enthusiastic champion.

Cadaveric Training and Mentorship

Like any sport requiring a high degree of skill and manual dexterity, prepare for your first case by practicing on models and cadavers until the entire surgery can be performed from start to finish (“skin to skin”) without undue difficulty. The procedural details should follow the well-established, “tried and true,” technique of an experienced endoscopic surgeon. Each step should be followed precisely, without alteration, for at least 5 to 10 cases. During these initial cases, do not mix and match various techniques from different surgeons. Rather, rely on the exact steps of a single mentor

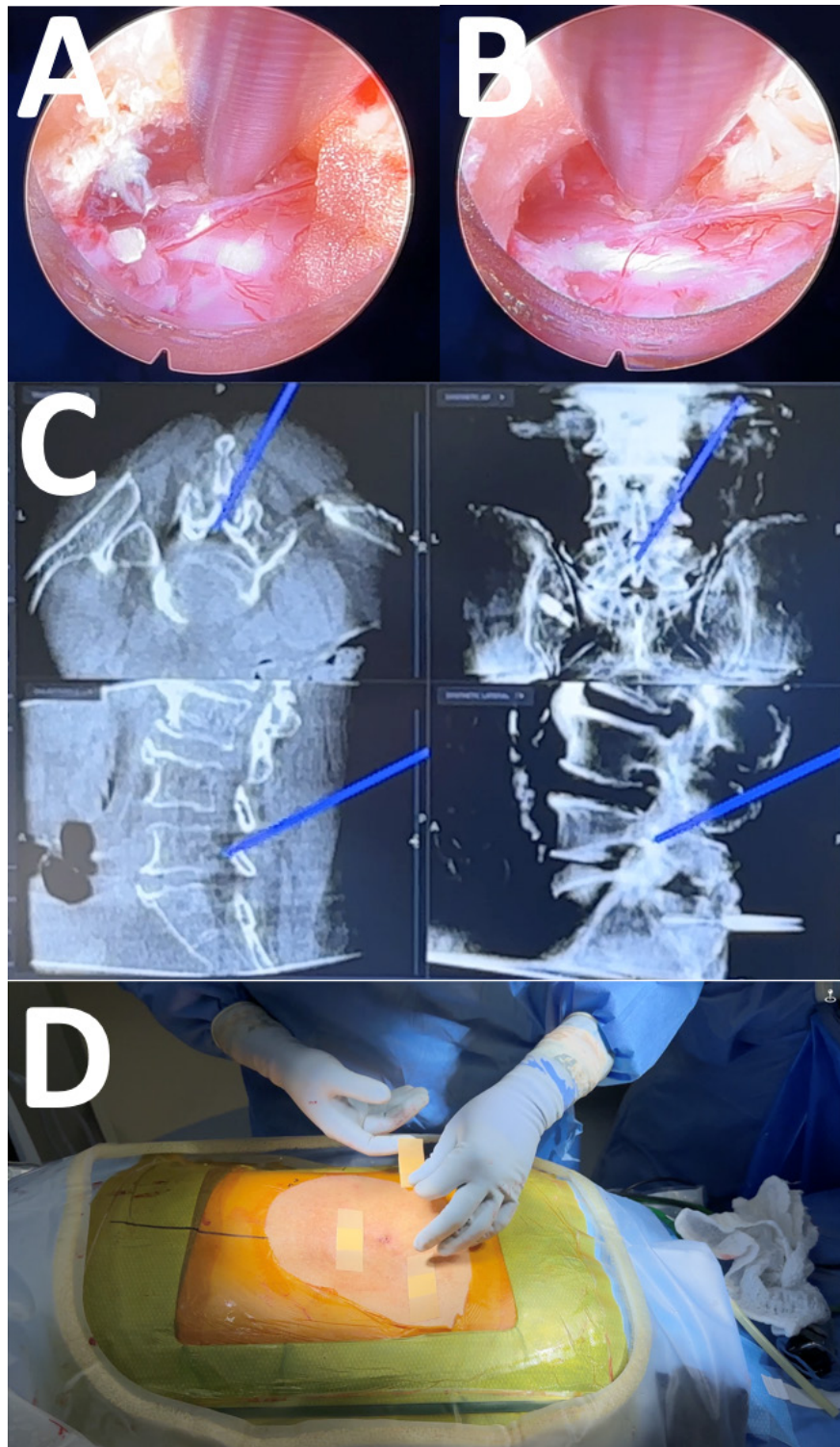


Figure 17. The interlaminar approach, whether uniportal or biportal, allows for contralateral decompression to be readily achieved through the over-the-top technique. The cannula is angled dorsally and medially to expose the base of the spinous process and ligamentum flavum. The ligamentum flavum is separated from the dural tube using curved probes. The ligament is excised using rongeurs and YAG-Holmium laser all the way to the contralateral recess, which seems more anterior than expected. Curettes and probes are used to elevate the dense ligamentous tissue from the dural tube, which can then be further resected with rongeurs. Again, probes should readily pass to the contralateral side, and any other pathology areas, without impediment, and confirmed with intra-operative imaging, either C-arm or navigation (C). Upon completion of the endoscopic procedure, the individual stab incisions are closed with a single subdermal bioabsorbable stitch, skin glue, and a small dressing (D).

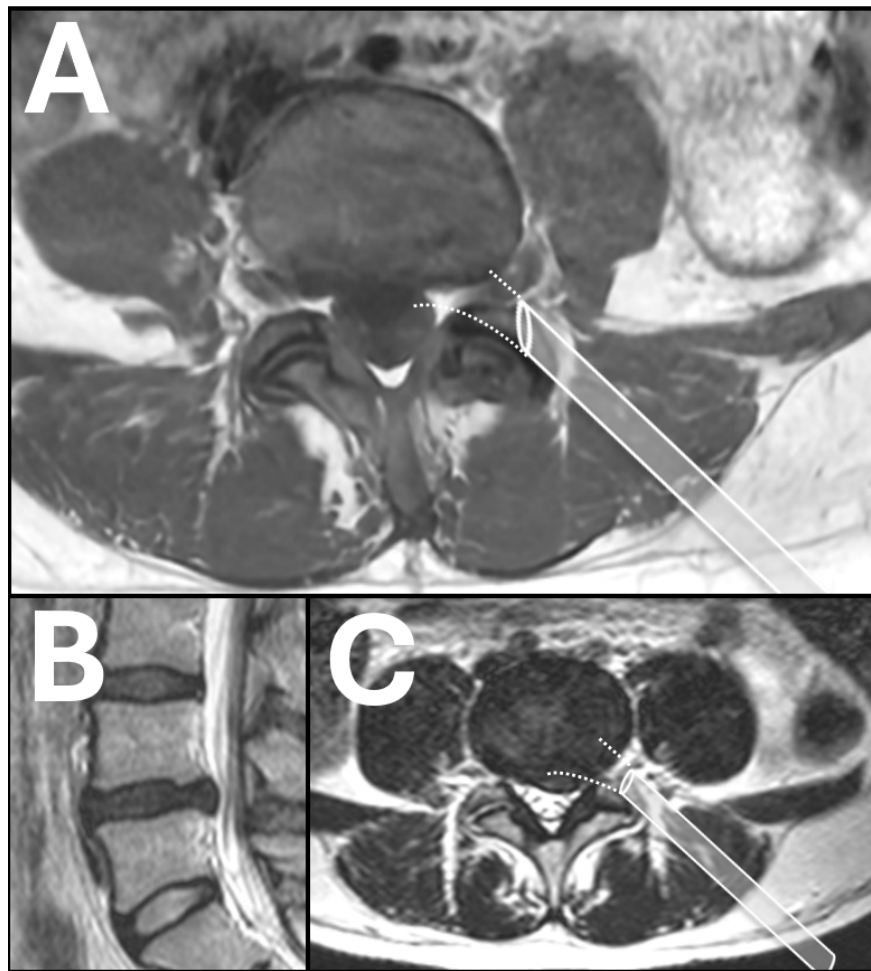


Figure 18. An important learning curve issue is choosing the wrong first case. Most commonly, surgeons will choose a foraminal disc herniation for the first transforaminal case. While a foraminal disc herniation is well treated with lumbar endoscopic spine surgery, it is also very difficult technically. The endoscope, which is angled at 30°, is usually docked medial to the foraminal disc herniation (A). To reach the pathology, the surgeon must work with an endoscope facing in the opposite direction of its design, rendering the image upside down and backward. For experienced endoscopic surgeons, this shift in the visual field can be readily accommodated, although still challenging. Another common misconception is that the contained disc is easier to treat than an extruded herniated disc (B). In actuality, the contained disc herniation that is broad, extending to the contralateral side, is another difficult learning curve case. Again, it is difficult to reach past the midline from a transforaminal approach (C). Furthermore, the lack of a tail that an extruded disc might have is usually absent from a contained disc herniation, making it difficult to know how disc to remove.

who can provide support and guidance throughout the initial phase of the learning curve. Frequent discussions between the surgeon and mentor greatly hasten the learning curve process. Optimally, such discussions occur before and after every case, ensuring that the most appropriate indications are chosen, and each experience allows for ongoing improvements over subsequent cases.

Become an Interventional Radiologist

An additive skill needed by the endoscopic spine surgeon is the facile use of intraoperative C-arm imaging. I began my endoscopic journey by performing epidural injections myself, which gave me familiarity and experience with the world of interventional radiology. By performing my own transforaminal epidural

steroid injections, I became very comfortable with the intraoperative C-arm and realized the importance of effectively communicating with the radiology technician, affectionately termed the “x-ray tech.” An x-ray technician who is engaged, familiar with the specific C-arm machine in use, and able to maneuver the C-arm gracefully will make endoscopic spine surgery seem effortless. In contrast, an uninterested, inexperienced x-ray technician can make it unduly cumbersome and time consuming. Similar to elite special forces units in our military, specific “call signs” are agreed upon prior to the procedure. The most basic call signs involve the direction of movement of the C-arm. Terms such as “wag North,” “roll South,” “push in,” “rainbow over,” and “tilt to the head” are specific terms that describe an agreed-upon maneuver of the C-arm. Even further, the

x-ray technician is encouraged to learn how to go from the AP position to the lateral position expeditiously using the “up and down button” while simultaneously “pushing in” and “rainbowing under” in a smooth integrated movement called the “San Diego Limbo.” Make it known that the x-ray technician is an integral part of the surgical team and expect them to practice and improve upon their respective duties.

Above all else, be absolutely meticulous about accurate intraoperative imaging. Be aware of the effects of parallax and always find the true AP and true lateral view of the surgical target site. Be prepared to use the C-arm intermittently throughout the case, confirming anatomic location during surgery as well as assessing the satisfactory completion of the procedure.

Best and Worst Learning Curve Cases

The most straightforward case for transforaminal endoscopic surgery is an extruded, posterolateral disc herniation at L3 to L4 or L4 to L5. For interlaminar surgery, it is an L5 to S1 disc herniation. Choosing the appropriate first case is paramount to avoiding learning curve complications. For transforaminal approaches, posterolateral disc herniations and symptomatic annular tears at L3 to L4 and L4 to L5 are the best first cases. For interlaminar (uniportal or biportal), L5 to S1 disc herniations are easiest.

Interestingly, aspiring endoscopic spine surgeons will often choose a far lateral disc herniation for their first case. While a foraminal or far lateral disc herniation is a very good indication for a transforaminal endoscopic approach, it is also one of the most difficult learning curve cases. When working through the transforaminal approach, the initial dilator will land medial to the far lateral disc fragment. Thus, when working with a 30° angle endoscope, the pathology is behind the visual field (Figure 18). This necessitates that the surgeon work upside down and backward, in the direction of the unprotected exiting nerve root. This is especially true for an L5 to S1 far lateral disc herniation, where the pelvis and small interpedicular distance greatly limit the size and shape of the surgical corridor.

Another common learning curve challenge is the broad, contained disc bulge that extends medial and to the contralateral side. The geometry of the transforaminal approach makes it difficult to reach such lesions (Figure 18). Finally, endoscopic treatment of bony foraminal stenosis seems appealing, but again, the proximity of the exiting nerve root to the tip of the SAP can lead to excessive DRG irritation.

CONCLUDING REMARKS

LESS represents a major advancement in the field of spine care. Numerous studies show its safety and efficacy in a wide variety of practices. Unfortunately, the adoption of the endoscopic technique has been unusually slow. Much of this is attributable to a very difficult learning curve, rather than a lack of effectiveness. More attention must be focused on the learning curve problem. It is not enough to acknowledge the difficulty of the learning curve. It is necessary to ask what makes the learning curve difficult, and more importantly, how the learning curve can be improved.

ACKNOWLEDGMENTS

Halleck Cui, Black Horse Animation and Design.

REFERENCES

1. Barber SM, Nakhla J, Konakondla S, et al. Outcomes of endoscopic discectomy compared with open microdiscectomy and tubular microdiscectomy for lumbar disc herniations: a meta-analysis. *J Neurosurg*. 2019;31(6):802–815. doi:10.3171/2019.6.SPINE19532
2. Gore S, Yeung A. The “inside out” transforaminal technique to treat lumbar spinal pain in an awake and aware patient under local anesthesia: results and a review of the literature. *Int J Spine Surg*. 2014;8:28. doi:10.14444/1028
3. Morgenstern R, Morgenstern C, Yeung AT. The learning curve in foraminal endoscopic discectomy: experience needed to achieve a 90% success rate. *SAS J*. 2007;1(3):100–107. doi:10.1016/SASJ-2007-0005-RR
4. Lewandrowski K-U, Dowling Á, Calderaro AL, et al. Dyesthesia due to irritation of the dorsal root ganglion following lumbar transforaminal endoscopy: analysis of frequency and contributing factors. *Clin Neurol Neurosurg*. 2020;197(106073):106073. doi:10.1016/j.clineuro.2020.106073

Funding: The author received no financial support for the research, authorship, and/or publication of this article.

Declaration of Conflicting Interests: Choll Kim reports receiving consulting fees from Elliquence.

Corresponding Author: Choll W. Kim, Excel Spine Center, University of California Medical Center, East Campus, San Diego, CA 92120, USA; choll@excelspine.com

This manuscript is generously published free of charge by ISASS, the International Society for the Advancement of Spine Surgery. Copyright © 2025 ISASS. To see more or order reprints or permissions, see <http://ijssurgery.com>.