

Single Entry Posterior Parasagittal Approach Radiofrequency Neurotomy of Cervical Medial Branch: A Feasible Alternative to Conventional Approaches in the Treatment of Cervical Facet Pain

Chee Kean Chen, Chung Chek Wong, Yian Young Teo and Vui Eng Phui

Int J Spine Surg 2021, 15 (6) 1192-1200

doi: <https://doi.org/10.14444/8151>

<https://www.ijssurgery.com/content/15/6/1192>

This information is current as of May 17, 2025.

Email Alerts Receive free email-alerts when new articles cite this article. Sign up at:
<http://ijssurgery.com/alerts>

Single Entry Posterior Parasagittal Approach Radiofrequency Neurotomy of Cervical Medial Branch: A Feasible Alternative to Conventional Approaches in the Treatment of Cervical Facet Pain

CHEE KEAN CHEN, MD, FIPP¹; CHUNG CHEK WONG, MBBS, FRCS, MS (ORTHO)^{2,3}; YIAN YOUNG TEO, MD, MS (ORTHO)²; AND VUI ENG PHUI, MBBS, MRCP⁴

¹Department of Anesthesiology and Intensive Care KPJ Kuching Specialist Hospital, Sarawak, Malaysia; ²Department of Orthopaedics KPJ Kuching Specialist Hospital, Sarawak, Malaysia; ³Department of Orthopaedics Sarawak General Hospital, Sarawak, Malaysia; ⁴Department of Medicine Sarawak General Hospital, Sarawak, Malaysia

ABSTRACT

Background: Cervical facet joint pain is an important cause of chronic neck pain. The recommended treatment for this condition is radiofrequency (RF) neurotomy of the medial branch of dorsal rami. There have been attempts to find safe and effective ways to perform this procedure. The objective of this study is to describe the single entry posterior parasagittal approach and to evaluate the efficacy and safety of this approach compared to the conventional posterolateral approach of RF neurotomy of cervical medial branch.

Methods: The record of all patients with cervical facet pain who were treated with RF neurotomy medial branch of dorsal rami between January 2016 and December 2019 were reviewed retrospectively. Comparisons were made between patients who underwent RF neurotomy with multiple skin entry posterolateral approach and those who underwent RF neurotomy with single entry posterior parasagittal approach. The primary outcome was measured as the mean changes in numerical rating scale (NRS), and the secondary outcomes were duration and complications related to both approaches.

Results: Thirty-one patients who underwent RF neurotomy via posterolateral approach were compared with 40 patients who underwent the procedure via posterior parasagittal approach. Both approaches showed a significant decrease in the NRS from baseline values. However, the differences in the NRS lowering effect at 3 and 12 months between these 2 approaches were not statistically significant. The duration of the procedure was significantly shorter with posterior parasagittal approach (44.13 ± 4.72 minutes vs 54.68 ± 7.39 minutes; $P < 0.001$). There were no serious complications encountered in both approaches.

Conclusions: With comparable efficacy and safety profile between the posterior parasagittal and the conventional posterolateral approaches, the former single skin entry approach offers the added advantage of being less time-consuming. Further randomized prospective studies are necessary to validate these findings.

Cervical Spine

Keywords: cervical facet joint pain, medial branch, radiofrequency neurotomy, posterior parasagittal approach

INTRODUCTION

Cervical facet joint disorder is a common cause of neck pain with the reported prevalence being as high as 50% among patients with chronic neck pain.¹⁻³ When conservative measures fail to alleviate cervical facet joint pain, radiofrequency (RF) neurotomy of the medial branch of dorsal rami becomes the treatment of choice for this condition. Most of the available data over the past few decades have shown favorable outcomes with RF neurotomy in the treatment of cervical facet joint pain.^{4,5} Considering the demand for RF neurotomy in the management of cervical facet pain within the setting of contemporary pain practice, it is not surprising that several modifications to the approaches of

RF neurotomy have been attempted with the aim of improving the efficacy and safety profile of the procedure.

Sluiter et al was the first to describe the posterolateral approach to the cervical medial branch in 1980.⁶ This approach was subsequently modified by van Eerd et al.^{7,8} The posterior approach was first described by Lord et al in 1996. This technique has been adopted by the Spine Interventional Society and is the only technique of which the efficacy was evaluated with a control group.⁹ The lateral approach was first described by Bogduk and Lord as another technique for cervical medial branch block in 1998.¹⁰ It was only in 2005 that the approach was adopted as a technique of RF neurotomy by Vallejo.¹¹ Each approach has its strengths and

weaknesses, but the principle of treatment remains the same: to denervate the medial branch of dorsal rami.

We have been performing both posterolateral and posterior parasagittal approaches for RF neurotomy of cervical medial branch. The posterior parasagittal approach, which is a modification of the posterior approach described by Lord et al,⁹ is carried out with a single skin entry to target 3 consecutive segments of medial branches. The purpose of this study is to describe the posterior parasagittal approach and to evaluate the efficacy and safety profile of this modified technique as compared to the conventional posterolateral approach.

METHODS

This retrospective study was approved by Kuching Clinical Research Centre (CRC Research ID: 55493) and local institutional ethics committee. The study was carried out in Kuching Specialist Hospital, Sarawak, Malaysia. Because this study has a retrospective design, the requirement for written consent was waived. The medical records of all patients undergoing RF neurotomy of cervical medial branch of dorsal rami for cervical facet joint pain from January 2016 to December 2019 were reviewed. Exclusion criteria include cases undergoing other pain procedures in addition to RF neurotomy, such as cervical epidural injection, myofascial trigger point injection, cervical intradiscal procedure, occipital nerve block, RF treatment of C2-C3 joint pain, and RF neurotomy of bilateral cervical medial branches.

The data of eligible cases were retrieved from computerized clinic registries, medical records, procedure charts, and follow-up questionnaires. These include patient demographics which were de-identified (age, gender, body mass index, and occupation) as well as clinical data of the condition (diagnosis and duration of symptom) and pain procedure (duration and complications). Duration of the procedure was defined as the time from the prone positioning on the operating table until the procedure was completed with the application of wound dressing. The data were retrieved with the assistance of clinical assistants who were not involved in the study but had access to the clinical specialists for any queries and clarification in relation to data extraction.

During initial evaluation in outpatient clinic, patients were chosen based on the pattern and distribution of neck pain and local tenderness over cervical paravertebral area, which was typical for cervical facet joint pain. Those with radiological assessments that revealed other conditions, such as cervical disc prolapse, cervical myelopathy, malignancy, infection, and radiculitis,

were excluded. The rest of the patients with cervical facet joint pain without other pathology received a diagnostic cervical medial branch block using 0.5 mL of 0.5% levobupivacaine to confirm the diagnosis, in accordance with the Spine Interventional Society Guidelines.¹² Patients with more than 50% pain reduction lasting longer than 3 hours after the diagnostic block were offered RF neurotomy of cervical medial branch. Informed consent outlining the benefits and potential adverse effects of RF neurotomy was obtained before proceeding with the procedure. The RF neurotomy level was based on the localization of paravertebral tenderness over the corresponding cervical facet joints. Three consecutive medial branches spanning 2 adjacent facet joints were denervated. For example, for paravertebral tenderness over C3-C4 and C4-C5 facet joints, medial branches of C3, C4, and C5 would have to be denervated. From January 2016 until December 2017, RF neurotomy of cervical medial branch was carried out by the posterolateral approach using multiple skin entries. From January 2018 until December 2019, a similar procedure was carried out via the posterior parasagittal approach, and most of the RF neurotomy of ipsilateral multiple segments medial branches were done using only a single skin entry.

Posterolateral Approach Technique

Resuscitation medications and equipment were prepared prior to the procedure. The patient's hemodynamic status (ie, blood pressure, oxygen saturation, and electrocardiogram) were monitored closely throughout the procedure. The patient lay supine on the operating table with the C-arm positioned to provide a lateral view of cervical spine. The target needle point for RF neurotomy was aimed at the center of the trapezoidal shape of the articular pillar. The needle entry site was estimated to be posterior and caudal to the target point. After skin infiltration with 1 mL of lignocaine 1.0%, a 22-gauge, 10-cm sharp and curve RF insulated cannula with an active tip of 5 mm was inserted at the corresponding spinous process under lateral fluoroscopic view. The cannula was advanced at an anterior and superior angle until bone contact (lateral border of vertebral body/waist of facet column) was made (Figure 1A). The C-arm was rotated to the 30° oblique position to ensure that a safe distance between the cannula tip and the segmental nerve was achieved when neural foramen was visualized (Figure 1B). Subsequently, the C-arm was rotated to the anteroposterior (AP) position to confirm the position of the cannula tip at the waist of the articular pillar, as shown in Figure 1C.

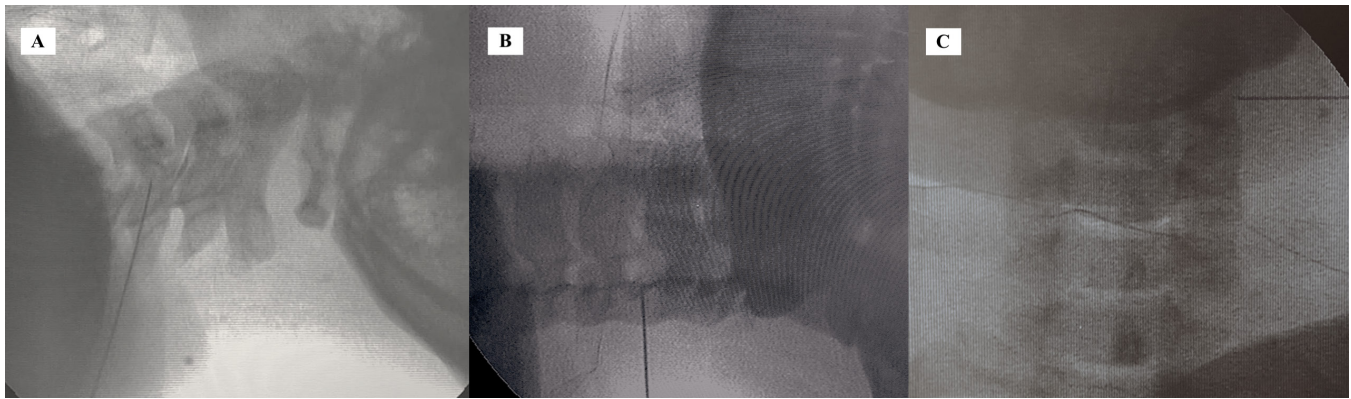


Figure 1. The posterolateral radiofrequency (RF) neurotomy of cervical medial branch. (A) Lateral fluoroscopic view with the RF cannula at C4 anterior portion of articular pillar. (B) Oblique fluoroscopic view with the RF cannula at a safe distance from the neural foramen. (C) Anteroposterior fluoroscopic view with the RF cannula at the waist of the articular pillar.

Single Needle Entry Posterior Parasagittal Approach Technique

As with the posterolateral approach, the necessary resuscitative measures and close monitoring were in place. The patient lay prone on the operating table with the C-arm placed in the axial plane. Three consecutive segments of vertebral bodies intended to be treated were first identified by counting either from C1 caudally or T1 cranially. The patient's head was slightly flexed or extended to obtain an optimal AP view image in the presence of superposition of the head and face with the

cervical spine during initial fluoroscopy. The C-arm was adjusted crania-caudally to square the caudal-most segment of the involved cervical vertebral end plate. The waist of facet column was marked with a horizontal line. A vertical line connecting 2 other ipsilateral waists of the facet column cranially was marked. The intersection of these 2 lines was the needle entry point, as shown in Figure 2.

After the skin was infiltrated with 1 to 2 mL of lignocaine 1.0%, a 22-gauge, 10-cm sharp and curve RF insulated cannula with an active tip of 5 mm was inserted

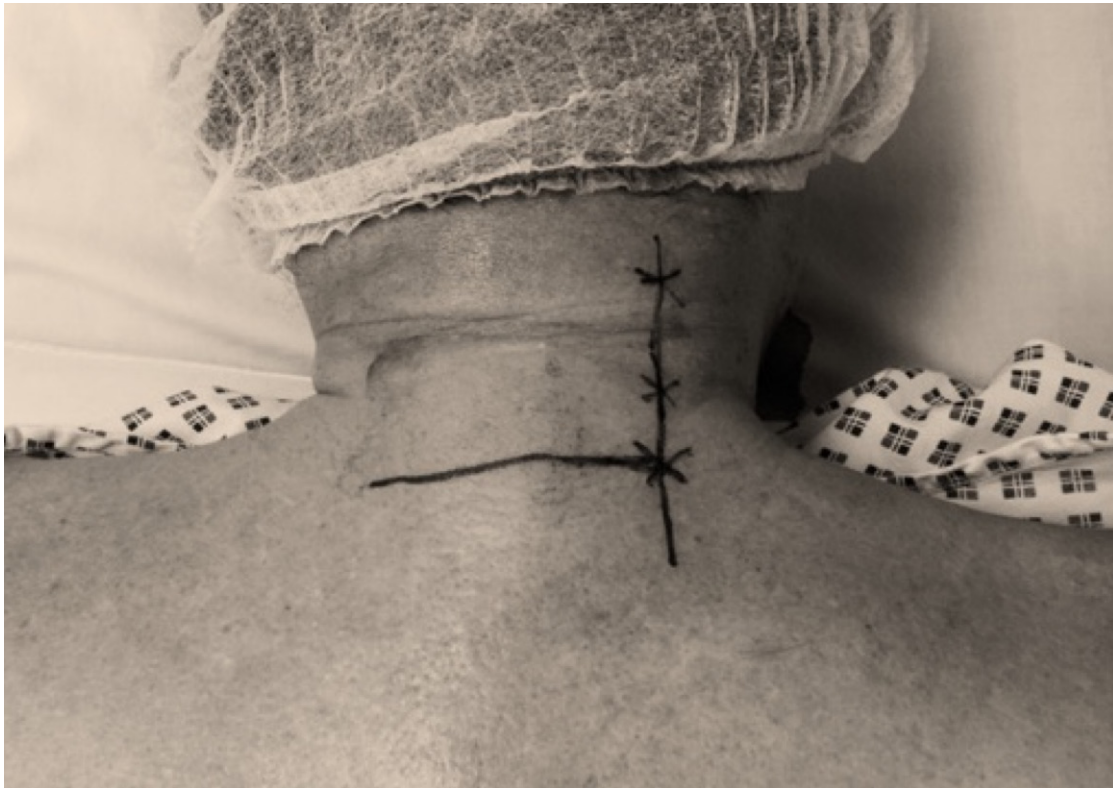

Figure 2. Surface markings with a horizontal line denoting the first segment of medial branch to be treated, vertical line denoting the lateral border of vertebral body. The intersection of these 2 lines is the needle entry point.

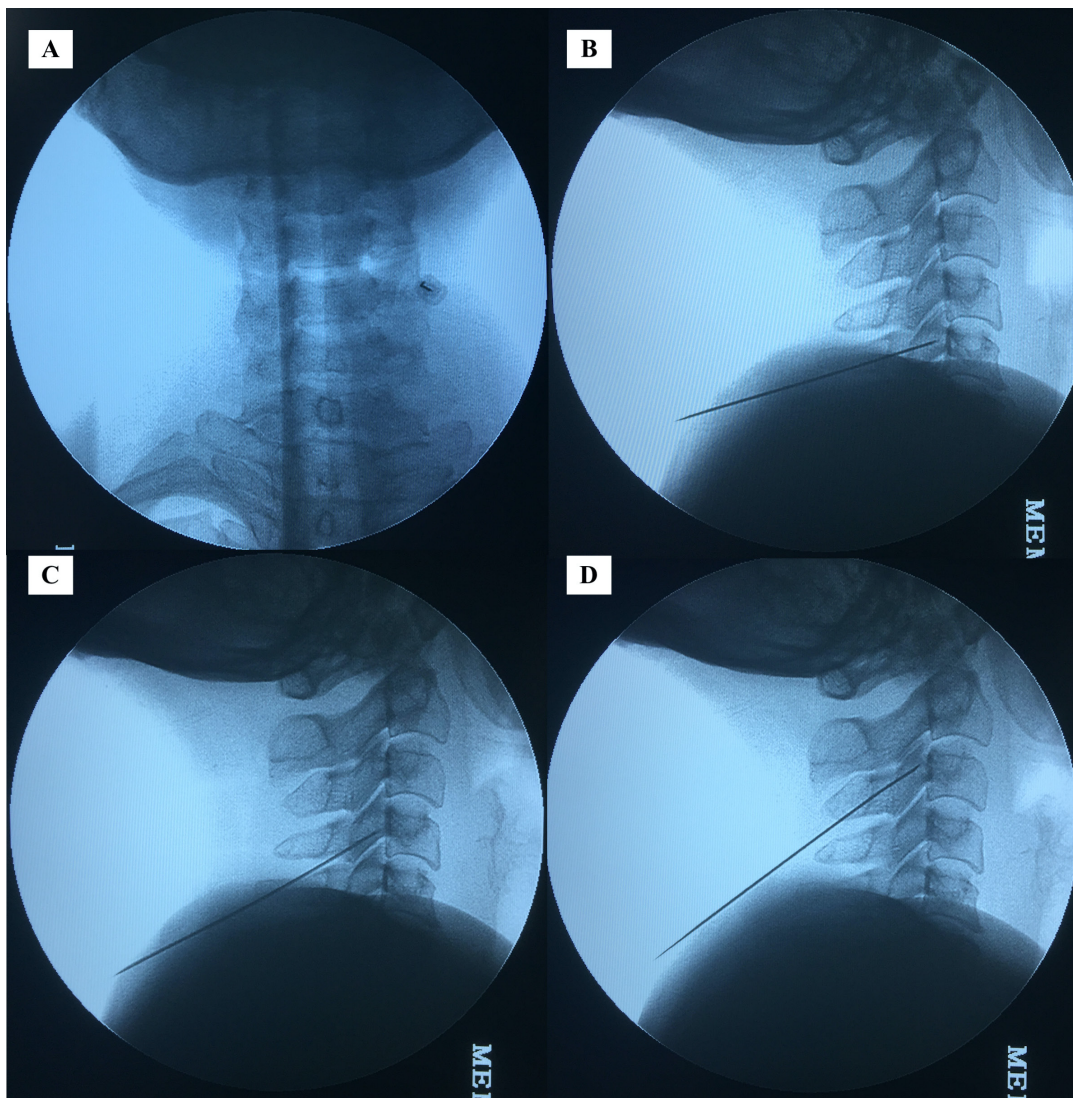


Figure 3. The single entry posterior parasagittal radiofrequency (RF) neurotomy of cervical medial branch. (A) Anteroposterior fluoroscopic view with the RF cannula at the waist of C5 vertebral body. (B) Lateral fluoroscopic view with the RF cannula at the final position of C5 articular pillar. (C) Lateral fluoroscopic view with the RF cannula at the final position of C4 articular pillar. (D) Lateral fluoroscopic view with the RF cannula at the final position of C3 articular pillar.

perpendicular to the skin in a coaxial method until bone contact (lateral border of vertebral body/waist of facet column) was made under AP view (Figure 3A). The C-arm was rotated to the lateral position. The curve RF cannula was advanced farther strictly in the parasagittal plane under lateral view with the cannula sliding along the lateral aspect of the vertebral body. The final location of the needle tip was at the center of the facet column in the lateral view, as shown in Figure 3B.

Neurostimulation was carried out first with 50 Hz which reproduced the concordant pain, then followed with 2 Hz. The 2-Hz motor stimulation elicited contraction of the multifidus muscles at intensities below 0.5 V. Subsequently, 0.5 mL levobupivacaine 0.5% was injected through RF cannula. Using Cosman G4 RF generator (Cosman Medical, Inc., Burlington,

MA, USA), an RF thermal lesion was carried out at 80°C for 90 seconds.

For the RF neurotomy of the cervical medial branch immediately 1 segment cranially, the curve RF cannula was withdrawn slowly until the cannula was no longer firmly held by surrounding neck muscles. With lateral projection of fluoroscopy, the RF cannula was angulated slightly more cranially, aligned with the corresponding facet column. Again, strictly in the parasagittal plane, the RF cannula was advanced until the cannula tip was at the center of the facet column in lateral view, as shown in Figure 3C. Once satisfactory neurostimulation was achieved, RF thermal lesion was carried out at a similar setting as above.

A similar method in terms of cannula withdrawal and advancement without making another skin entry was applied as described previously prior to RF neurotomy of another segment cervical medial branch cranially, with the final cannula tip position as shown in Figure 3D. Patients were discharged home with oral celecoxib 400 mg daily, pantoprazole 40 mg daily, and paracetamol 1 g 3 times daily for 5 days to relieve post-procedural needle soreness.

The primary outcome measure was to compare the analgesic efficacy of both approaches of RF neurotomy of the cervical medial branch using the numerical rating scale (NRS) (which measures pain from no pain to worst possible pain on a 0–10 scale). The NRS score was recorded during clinic visits prior to treatment (baseline) and at the third month after treatment. Telephone calls were made during data collection to obtain the NRS at 12 months after treatment. Secondary outcomes compared the duration and complications between the 2 approaches of RF neurotomy.

Data were analyzed using SPSS software (version 25.0. Chicago, IL, USA) in which a *P* value of less than 0.05 was considered significant. Descriptive statistics of the data were presented as a mean and standard deviation. The distribution of categorical variables in each group was compared with Pearson χ^2 test. Continuous variables were compared with analysis of variance. Differences in NRS during subsequent follow-up visits with baseline measurements were measured with a paired *t* test. The between-group differences were determined with independent *t* test or Mann-Whitney test where appropriate.

RESULTS

Between January 2016 and December 2019, 276 patients were treated with RF neurotomy of cervical medial branch. Most of the patients were treated by combination treatment of RF neurotomy with other pain interventions, and we had a number of patients lost to follow-up (Figure 4). Consequently, the findings presented in this study were derived from complete data of 71 patients: 31 patients with the posterolateral approach and 40 patients with the posterior parasagittal approach.

Patients in these 2 groups were comparable in terms of age, gender, weight, height, body mass index, and duration of neck pain, as shown in Table 1. There were no significant differences between groups for the levels of medial branch treated. The duration of the procedure was significantly shorter in the posterior parasagittal group than in the posterolateral group (44.13 \pm 4.72 minutes vs 54.68 \pm 7.39 minutes; *P* < 0.001). As far

as complications were concerned, neuritis, numbness, pruritus, and dysesthesia were reported in both groups. However, there were no significant differences between groups (Table 2).

For pain reduction efficacy as shown in Table 3, the NRS for both groups decreased significantly at 3 and 12 months as compared to the baseline NRS. For the posterolateral approach, the NRS change at 3 and 12 months was 4.87 (*P* < 0.001) and 3.04 (*P* < 0.05), respectively. For the posterior parasagittal group, the NRS changes at 3 and 12 months were 4.66 (*P* < 0.001) and 2.88 (*P* < 0.05), respectively. There were no significant differences between groups in terms of pain-lowering effect at 3 and 12 months after RF neurotomy.

DISCUSSION

RF neurotomy of cervical medial branch for the treatment of cervical facet joint pain usually involves multiple level medial branch denervation, as cervical facet joint pain frequently involves 2 or more facet joints and each facet joint has multisegmental innervation.^{13,14} C3 to C6 vertebrae possess uniform morphology and are therefore known as typical cervical vertebrae. They are of similar width when viewed on fluoroscopic AP view. This allows targeting multiple medial branch nerves, which wrap around the waist of the articular pillars along the same parasagittal plane with a single needle entry as in the case for posterior parasagittal approach technique as described in this study. RF neurotomy of C7 medial branch was also included in this study as the pathway of this nerve is along the superior articular process, which has a similar width as the typical cervical spine.^{15,16}

The technique used in this study is a modification of the posterior technique described by Lord et al in 1996. The original technique consisted of 2 skin entries: 1 through the posterior parasagittal approach and another entry at a 30° angle to the sagittal plane. At least 2 neurotomy lesions were made for each segment of nerves. As a result, the duration of treatment for each patient in that study was approximately 3 hours.⁹ This approach is possibly the most time consuming among all of the approaches, but in view of its more efficacious outcome, it remains the preferred approach in the current available literature.^{5,17–19} The first cannula entry (the posterior parasagittal approach) was carried out in coaxial view. However, for the second skin entry, when the cannula entered at 30° to the sagittal plane, coaxial view was no longer applied.

The technique of needle entry at 30° to the sagittal plane is similar to the posterolateral approach, which

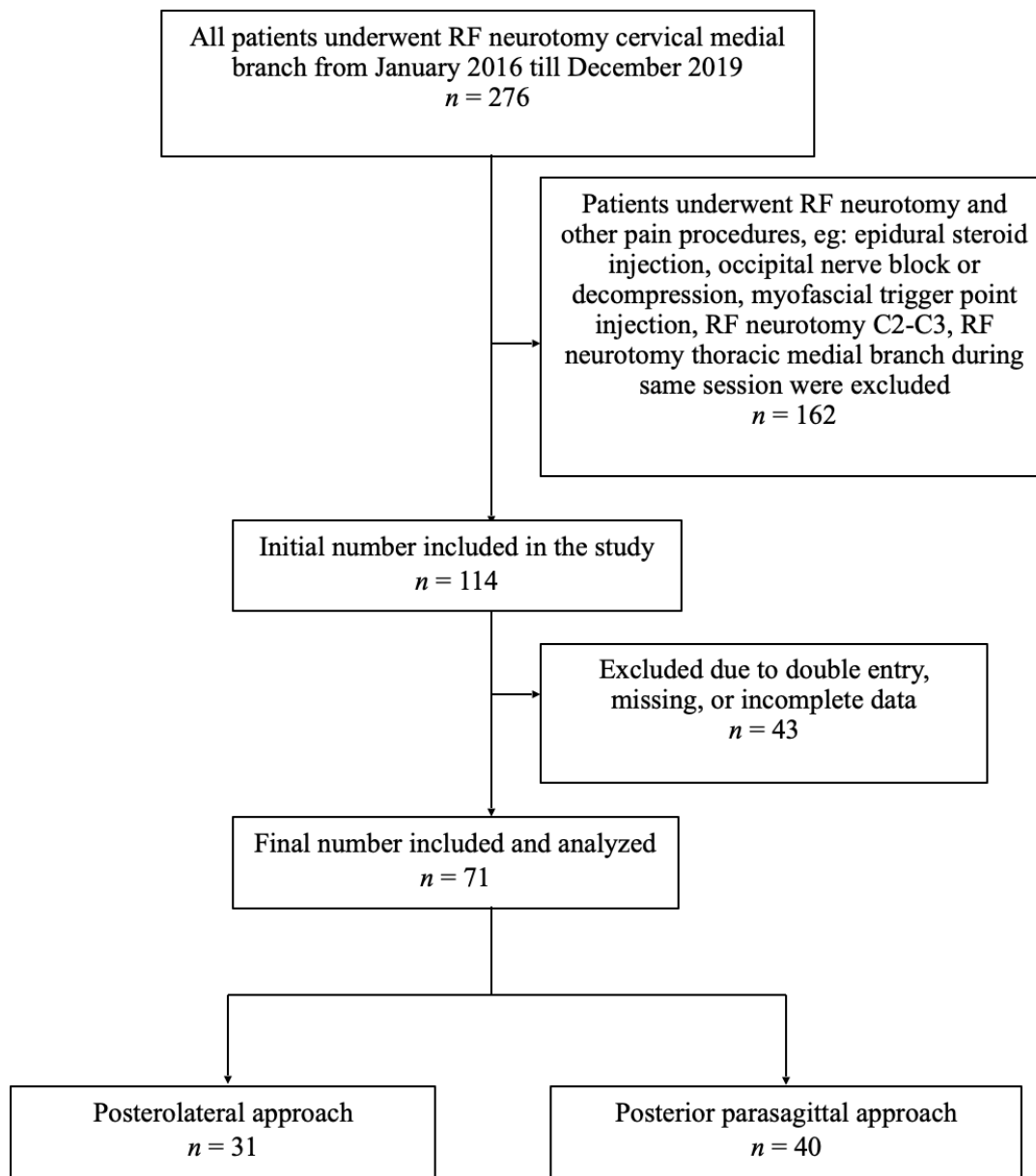


Figure 4. Flow diagram for patient inclusion. RF, radiofrequency.

Table 1. Baseline demographic characteristics of patients.

| Variables | Posterolateral Approach (n = 31) | Posterior Parasagittal Approach (n = 40) | P Value |
|------------------------------------|----------------------------------|--|---------|
| Age, y | 47.35 ± 10.11 | 47.50 ± 7.53 | 0.947 |
| Gender, Female | 19 (61) | 22 (55) | 0.595 |
| Weight, kg | 66.35 ± 10.71 | 68.83 ± 12.43 | 0.381 |
| Height, cm | 161.52 ± 9.88 | 162.95 ± 9.91 | 0.547 |
| Body mass index, kg/m ² | 25.39 ± 3.12 | 25.78 ± 3.02 | 0.595 |
| Duration of pain, mo | 16.55 ± 5.48 | 15.38 ± 5.41 | 0.370 |

Note: Qualitative data were expressed as number (%), and qualitative variables were expressed as the mean ± standard deviation.

was described by Sluiter in 1980. It was not carried out in the coaxial method. An estimation of the skin entry point, which was posterior and inferior to the target point, was made on an oblique or lateral fluoroscopic view.⁶ Estimation of the skin entry and needle advancement in a noncoaxial manner could be difficult sometimes. The needle might need to be withdrawn, and needle entry angulation might need to be adjusted more frequently compared to a more straightforward coaxial (tunnel view) method. The target point, which is the final needle placement, will be at the anterolateral side of the facet column, just posterior to the neural

Table 2. Clinical presentation of patients.

| Variables | Posterolateral Approach (n = 31) | Posterior Parasagittal Approach (n = 40) | P Value |
|--------------------------------|----------------------------------|--|--------------------|
| Level of medial branch treated | | | 0.360 |
| C3-5 | 0 (0.0) | 2 (5.0) | |
| C4-6 | 18 (58.1) | 19 (47.5) | |
| C5-7 | 13 (41.9) | 19 (47.5) | |
| Duration of procedure, min | 54.68 ± 7.39 | 44.13 ± 4.72 | 0.000 ^a |
| Complications ^b | | | |
| Neuritis | 4 (12.9) | 3 (7.5) | 0.449 |
| Numbness | 14 (45.2) | 12 (30.0) | 0.188 |
| Pruritus | 11 (35.5) | 16 (40.0) | 0.697 |
| Dysesthesia | 14 (45.2) | 21 (52.5) | 0.540 |

Note: Qualitative data were expressed as number (%), and qualitative variables were expressed as the mean ± SD.

^aSignificant different between 2 groups where $P < 0.05$.

^bSome patients presented with more than one complication.

foramen. This approach runs the risk of traumatizing the cervical spinal nerves and their ventral rami, as well as puncturing the vertebral artery when the needle is accidentally advanced too anteriorly.

Although the lateral approach is done with the coaxial method, this technique is not the preferred approach for RF neurotomy of the cervical medial branch. The needle tip which is perpendicular to the medial branch may not generate adequate RF lesioning as compared to other approaches where the needle trajectory is along the nerve pathway.^{10,11} This approach is more suitable for cervical medial branch block, where adequate neural blockade is dependent on the volume dispersion of local anesthetic.

In this study, we omitted a second needle entry, which is made 30° from the parasagittal plane due to safety concerns of a noncoaxial needle entry method. Besides that, similar to other studies, we believe that a single RF lesion for a medial branch might be adequate.^{7,20,21} Extra RF lesion for the same medial branch was unnecessary and might lead to potentially serious complications, such as cervical paraspinous muscle weakness, especially in the case of multiple levels or bilateral denervation of medial branches.^{22,23} The complications reported in this study are comparable with previous studies.¹⁹ No serious complications were noted with

Table 3. Mean pain scores of patients at different time points.

| Time Point | Posterolateral Approach (n = 31) | Posterior Parasagittal Approach (n = 40) | P Value |
|--------------|----------------------------------|--|---------|
| Baseline NRS | 7.52 ± 1.21 | 7.43 ± 1.03 | 0.738 |
| NRS at 3 mo | 2.65 ^a ± 1.08 | 2.77 ^a ± 1.10 | 0.620 |
| NRS at 12 mo | 4.48 ^b ± 1.41 | 4.55 ^b ± 1.15 | 0.833 |

Note: Data expressed as the mean ± SD.

^aSignificant different with baseline value where $P < 0.001$.

^bSignificant different with baseline value where $P < 0.05$.

Abbreviation: NRS, numerical rating scale.

both approaches, and all of the procedure-related complications were transient and resolved within 6 weeks.

Radiation exposure of both the physician and patient needs to be considered and minimized in the performance of interventional procedures utilizing fluoroscopy, particularly that for the cervical spine region.²⁴ The area in the cervical region is smaller in scale and contains many vital structures as compared to the lumbar region. Procedures done in this region require multiple small adjustments of cannula and frequent confirmation with fluoroscopy.²⁵ The need to rotate the C-arm interchangeably to produce AP and lateral views is very much reduced with the current parasagittal approach. As the current study was not intentionally designed as a prospective study, the extent of radiation exposure was not measured by dosimetry. The duration of the procedure which was recorded retrospectively might indirectly reflect the amount of radiation exposure of the physician and the patient during RF neurotomy. The significantly shorter duration imposed by the posterior parasagittal approach might imply shorter radiation exposure time compared to the posterolateral approach, thus favoring the former as far as radiation exposure is concerned.

In contradistinction to the lumbar spine, the smaller anatomy of the cervical spine allows targeting of multiple levels with a single needle entry. However, this technique might not be appropriate and safe in patients who are obese, who have a large body habitus, or who have bull necks because thick connective tissues and muscle layers do decrease the maneuverability of the cannula when targeting levels distant to the skin entry level. This technique is also not recommended if more than 3 segments need to be targeted for the same reason. Making another new skin entry is usually required to overcome this obstacle.

We suggest performing this technique at the cranial end rather than at the side of the patients to allow the visual advantage of ensuring parasagittal placement of the cannula. A curve RF cannula is needed to increase maneuverability during needle advancement to reach different segments of the cervical spine. During the advancement of the cannula in the lateral fluoroscopic view, if the cannula encounters bone resistance before reaching a satisfactory final needle position, the cannula can be rotated laterally in order to be advanced further. However, if the cannula encounters no resistance while the lateral fluoroscopic view demonstrates overlapping of the cannula with the articular pillar, the cannula should be withdrawn 1 to 2 mm and rotated medially to ensure constant bone contact. When the curve RF

cannula is rotated medially during final needle positioning prior to RF neurotomy, the cannula contact with the medial branch would be maximal, as the cannula is actually “hugging” a large portion of the articular pillar with the trajectory of the needle tip along the axis of the medial branch.

The limitation of this study is that it is retrospective in design; therefore, it has all the flaws and problems associated with such studies. Only 71 of 276 patients recruited were available for analysis, and this may result in a selection bias. Besides radiation exposure, other relevant information such as functional status and changes in postprocedural oral analgesic intake can be included in future studies. Despite being a retrospective study, reporting such a case series is hoped to provide an insight into the feasibility of various innovations and modifications of any pre-existing established technique.

CONCLUSIONS

Our analysis shows that single entry posterior parasagittal RF neurotomy of cervical medial branch is a safe and effective technique for cervical facet joint pain. The promising results from this study need to be validated with randomized prospective studies to confirm the feasibility and benefits of this modification of technique.

ACKNOWLEDGMENTS

The authors would like to thank Dr. Goh Kiang Hua, MBBS, FRCS, and Dr. Chang Li Kuin, MD, MRCSEd (Surgery), for critical review and editing support of this manuscript.

REFERENCES

1. Lord SM, Barnsley L, Wallis BJ, Bogduk N. Chronic cervical zygapophysial joint pain after whiplash. A placebo-controlled prevalence study. *Spine*. 1996;21(15):1737–1744. doi:10.1097/00007632-199608010-00005.
2. Manchikanti L, Singh V, Rivera J, Pampati V. Prevalence of cervical facet joint pain in chronic neck pain. *Pain Physician*. 2002;5(3):243–249. doi:10.36076/ppj.2002/5/243.
3. Manchukonda R, Manchikanti KN, Cash KA, Pampati V, Manchikanti L. Facet joint pain in chronic spinal pain: an evaluation of prevalence and false-positive rate of diagnostic blocks. *J Spinal Disord Tech*. 2007;20(7):539–545. doi:10.1097/BSD.0b013e3180577812.
4. McDonald GJ, Lord SM, Bogduk N. Long-term follow-up of patients treated with cervical radiofrequency neurotomy for chronic neck pain. *Neurosurgery*. 1999;45(1):61–67. doi:10.1097/00006123-199907000-00015.

5. Barnsley L. Percutaneous radiofrequency neurotomy for chronic neck pain: outcomes in a series of consecutive patients. *Pain Med*. 2005;6(4):282–286. doi:10.1111/j.1526-4637.2005.00047.x.
6. Sluifster ME, Koetsveld-Baart CC. Interruption of pain pathways in the treatment of the cervical syndrome. *Anaesthesia*. 1980;35(3):302–307. doi:10.1111/j.1365-2044.1980.tb05102.x.
7. van Eerd M, de Meij N, Dortangs E, et al. Long-term follow-up of cervical facet medial branch radiofrequency treatment with the single posterior-lateral approach: an exploratory study. *Pain Pract*. 2014;14(1):8–15. doi:10.1111/papr.12043.
8. van Eerd M, Lataster A, Sommer M, Patijn J, van Kleef M. A modified posterolateral approach for radiofrequency denervation of the medial branch of the cervical segmental nerve in cervical facet joint pain based on anatomical considerations. *Pain Pract*. 2017;17(5):596–603. doi:10.1111/papr.12499.
9. Lord SM, Barnsley L, Wallis BJ, McDonald GJ, Bogduk N. Percutaneous radio-frequency neurotomy for chronic cervical zygapophysial joint pain. *N Engl J Med*. 1996;335(23):1721–1726. doi:10.1056/NEJM199612053352302.
10. Bogduk N, Lord SM. Cervical zygapophysial joint pain. *Neurosurg Q*. 1998;8(2):107–117. doi:10.1097/00013414-199806000-00004.
11. Vallejo R. Cervical facet radiofrequency. *Tech Reg Anesth Pain Manag*. 2005;9(2):81–85. doi:10.1053/j.trap.2005.05.006.
12. Bogduk N. Cervical medial branch blocks. In: Bogduk N, ed. *Practice Guidelines for Spinal Diagnostic and Treatment Procedures*. 2nd ed. San Francisco (CA): International Spine Intervention Society; 2013:85–114.
13. Groen GJ, Baljet B, Drukker J. The innervation of the spinal dura mater: anatomy and clinical implications. *Acta Neurochir*. 1988;92(1–4):39–46. doi:10.1007/BF01401971.
14. Stolker RJ, Vervest ACM, Groen GJ. The management of chronic spinal pain by blockades: a review. *Pain*. 1994;58(1):1–20. doi:10.1016/0304-3959(94)90180-5.
15. Tan SH, Teo EC, Chua HC. Quantitative three-dimensional anatomy of cervical, thoracic and lumbar vertebrae of Chinese Singaporeans. *Eur Spine J*. 2004;13(2):137–146. doi:10.1007/s00586-003-0586-z.
16. Wysocki J, Bubrowski M, Reymond J, Kwiatkowski J. Anatomical variants of the cervical vertebrae and the first thoracic vertebra in man. *Folia Morphol*. 2003;62(4):357–363.
17. MacVicar J, Borowczyk JM, MacVicar AM, Loughnan BM, Bogduk N. Cervical medial branch radiofrequency neurotomy in New Zealand. *Pain Med*. 2012;13(5):647–654. doi:10.1111/j.1526-4637.2012.01351.x.
18. Klessinger S. Radiofrequency neurotomy for the treatment of therapy-resistant neck pain after ventral cervical operations. *Pain Med*. 2010;11(10):1504–1510. doi:10.1111/j.1526-4637.2010.00942.x.
19. Engel A, Rappard G, King W, Kennedy DJ, Standards Division of the International Spine Intervention Society. The effectiveness and risks of fluoroscopically-guided cervical medial branch thermal radiofrequency neurotomy: a systematic review with comprehensive analysis of the published data. *Pain Med*. 2016;17(4):658–669. doi:10.1111/pme.12928.
20. Cohen SP, Bajwa ZH, Kraemer JJ, et al. Factors predicting success and failure for cervical facet radiofrequency denervation: a multi-center analysis. *Reg Anesth Pain Med*. 2007;32(6):495–503. doi:10.1016/j.rapm.2007.05.009.
21. Park SW, Park YS, Nam TK, Cho T. G. The effect of radiofrequency neurotomy of lower cervical medial

branches on cervicogenic headache. *J Korean Neurosurg Soc.* 2011;50(6):507–511. doi:10.3340/jkns.2011.50.6.507.

22. Ahmed MM, Lake WB, Resnick DK. Progressive severe kyphosis as a complication of multilevel cervical percutaneous facet neurotomy: a case report. *Spine J.* 2012;12(10):e5-8. doi:10.1016/j.spinee.2012.09.037.

23. Stoker GE, Buchowski JM, Kelly MP. Dropped head syndrome after multilevel cervical radiofrequency ablation: a case report. *J Spinal Disord Tech.* 2013;26(8):444–448. doi:10.1097/BSD.0b013e31825c36c0.

24. Zhou YL, Singh N, Abdi S, JH W, Crawford J, Furgang FA. Fluoroscopy radiation safety for spine interventional pain procedures in university teaching hospitals. *Pain Phys.* 2006;1;8(1;1):49–53. doi:10.36076/ppj.2006/9/49.

25. Giordano BD, Baumhauer JF, Morgan TL, Rehtine GR. Cervical spine imaging using standard C-arm fluoroscopy. *Spine.* 2008;33(18):1970–1976. doi:10.1097/BRS.0b013e31817e69b7.

Funding: The authors received no financial support for the research, authorship, and/or publication of this article.

Declaration of Conflicting Interests: The authors report no conflicts of interest with respect to the research, authorship, and/or publication of this article.

Corresponding Author: Chee Kean Chen, Department of Anaesthesiology and Intensive Care, KPJ Kuching Specialist Hospital, Lot 10420, Block 11, Tabuan Stutong Commercial Centre, Jalan Setia Raja, 93350 Kuching, Sarawak, Malaysia; chenck@hotmail.my

Published 20 January 2022

This manuscript is generously published free of charge by ISASS, the International Society for the Advancement of Spine Surgery. Copyright © 2021 ISASS. To see more or order reprints or permissions, see <http://ijssurgery.com>.