

The Role of Instrumentation in the Surgical Treatment of Spondylodiscitis and Spinal Epidural Abscess: A Single-Center Retrospective Cohort Study

Jonathan J. Lee, Saeed S. Sadrameli, Suraj Sulhan, Virendra R. Desai, Marcus Wong and Sean M. Barber

Int J Spine Surg 2022, 16 (1) 61-70
doi: <https://doi.org/10.14444/8178>
<https://www.ijssurgery.com/content/16/1/61>

This information is current as of May 17, 2025.

Email Alerts Receive free email-alerts when new articles cite this article. Sign up at:
<http://ijssurgery.com/alerts>

The Role of Instrumentation in the Surgical Treatment of Spondylodiscitis and Spinal Epidural Abscess: A Single-Center Retrospective Cohort Study

JONATHAN J. LEE, MD¹; SAEED S. SADRAMELI, MD¹; SURAJ SULHAN, MD¹; VIRENDRA R. DESAI, MD²;
MARCUS WONG, MD¹; AND SEAN M. BARBER, MD¹

¹Department of Neurosurgery, Houston Methodist Neurological Institute, Houston, TX, USA; ²Department of Neurosurgery, University of Oklahoma School of Medicine, Oklahoma City, OK, USA

ABSTRACT

Background: Despite the high incidence of spinal infections that require an operation, there is no consensus on the most appropriate initial surgical management for these patients regarding decompression with vs without instrumented fusion. In this study, we investigated the differences in clinical outcomes, complication rates, and reoperation rates between patients with spinal epidural abscess who underwent decompression alone vs decompression with instrumented fusion.

Methods: Records of patients undergoing operative intervention for spondylodiscitis with spinal epidural abscess at the authors' institution between 2011 and 2018 were reviewed. Two cohorts were observed: patients who underwent decompression alone and patients who underwent decompression with instrumented fusion as the initial operation. Patient demographics and primary outcomes were analyzed and compared.

Results: Medical records of 74 patients with spinal infection were reviewed, and 47 patients met the inclusion criteria. There were 27 (57.4%) patients who underwent decompression alone and 20 (42.6%) patients who underwent decompression and fusion. There were no significant differences in the comorbidities, level, and/or extent of infectious involvement between the decompression alone cohort and the decompression with fusion cohort. Although no significant differences were seen between groups with regard to complication rates and neurological outcomes, the reoperation rate was significantly higher in the patients who underwent decompression alone (51.9% vs 10%, $P = 0.004$).

Conclusions: Decompression with instrumented fusion delivers neurological outcomes and complication rates similar to those seen with decompression alone in patients with spondylodiscitis. However, there was a significantly higher reoperation rate in the decompression only cohort compared to the decompression and fusion cohort.

Level of Evidence: 3.

Lumbar Spine

Keywords: spondylodiscitis, spinal infection, osteomyelitis, discitis, decompression, instrumented fusion, reoperation

INTRODUCTION

Spondylodiscitis is an uncommon infection of the intervertebral disc with osteomyelitis of the adjacent vertebral body endplates and represents 0.15%–5% of all osteomyelitis cases.^{1,2} Its incidence has been reported to be between 0.2 and 2.4/100,000 annually, with a broad consensus indicating that cases are on the rise.^{2,3} Risk factors for spondylodiscitis include underlying compromise of the immune system, such as human immunodeficiency virus/acquired immunodeficiency syndrome, end-stage renal disease, diabetes mellitus, hepatic cirrhosis, and malignancy.⁴ Typical clinical manifestations include back pain, fever, malaise, and variable compressive neurological symptoms; however, severe cases can escalate to epidural abscesses, septicemia, and general multiorgan failure.^{5,6}

In one large study, spondylodiscitis was seen more commonly in the lumbosacral spine (48%), followed by the thoracic (38%), cervical (8%), and thoracolumbar (6%) region.⁵ Infections can access the spine either through hematogenous or nonhematogenous routes, the latter including contiguous spread from an active infectious site or direct inoculation from spinal procedures or trauma.^{1,4} Hematogenous spread is the more common route, likely secondary to the vascular anatomy of the spine.^{7,8} Typically, a single vascular pedicle will bifurcate and supply 2 adjacent vertebral endplates, which become infected first and propagate to the disc and body nearby.^{4,9} The lack of valves and slower blood flow in the venous spinal vasculature are thought to predispose one to the seeding of infection.^{4,9}

While there are several reported causative organisms for spondylodiscitis, the most common organism

is *Staphylococcus aureus*, followed by *Streptococcus viridans*, *Escherichia coli*, and *Staphylococcus epidermidis*.^{3,5} Most cases are caused by a single microorganism, with polymicrobial infections representing <10% of cases.⁴

The treatment of spondylodiscitis varies from conservative medical management to surgical decompression with or without instrumented fusion, depending on a multitude of factors. Conservative medical management typically involves isolation of an organism via culture or percutaneous biopsy, appropriate antibiotic treatment, and external bracing for pain control.¹⁰ For those patients who have rapidly worsening neurological deficits, disease refractory to maximum medical management, or severe compressive spinal epidural abscess (SEA), surgical treatment strategies should be considered.¹¹ This commonly involves decompression and drainage of any associated SEA, debridement of infected tissue, and antibiotic irrigation, with or without stabilization.^{5,10,12-14}

While decompression of the neural elements is often the primary goal of surgical intervention for SEA, the degree of bony and ligamentous destruction related to the infectious process has, at times, led surgeons to supplement the decompression with spinal stabilization out of concern for underlying instability.^{11,13,15-17} Little consensus currently exists regarding the use of instrumentation in patients without overt instability undergoing decompression for SEA, and reports of differences in complication rates and reoperation rates between those undergoing decompression alone and those undergoing decompression and fusion are variable.^{10-14,18,19}

We retrospectively reviewed the cases of 47 patients with spondylodiscitis with SEA who underwent decompression alone or decompression with fusion as the initial operation at our institution with the goal to better understand the advantages and limitations of each technique in the treatment of SEA. Although there are instances when the decision to instrument or not is self-evident (eg, profound kyphotic deformity), we sought to better investigate the criteria that would increase the likelihood of consequent spinal deformity and the need for reoperation in patients with SEA using an analysis of patients who underwent both surgical techniques.

METHODS

Inclusion/Exclusion Criteria

Records of patients undergoing operative intervention for spondylodiscitis at the authors' institution between 2011 and 2018 were reviewed. Patients who

underwent neurosurgical intervention for an SEA were selected. Patients who were lost to follow-up (less than 6 months of clinical or radiographic follow-up) or who had incomplete written medical records were excluded. Patients who developed spondylodiscitis or SEA as a result of a recent spinal operation or procedure (ie, post-operative discitis or SEA) were excluded.

Data Collection and Statistical Analysis

Patients were divided into 2 groups: those who initially underwent decompression alone and those who initially underwent decompression with fusion. The choice of operative procedure for each patient was determined by the neurosurgeon treating the patient at the time. Operative notes, imaging studies, and other clinical records were reviewed. Patient demographics, including mean age, sex, source of infection, comorbidities, presenting symptoms, spinal levels of involvement, length of stay, and 30-day readmission were studied. Primary outcome measures were reoperation rate, complication rate, and clinical outcomes. Patients for whom reoperation was recommended by the treating surgeon but not undertaken due to patient preference or medical condition were not included in the analysis as having undergone reoperation.

Frequency distributions and summary statistics were calculated for all clinical and radiographic variables. Fisher exact tests were used to compare distributions for categorical variables, and *t* tests were used to investigate differences in the distributions of continuous variables between subsets of patients classified by dichotomous data. A *P* value of ≤ 0.05 was considered significant.

RESULTS

Patient Demographics and Clinical Presentations

A total of 74 patients with spinal infections were reviewed, and 47 patients met the inclusion/exclusion criteria. Twenty-seven (57.4%) patients underwent decompression alone, and 20 (42.6%) patients underwent decompression and fusion as the index operation. All decompression alone procedures were performed from a posterior approach (ie, laminectomy). Of the patients undergoing decompression and fusion, 7 patients (35%) underwent a posterior decompression and fusion (eg, laminectomy with fusion), 2 (10%) underwent an anterior decompression and fusion (eg, anterior cervical discectomy or corpectomy and fusion), and 11 (55%) underwent circumferential decompression and fusion. The average age of patients undergoing decompression alone and decompression with fusion was 60.3 and 58.5 years, respectively

($P = 0.52$). The majority of the patients were men ($N = 32$, 68.1%). The source of infection was unknown in the majority of cases (51.1%) while the known sources of infection included skin/subcutaneous tissue (21.3%), pneumonia (6.4%), and septic arthritis (6.4%) with no significant differences between the 2 cohorts. The most common bacterial pathogens isolated (either via needle biopsy or open biopsy) were methicillin-sensitive *S aureus* ($n = 16$, 34%), methicillin-resistant *S aureus* ($n = 9$, 19.1%), and group B streptococcus ($n = 4$, 8.5%). In 6 patients (12.8%), no bacterial pathogen was ever isolated, and in 1 patient, a polymicrobial infection was isolated (*Enterococcus faecalis* + *Escherichia coli*). There was no significant difference between cohorts with regard to patient age, sex, comorbidities, pathogen isolated, or duration of postoperative antibiotic therapy. Patient demographics and clinical presentations are summarized in Table 1.

Reoperations

The reoperation rate was significantly higher in patients who underwent decompression alone (51.9% vs 10%, $P = 0.004$) (Figure 1). In patients who underwent decompression plus fusion, both reoperations were due to hardware failure ($n = 2$), and in 1 of these 2 cases, deep wound infection was also present. Reoperations in the decompression alone group were undertaken due to axial pain ($n = 11$, 78.6%), progressive deformity ($n = 7$, 50%), recurrence of deep infection ([discitis/SEA], $n = 3$, 21.4%), neurological decline ($n = 3$, 21.4%), or some combination of the above. Goals of the first reoperation in patients who underwent decompression alone initially included: further decompression ($n = 7$, 50%), instrumentation and fusion ($n = 11$, 78.6%), or a combination of the 2.

We describe here in detail an example of a case in which a reoperation was indicated. A 58-year-old man with a history of diabetes mellitus type 1, hypertension, and a diabetic foot ulcer presented to the hospital with upper thoracic pain and upper respiratory symptoms. He was found to have pneumonia at the time and was treated with intravenous antibiotics, later to be discharged from the hospital. After several weeks of persistent back pain, imaging of the thoracic spine showed discitis-osteomyelitis at T4-5 with epidural extension and cord compression (Figure 2). The patient underwent a left T4-5 hemilaminectomy with evacuation of an epidural abscess the day after admission (Figure 2). Intraoperative cultures resulted in *S aureus*, and the patient was treated with 6 weeks of nafcillin. The patient recovered well over the next 4 weeks; however, the patient presented again to the emergency room with 2 weeks of persistent mechanical, thoracic back pain, especially

with axial loading. The patient remained compliant on his antibiotics. Given the mechanical nature of his extreme pain, the decision was made to pursue a redo laminectomy at T4-5 and to support the decompression with instrumentation from T2-7 (Figure 2). The patient did well after surgery with resolution of his back pain. Subsequent imaging of the spine showed resolution of his infection.

Reoperation was recommended in an additional 2 patients who underwent decompression alone, but they either refused or were not medically fit. The first of these 2 patients was a 58-year-old man with a medical history that included atrial fibrillation, coronary artery disease, aortic stenosis, diastolic heart failure, and hypertension who presented with severe refractory low back pain and was found to have L4-5 spondylodiscitis with epidural abscess formation and L4-S1 severe stenosis with resultant neurogenic claudication. The patient underwent an L4-S1 laminectomy for decompression. After many weeks of intravenous antibiotics, the patient presented with recurrent lower back pain without new neurologic deficits. Further imaging revealed persistent L4-5 discitis-osteomyelitis and epidural phlegmon without significant spinal cord compression. An L4-5 corpectomy and a multilevel lumbar instrumented fusion were recommended. After extensive discussions with various specialty teams, the patient's comorbidities, including a need for an urgent cardiac valve replacement, prohibited a reoperation at the time and the patient was treated with aggressive antibiotics. At latest clinical follow-up (6 months), the patient remained neurologically stable with persistent axial back pain.

The second patient was a 71-year-old man with a past medical history of chronic obstructive pulmonary disease, congestive heart failure, hypertension, obstructive sleep apnea, abdominal aortic aneurysm, foot ulcers, and diabetes mellitus who presented with 1 month of lower back pain. The patient was found to have persistent bacteremia and T12-L1 osteomyelitis-discitis with an extensive ventral and dorsal epidural compression spanning from T2 to T10 on imaging suspected to be either an abscess or phlegmon. The patient underwent a right-sided T3-4 hemilaminotomy and partial medial facetectomy for exploration; neither liquid pus nor significant compressive phlegmon was encountered. The operation was terminated with plans to bring the patient back for a second stage of debridement and fusion with corpectomy of the osteomyelitis. The patient had a prolonged and difficult postoperative course with an extensive intensive care unit stay due to his poor medical health. The patient eventually had

Table 1. Patient demographics.

	Total (n = 47)	Decompression Alone (n = 27)	Decompression + Fusion (n = 20)	P Value
Mean age, y	59.5	60.3	58.5	0.52
Male, % (n)	68.1% (32)	81.5% (22)	50% (10)	0.03
Presumed source of infection, % (n)				
Urinary tract	4.3% (2)	7.4% (2)	0% (0)	0.50
Skin and subcutaneous tissues	21.3% (10)	25.9% (7)	15% (3)	0.48
Infected vascular access	2.1% (1)	3.7% (1)	0% (0)	1
Pneumonia	6.4% (3)	0% (0)	15% (3)	0.07
Septic joint	6.4% (3)	3.7% (1)	10% (2)	0.57
Postoperative infection	4.3% (2)	3.7% (1)	5% (1)	1
IVDU	4.3% (2)	0% (0)	10% (2)	0.18
Unknown	51.1% (24)	55.6% (15)	45% (9)	0.56
Underlying illness/conditions, % (n)				
Diabetes mellitus	42.6% (20)	44.4% (12)	40% (8)	1
Hypertension	68.1% (32)	70.4% (19)	65% (13)	0.76
Hyperlipidemia	8.5% (4)	11.1% (3)	5% (1)	0.63
Immunosuppression	4.3% (2)	7.4% (2)	0% (0)	0.50
ESRD/CKD	19.1% (9)	18.5% (5)	20% (4)	1
Coronary artery disease	21.3% (10)	29.6% (8)	10% (2)	0.15
Atrial fibrillation	14.9% (7)	14.8% (4)	15% (3)	1
Congestive heart failure	12.8% (6)	7.4% (2)	20% (4)	0.38
Liver disease	6.4% (3)	3.7% (1)	10% (2)	0.57
COPD	4.3% (2)	3.7% (1)	5% (1)	1
Peripheral vascular disease	6.4% (3)	7.4% (2)	5% (1)	1
Malignancy	8.5% (4)	3.7% (1)	15% (3)	0.30
IVDU	8.5% (4)	7.4% (2)	10% (2)	1
Hepatitis B/C	6.4% (3)	7.4% (2)	5% (1)	1
Obesity	6.4% (3)	7.4% (2)	5% (1)	1
Rheumatic disease	6.4% (3)	7.4% (2)	5% (1)	1
Clinical data, % (n)				
Back pain	68.1% (32)	81.5% (22)	50% (10)	0.03
Neck pain	17% (8)	0% (0)	40% (8)	0.0004
Radicular pain	17% (8)	22.2% (6)	10% (2)	0.44
Neurologic deficit	34% (16)	37% (10)	30% (6)	0.76
Involvement levels, % (n)				
≥3 Vertebral bodies	42.6% (20)	51.9% (14)	30% (6)	0.15
Epidural involvement	48.9% (23)	44.4% (12)	55% (11)	0.56
Cervical spine only	6.4% (3)	0% (0)	15% (3)	0.07
Thoracic spine only	31.9% (15)	29.6% (8)	35% (7)	0.76
Lumbar spine only	23.4% (11)	25.9% (7)	20% (4)	0.74
Cervicothoracic spine	10.6% (5)	3.7% (1)	20% (4)	0.15
Thoracolumbar spine	12.8% (6)	18.5% (5)	5% (1)	0.22
Lumbosacral spine	14.9% (7)	22.2% (6)	5% (1)	0.22
Bacterial pathogen isolated, % (n)				
MSSA	34% (16)	33.3% (9)	35% (7)	1
MRSA	19.1% (9)	18.5% (5)	20% (4)	1
Unknown	12.8% (6)	14.8% (4)	10% (2)	1
Group B streptococcus	8.5% (4)	11.1% (3)	5% (1)	0.63
<i>Mycobacterium avium</i>	6.4% (3)	7.4% (2)	5% (1)	1
Alpha streptococcus	4.6% (2)	3.7% (1)	5% (1)	1
<i>Enterococcus faecalis</i>	2.1% (1)	3.7% (1)	0% (0)	1
<i>Escherichia coli</i>	2.1% (1)	3.7% (1)	0% (0)	1
Coagulase-negative staphylococcus	2.1% (1)	3.7% (1)	0% (0)	1
<i>Staphylococcus lugdunensis</i>	2.1% (1)	3.7% (1)	0% (0)	1
<i>Propionibacterium acnes</i>	2.1% (1)	0% (0)	5% (1)	1
Enterobacter	2.1% (1)	0% (0)	5% (1)	1
Nocardia	2.1% (1)	0% (0)	5% (1)	1
<i>Klebsiella pneumoniae</i>	2.1% (1)	0% (0)	5% (1)	1
Mean length of intravenous antibiotic therapy, wk	6.7	6.7	6.7	1

Abbreviations: CKD, chronic kidney disease; COPD, chronic obstructive pulmonary disease; ESRD, end-stage renal disease; IVDU, intravenous drug use; MRSA, methicillin-resistant *Staphylococcus aureus*; MSSA, methicillin-sensitive *Staphylococcus aureus*.

a tracheostomy and percutaneous gastrostomy tube placed. The patient remained neurologically stable at last clinical follow-up (7 months) and, after many discussions with specialty teams, it was decided that

he would not be well enough to tolerate an additional fusion surgery.

A third operation was performed for 5 patients in the decompression alone group and a single patient in the

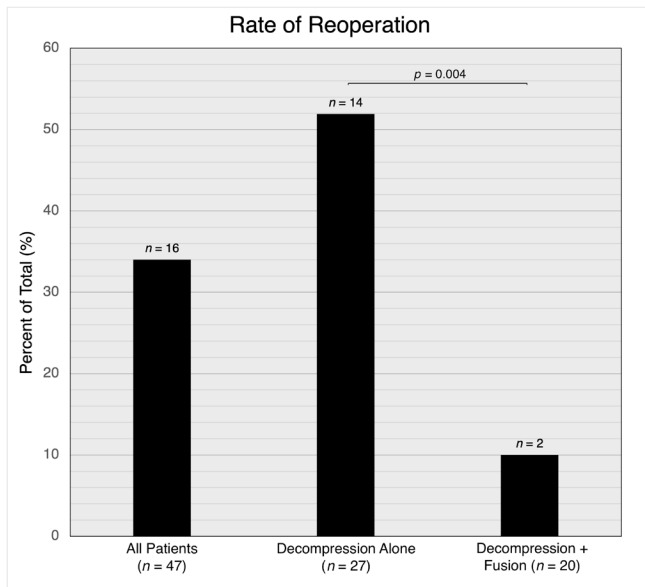


Figure 1. Bar graph illustrating the rate of reoperation among 47 patients undergoing surgical intervention for spondylodiscitis with spinal epidural abscess between 2011 and 2018. The reoperation rate was significantly higher in patients who underwent decompression alone as an index operation compared with those who underwent decompression and fusion (51.9% vs 10%, $P = 0.004$).

decompression and fusion group ($P = 0.22$). Indications for the third operation included axial pain ($n = 4$), recurrent deep infection ($n = 3$), progressive deformity ($n = 2$), pseudarthrosis ($n = 1$), and hardware failure ($n = 1$). Four of the 5 patients in the decompression alone group who required

a third operation underwent instrumentation and fusion at the time of the second operation (first reoperation). Details of the reoperations are summarized in Table 2.

There was a trend toward discitis at the level of laminectomy (seen as increased T2 signal within the disc space) being a predictor for reoperation for fusion/stabilization in patients undergoing decompression alone, but this did not reach statistical significance ($P = 0.1071$). Discitis at the level of laminectomy in patients undergoing laminectomy alone was, however, a predictor of reoperation for fusion/stabilization being recommended by the treating surgeon (ie, when the 2 patients for whom a reoperation was recommended by the treating surgeon—but not undertaken due to patient comorbidities/medical fitness—are included as having in fact undergone reoperation; $P = 0.018$). Further analysis showed no significant difference between overall reoperation rates ($P = 0.23$) and need for fusion/stabilization ($P = 0.42$) between patients receiving full laminectomy and hemilaminectomy/laminotomy in the decompression alone group.

Clinical Outcomes

There was no statistically significant difference in length of stay between decompression alone and decompression plus fusion cohorts (13.5 days vs 16.7 days, $P = 0.13$). The 30-day all-cause readmission rates following the index hospitalization were 7.4% and 25% in decompression

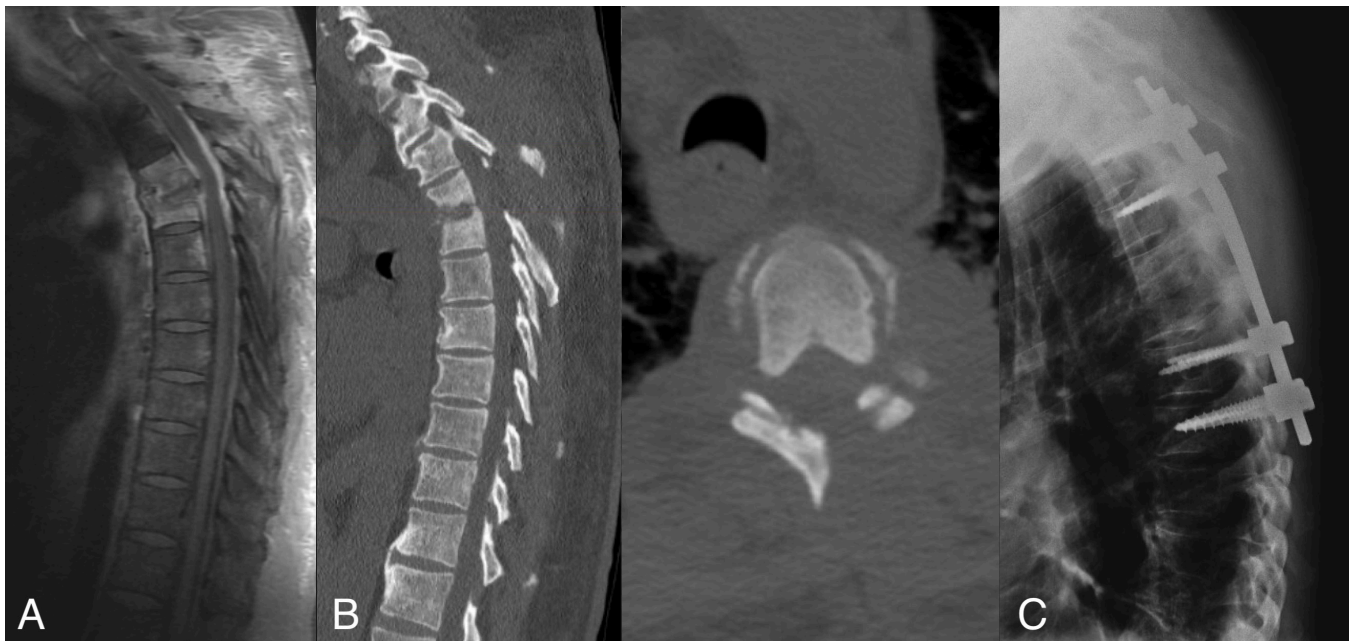


Figure 2. (A) Sagittal magnetic resonance imaging with contrast of the thoracic spine in a patient who presented with upper thoracic back pain showing discitis-osteomyelitis at T4-5. (B) Sagittal and axial postoperative computed tomography images showing a left-sided T4-5 hemilaminectomy, which was the initial surgical treatment for this patient. (C) Sagittal x-ray images showing the patient's reoperation, having undergone a T4-5 redo laminectomy and a T2-7 posterior fusion after the patient presented with persistent mechanical back pain, especially with axial loading.

Table 2. Radiographic follow-up and reoperation rates.

	Total Patients (n = 47)	Decompression Alone Cohort (n = 27)	Decompression + Fusion Cohort (n = 20)	P Value
Mean radiographic follow-up, mo	17.9	19.7	15.3	0.83
Reoperations, % (n)				
≥1 Reoperation	34.0% (16)	51.9% (14)	10% (2)	0.004
2 Reoperations	12.8% (6)	18.5% (5)	5% (1)	0.22
Indications for initial reoperation, % (n)				
Axial pain	27.7% (13)	78.6% (11)	10% (2)	0.025
Progressive deformity	14.9% (7)	50% (7)	0% (0)	0.015
Neurological decline	6.4% (3)	21.4% (3)	0% (0)	0.25
Recurrence of deep infection	8.5% (4)	21.4% (3)	5% (1)	0.63
Hardware failure	4.3% (2)	0% (0)	10% (2)	0.18
Goals of initial reoperation, % (n)				
Further decompression	6.4% (3)	7.4% (3)	0% (0)	0.25
Fusion	14.3% (7)	29.6% (7)	0% (0)	0.015
Further decompression + fusion	8.5% (4)	14.8% (4)	0% (0)	0.13
Debridement of recurrent infection	0% (0)	0% (0)	5% (1)	0.46
Revision of hardware	4.3% (2)	0% (0)	10% (2)	0.18
Indications for second reoperation, % (n)				
Axial pain	8.5% (4)	14.8% (4)	0% (0)	0.13
Progressive deformity	4.3% (2)	7.4% (2)	0% (0)	0.5
Recurrence of deep infection	6.4% (3)	7.4% (2)	5% (1)	1
Pseudarthrosis	2.1% (1)	3.7% (1)	0% (0)	1
Hardware failure	2.1% (1)	3.7% (1)	0% (0)	1
Goals of second reoperation, % (n)				
Further decompression	0% (0)	0% (0)	0% (0)	1
Fusion	6.4% (3)	11.1% (3)	0% (0)	0.25
Further decompression + fusion	0% (0)	0% (0)	0% (0)	1
Debridement of recurrent infection	6.4% (3)	7.4% (2)	5% (1)	1
Revision of hardware	0% (0)	0% (0)	0% (0)	1

and decompression plus fusion cohorts, respectively ($P = 0.12$). The baseline patient demographics are summarized in Table 1. The average length of radiographic follow-up in decompression alone and decompression plus fusion cohorts was 19.7 and 15.3 months, respectively ($P = 0.83$). The majority of all patients either had an improved (53.2%) or stable (36.2%) neurologic exam postoperatively. Among the decompression alone cohort, 59.3% (16) of patients exhibited an improved neurologic exam, compared to 45% (9) of patients in the decompression plus fusion cohort ($P = 0.39$). There were no significant differences in the percentage of patients who exhibited a stable ($P = 0.36$) or worse ($P = 1$) postoperative exam when comparing the decompression cohort and the decompression plus fusion cohort. Clinical outcomes are summarized in Table 3.

Among the 27 patients in the decompression alone cohort, most patients were discharged home (37%; 10), 18.5% (5) of patients were discharged to a skilled nursing facility, 22.2% (6) were discharged to rehabilitation, and 22.2% (6) were discharged to a long-term acute care facility. Among the 20 patients in the decompression plus fusion cohort, most patients were discharged to a skilled nursing facility (40%; 8), 35% (7) of patients were discharged home, 10% (2) of patients were discharged to

rehabilitation, and 15% (3) of patients were discharged to a long-term acute care. Discharge dispositions are summarized in Table 3.

Complications

There were a total of 12 adverse events, 5 of these in the decompression alone cohort and 7 in the decompression and fusion cohort. In the decompression alone cohort, there were 3 operative complications. In one patient who underwent an L4 to S1 hemilaminectomy for drainage of abscess, 2 durotomies were encountered during the exploration. The durotomies were unable to be repaired primarily; therefore, a dural substitute was used for closure and a lumbar drain was placed intraoperatively for wound healing. The drain was subsequently titrated and discontinued on postoperative day 12 with no evidence of cerebrospinal leak. The 2 remaining complications in the decompression alone cohort was a wound dehiscence requiring a washout and a superficial wound dehiscence that was treated and resolved conservatively.

In the decompression and fusion cohort, there were 3 operative complications. After a reoperation for revision of hardware, one patient experienced a deep wound infection that required a washout. Another patient had postoperative

Table 3. Clinical outcomes and complications.

	Total Patients (n = 47)	Decompression Alone Cohort (n = 27)	Decompression + Fusion Cohort (n = 20)	P Value
Clinical outcomes, % (n)				
Neurologic exam at latest follow-up				
Improved	53.2% (25)	59.3% (16)	45% (9)	0.39
Stable	36.2% (17)	29.6% (8)	45% (9)	0.36
Worse	10.6% (5)	11.1% (3)	10% (2)	1
Posthospital disposition				
Discharged home	36.1% (17)	37% (10)	35% (7)	1
Skilled nursing facility	27.7% (13)	18.5% (5)	40% (8)	0.19
Rehabilitation	17% (8)	22.2% (6)	10% (2)	0.44
Long-term acute care facility	19.1% (9)	22.2% (6)	15% (3)	0.71
Length of stay, d	14.9	13.5	16.7	0.13
30-day Readmission	14.9% (7)	7.4% (2)	25% (5)	0.12
Complications, % (n)				
Operative complications				
Total	12.8% (6)	11.1% (3)	15% (3)	1
Durotomy	2.1% (1)	3.7% (1)	0% (0)	1
Wound dehiscence requiring take back	2.1% (1)	3.7% (1)	0% (0)	1
Wound infection requiring take back	2.1% (1)	0% (0)	5% (1)	0.43
Superficial wound dehiscence	2.1% (1)	3.7% (1)	0% (0)	1
Postoperative seroma	2.1% (1)	0% (0)	5% (1)	0.43
Brachial plexopathy	2.1% (1)	0% (0)	5% (1)	0.43
Medical complications				
Total	12.8% (6)	7.4% (2)	20% (4)	0.38
Deep vein thrombosis	4.3% (2)	7.4% (2)	0% (0)	0.50
Metabolic encephalopathy	2.1% (1)	0% (0)	5% (1)	0.43
Pneumonia	2.1% (1)	0% (0)	5% (1)	0.43
Respiratory failure	2.1% (1)	0% (0)	5% (1)	0.43
Urinary tract infection	2.1% (1)	0% (0)	5% (1)	0.43

pain and weakness in his left arm that was later found on electromyography to be brachial plexopathy. The third patient developed a postoperative seroma that was treated conservatively.

There were a total of 6 major medical complications that occurred in the perioperative period. One patient in the decompression alone cohort with a history of chronic obstructive pulmonary disease and pulmonary hypertension was found to have hypercapnic respiratory failure requiring emergent intubation in the postoperative period. The patient underwent a bronchoscopy showing tracheobronchitis; after several attempts to wean ventilation, he ultimately had to undergo a tracheostomy and percutaneous endoscopic gastrostomy tube placement prior to discharge. Additionally, there were 2 patients in the decompression alone cohort who were found to have deep venous thromboses postoperatively.

In the decompression and fusion cohort, one patient developed respiratory distress during the postoperative period requiring intubation and was found to have a hospital acquired pneumonia. This patient ultimately required placement of a tracheostomy and percutaneous endoscopic gastrostomy tube prior to discharge. Another patient developed a significant metabolic encephalopathy, which resolved expectantly after treating the underlying medical derangements. Another patient was found to have a urinary tract infection that was treated without complication. There was no significant difference between

decompression alone and decompression with fusion groups with regard to operative ($P = 1$) or medical complications ($P = 0.38$). Complication details are summarized in Table 3.

DISCUSSION

Spinal infections can present with much anatomical variability and diversity of clinical symptoms.¹ In addition to the intervertebral discs and vertebral bodies, the spinal canal and the paraspinal structures can also be involved.¹ Spondylodiscitis arises most commonly through hematogenous spread from a remote infectious source,²⁰ and past, landmark studies have investigated the vascular anatomy of the spine to elucidate the pathophysiology of these infectious routes.²¹ Wiley and Trueta²¹ described an abundant arterial anastomotic system that spreads to vertebral metaphysis and cartilaginous endplates; bacteria can then destroy intervertebral discs and nearby bony structures by the release of bacterial proteolytic enzymes.^{1,20}

As a result of this tissue destruction, spinal infections can lead to deformity and resultant instability of the spine. Panjabi and White²² described spinal instability as the loss of the ability of the spine under physiologic loads to maintain relationships between vertebrae in such a way that there is neither initial damage nor subsequent irritation to the spinal cord or nerve roots; in addition, there is no development of incapacitating deformity or pain due

to the structural changes. Given the destructive process of spinal infections, it has been shown that spinal infections can result in spinal instability.¹² In addition, it is known in the orthopedic literature that nonunion of long bones can lead to persistent infection²³⁻²⁵; one could thus extrapolate that spinal pseudarthrosis and instability after infection may lead to the persistence or recurrence of discitis, osteomyelitis, and SEA, although more evidentiary basis is warranted.

The question of whether to solely decompress or to supplement decompression with instrumented fusion in an active spinal infection is a matter of some debate; in cases where a clear indication (eg, overt spinal instability, profound kyphotic deformity, etc) is lacking, there is no consensus. Some investigators argue that decompression alone may destabilize the spine.⁵ In turn, there is apprehension in instrumenting during an active infection due to concerns of continued infection with the supplementation of foreign materials; thus, arguing for a delayed instrumentation procedure.²⁶⁻²⁸ However, there are many investigators who disagree this notion and advocate the safety and effectiveness of instrumentation during an active spinal infection.²⁹⁻³³ In our patients, there was a trend toward fusion rather than decompression alone if there was active discitis at the laminectomy and the patient was more medically fit for an extended surgery.

Key Results

Despite the high incidence of spinal infections that require a neurosurgical operation, there is no definite consensus on the appropriate, initial surgical management for these patients with regard to the use of instrumentation. The complexity and variability of pathology can make surgical decision-making reasonably difficult. In this retrospective study of a cohort of patients with SEA that required surgical management at our institution, we evaluated the outcomes of patients who underwent decompression alone and those who underwent decompression with instrumented fusion, finding that the reoperation rate was significantly higher in patients who underwent decompression alone initially (51.9%) compared with those who underwent decompression with instrumented fusion (10%; $P = 0.004$).

In our study, a total of 47 patients underwent surgery for spinal infection. The total reoperation rate was 51.9% in the decompression alone cohort and 10% in the decompression with fusion cohort, which was a larger difference than reported in previous investigations by other authors. In a review performed by Karadimas et al,⁵ nearly half of the patients with spinal infection treated with decompression alone required reoperations to stabilize the spine

compared to 16.2% of patients who underwent decompression and fusion initially; these results are similar to our current study. Dietz et al¹⁰ reported a 12.7% reoperation rate in the nonfusion cohort and a 8.16% reoperation rate in the fusion cohorts. Bydon et al,¹³ Park et al,¹⁴ and Baek et al¹⁹ found no significant difference in reoperation rates between decompression alone and decompression with fusion cohorts in their separate studies, arguing that instrumentation in the setting of spinal infection may be a safe treatment modality and should be a consideration when spinal instability is of concern.

Conversely, there are separate studies that report a higher reoperation rate in patients who underwent initial fusion procedures for spinal infection. Utilizing a large national database consisting of 738 patients, Chaker et al¹¹ found that 12.2% of patients who underwent decompression alone needed reoperations compared to 23.8% of those who underwent decompression with fusion.

Previous studies that showed a larger reoperation rate in patients with decompression alone vs decompression with fusion state that a potential reason for this difference may be a selection bias with greater disease severity in the decompression alone cohort.¹⁰ In our study, there were no significant differences in the comorbidities and level and extent of involvement between the decompression alone cohort and the decompression with fusion cohort. Therefore, we submit that disease severity and patient surgical candidacy were unlikely to influence reoperation rate results.

Limitations and Generalizability

Our study has inherent limitations. Due to its retrospective nature, patients were not randomized and were prone to selection bias. Additionally, our study includes a small sample size from a single institution that can lead to limitations in significance among cohorts. A prospective, multicenter, randomized, controlled trial would be beneficial for future analysis.

Although we found a higher reoperation rate in patients who were decompressed alone vs those who underwent additional fusion, we do not argue that all patients should be fused in the initial operation for spinal infection. All patients should be properly analyzed and managed according to their unique presentation, clinical manifestations, presence or absence of spinal stability, and imaging characteristics. We instead argue that our results can aid surgeons who may be considering instrumented fusion in the setting of spinal infections in their initial operation.

At our institution, we favor instrumentation if there is significant bony destruction, fracture, deformity, substantial mechanical back pain, or persistent infection despite

appropriate antibiotics. Patients with these characteristics increase the likelihood that we would instrument in those with active spinal infection. In spinal oncology, a comprehensive classification system, the Spine Instability Neoplastic Score, based on patient symptoms and radiographic criteria was developed to aid in predicting spine stability of neoplastic lesions.³⁴ For our future research, we hope to develop a similar score that would aid in the surgical decision-making in those with spinal infections.

CONCLUSION

Additional studies are needed before reliable conclusions may be drawn, and patients with spinal infection should be managed according to their unique clinical scenario; however, the results of this study suggest that decompression with instrumented fusion for patients with SEA results in similar complication rates and significantly lower reoperation rates when compared with decompression alone.

REFERENCES

- Mavrogenis AF, Megaloiakonimos PD, Igoumenou VG, et al. Spondylodiscitis revisited. *EFORT Open Rev.* 2017;2(11):447–461. doi:10.1302/2058-5241.2.160062
- Sur A, Tsang K, Brown M, Tzerakis N. Management of adult spontaneous spondylodiscitis and its rising incidence. *Ann R Coll Surg Engl.* 2015;97(6):451–455. doi:10.1308/rcsann.2015.0009
- Herren C, Jung N, Pishnamaz M, Breuninger M, Siewe J, Sobottke R. Spondylodiscitis: diagnosis and treatment options. *Dtsch Arztebl Int.* 2017;114(51–52):875–882. doi:10.3238/arztebl.2017.0875
- Tsantes AG, Papadopoulos DV, Vrioni G, et al. Spinal infections: an update. *Microorganisms.* 2020;8(4):E476. doi:10.3390/microorganisms8040476
- Karadimas EJ, Bungler C, Lindblad BE, et al. Spondylodiscitis. A retrospective study of 163 patients. *Acta Orthop.* 2008;79(5):650–659. doi:10.1080/17453670810016678
- Carragee E, Iezza A. Does acute placement of instrumentation in the treatment of vertebral osteomyelitis predispose to recurrent infection: long-term follow-up in immune-suppressed patients. *Spine.* 2008;33(19):2089–2093. doi:10.1097/BRS.0b013e3181839b9c
- Fantoni M, Trecarichi EM, Rossi B, et al. Epidemiological and clinical features of pyogenic spondylodiscitis. *Eur Rev Med Pharmacol Sci.* 2012;16 Suppl 2:2–7.
- Skaf GS, Domloj NT, Fehlings MG, et al. Pyogenic spondylodiscitis: an overview. *J Infect Public Health.* 2010;3(1):5–16. doi:10.1016/j.jiph.2010.01.001
- Babic M, Simpfendorfer CS. Infections of the spine. *Infect Dis Clin North Am.* 2017;31(2):279–297. doi:10.1016/j.idc.2017.01.003
- Dietz N, Sharma M, Alhourani A, et al. Outcomes of decompression and fusion for treatment of spinal infection. *Neurosurg Focus.* 2019;46(1):2018.10.FOCUS18460. doi:10.3171/2018.10.FOCUS18460
- Chaker AN, Bhimani AD, Esfahani DR, et al. Epidural abscess: a propensity analysis of surgical treatment strategies. *Spine.* 2018;43(24):E1479–E1485. doi:10.1097/BRS.0000000000002747
- Bridges KJ, Than KD. Holospinal epidural abscesses - institutional experience. *J Clin Neurosci.* 2018;48:18–27. doi:10.1016/j.jocn.2017.10.057
- Bydon M, De la Garza-Ramos R, Macki M, et al. Spinal instrumentation in patients with primary spinal infections does not lead to greater recurrent infection rates: an analysis of 118 cases. *World Neurosurg.* 2014;82(6):e807-14. doi:10.1016/j.wneu.2014.06.014
- Park K-H, Cho O-H, Lee Y-M, et al. Therapeutic outcomes of hematogenous vertebral osteomyelitis with instrumented surgery. *Clin Infect Dis.* 2015;60(9):1330–1338. doi:10.1093/cid/civ066
- Subbiah M, Shiromi S, Yegumuthu K. Comprehensive treatment algorithm for management of thoracic and lumbar tubercular spondylodiscitis by single-stage posterior transforaminal approach. *Musculoskelet Surg.* 2020;104(1):101–109. doi:10.1007/s12306-019-00606-1
- Noh SH, Zhang HY, Lim HS, Song HJ, Yang KH. Decompression alone versus fusion for pyogenic spondylodiscitis. *Spine J.* 2017;17(8):1120–1126. doi:10.1016/j.spinee.2017.04.015
- Lin C-P, Ma H-L, Wang S-T, Liu C-L, Yu W-K, Chang M-C. Surgical results of long posterior fixation with short fusion in the treatment of pyogenic spondylodiscitis of the thoracic and lumbar spine: a retrospective study. *Spine.* 2012;37(25):E1572-9. doi:10.1097/BRS.0b013e31827399b8
- Löhr M, Reithmeier T, Ernestus RI, Ebel H, Klug N. Spinal epidural abscess: prognostic factors and comparison of different surgical treatment strategies. *Acta Neurochir.* 2005;147(2):159–166. doi:10.1007/s00701-004-0414-1
- Baek KH, Lee Y-S, Kang DH, Lee CH, Hwang SH, Park IS. The safety and decision making of instrumented surgery in infectious spondylitis. *Korean J Spine.* 2016;13(3):120–123. doi:10.14245/kjs.2016.13.3.120
- Hadjipavlou AG, Mader JT, Necessary JT, Muffoletto AJ. Hematogenous pyogenic spinal infections and their surgical management. *Spine.* 2000;25(13):1668–1679. doi:10.1097/00007632-200007010-00010
- WILEY AM, TRUETA J. The vascular anatomy of the spine and its relationship to pyogenic vertebral osteomyelitis. *J Bone Joint Surg Br.* 1959;41-B:796–809. doi:10.1302/0301-620X.41B4.796
- Panjabi MM. The stabilizing system of the spine. Part I. *Function, Dysfunction, Adaptation, and Enhancement Clinical Spine Surgery.* 1992;5(4):383. doi:10.1097/00002517-199212000-00001
- Struijs PAA, Poolman RW, Bhandari M. Infected non-union of the long bones. *J Orthop Trauma.* 2007;21(7):507–511. doi:10.1097/BOT.0b013e3181812e5578
- Elliott DS, Newman KJH, Forward DP, et al. A unified theory of bone healing and nonunion: BHN theory. *Bone Joint J.* 2016;98-B(7):884–891. doi:10.1302/0301-620X.98B7.36061
- Agrawal M, Yuvarajan P, Maini L, Gautam VK. Management of infected non-union in long bones: our experience with bone cement. *J Clin Orthop Trauma.* 2010;1(1):41–46. doi:10.1016/S0976-5662(11)60009-X
- Dimar JR, Carreon LY, Glassman SD, Campbell MJ, Hartman MJ, Johnson JR. Treatment of pyogenic vertebral osteomyelitis with anterior debridement and fusion followed by delayed posterior spinal fusion. *Spine.* 2004;29(3):326–332. doi:10.1097/01.brs.0000109410.46538.74

27. Przybylski GJ, Sharan AD. Single-stage autogenous bone grafting and internal fixation in the surgical management of pyogenic discitis and vertebral osteomyelitis. *J Neurosurg*. 2001;94(1 Suppl):1–7. doi:10.3171/spi.2001.94.1.0001

28. Hwang GJ, Kuh SU, Chin DK, Cho YE, Kim YS. Management of wound infection after lumbar spine fusion with instruments. *J Korean Neurosurg Soc*. 2004;35(1):36–41.

29. Lee MC, Wang MY, Fessler RG, Liauw J, Kim DH. Instrumentation in patients with spinal infection. *Neurosurg Focus*. 2004;17(6):E7:1–6. doi:10.3171/foc.2004.17.6.7

30. Talia AJ, Wong ML, Lau HC, Kaye AH. Safety of instrumentation and fusion at the time of surgical debridement for spinal infection. *J Clin Neurosci*. 2015;22(7):1111–1116. doi:10.1016/j.jocn.2014.12.028

31. Carragee EJ. Instrumentation of the infected and unstable spine: a review of 17 cases from the thoracic and lumbar spine with pyogenic infections. *J Spinal Disord*. 1997;10(4):317–324.

32. Dietze DD, Fessler RG, Jacob RP. Primary reconstruction for spinal infections. *J Neurosurg*. 1997;86(6):981–989. doi:10.3171/jns.1997.86.6.0981

33. Faraj AA, Webb JK. Spinal instrumentation for primary pyogenic infection report of 31 patients. *Acta Orthop Belg*. 2000;66(3):242–247.

34. Fisher CG, DiPaola CP, Ryken TC, et al. A novel classification system for spinal instability in neoplastic disease: an

evidence-based approach and expert consensus from the spine oncology study group. *Spine*. 2010;35(22):E1221–9. doi:10.1097/BRS.0b013e3181e16ae2

Funding: The author(s) received no financial support for the research, authorship, and/or publication of this article.

Disclosures and COI: The authors report no financial disclosures or conflicts of interest related to this article.

Corresponding Author: Marcus Wong, Department of Neurosurgery, Houston Methodist Neurological Institute, Houston, TX 77030, USA; mswong@houstonmethodist.org

Published 15 February 2022

This manuscript is generously published free of charge by ISASS, the International Society for the Advancement of Spine Surgery. Copyright © 2022 ISASS. To see more or order reprints or permissions, see <http://ijssurgery.com>.