

Expandable Lateral Lumbar Cages With Integrated Fixation: A Viable Option for Rostral Adjacent Segment Disease

Gregory M. Malham, Carl M. Blecher, Nigel R. Munday and Ryan P. Hamer

Int J Spine Surg 2022, 16 (4) 748-759

doi: <https://doi.org/10.14444/8307>

<https://www.ijssurgery.com/content/16/4/748>

This information is current as of May 17, 2025.

Email Alerts Receive free email-alerts when new articles cite this article. Sign up at:
<http://ijssurgery.com/alerts>

Expandable Lateral Lumbar Cages With Integrated Fixation: A Viable Option for Rostral Adjacent Segment Disease

GREGORY M. MALHAM, MB, ChB, FRACS¹; CARL M. BLECHER, MB, BS, FRANZCR, DDU²; NIGEL R. MUNDAY, MB, BS, MBA¹; AND RYAN P. HAMER, BSc, MBA³

¹Neuroscience Institute, Epworth Hospital, 89 Bridge Road, Richmond, Melbourne, Australia; ²Richmond Diagnostic Imaging, Richmond, Melbourne, Australia; ³University of Sydney, Faculty of Medicine and Health, Edward Ford Building, Fisher Road, NSW 2006, Australia

ABSTRACT

Background: Adjacent segment disease (ASD) above a previous posterior lumbar instrumented fusion can be managed with minimally invasive lateral lumbar interbody fusion. Earlier procedures with stand-alone lateral cages risked nonunion, and lateral cages with separate lateral plates risked lumbar plexus injury and vertebral fracture. We investigated clinical and radiographic outcomes of an expandable lateral titanium interbody cage with an integrated lateral fixation (eLLIFp) device as a stand-alone treatment for symptomatic ASD above a previous posterior lumbar fusion and performed a comparative cost analysis of eLLIFp to alternative operations for ASD.

Methods: In this prospective, observational study, patients with ASD above 1-, 2-, 3-, or 4-level instrumented posterior fusions underwent surgery with lateral expandable titanium cage(s) with an integrated lateral plate with single screws into each adjacent vertebra from August 2017 to August 2019. Multimodality intraoperative neural monitoring was performed. Patient-reported outcomes, computed tomography outcomes, and total costs were analyzed.

Results: A total of 33 patients received 35 eLLIFp cages. All clinical outcomes improved significantly. The eLLIFp cages added 2.2° segmental lordosis and 2.7 mm posterior disc height. Interbody fusion rate was 94% at 12 months. There were 2 neurologic complications (6%): 1 patient reported transient anterior thigh numbness and 1 had mild persistent L4 radiculopathy. No cage subsidence, cage migration, screw loosening, or vertebral fracture occurred. No revision lateral surgery, posterior decompression, or supplemental posterior fixation was required. The total eLLIFp cost (AU\$19,715) was lower than the cost for all other procedures.

Conclusions: eLLIFp provided a minimally invasive, low morbidity, cost-effective, and robust alternative to traditional posterior construct extension surgery for rostral lumbar ASD in selected patients with 1- to 2-level stenosis and minimal deformity.

Clinical Relevance: Traditional ASD treatment involves substantial risks and expense. eLLIFp should be considered a safe, effective, and lower cost alternative to posterior construct extension surgery.

Level of Evidence: 2.

New Technology

Keywords: adjacent segment disease, expandable lateral lumbar cages, posterior lumbar fusion, cost analysis

INTRODUCTION

Radiologic degeneration of the disc space adjacent to a previous posterior lumbar instrumented fusion is becoming more common, as more patients undergo lumbar fusion surgery and as life expectancy increases.¹ Symptomatic adjacent segment disease (ASD) above a prior posterior lumbar fusion requiring further surgery occurs in 9% to 22% of patients 5 to 10 years later.^{2,3} Traditional ASD management involves posterior extension of the construct, which is accompanied by substantial risks of infection, major blood loss, cerebrospinal fluid leak, neural injury, and prolonged surgical duration.⁴

An alternative treatment option is minimally invasive surgery (MIS) lateral lumbar interbody fusion (LLIF), which is a reliable technique for degenerative disc disease, canal stenosis, foraminal stenosis, and spinal deformity^{5,6} and a good option for rostral ASD.^{4,7} Stand-alone lateral cages are indicated in the absence of instability, deformity, or reduced bone density^{8,9} but increase the risk of nonunion; hence, supplemental fixation is recommended.⁴ Coronal vertebral body fractures have occurred in patients with osteoporosis using a separate lateral plate and unilateral pedicle screws¹⁰ and in patients without osteoporosis using 1- and 2-level separate lateral plates.¹¹ Recent studies reported improved segmental lordosis (SL) and restoration of

disc height with less subsidence utilizing expandable lateral cages compared with impacted static lateral cages.¹²⁻¹⁴ Expandable cages with lateral fixation significantly improved segmental stability and prevented anterior cage dislodgment.¹⁵ Early experience using these expandable lateral titanium interbody cages with integrated lateral plate fixation (eLLIFp) found the device to be robust and not require supplemental posterior pedicle screw-rod fixation.

To our knowledge, no clinical study has heretofore assessed the eLLIFp device as a stand-alone treatment for ASD. In this study, we investigated clinical and radiographic outcomes of eLLIFp alone for symptomatic ASD above a previous posterior instrumented fusion.

METHODS

This prospective observational cohort study included 33 consecutive patients with ASD above a previous posterior instrumented fusion. Patients were evaluated with dynamic (flexion, extension, and lateral bending) radiography, computed tomography (CT) coregistered with isotope bone scans, magnetic resonance imaging, and bone mineral density (DEXA) scans. All patients underwent subsequent MIS LLIF ASD surgery at 1 to 2 contiguous level(s) by a single surgeon from August 2017 to August 2019 via eLLIFp using the ELSA device (Globus Medical Inc., Audubon, PA). Patients were followed for more than 12 months. Radiographic and clinical outcomes were assessed preoperatively and at 2 days, 6 weeks, 6 months, 12 months, 18 months, and 24 months postoperatively. Our institutional ethics committee approved this study. All patients provided written informed consent.

Inclusion and Exclusion Criteria

Inclusion criteria were age between 18 and 80 years; presence of ASD at 1 or 2 levels above a previous posterior lumbar fusion (posterolateral instrumented fusion [PLF] or posterior lumbar interbody fusion [PLIF]); degenerative disc disease, grade 1 degenerative spondylolisthesis, mild or moderate canal stenosis, foraminal stenosis, or facet arthropathy at the ASD level(s); and willingness to attend all follow-up visits.

Patients were excluded if they had 3-level ASD, body mass index (BMI) greater than 40 kg/m², pars defect, isthmic spondylolisthesis, coronal or sagittal deformity,¹⁶ grade 2 or more degenerative spondylolisthesis, moderately severe or severe canal stenosis, bony lateral recess stenosis, osteoporosis (femoral neck *T* score of

-2.5 or less),⁸ unfavorable psoas muscle anatomy,¹⁷ previous complex/extensive retroperitoneal surgery, or prior abdominal/pelvic radiotherapy.

Patient and Treatment Characteristics

Medical records were reviewed to obtain baseline patient information. We also collected treatment information.

Surgery

LLIF was performed under anteroposterior and lateral fluoroscopy. The lateral border of the target disc space was approached via a 90° off-midline retroperitoneal incision and passage through the psoas. Sequential muscle-splitting dilators were inserted under neural monitoring to identify branches of the lumbar plexus and ensure the retractors were placed anterior to the nerves. The tubular retractor was anchored with an intradiscal shim in the posterior one-third of the disc, then opened to a diameter of 22 mm. A Cobb elevator was inserted around the disc to release the contralateral lateral ligament, discectomy was performed, and endplates were prepared using curettes and rasps. Trial cages were inserted to determine the required lateral cage length. The retractor was then opened to 25 mm. The device was inserted at an initial height of 8 mm, then expanded using the lateral torque-limiting driver (Globus Medical Inc.) to obtain a snug fit. Fluoroscopy-guided holes were then made through the integrated lateral plate for fixation using a drill rather than an awl. The superior screw length was usually the same length or 10 mm shorter than the eLLIFp cage length. The inferior screw length was often dictated by the position of the in situ contralateral upper instrumented vertebra pedicle screw. Each screw head was secured to prevent movement. Psoas retraction durations were recorded. The retractor was then released to permit cage backfill with graft and coverage of the ipsilateral cage and exposed psoas muscle with absorbable hemostatic agent (SURGICEL; Ethicon, Inc., Somerville, NJ). The retractor and shim were carefully removed under direct vision.

Interbody Cages and Graft Material

All patients received an eLLIFp device with screws inserted into each adjacent vertebra. The lordosis options were a fixed 6° lordosis at L1-L2 and L2-L3 or an adjustable 5° to 20° lordosis at L3-L4 and L4-L5, permitting customized segmental height and lordosis.

The eLLIFp cages for patients 1 to 28 were filled with recombinant human bone morphogenic protein-2 (BMP) (1.5 mg/mL) applied to an absorbable collagen sponge (Infuse; Medtronic, Inc., Memphis, TN, USA), which was trimmed to the cage volume. The Infuse dose used per level was volume-dependent (ie, the internal cage volume equaled BMP volume in cc). A small kit of BMP (2.8 cc providing a 4.2 mg dose) was used as per the manufacturer's recommendation following a 1-hour absorption into the carrier period.¹⁸ No Infuse was placed outside the cage. The cages for patients 29 to 33 were filled with cortico-cancellous fibers (Device Technologies, Inc., Belrose, NSW, Australia) because of regulatory withdrawal of Infuse. After cage expansion, all cages were back-filled with granules of synthetic hydroxyapatite bone substitute in an amorphous silica gel (NanoBone; Artoss, Inc., St. Cloud, MN).

Neural Monitoring

All patients underwent multimodal intraoperative neural monitoring (IONM) with transcranial motor evoked potentials, somatosensory evoked potentials, electromyography (EMG), and triggered EMG.

Complications

Complications were identified during hospitalization and after discharge. Perioperative complications were classified as minor (anterior thigh sensory changes or psoas muscle approach-related pain) or major (lumbar radiculopathy, femoral neuropathy, bowel injury, or major vascular injury), as per previous LLIF studies.¹⁹

Clinical Outcomes

Preoperative and postoperative assessments of patient-reported outcome measures included back and leg pain (visual analog scale), disability (Oswestry Disability Index), and quality of life (Short Form 12 physical component score and mental component score).

Radiographic Quantitative Measurements

SL was measured as the angle between the cranial endplate of the superior vertebra and the cranial endplate of the inferior vertebra. Lumbar lordosis (LL) was measured as the angle between the cranial endplate of the L1 vertebra and the cranial endplate of the S1 vertebra. Posterior disc height (PDH) was measured between the posterior vertebral margins of

the caudal and cranial endplates adjacent to the disc.⁸ Lordosis and PDH were measured on CT images preoperatively, postoperatively, and at the time of interbody fusion. All measurements were obtained digitally using Inteleviewer software (Interad Medical Systems Inc., Quebec, Canada).

Interbody Fusion

High-definition, low-dose CT images (Somatom Definition Flash; Siemens AG, Erlangen, Germany) were obtained preoperatively and 2 days postoperatively to assess cage and plate-screw position and at 6 and 12 months until solid interbody fusion was confirmed on coronal and sagittal views. All postoperative scans focused on the operative level alone.²⁰ To reduce radiation exposure, no scans were performed after confirming interbody fusion. Fusion was defined as bridging interbody trabecular bone on coronal and sagittal views²¹ (Figure 1). An independent radiologist interpreted CT results.

Subsidence

Subsidence was measured radiographically from the vertebral endplate to the caudal or cranial margin of each cage. Subsidence was deemed early cage subsidence (ECS) if evident on postoperative day 2 CT images and was therefore secondary to intraoperative vertebral endplate violation. Subsidence detected only on later CT images was deemed delayed cage subsidence (DCS). Endplate breaches were classified as type 1, subsidence into the contralateral caudal endplate; type 2, bilateral subsidence into the caudal endplate, producing an anterior tilt of the cage; or type 3, bilateral subsidence into both caudal and cranial endplates.²²

Cost Analysis

A comparative cost analysis between eLLIFp and alternative procedures for single-level ASD in a private hospital in Australia was undertaken (Table 1). The total implant charges were calculated using the Private Health Insurance Prostheses List²³ for the eLLIFp prosthesis compared with a single LLIF cage, single transforaminal lumbar interbody fusion (TLIF) cage, and 2 PLIF cages all with posterior pedicle screw-rod extension, PLF (without cage[s]), and an integrated anterior lumbar interbody fusion (ALIF) cage (without posterior instrumentation). The total operating room (OR) charges were calculated using the mean OR time per procedure (eLLIFp 2 hours; PLF 2.5 hours; TLIF, PLIF, ALIF, and LLIF with posterior instrumentation all 3 hours) times

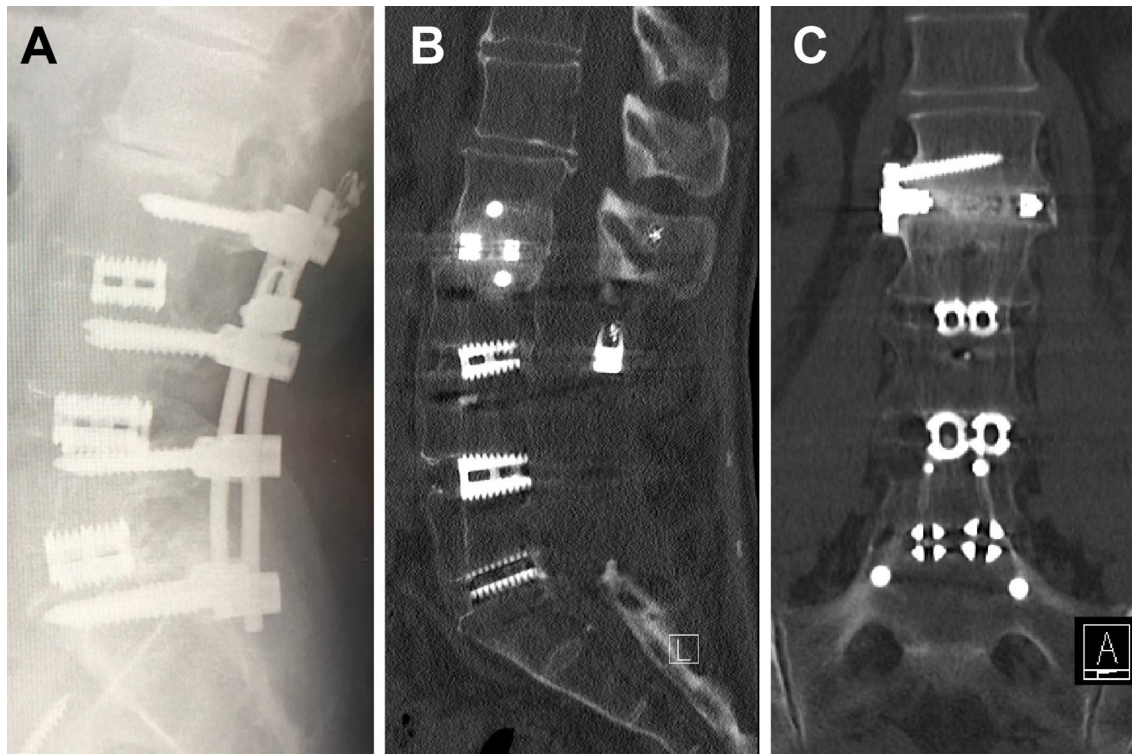


Figure 1. (A) L2-L3 adjacent segment disease above a previous L3-S1 posterior lumbar interbody fusion on a lateral radiograph. The expandable lateral titanium interbody cage with an integrated lateral fixation at the L2-L3 level with solid interbody fusion at 12 months noted on computed tomography. (B) Sagittal and (C) coronal views.

the mean operating theater cost of AU\$2500 per hour.²⁴ The total inpatient hospital charges were calculated using the mean length of stay per procedure (eLLIFp and LLIF with posterior instrumentation both 3 days; PLF 4 days; TLIF, PLIF/ALIF all 5 days) times hospital bed cost of AU\$1335 per day.²⁵ The specialist fees for the spine and vascular access surgeon (operation item code numbers) and anesthetist (AU\$19.80/unit) were calculated using the Medicare Benefits Schedule.²⁶ The cell saver with perfusionist charge is AU\$500 per procedure (used in PLIF, PLF, and ALIF). Multimodal IONM with neurophysiologist charge is AU\$1500 per procedure (used in eLLIFp and LLIF with posterior instrumentation). The mean total cost per procedure for single-level ASD was then calculated by the sum of the contributing charges.

Statistical Methods

Analyses were performed using IBM SPSS Statistics, version 21.0 (IBM Corp., Armonk, New York, USA) and included paired *t* tests, unpaired *t* tests, and Fisher exact tests. *P* values less than 0.05 were considered statistically significant.

RESULTS

Patient Characteristics

Thirty-three patients received 35 eLLIFp devices. Their mean age was 64.9 years, and 18 were women (Table 2). Mean time from posterior fusion to ASD was 7.8 years. The most common ASD pathology was degenerative spondylolisthesis, followed by foraminal stenosis and canal stenosis. One patient with multiple myeloma died before 6-month follow-up. Two-level fusion was the most common previous posterior fusion surgery.

Surgical Data

The most commonly treated ASD levels were L3-L4 (Figure 2) and L2-L3 (Figure 1). Mean total psoas retraction time was 30.5 minutes. Mean retraction time was 14.4 minutes with the retractor opened 22 mm and 13.9 minutes with it opened 25 mm (Table 2). Estimated blood loss was less than 50 mL for all patients.

Clinical Outcomes

Mean follow-up duration was 18 months. By last follow-up, mean back and leg pain scores improved from

Table 1. Comparative cost analysis of single-level eLLIFp, LLIF with posterior fixation, TLIF, PLIF, PLF, and ALIF.

Procedure (Single-Level Adjacent Segment Disease/Extension of Construct)	Implant	Implant Charges	Total Implant Charges	OR Charges (Mean OR Time @ \$2500/h)	Inpatient Hospital Charges (Mean LOS @ \$1335/d)	Total Specialist (Surgeon + Anesthetist @ \$19,800/unit) Medicare Charges ⁶⁷	Cell Saver	Intraoperative Neural Monitoring	Mean Total Cost ^a	Cost Relativity (Using eLLIFp as Index)
eLLIFp	Expandable lateral cage with plate screws	\$6021; \$186 × 2 (2 screws)	\$6393	\$5000 (2 h)	\$4005 (3 d)	\$2817 (\$2193 + \$614 [31 units])	N/A	\$1500	\$19,715	1
LLIF with posterior fixation	Expandable lateral cage; Polyaxial screws; Caps/blockers; Prelordosed rods	\$3335; \$1232 × 2 (2 screws); \$560 × 6 (6 caps); \$410 × 2 (2 rods)	\$9979	\$7500 (3 h)	\$4005 (3 d)	\$3656 (\$2923 + \$733 [37 units])	N/A	\$1500	\$26,640	1.4
TLIF	Expandable TLIF cage; Polyaxial screws; Caps/blockers; Prelordosed rods	\$3335; \$1232 × 2 (2 screws) ^b ; \$560 × 6 (6 caps); \$410 × 2 (2 rods)	\$9979	\$7500 (3 h)	\$6675 (5 d)	\$3514 (\$2663 + \$851 [43 units])	Optional	N/A	\$27,668	1.4
PLIF	Expandable PLIF cage; Polyaxial screws; Caps/blockers; Prelordosed rods	\$2780 × 2 (2 cages); \$1232 × 2 (2 screws) ^b ; \$560 × 6 (6 caps); \$410 × 2 (2 rods)	\$12,204	\$7500 (3 h)	\$6675 (5 d)	\$3514 (\$2663 + \$851 [43 units])	\$500	N/A	\$30,393	1.5
PLF	Polyaxial screws; Caps/blockers; Prelordosed rods	\$1232 × 2 (2 screws) ^b ; \$560 × 6 (6 caps); \$410 × 2 (2 rods)	\$6644	\$6250 (2.5 h)	\$5340 (4 d)	\$3232 (\$2499 + \$733 [37 units])	\$500	N/A	\$21,966	1.1
ALIF	Integrated static cage; Screws	\$6021; \$186 × 3 (3 screws)	\$6579	\$7500 (3 h)	\$6675 (5 d)	\$2613 (\$1880 + \$733 [37 units]) plus vascular surgeon: \$1186	\$500	N/A	\$25,053	1.3

Abbreviations: ALIF, anterior lumbar interbody fusion; eLLIFp, expandable lateral titanium interbody cages with integrated lateral plate fixation; LLIF, lateral lumbar interbody fusion; LOS, length of stay; N/A, not applicable; OR, operating room; PLF, posterolateral instrumented fusion; PLIF, posterior lumbar interbody fusion; TLIF, transforaminal lumbar interbody fusion.

Note: All costs given in Australian dollars.

^a Total cost does not include charges for bone graft substitutes (which depend on the surgeon's preference).

^b Assumes posterior fixation with 2 new screws above the construct and using the existing screws below with new caps.

Table 2. Patient and treatment characteristics.

Characteristic	Value (N = 33)
Age, y, mean (range)	64.9 (34–82)
Female, n (%)	18 (55)
Body mass index, kg/m ² , mean (range)	29.5 (20.0–38.5)
Current smoker, n (%)	4 (12)
Previous posterior fusion level, n (%)	
L5-S1 (1-level)	8 (24)
L4-S1 (2-level)	15 (46)
L3-S1 (3-level)	8 (24)
L2-S1 (4-level)	2 (6)
Time from fusion to ASD, y, mean (range)	7.8 (1–25)
ASD pathology (35 devices), n (%)	
Degenerative spondylolisthesis	12 (34)
Foraminal stenosis	10 (29)
Canal stenosis	8 (23)
Degenerative disc disease	5 (14)
ASD level treated (35 devices)	
L1-L2, n (%)	4 (11)
L2-L3, n (%)	10 (29)
L3-L4, n (%)	14 (40)
L4-L5, n (%)	7 (20)
Psoas retraction time, min, mean (range)	
Total time	30.8 (15–40)
Time with retractor open to 22 mm	14.4 (8–24)
Time with retractor open to 25 mm	13.9 (7–22)

Abbreviation: ASD, adjacent segment disease.

7.8 to 0.6 and 6.9 to 0.6, representing 92% and 91% improvements, respectively. Oswestry Disability Index improved by 47% at 12-month follow-up (Table 3). Quality-of-life scores also improved from baseline to 12-month follow-up, with physical component score and mental component score improving by 69% and

42%, respectively. All clinical outcomes improved significantly from baseline.

Radiographic Outcomes

The eLLIFp cages were expanded to a mean anterior height of 10 mm and lordosis of 8°, which added 2.2° SL, 2.2° LL, and 2.7 mm PDH from preoperatively to fusion time (Table 4). These increases were significant for SL and PDH but not LL. The mean difference in PDH from 6 weeks to 12 months was 2.7 ± 1.5 mm. Interbody fusion rates increased from 53% at 6 months to 94% (32/34 cages) at 12 months (Table 5). The 2 eLLIFp cage nonunions were both at the L4-L5 level. We found no significant difference in eLLIFp fusion rates between the previous 1 to 4 segment posterior fusions. There was also no significant difference in fusion rates between cages filled with Infuse or cortico-cancellous fibers. No ECS or DCS was observed at any of 35 eLLIFp cages.

Complications

Total complication rate was 9%, with rates of 6% and 3% for minor and major complications, respectively (Table 6). One patient experienced right anterior thigh pain, which resolved after 2 weeks; one developed anterior thigh sensory loss, which resolved by 4 weeks. Another patient developed new motor deficit with right L4 radiculopathy after L3-L4 eLLIFp despite normal IONM, which improved at 12 months. Neurologic complication rate was 6%. No genitofemoral nerve palsy or femoral neuropathy occurred. There were no bowel injuries or cage migration. No secondary lateral surgery, posterior decompression, or supplemental posterior fixation at the index or adjacent levels was required.

Cost Analysis

The mean total cost of each procedure for single-level ASD included the proportion of total implant charges (26%–40%), total OR charges (25%–28%), and total hospital charges (22%–27%). Mean total cost of eLLIFp for single-level ASD was AU\$19,715²³ (Table 1). By relative costs using eLLIFp as the index cost, an extension PLF without cage (AU\$21,996) was 1.1 times greater; ALIF with integrated plate and screws was 1.3; LLIF with pedicle screw-rod extension and extension TLIF were both 1.4; and an extension PLIF was 1.5 times greater total cost.

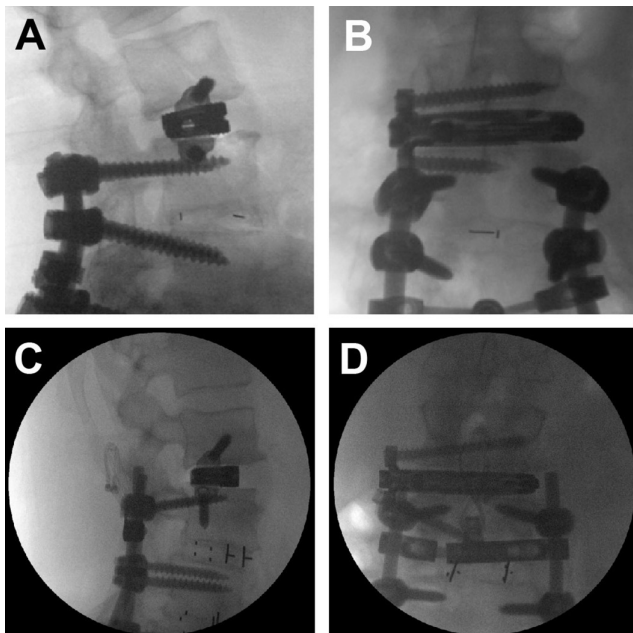


Figure 2. Radiograph of expandable lateral titanium interbody cage with an integrated lateral fixation at the L3-L4 level with the inferior screw of the lateral plate placed above (A, B) and below (C, D) the in situ superior pedicle screw: (A, C) lateral and (B, D) anteroposterior films.

Table 3. Clinical outcome scores.

Outcome Measure	Preop	6 wk	6 mo	12 mo	P (Preop vs 12 mo)
Back VAS pain score	7.8 ± 1.4	2.1 ± 0.6	1.3 ± 0.8	1.2 ± 0.8	<0.0001
Leg VAS pain score	6.9 ± 2.8	1.8 ± 1.7	1.4 ± 1.2	1.4 ± 1.3	<0.0001
Oswestry Disability Index	61.0 ± 11.5	39.0 ± 6.2	30.9 ± 16.4	32.2 ± 12.2	<0.0001
SF-12 physical component score	30.1 ± 6.4	44.5 ± 7.8	49.0 ± 8.3	50.9 ± 5.4	<0.0001
SF-12 mental component score	39.0 ± 7.3	50.1 ± 7.6	52.7 ± 8.1	55.3 ± 4.3	<0.0001

Abbreviations: Preop, preoperative; SF-12, Short Form 12-item health survey; VAS, visual analog scale.

Note: Data are presented as mean ± SD.

DISCUSSION

While MIS fusion has been identified with similar fusion rates, patient satisfaction, patient-reported outcomes, and complications as open techniques, it has the advantages of less blood loss, length of hospital stay, and cost savings.²⁷ However, both clinically symptomatic ASD and radiographic degeneration classifications remain substantial following spinal fusion. Rates of radiographic degeneration adjacent to previous PLIF are 29% to 34% over 5 to 10 years.²⁸ A review of 4206 patients reported incidences of 5.9% and 1.8% per year for adjacent level degeneration and ASD, respectively.²⁸ Sears et al reported 5- and 10-year ASD rates of 9% and 16%, 17% and 31%, and 29% and 40% after 1-, 2-, and 3/4-level PLIF, respectively.² Accordingly, most patients (75%) in our study had previous 2-level or 3/4-level PLIF.

In this study, the mean duration between primary PLIF and ASD was 7.8 years, which was longer than the 4.7 years observed in a retrospective review of 1000 patients.³ Our mean age at presentation for ASD was 65 years, similar to ages reported previously.^{3,4} The most common initial ASD pathologies reported previously³ were degenerative spondylolisthesis and canal stenosis, which were similar to our most common pathologies: spondylolisthesis, foraminal stenosis, and canal stenosis.

Sex did not appear to affect the risk of ASD. Women and men were approximately equally represented in this study, which is consistent with previous results.²⁹

Higher BMI is a risk factor for ASD, and our cohort had an average BMI of 29.5 kg/m². Laminectomy for stenosis adjacent to a fusion also increases the risk of ASD; hence, extension of PLIF² or LLIF with supplemental posterior fixation³ is recommended.

LLIF is an alternative technique for ASD. It enhances interbody fusion and provides better biomechanical stability.^{30,31} It preserves all posterior stabilizing ligamentous structures, prevents injury to paraspinal muscles, and avoids denervation or injury to the adjacent superior facet joints. Epidural scarring, perineural fibrosis, cerebrospinal fluid leak, and direct nerve root injury are also avoided.⁵ LLIF also produces lower infection rates and less estimated blood loss. No wound infections occurred in our study.

Intervertebral cages used with LLIF span both apophyseal cortical rims, providing optimal endplate support to minimize subsidence risk.³² Reported subsidence rates after LLIF range from 10% to 62%.³³⁻³⁵ Higher rates of subsidence with stand-alone LLIF cages occur with reduced bone density (*T* scores less than -1.0),³⁴ but we found no cases in our patient cohort with eLLIFp cages. Cage geometry is important for avoiding subsidence.³² Subsidence rates are higher with 18-mm polyetheretherketone cages than with 22-mm polyetheretherketone cages (14.1% vs 1.9%).³⁶ The eLLIFp cage width of 20 mm is thus advantageous for avoiding subsidence. Effects of cage length are less clear. Previous studies reported that length does not affect subsidence unless it is insufficient to cover the periphery

Table 4. Lordosis and posterior disc height on computed tomographic images.

Time	Segmental Lordosis, °	Lumbar Lordosis, °	Posterior Disc Height, mm
Preop	8.2 ± 4.1	41.0 ± 11.2	3.2 ± 1.6
Postop ^a	10.6 ± 2.9	43.1 ± 8.4	6.0 ± 1.7
Fusion ^b	10.4 ± 4.1	43.2 ± 11.0	5.9 ± 1.5
<i>P</i> (preop vs postop)	0.0078	0.3921	<0.0001
<i>P</i> (preop vs fusion)	0.0330	0.4238	<0.0001
<i>P</i> (postop vs fusion)	0.8198	0.9670	0.8008

Abbreviations: postop, postoperative; preop, preoperative.

Note: Data are mean ± SD.

^aAt 6 wk postoperatively.

^bAt the time of fusion (6 or 12 mo postoperatively).

Table 5. Fusion rates on computed tomography images at 6 and 12 mo postoperatively.

Time	% Solid Interbody Fusion (n Fused/n Total)
6 mo	53 (18/34)
12 mo	94 (32/34)

Abbreviation: n, number of cages.

of the endplates.^{31,36} However, a greater cage height appeared to increase the rate of subsidence.³⁵ Hence, we took great care to expand the cage using tactile feedback to obtain a snug fit and not torque the expansion mechanism.

Frisch et al reported subsidence rates of 16% with static cages and 0% with expandable cages.¹² However, patients with static cages underwent unilateral posterior stabilization, whereas most patients with expandable cages underwent bilateral posterior stabilization requiring repositioning to the prone position. Compared with static cages, expandable cages are inserted at a lower profile and expanded in situ, resulting in less trialing and iatrogenic endplate disruption secondary to impaction. Li et al noted significantly lower subsidence rates with expandable cages compared with static cages at 12-month follow-up.¹³ The absence of ECS or DCS in our study reflects an experienced lateral surgeon considering the following factors: (1) appropriate case selection; (2) choosing the side of approach best for disc space entry; (3) judicious use of anteroposterior and lateral fluoroscopy; (4) Cobb elevator release of the contralateral lateral ligament; (5) careful endplate preparation; (6) minimal endplate trauma with trials; (7) using angled instruments if indicated (especially at

Table 6. Minor and major complications.

Complication	Number
Minor	
Anterior thigh sensory change	1
Anterior thigh pain	1
Atelectasis	0
Ileus	0
Superficial wound infection	0
Hematoma	0
Incisional hernia	0
Total	2
Major	
Radiculopathy (motor deficit)	1
Femoral neuropathy	0
Pneumothorax	0
Deep wound infection	0
Bowel injury	0
Major vascular injury	0
Subsidence	0
Cage migration	0
Screw loosening or fracture	0
Vertebral fracture	0
Revision surgery	0
Total	1

L4-L5); (8) impaction of a wide footprint cage orthogonal to the disc space; (9) the fact that a cage of adequate length is critical to span the apophyseal ring appreciative of ipsilateral osteophytes; (10) careful distraction of the cage avoiding torque release (designed to protect the cage); and (11) lateral plate fixation screws equal to or 10 mm less than cage length.

Biomechanical data for LLIF indicate that spinal segment stability is greater with supplemental fixation than with stand-alone cages.^{30,37} Indications for supplemental “gold standard” posterior pedicle screw-rod fixation follow a published treatment algorithm and include reduced bone density, facet arthropathy, instability, deformity, pars defect, and at least 3-level pathology.⁸ The benefits of lateral fixation are a shorter surgical time and no patient repositioning for posterior fixation. Lateral plates reduce lateral bending significantly and also reduce axial rotation, flexion, and extension compared with LLIF cages alone.^{30,37} However, coronal vertebral body fractures have occurred in osteoporotic patients with a separate 2-hole lateral plate and unilateral pedicle screws¹⁰ and in nonosteoporotic patients with 1- and 2-level separate 2-hole lateral plates.¹¹ Separate 4-screw plates are more rigid in all motion planes³⁸ but are technically difficult to insert without causing psoas trauma and are associated with higher risk of lumbar plexus injury. Static lateral cage with integrated 2-screw fixation was initially utilized to limit cage migration after planned or inadvertent anterior longitudinal ligament disruption.³⁹ In our experience, the eLLIFp device was robust with screw lengths equal to or 10 mm less than the cage length to optimize fixation and did not require supplemental posterior pedicle screw-rod fixation.

In our eLLIFp technique, we used a drill, rather than an awl, to create holes for the integrated lateral plate screws and to navigate the superior screw and the inferior screw more accurately. We observed no misplaced screws, cage migration, screw pullout, screw fracture, or vertebral body fracture during follow-up. Likewise, no patient required secondary lateral surgery, posterior decompression, or supplemental posterior fixation at the index or adjacent levels.

The transpsoas approach is associated with anterior thigh pain, weakness, or sensory loss in 27.5% to 38.5% of patients, with the highest risk at the L4-L5 level.⁴⁰ A rising psoas sign or “Mickey Mouse”-shaped psoas muscle rising away from the vertebral column⁴¹ with a more anterior position of the lumbar plexus is associated with a higher incidence of iatrogenic plexus injury.¹⁷ In a prospective, multicenter study of over 300

LLIF procedures at L4-L5, mean retraction time was 32 minutes in patients with new postoperative symptomatic lumbar plexus neuropraxia and 23 minutes in those without.⁴² Despite longer mean retraction times for eLLIFp than for impaction of lateral static cages,⁴³ we observed low rates of anterior thigh pain and sensory changes. The majority of our eLLIFp cages was at the L2-L3 and L3-L4 levels, with only 20% at L4-L5 level. One 79-year-old female patient developed a new motor deficit postoperatively. She had a 12-month history of worsening low back pain and bilateral L4 radicular pain unresponsive to conservative treatment. Magnetic resonance imaging showed moderate central canal and lateral recess stenosis above the L4-S1 PLIF performed 4 years before. L3-L4 eLLIFp was performed, with normal IONM results pre-, intra-, and postoperatively. The patient awoke with severe right L4 radiculopathy, which improved 40% by 6 weeks and 70% by 12 months. The presumed etiology was ipsilateral lumbar plexus traction injury, given the unilateral improving weakness and sensory loss, rather than L4 nerve root tethering from scar in the lateral recesses, which would cause bilateral deficits. The low rate of anterior thigh symptoms and lumbar plexus injury using the eLLIFp in our series is multifactorial. First, an experienced lateral surgeon and operating team took great care in patient positioning to minimize the table break, thus reducing the stretch on the psoas muscle. Second, multimodal IONM detected nerve compromise earlier (compared with electromyography alone), enabling protective adjustments such as reducing table break and repositioning the initial probe and K-wire to ensure the tubular retractor is anterior to the plexus. Critically, the surgeon must directly visualize the target disc space and use triggered EMG to ensure that no nerves, particularly the femoral nerve, cross the operative field. Third, sequential opening of the tubular retractor, initially to a 22-mm diameter for discectomy and then ultimately trialing to a 25-mm diameter, accommodated the eLLIFp prosthesis. Moreover, the eLLIFp is low profile, reducing the risk of psoas muscle and nerve entrapment underneath the insertion. The integrated 2-hole plate is fixed to the cage to prevent posterior plate migration and requires less exposure compared with larger separate lateral plates.

With eLLIFp, back and leg pain improved over 90% by the time of solid fusion. These results were somewhat better than the 80% improvement reported for expandable lateral cages¹⁴ and clearly superior to the 49% to 60% improvement with static cages.^{4,8,13,19} Functional status and disability improved 47% and 69% in our

cohort, which were similar to improvements reported for static cages but lower than that reported for expandable lateral cages.¹³

Our results suggest that indirect neural decompression with eLLIFp was successful, as none of our patients required subsequent posterior direct decompression for either central or foraminal stenoses. In a prospective study of 122 consecutive patients who underwent lateral interbody fusion with impacted 10° lordotic cages, 9% required subsequent unplanned direct posterior decompression for missed unstable spondylolisthesis, bony lateral recess stenosis, or misaligned cages, resulting in contralateral foraminal encroachment.⁴³ The authors concluded that patients with neurogenic claudication and radiculopathy from spinal canal or foraminal stenosis could be successfully treated with lateral interbody fusion, but those with leg pain secondary to bony lateral recess stenosis or unstable degenerative spondylolisthesis may benefit from second-stage direct decompression and fixation.

Solid interbody fusion was achieved for 94% of eLLIFp cages on CT evaluation at 12 months. Our fusion rate was superior to fusion rates reported for stand-alone LLIF cages³³ and similar to those for LLIF cages with supplemental posterior fixation.³² A recent study proposed evaluating segmental immobilization in LLIF by both interbody and zygapophyseal joint fusion rather than anterior fusion alone.⁴⁴ We observed no significant difference in eLLIFp interbody fusion rates between 1 and 4 segment previous fusions, although the 2 nonunions in our study were both found at the L4-L5 level. We suspect the eLLIFp nonunion rate is more dependent on the specific level (L4-L5), rather than on the number of levels (1-, 2-, 3-, or 4-level) of previous posterior fusions, due to the higher biomechanical stress at the L4-L5 segment. The 2 cages in our study without bridging intertrabecular bone showed titanium endplates fused to the vertebrae and no radiolucent lines, subsidence, or screw loosening, consistent with stable locked pseudarthrosis.³² These patients also had no increased mechanical pain indicative of nonunion.

SL and PDH improved significantly from preoperatively to postoperatively and were maintained until fusion, without the need for posterior fixation. The 8 to 17 mm × 5° to 20° eLLIFp cages were expanded to an average 10 mm and 8°, which added 2.2° of SL and 2.7 mm of PDH. These were similar to the changes with static 10 mm × 10° lordotic cages, which increased SL by 2.4° and PDH by 2.6 to 2.7 mm from preoperatively to fusion.^{19,45} Expandable lateral cages with posterior fixation provide superior SL improvement and similar

PDH improvement, compared with eLLIFp. The SL difference may reflect differences in operative levels: 80% of eLLIFp cages were used at less lordotic upper lumbar levels,⁴⁶ whereas 76% of expandable lateral cages were inserted at L3-L4 and L4-L5.¹³

We found a comparative mean total cost analysis of eLLIFp (AU\$19,715) to single-level PLF, ALIF, LLIF with posterior fixation, TLIF/PLIF (range AU\$21,966–30,393) was consistent with median total US costs by the corresponding surgical approach type (range US\$18,038–29,640) for single-level lumbar fusions,⁴⁷ and the mean total cost of lumbar fusions by US national Medicare claims of US\$31,716 ± 18,124.48.⁴⁸ The proportion of our mean total costs for the 6 procedures for lumbar ASD comprising implant charges, OR charges, and hospital charges was similar to the implant, OR, and room charges reported in a cost analysis of single-level lumbar fusions at the University of California.⁴⁷ The total implant charges were lower for eLLIFp than for alternative procedures (Table 1). Additionally, eLLIFp has lower direct hospital costs with a shorter operation time and hospital length of stay than ALIF, PLF, and TLIF/PLIF.²⁵ Both eLLIFp and LLIF require IONM but no vascular access surgeon,²⁶ cell saver, or perfusionist. None of our eLLIFp patients required intensive care unit admission. These costs have external validity for surgeons in other countries to compare surgical treatment options for symptomatic ASD.

The strengths of this study include the consistent surgical technique performed by a single senior surgeon well experienced in lateral fusion procedures. Furthermore, IONM facilitated a low rate of neurological injury. CT was used for serial radiologic assessments of subsidence, SL, and PDH, with measurements performed using digital software. Additionally, thin-section CT assessments of fusion are superior to evaluating plain static and flexion-extension radiographs.⁴⁹ It is also the first study to assess efficacy and cost-effectiveness of the eLLIFp device as a stand-alone treatment in appropriately selected patients with 1 to 2 levels of ASD with minimal to no deformity.

Limitations of this study include the relatively small cohort size and intermediate duration of follow-up. Although a comparison cohort was not included, our results are consistent with those reported in the literature. Long-term follow-up of eLLIFp is planned to evaluate the incidence and timing of further ASD. In patients with significant global deformities (sagittal and/or coronal imbalance) more extensive fusion incorporating posterior fixation and osteotomies would be indicated.

CONCLUSION

This study showed that the MIS eLLIFp provided a low morbidity, cost-effective, and robust alternative to traditional posterior construct extension surgery for rostral lumbar ASD in carefully selected patients with 1- to 2-level stenosis and minimal deformity. Significant changes in SL and PDH were observed during 12-month follow-up. Significant improvements in pain, function, and disability were also demonstrated. By 12 months, there was a high rate of interbody fusion and no cases of subsidence. Expandable cage technology reduced psoas retraction, minimized endplate trauma, and permitted customized lordosis and disc height. Despite longer psoas retraction times, eLLIFp was not associated with increased risk of lumbar plexus injury. Multimodal IONM and an experienced surgeon likely contributed to this low risk. No revision lateral surgery, posterior decompression, or supplemental posterior fixation was required.

REFERENCES

1. Nakashima H, Kawakami N, Tsuji T, et al. Adjacent segment disease after posterior lumbar interbody fusion. *Spine*. 2015;40(14):E831–E841. doi:10.1097/BRS.0000000000000917
2. Sears WR, Sergides IG, Kazemi N, Smith M, White GJ, Osburg B. Incidence and prevalence of surgery at segments adjacent to a previous posterior lumbar arthrodesis. *Spine J*. 2011;11(1):11–20. doi:10.1016/j.spinee.2010.09.026
3. Okuda S, Yamashita T, Matsumoto T, et al. Adjacent segment disease after posterior lumbar interbody fusion: a case series of 1000 patients. *Global Spine J*. 2018;8(7):722–727. doi:10.1177/2192568218766488
4. Louie PK, Varthi AG, Narain AS, et al. Stand-alone lateral lumbar interbody fusion for the treatment of symptomatic adjacent segment degeneration following previous lumbar fusion. *Spine J*. 2018;18(11):2025–2032. doi:10.1016/j.spinee.2018.04.008
5. Rodgers WB, Gerber EJ, Patterson J. Intraoperative and early postoperative complications in extreme lateral interbody fusion: an analysis of 600 cases. *Spine (Phila Pa 1976)*. 2011;36(1):26–32. doi:10.1097/BRS.0b013e3181e1040a
6. Salzman SN, Shue J, Hughes AP. Lateral lumbar interbody fusion-outcomes and complications. *Curr Rev Musculoskelet Med*. 2017;10(4):539–546. doi:10.1007/s12178-017-9444-1
7. Wang MY, Vasudevan R, Mindea SA. Minimally invasive lateral interbody fusion for the treatment of rostral adjacent-segment lumbar degenerative stenosis without supplemental pedicle screw fixation. *J Neurosurg Spine*. 2014;21(6):861–866. doi:10.3171/2014.8.SPINE13841
8. Malham GM, Ellis NJ, Parker RM, et al. Maintenance of segmental lordosis and disk height in stand-alone and instrumented extreme lateral interbody fusion (XLIF). *Clin Spine Surg*. 2017;30(2):E90–E98. doi:10.1097/BSD.0b013e3182aa4c94
9. Manzur MK, Steinhaus ME, Virk SS, et al. Fusion rate for stand-alone lateral lumbar interbody fusion: a systematic review. *Spine J*. 2020;20(11):1816–1825. doi:10.1016/j.spinee.2020.06.006

10. Dua K, Kepler CK, Huang RC, Marchenko A. Vertebral body fracture after anterolateral instrumentation and interbody fusion in two osteoporotic patients. *Spine J.* 2010;10(9):e11-5. doi:10.1016/j.spinee.2010.07.007
11. Brier-Jones JE, Palmer DK, İnceoğlu S, Cheng WK. Vertebral body fractures after transpsoas interbody fusion procedures. *Spine J.* 2011;11(11):1068–1072. doi:10.1016/j.spinee.2011.07.020
12. Frisch RF, Luna IY, Brooks DM, Joshua G, O'Brien JR. Clinical and radiographic analysis of expandable versus static lateral lumbar interbody fusion devices with two-year follow-up. *J Spine Surg.* 2018;4(1):62–71. doi:10.21037/jss.2018.03.16
13. Li YM, Frisch RF, Huang Z, et al. Comparative effectiveness of laterally placed expandable versus static interbody spacers: a 1-year follow-up radiographic and clinical outcomes study. *Asian Spine J.* 2021;15(1):89–96. doi:10.31616/asj.2019.0260
14. Li YM, Frisch RF, Huang Z, et al. Comparative effectiveness of expandable versus static interbody spacers via MIS LLIF: a 2-year radiographic and clinical outcomes study. *Global Spine J.* 2020;10(8):998–1005. doi:10.1177/2192568219886278
15. Kim C, Harris JA, Muzumdar A, et al. The effect of anterior longitudinal ligament resection on lordosis correction during minimally invasive lateral lumbar interbody fusion: Biomechanical and radiographic feasibility of an integrated spacer/plate interbody reconstruction device. *Clin Biomech (Bristol, Avon).* 2017;43:102–108. doi:10.1016/j.clinbiomech.2017.02.006
16. Schwab F, Ungar B, Blondel B, et al. Scoliosis research society-schwab adult spinal deformity classification: a validation study. *Spine (Phila Pa 1976).* 2012;37(12):1077–1082. doi:10.1097/BRS.0b013e31823e15e2
17. Kepler CK, Bogner EA, Herzog RJ, Huang RC. Anatomy of the psoas muscle and lumbar plexus with respect to the surgical approach for lateral transpsoas interbody fusion. *Eur Spine J.* 2011;20(4):550–556. doi:10.1007/s00586-010-1593-5
18. Boden SD, Kang J, Sandhu H, Heller JG. Use of recombinant human bone morphogenetic protein-2 to achieve posterolateral lumbar spine fusion in humans. *Spine.* 2002;27(23):2662–2673. doi:10.1097/00007632-200212010-00005
19. Malham GM, Parker RM, Blecher CM, Chow FY, Seex KA. Choice of approach does not affect clinical and radiologic outcomes: a comparative cohort of patients having anterior lumbar interbody fusion and patients having lateral lumbar interbody fusion at 24 months. *Global Spine J.* 2016;6(5):472–481. doi:10.1055/s-0035-1569055
20. Trattner S, Pearson GDN, Chin C, et al. Standardization and optimization of CT protocols to achieve low dose. *J Am Coll Radiol.* 2014;11(3):271–278. doi:10.1016/j.jacr.2013.10.016
21. Williams AL, Gornet MF, Burkus JK. CT evaluation of lumbar interbody fusion: current concepts. *AJNR Am J Neuroradiol.* 2005;26(8):2057–2066.
22. Malham GM, Parker RM, Blecher CM, Seex KA. Assessment and classification of subsidence after lateral interbody fusion using serial computed tomography. *J Neurosurg Spine.* 2015;23(5):589–597. doi:10.3171/2015.1.SPINE14566
23. AGDo H. Private Health Insurance Prostheses List, Prostheses List—Part A. 2020.
24. Mizumoto R, Cristaudo AT, Hendaheba R. A surgeon-led model to improve operating theatre change-over time and overall efficiency: A randomised controlled trial. *Int J Surg.* 2016;30(83–89):83–89. doi:10.1016/j.ijsu.2016.04.033
25. Government VS. *Overnight Stays, Accommodation Fees (2020-2021).* <https://www2.health.vic.gov.au/hospitals-and-health-services/patient-fees-charges/admitted-patients/private-patients/overnight-stays>.
26. Health AGDo. Medicare Benefits Schedule, Complete MBS. 2020.
27. Goldstein CL, Macwan K, Sundararajan K, Rampersaud YR. Perioperative outcomes and adverse events of minimally invasive versus open posterior lumbar fusion: meta-analysis and systematic review. *J Neurosurg Spine.* 2016;24(3):416–427. doi:10.3171/2015.2.SPINE14973
28. Zhang C, Berven SH, Fortin M, Weber MH. Adjacent segment degeneration versus disease after lumbar spine fusion for degenerative pathology. *Clin Spine Surg.* 2016;29(1):21–29. doi:10.1097/BSD.0000000000000328
29. Burch MB, Wiegers NW, Patil S, Nourbakhsh A. Incidence and risk factors of reoperation in patients with adjacent segment disease: a meta-analysis. *J Craniovertebr Junction Spine.* 2020;11(1):9–16. doi:10.4103/jcvjs.JCVJS_10_20
30. Cappuccino A, Cornwall GB, Turner AWL, et al. Biomechanical analysis and review of lateral lumbar fusion constructs. *Spine (Phila Pa 1976).* 2010;35(26 Suppl):S361-7. doi:10.1097/BRS.0b013e318202308b
31. Grant JP, Oxland TR, Dvorak MF. Mapping the structural properties of the lumbosacral vertebral endplates. *Spine (Phila Pa 1976).* 2001;26(8):889–896. doi:10.1097/00007632-200104150-00012
32. Waddell BS, Briski DC, Zavatsky JM. Lateral lumbar interbody fusion for the correction of spondylolisthesis and adult degenerative scoliosis in high-risk patients: early results and complications. *Global Spine J.* 2017;5(1_suppl):s-0035. doi:10.1055/s-0035-1554259
33. Marchi L, Abdala N, Oliveira L, Amaral R, Coutinho E, Pimenta L. Radiographic and clinical evaluation of cage subsidence after stand-alone lateral interbody fusion. *J Neurosurg Spine.* 2013;19(1):110–118. doi:10.3171/2013.4.SPINE12319
34. Tempel ZJ, Gandhoke GS, Okonkwo DO, Kanter AS. Impaired bone mineral density as a predictor of graft subsidence following minimally invasive transpsoas lateral lumbar interbody fusion. *Eur Spine J.* 2015;24 Suppl 3(S3):414–419. doi:10.1007/s00586-015-3844-y
35. Tohmeh AG, Khorsand D, Watson B, Zielinski X. Radiographical and clinical evaluation of extreme lateral interbody fusion. *Spine.* 2014;39(26):E1582–E1591. doi:10.1097/BRS.0000000000000645
36. Le TV, Baaj AA, Dakwar E, et al. Subsidence of polyetheretherketone intervertebral cages in minimally invasive lateral retroperitoneal transpsoas lumbar interbody fusion. *Spine (Phila Pa 1976).* 2012;37(14):1268–1273. doi:10.1097/BRS.0b013e3182458b2f
37. Shasti M, Koenig SJ, Nash AB, et al. Biomechanical evaluation of lumbar lateral interbody fusion for the treatment of adjacent segment disease. *Spine J.* 2019;19(3):545–551. doi:10.1016/j.spinee.2018.09.002
38. Wang MY, Sama AA, Uribe JS. *Lateral Access Minimally Invasive Spine Surgery.* Cham: Springer International Publishing; 2016:259–264. <http://link.springer.com/10.1007/978-3-319-28320-3>. doi:10.1007/978-3-319-28320-3
39. Godzik J, Pereira B de A, Hemphill C, et al. Minimally invasive anterior longitudinal ligament release for anterior column realignment. *Global Spine J.* 2020;10(2 Suppl):101S-110S. doi:10.1177/2192568219880178

40. Salzmann SN, Shirahata T, Okano I, et al. Does L4-L5 pose additional neurologic risk in lateral lumbar interbody fusion? *World Neurosurg*. 2019;129:e337–e342. doi:10.1016/j.wneu.2019.05.144
41. Voyadzis JM, Felbaum D, Rhee J. The rising psoas sign: an analysis of preoperative imaging characteristics of aborted minimally invasive lateral interbody fusions at L4-5. *J Neurosurg Spine*. 2014;20(5):531–537. doi:10.3171/2014.1.SPINE13153
42. Uribe JS, Isaacs RE, Youssef JA, et al. Can triggered electromyography monitoring throughout retraction predict postoperative symptomatic neuropraxia after XLIF? Results from a prospective multicenter trial. *Eur Spine J*. 2015;24 Suppl 3(S3):378–385. doi:10.1007/s00586-015-3871-8
43. Malham GM, Parker RM, Goss B, Blecher CM. Clinical results and limitations of indirect decompression in spinal stenosis with laterally implanted interbody cages: results from a prospective cohort study. *Eur Spine J*. 2015;24 Suppl 3(S3):339–345. doi:10.1007/s00586-015-3807-3
44. Proietti L, Perna A, Ricciardi L, et al. Radiological evaluation of fusion patterns after lateral lumbar interbody fusion: institutional case series. *Radiol Med*. 2021;126(2):250–257. doi:10.1007/s11547-020-01252-5
45. Malham GM, Parker RM, Goss B, Blecher CM, Ballok ZE. Indirect foraminal decompression is independent of metabolically active facet arthropathy in extreme lateral interbody fusion. *Spine (Phila Pa 1976)*. 2014;39(22):E1303-10. doi:10.1097/BRS.0000000000000551
46. Damasceno LHF, Catarin SRG, Campos AD, Defino HLA. Lordose lombar: estudo dos valores angulares e da participação dos corpos vertebrais e discos intervertebrais. *Acta ortop bras*. 2006;14(4):193–198. doi:10.1590/S1413-78522006000400003
47. Beckerman D, Esparza M, Lee SI, et al. Cost analysis of single-level lumbar fusions. *Global Spine J*. 2020;10(1):39–46. doi:10.1177/2192568219853251
48. Malik AT, Phillips FM, Yu E, Khan SN. Are current DRG-based bundled payment models for lumbar fusions risk-adjusting adequately? An analysis of medicare beneficiaries. *Spine J*. 2020;20(1):32–40. doi:10.1016/j.spinee.2019.04.024
49. Morimoto T, Kobayashi T, Mawatari M. Letter to the editor concerning “comparison of stand-alone lateral lumbar interbody fusion versus open laminectomy and posterolateral instrumented fusion in the treatment of adjacent segment disease following previous lumbar fusion surgery” by Louie et al. *Spine (Phila Pa 1976)*. 2020;45(17):E1132. doi:10.1097/BRS.0000000000003590

Funding: The authors received no financial support for the research, authorship, and/or publication of this article.

Declaration of Conflicting Interests: The authors report no conflicts of interest in this work.

Disclosures: Gregory M. Malham reports speaking/teaching and trips/travel arrangements with Device, Globus Medical, LifeHealthcare, and National Surgical and consulting fees from Globus Medical. The remaining authors have nothing to report.

Ethics Approval: Epworth HealthCare, Professor Nikolas Zeps, Group Director of Research and Development, nik.zeps@epworth.org.au

Corresponding Author: Gregory M. Malham, Suite 8.3, Epworth Hospital, 89 Bridge Rd, Richmond, Melbourne, VIC 3121, Australia; gmalham@bigpond.net.au

Published 13 June 2022

This manuscript is generously published free of charge by ISASS, the International Society for the Advancement of Spine Surgery. Copyright © 2022 ISASS. To see more or order reprints or permissions, see <http://ijssurgery.com>.