

Sagittal Plane Geometry of Cervical, Thoracic, and Lumbar Endplates

Rangel Roberto de Assis, Marcello Nogueira Barbosa and Helton L.A. Defino

Int J Spine Surg 2022, 16 (5) 792-799

doi: <https://doi.org/10.14444/8336>

<https://www.ijssurgery.com/content/16/5/792>

This information is current as of May 2, 2025.

Email Alerts Receive free email-alerts when new articles cite this article. Sign up at:
<http://ijssurgery.com/alerts>

Sagittal Plane Geometry of Cervical, Thoracic, and Lumbar Endplates

RANGEL ROBERTO DE ASSIS, MD¹; MARCELLO NOGUEIRA BARBOSA, MD, PhD²; AND HELTON L.A. DEFINO, MD, PhD¹

¹Department of Orthopedics and Anesthesiology, Ribeirão Preto Medical School - São Paulo University, São Paulo, Brazil; ²Department of Medical Imaging, Hematology and Clinical Oncology, Ribeirão Preto Medical School - São Paulo University, São Paulo, Brazil

ABSTRACT

Background: Many studies have emphasized the importance of interface contact between implants and the vertebral endplate (VE). The goal of this study was to analyze the shape and other specific parameters of the VE to provide reference data for better implant interface contact in intervertebral disc space procedures.

Methods: Cervical, thoracic, and lumbar spine midsagittal plane magnetic resonance images of 100 adults (58 women) were analyzed. The morphology of the VEs was classified as concave, convex, flat, or irregular. Midsagittal endplate length (ML), endplate concavity depth (ECD), and endplate concavity axis (ECA) location were measured in the midsagittal plane. The parameters were compared between the cervical, thoracic, and lumbar spines and between the sexes.

Results: The VE morphology, ML, ECD, and ECA showed variations along the spine, mainly in the cervical and lower lumbar spines. The sagittal geometry of the VE was not flat or uniform along the cervical, thoracic, and lumbar spines. Different morphological types were observed along different spinal segments and according to sex. In the cervical spine, the majority of cranial VEs were flat, while caudal VEs were mostly concave.

Conclusion: Sagittal VE geometry should be taken into consideration during the use of intervertebral cages or disc arthroplasty.

Biomechanics

Keywords: sagittal geometry, endplate, MRI, cervical, thoracic, lumbar spine

INTRODUCTION

The vertebral endplate (VE) lies between the vertebral body subchondral bone and the intervertebral disc (ID).^{1,2} The VE surrounds the cranial and caudal interface between the ID and vertebral body of all vertebrae, except C1-C2 and L5-S1.¹ Besides its biological function, the VE absorbs the mechanical load of the spine³ and prevents the bulging of the nucleus pulposus of the ID into the vertebral body.² It also plays an important role in surgical procedures. Surgical procedures involving VE are usually related to ID removal and are frequently performed to decompress neural elements, and for sagittal balance correction, spine stabilization, and replacement of degenerated ID using artificial IDs.^{4,5} Cervical fusion and cervical disc replacement involve artificial devices such as disc prostheses or cages.^{6,7} Complications such as subsidence, shift, and migration have been reported with the use of cages and artificial discs.^{1,4,8} The mismatch between VE shape and implant contact surface has been reported as the main cause of complications.^{4,7,9}

This study was designed considering the importance of VE shape and geometry in the design of artificial

devices used in spinal surgery, as well as the lack of data on VE shape and geometry.^{8,9} The ideal artificial disc or cage should have a maximal endplate-device interface contact area so that it can mirror the shape of the cranial and caudal VE in all 3 dimensions.^{7,9} The goal of this study was to analyze VE shape and specific sagittal parameters of the cervical, thoracic, and lumbar spine to provide reference data for cages and artificial prostheses.

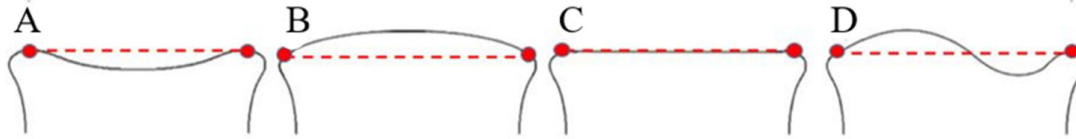
METHODS

Ethical approval was granted by the institutional research ethics committee and was carried out in accordance with the Helsinki Declaration of 1975, as revised in 2000. The requirement for written consent from patients was waived due to the retrospective nature of the study. A total of 100 patients (42 men and 58 women) ranging in age from 18 to 59 years (mean 31.44 ± 9.10) underwent magnetic resonance imaging (MRI) (33 cervical, 32 thoracic, and 35 lumbar) for reasons unrelated to the study and were retrospectively selected for analysis. Patients with normal MRI were included. Cases with MRI evidence or clinical history of fracture,

Table. Patient distribution according to age, gender, and spinal segment.

Segment	<i>n</i>	Age, y, Mean \pm SD	Gender: <i>n</i> (%)
Cervical	33	29.45 \pm 9.62	M: 16 (48.5); F: 17 (51.5)
Thoracic	32	30.94 \pm 7.29	M: 11 (34.4); F: 21 (65.6)
Lumbar	35	33.77 \pm 9.8	M: 16 (45.7); F: 19 (54.3)

Abbreviations: F, female; M, male.

**Figure 1.** Types of vertebral endplates (VEs) according to the morphology: (A) concave, (B) convex, (C) flat, and (D) irregular. In the flat type, the entire extension of the VE was contained in the line that joined the anterior and posterior corners of the vertebral body. In the concave type, the deepest part of the VE was located at least 1 mm deep in relation to the line that joined the anterior and posterior corners of the vertebral body. In the convex type, part of the plate was located at least 1 mm from the reference line. In the irregular type, the plate was at least one point above and one point below the reference line. The nomenclature describing the cranial and caudal VEs refers to the vertebral body. Cranial VEs are on the cranial side and the caudal endplates are on the caudal side of the vertebral body.

tumor, deformity, infection, congenital abnormalities, advanced degenerative process of the articular or ID, prior surgery, or evidence of osteoporosis were excluded. The distribution of patients according to age, sex, and involved segment of the spine is shown in the Table.

Measurements

Spine MRI was performed using a 1.5T scanner (Achieva; Philips Healthcare, Best, The Netherlands) with a 16-channel spine coil (SENSE-SPINE; Philips). K-PACS DICOM viewer software v1.6.0 (IMAGE Information Systems, Rostock, Germany) was used to anonymize data and for posterior image analysis and measurements. Measurements were performed on the midsagittal plane. Evaluation and measurements were performed by an independent orthopedic spine surgeon and a blinded observer. All cranial and caudal VEs from C3-L5 were evaluated, except C2 and S1. Caudal VE was evaluated at C2 and cranial VE at S1. The cranial

or caudal reference for VE was established according to VE location on the vertebral body.

The selected parameters for evaluation were VE shape, midsagittal length (ML), endplate concavity depth (ECD), and endplate concavity axis (ECA) location (Figures 1 and 2). The VEs were classified into 4 types according to morphology: flat, concave, convex, or irregular (described in Figure 1).^{7,10–13} The ML was defined as the distance between the anterior and posterior border of the VE in the midsagittal plane. The ECD was defined as the distance between the perpendicular line from the anterior to posterior rim of the VE on the sagittal plane to the deepest point of the VE. The ECA location was defined as the point anterior or posterior to the midpoint of the line from the anterior to posterior rim of the VE on the sagittal plane.

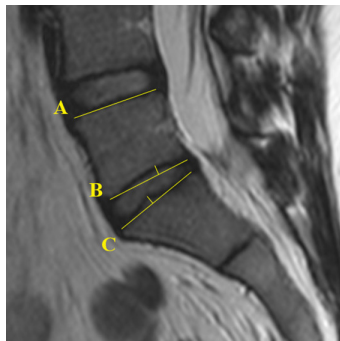Statistical Methods

Statistical analyses were conducted using SAS version 9.4 (SAS Institute Inc., Cary, NC, USA). Descriptive statistics (means and SD) were used for quantitative variables. Analysis of variance, Student *t* tests, and Fisher's exact tests were used for comparisons. The significance level was set at $P < 0.05$.

RESULTS

Cervical Spine

The VE shape differed on the cranial and caudal sides of the same vertebrae. The concave shape was more common in caudal VEs along the cervical spine in both the sexes. In cranial VEs, the flat shape was the most

**Figure 2.** Sagittal magnetic resonance imaging of lumbar spine illustrating (A) flat, (B) concave, and (C) convex vertebral endplates.

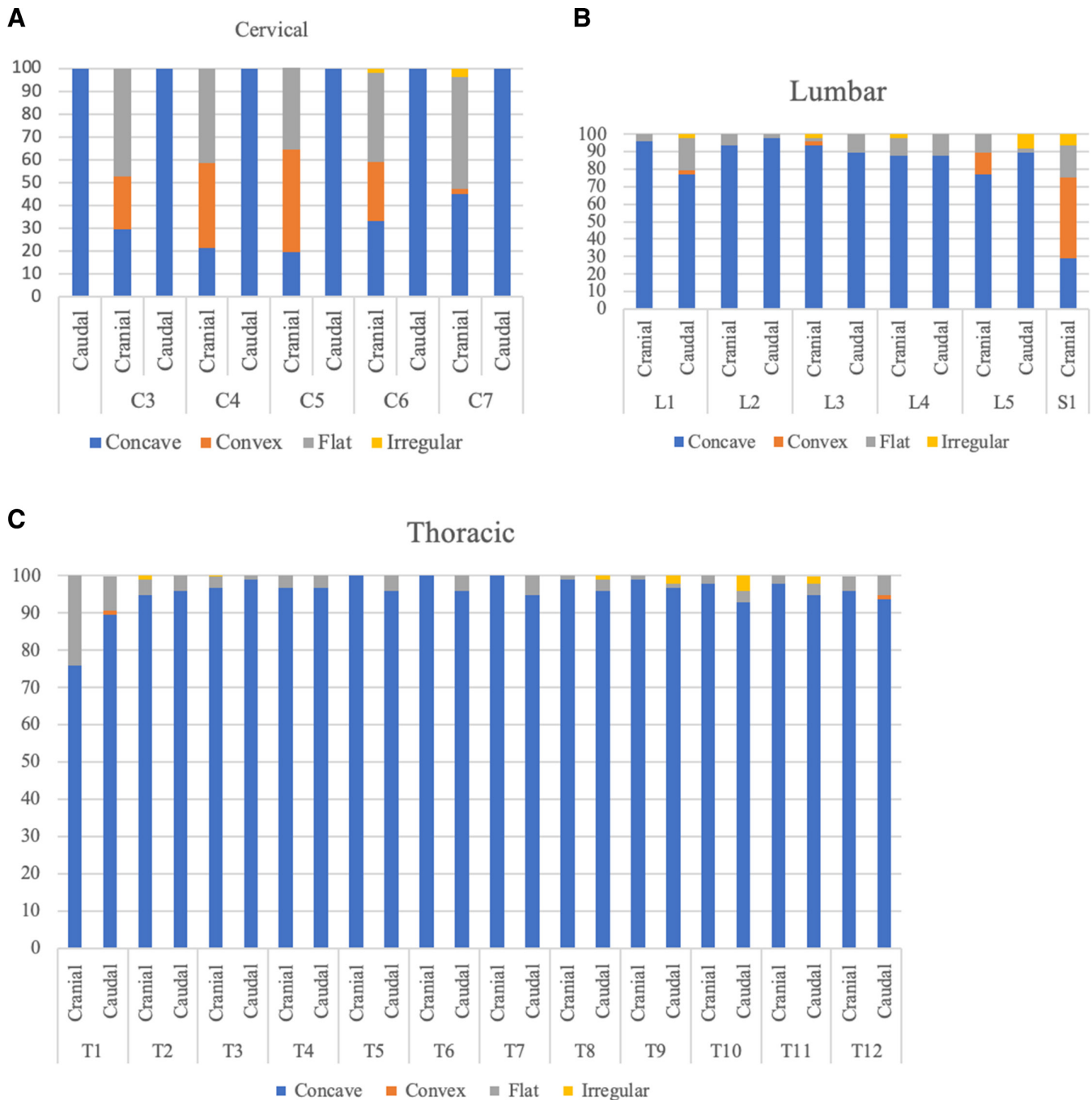


Figure 3. Distribution of vertebral endplate shapes in the cervical, lumbar, and thoracic spines.

common in both the sexes. The flat shape was more common in cranial VEs of men, and the convex type was more common in women ($P = 0.0119$; Figure 3).

The ML increased in the cranio-caudal direction in both the sexes. The ML value ranged from 8.10 to 18.40 mm (mean, 12.86 ± 1.30 mm in cranial VEs and from 8.10 to 18.70 mm in caudal VEs. The values for women were significantly smaller than those of men ($P < 0.001$), including cranial VE ($P < 0.0001$; Figure 4).

The ECD ranged from -2.4 to 5.10 mm (mean 1.15 ± 0.42 mm). Negative values were considered in VEs with a convex shape. There was a decrease in values in a cranio-caudal direction. In men, the ECD was higher in caudal VEs than cranial VEs ($P = 0.026$; Figure 5).

The ECA location in caudal VEs was the posterior half of the endplate in both the sexes. In cranial VEs, a posterior location was less common, and the

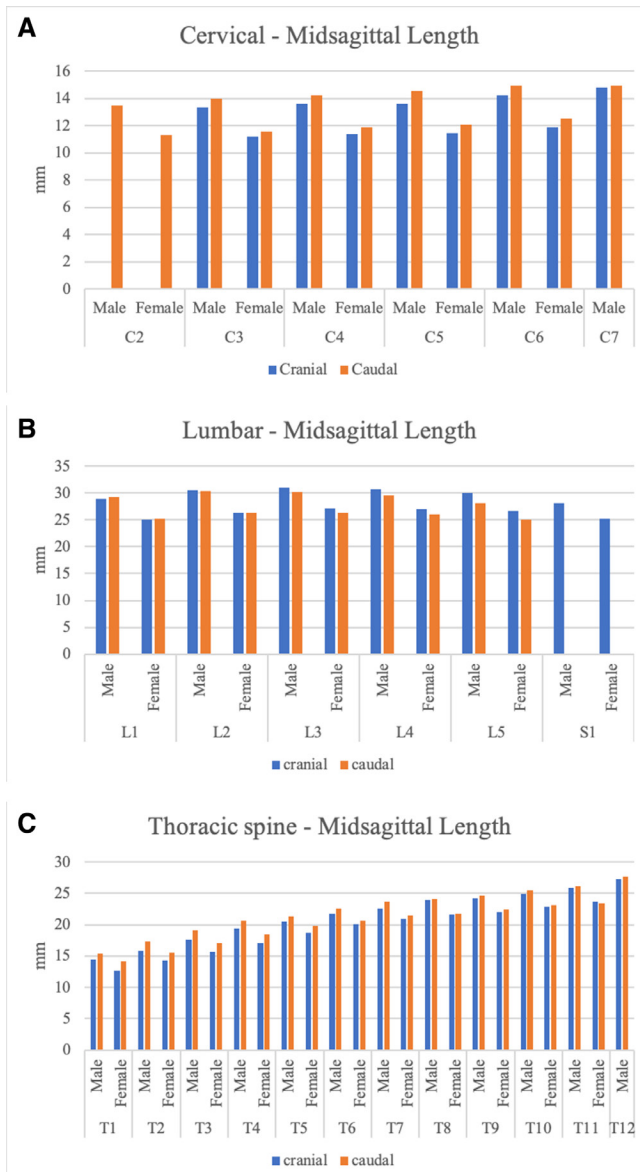


Figure 4. Midsagittal length in the cervical, lumbar, and thoracic spine.

majority could not be defined due to the flat VE shape or its location at the anterior half of the endplate (Figure 6).

Thoracic Spine

Overall, the concave shape was the most common shape in cranial (96.26%) and caudal VEs (95.39%). There was no statistical difference between cranial and caudal VEs according to sex ($P = 0.718$; Figure 3).

The ML varied from 10.7 to 34 mm (mean 20.57 ± 4.27 mm) and showed an increase in the cranio-caudal direction. Values for women were significantly smaller than for men ($P < 0.01$). Cranial VEs were significantly smaller than caudal VEs ($P < 0.0001$; Figure 4).

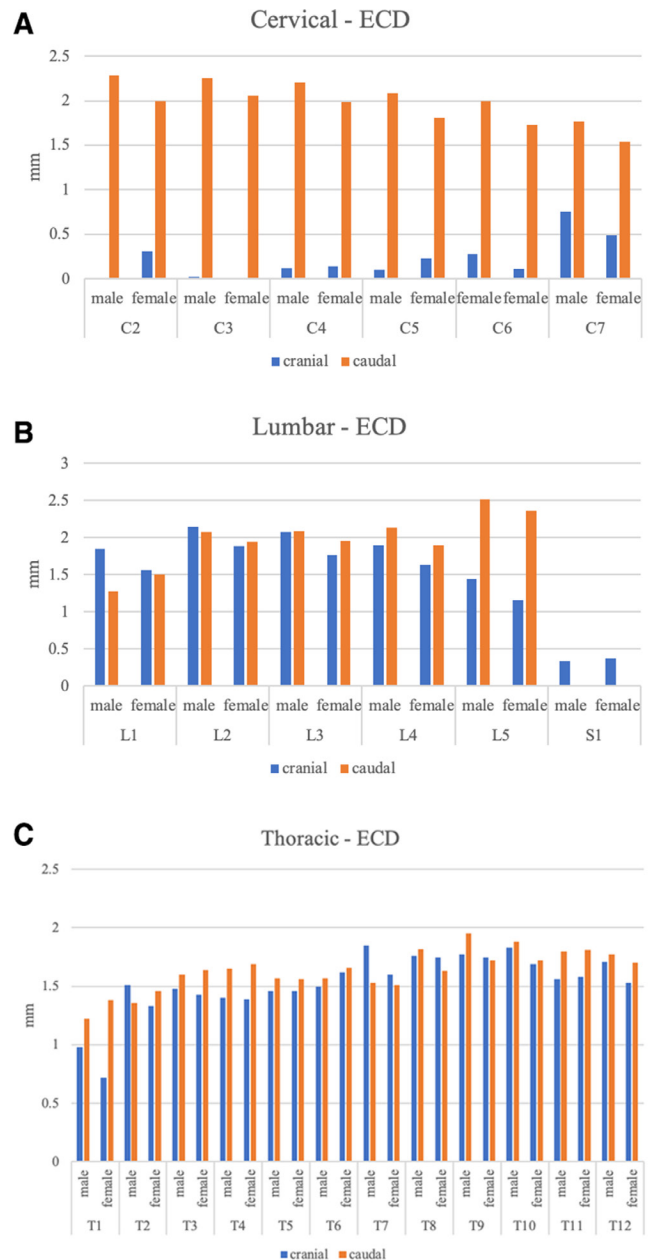


Figure 5. Endplate concavity depth (ECD) in the cervical, lumbar, and thoracic spine.

The ECD tended to increase from T1 to T8, and from there, it decreased. There was no difference between cranial and caudal VEs according to sex ($P = 0.0642$) (Figure 5). The ECA in the thoracic spine tended to be located in the posterior half of the VE in the proximal and distal third and anterior to the half of the VE in the middle of the thoracic spine (Figure 6).

Lumbar Spine

In the lumbar spine, the concave type was the most common in cranial and caudal VEs, except in S1. From

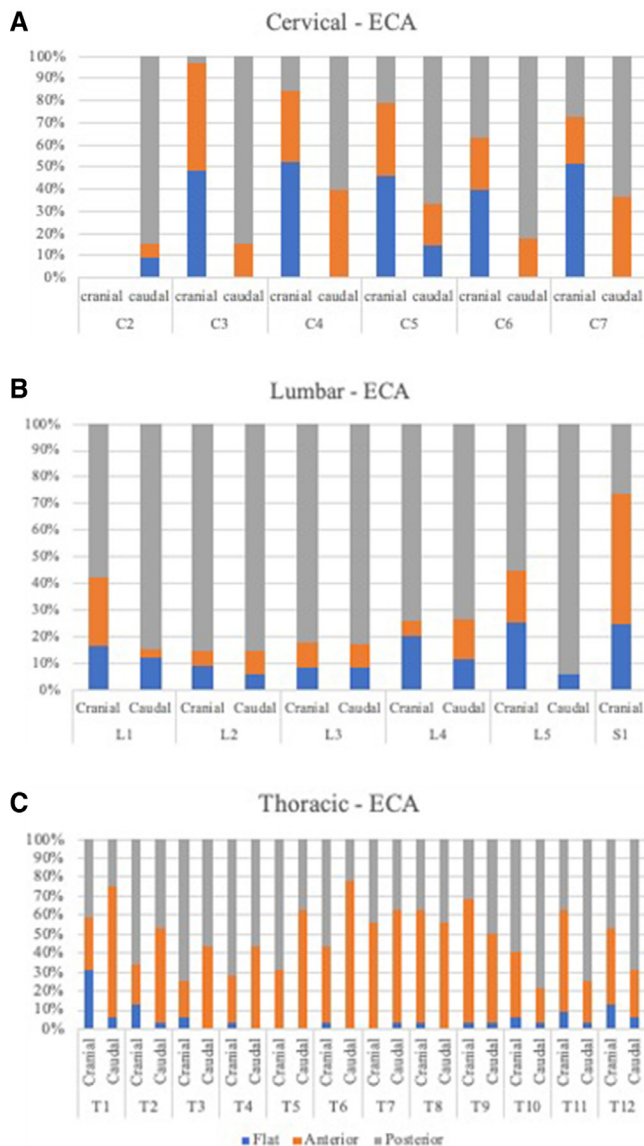


Figure 6. Endplate concavity axis (ECA) in the cervical, lumbar, and thoracic spine.

L1 to L5, the concave type was most common. There was a significantly different pattern at S1. Prevalence of the concave type dropped at S1, and the convex and flat types became the most common. The irregular type showed an increase at L5 and S1 levels. There was no statistical difference in morphological VE type between men and women ($P = 0.711$; Figure 3).

The ML ranged from 18 to 40.5 mm (mean 27.72 ± 3.59 mm), increased from L1 to L4, and decreased from L4 to S1. There was no difference between the cranial and caudal VE ML ($P = 0.079$). The ML was significantly greater in men ($P < 0.01$; Figure 4).

The ECD of cranial and caudal VEs tended to increase from L1 to L3 and decrease from L3 to S1, except for the L5 caudal VE, which increased. A significant decrease was

observed at S1. Overall, ECD values were significantly smaller in women ($P < 0.001$; Figure 5).

The ECA of cranial and caudal VEs was more commonly located in the posterior middle, except at S1. There was no statistical difference between men and women (Figure 6).

DISCUSSION

Our findings confirm that VEs are not flat structures and VE shape varies along different spine segments. There is an asymmetry between 2 adjacent endplates of the same ID, which is most marked in the cervical spine. In the thoracic spine, a more even distribution of VE shapes is observed and a concave VE shape is observed in almost all cranial and caudal VEs.

The morphological asymmetry of VE in the ID space is important in clinical practice as there is often a considerable mismatch between the endplate surface and the footprint of the prosthetic discs when replacement or fusion (anterior interbody fusion) is performed.^{8,14} Complications such as device migration and subsidence are related to the mismatch between the endplate and implant contact surface.^{6,8,15–18} Therefore, discrepancies between the design of current disc prostheses and the anatomic dimensions and shape of VEs prevent ideal contact, and the VE must be prepared or flattened, reducing its ability to withstand pressure, leading to subsidence.^{19,20} Devices used in the ID space are flat or have minor convexity,¹⁹ and they are oversimplified compared to the morphological complexity of VEs.^{12,19} Incorporation of different endplate shapes and sizes into the design of devices used in the ID space may avoid mismatch and complications.^{6,14}

In the cervical spine, the 2 VEs of the iID space showed marked asymmetry. Most cranial VEs were flat, while almost all caudal VEs were concave. Both these findings are consistent with other studies.^{8,11} The convex shape of VEs observed in the cranial VE of the cervical spine has not been reported in similar studies, possibly because of the criteria and anatomical references used to define VE shape.^{7,8,11} An increase in ML of the VE was observed in the cranio-caudal direction, and the values were significantly smaller in women, consistent with other reports.^{7,21} Linear parameters reportedly differ according to race (between Chinese, Korean, Singaporean, and Caucasian) with the cervical vertebrae of Caucasians being larger.⁸

Although sex differences in ECD have not been observed in some studies,^{8,19} we observed a significant difference according to sex, mainly in the cervical and lumbar spines, except at S1. We also observed an increase in ECD in the cranio-caudal direction, except at S1. The decrease in ECD at S1 in our study was related to VE shape. The concave shape was least common at this level.

Our finding that the ECA was located posteriorly in the cervical spine in the majority of caudal VEs, and even in cranial VEs, was consistent with Feng et al⁸ and Cheng et al.¹⁹

Morphometric data on the thoracic spine are less commonly reported compared to the cervical and lumbar spines, even though it carries clinical importance in terms of surgical implant design. In the thoracic spine, a concave VE shape was most frequent in cranial and caudal VEs, with an even distribution along the thoracic spine. The most homogeneous distribution of VE shapes was observed in the thoracic spine. Almost all intervertebral thoracic discs were surrounded at the cranial and caudal surface by concave VEs. Our findings were in accordance with Chen et al who reported an increase in ML from the cranial to caudal VE and significantly smaller values in women.²² There was a tendency for a posterior ECA location except at the apex of the thoracic kyphosis. Van der Houwen et al and Chen et al also indicated that endplates toward T12 show a tendency toward a posterior ECA.^{4,22}

In the lumbar spine, the concave-shaped VEs were most common, except at S1. The concave-shaped VE was also the most common shape reported by Lakshmanan et al and Van der Houwen et al.^{4,12} At S1, the convex shape was most common. We did not observe the higher flat shape at S1 reported by Lakshmanan et al⁴ who reported no convex-shaped VEs, but they considered a dome-shaped S1 as flat in some cases. Furthermore, in the lumbar spine, a marked change in shape pattern and other linear parameters was observed at L5 and S1. Remarkable morphological differences in some anatomical parameters of L5 compared with other lumbar vertebrae were also observed in anatomical studies utilizing linear and nonlinear regression analyses.²³ The morphological differences between L5 and S1 have been attributed to anatomical transition position.^{23,24}

The ML of VEs showed an increase in a cranio-caudal direction from C2 to L4 and a decrease from L4 to S1. Kishimoto et al also reported a decrease in the anterior-posterior endplate at L5-S1 using 3-dimensional “in vivo” measurements.²¹

In our study, the highest average ECD in the lumbar spine was found in L5 caudal VEs, and this finding was consistent with Lakshmanan et al⁴ who also reported a posterior ECA location in the lower lumbar spine, which was consistent with our results, except at S1.¹² Endplates toward T12 showed a tendency toward a posterior ECA.^{4,19} There is no known

explanation for ECA location or differences in ECD between cranial and caudal VEs.

The findings concerning shape, ML, concavity depth, and concavity depth axis location at L5-S1 have potential clinical relevance considering that most fusion or disc replacement surgeries of the lumbar spine involve these anatomical segments.^{15,19} Devices used in the ID space should have adequate shape and dimension to adapt to the adjacent VE and avoid a mismatch between the device and endplate interface. Endplate preparation with partial or complete excision to adapt to the devices weakens the compressive strength of the vertebral body, and this should be avoided.^{15,19}

Van der Houwen et al reported that inferior lumbar VEs have a larger depth than superior ones in the same space.⁴ We found the same results from L3 to the caudal lumbar spine. This asymmetry, which was also observed in other segments of the spine, cannot be explained based on biomechanical principles of ID pressure, which should be the same on both adjacent endplates for equal load distribution.⁴

The current study had some limitations. First, we only evaluated sagittal parameters and did not consider different age groups, the coronal plane, or surface area. Furthermore, the imaging method used is inferior to more sophisticated 3-dimensional evaluations.^{8,25} However, so far there are no available data in our country related to VE geometry, and the data from our study provide preliminary information for implant design and improvements in implantation techniques in the intervertebral space. More accurate information should be obtained from further studies using different methods and evaluation of different parameters, age groups, and degenerative discs. A surgical cohort of patients should also be studied. Lakshmanan et al reported that VE shape changes in patients with advanced disc degeneration and those who undergo surgery may present with different shapes.⁴

The sagittal morphology of the VE is significantly variable over all spine segments, mainly in the cervical and lumbar spines. The common surgical sites of anterior spine fusion or disc replacement present marked morphological changes that should be considered in the use of ID devices. The incorporation of endplate shapes and sizes into device design may avoid mismatch and resultant complications.

CONCLUSION

The VE morphology shows variations along the spine. The sagittal geometry of the VE is not flat and uniform along the cervical, thoracic, and lumbar spines. Different morphological types are observed along spine segments and between sexes, mainly in the cervical and lower lumbar spines. Sagittal VE geometry should be considered during the use of intervertebral cages or disc arthroplasty.

ACKNOWLEDGMENTS

We would like to thank the staff of Professor Helton Luis Aparecido Defino and orthopediacs department at the Clinical Hospital of Ribeirão Preto for their contribution to this study.

REFERENCES

- Humzah MD, Soames RW. Human intervertebral disc: structure and function. *Anat Rec*. 1988;220(4):337–356. doi:10.1002/ar.1092200402
- Lotz JC, Fields AJ, Liebenberg EC. The role of the vertebral end plate in low back pain. *Global Spine J*. 2013;3(3):153–164. doi:10.1055/s-0033-1347298
- Moore RJ. The vertebral end-plate: what do we know? *Eur Spine J*. 2000;9(2):92–96. doi:10.1007/s005860050217
- van der Houwen EB, Baron P, Veldhuizen AG, Burgerhof JGM, van Ooijen PMA, Verkerke GJ. Geometry of the intervertebral volume and vertebral endplates of the human spine. *Ann Biomed Eng*. 2010;38(1):33–40. doi:10.1007/s10439-009-9827-6
- Peng B, Chen J, Kuang Z, Li D, Pang X, Zhang X. Diagnosis and surgical treatment of back pain originating from endplate. *Eur Spine J*. 2009;18(7):1035–1040. doi:10.1007/s00586-009-0938-4
- Chen H, Zhong J, Tan J, Wu D, Jiang D. Sagittal geometry of the middle and lower cervical endplates. *Eur Spine J*. 2013;22(7):1570–1575. doi:10.1007/s00586-013-2791-8
- Lou J, Liu H, Rong X, Li H, Wang B, Gong Q. Geometry of inferior endplates of the cervical spine. *Clin Neurol Neurosurg*. 2016;142:132–136. doi:10.1016/j.clineuro.2016.01.027
- Feng H, Fang X-Y, Huang D-G, et al. A morphometric study of the middle and lower cervical vertebral endplates and their components. *Medicine (Baltimore)*. 2017;96(10):e6296. doi:10.1097/MD.00000000000006296
- Zhu Y-H, Cheng K-L, Zhong Z, Li Y-Q, Zhu Q-S. Morphologic evaluation of chinese cervical endplate and uncinat process by three-dimensional computed tomography reconstructions for helping design cervical disc prosthesis. *J Chin Med Assoc*. 2016;79(9):500–506. doi:10.1016/j.jcma.2016.04.003
- Wang Y, Battié MC, Videman T. A morphological study of lumbar vertebral endplates: radiographic, visual and digital measurements. *Eur Spine J*. 2017;21(11):2316–2323. doi:10.1007/s00586-012-2415-8
- Zhao S, Hao D, Jiang Y, Huang D, Ge C, Feng H. Morphological studies of cartilage endplates in subaxial cervical region. *Eur Spine J*. 2016;25(7):2218–2222. doi:10.1007/s00586-015-4336-9
- Lakshmanan P, Purushothaman B, Dvorak V, Schratz W, Thambiraj S, Boszczyk M. Sagittal endplate morphology of the lower lumbar spine. *Eur Spine J*. 2012;21(suppl 2):S160–S164. doi:10.1007/s00586-012-2168-4
- Louie PK, Espinoza Orías AA, Fogg LF, et al. Changes in lumbar endplate area and concavity associated with disc degeneration. *Spine (Phila Pa 1976)*. 2018;43(19):E1127–E1134. doi:10.1097/BRS.0000000000002657
- Thaler M, Hartmann S, Gstöttner M, Lechner R, Gabl M, Bach C. Footprint mismatch in total cervical disc arthroplasty. *Eur Spine J*. 2013;22(4):759–765. doi:10.1007/s00586-012-2594-3
- Polikeit A, Ferguson SJ, Nolte LP, Orr TE. The importance of the endplate for interbody cages in the lumbar spine. *Eur Spine J*. 2003;12(6):556–561. doi:10.1007/s00586-003-0556-5
- Buttermann GR, Beaubien BP, Freeman AL, Stoll JE, Chapuis JL. Interbody device endplate engagement effects on motion segment biomechanics. *Spine J*. 2009;9(7):564–573. doi:10.1016/j.spinee.2009.03.014
- Barsa P, Suchomel P. Factors affecting sagittal malalignment due to cage subsidence in standalone cage assisted anterior cervical fusion. *Eur Spine J*. 2007;16(9):1395–1400. doi:10.1007/s00586-006-0284-8
- Cabraja M, Oezdemir S, Koeppen D, Kroppenstedt S. Anterior cervical discectomy and fusion: comparison of titanium and polyetheretherketone cages. *BMC Musculoskelet Disord*. 2012;13:172. doi:10.1186/1471-2474-13-172
- Cheng C-C, Ordway NR, Zhang X, Lu Y-M, Fang H, Fayyazi AH. Loss of cervical endplate integrity following minimal surface preparation. *Spine (Phila Pa 1976)*. 2007;32(17):1852–1855. doi:10.1097/BRS.0b013e31811ece5a
- de Beer N, Scheffer C. Reducing subsidence risk by using rapid manufactured patient-specific intervertebral disc implants. *Spine J*. 2012;22(11):1060–1066. doi:10.1016/j.spinee.2012.10.003
- Kishimoto M, Akeda K, Sudo A, Espinoza Orías AA, Inoue N. In vivo measurement of vertebral endplate surface area along the whole-spine. *J Orthop Res*. 2016;34(8):1418–1430. doi:10.1002/jor.23354
- Chen H, Jiang D, Ou Y, Zhong J, Lv F. Geometry of thoracolumbar vertebral endplates of the human spine. *Eur Spine J*. 2011;20(11):1814–1820. doi:10.1007/s00586-011-1787-5
- Kunkel ME, Schmidt H, Wilke HJ. Prediction equations for human thoracic and lumbar vertebral morphometry. *J Anat*. 2010;216(3):320–328. doi:10.1111/j.1469-7580.2009.01187.x
- Panjabi MM, Goel V, Oxland T, et al. Human lumbar vertebrae. quantitative three-dimensional anatomy. *Spine (Phila Pa 1976)*. 1992;17(3):299–306. doi:10.1097/00007632-199203000-00010
- Oravec D, Quazi A, Xiao A, et al. Digital tomosynthesis and high resolution computed tomography as clinical tools for vertebral endplate topography measurements: comparison with micro-computed tomography. *Bone*. 2015;81:300–305. doi:10.1016/j.bone.2015.07.033

Funding: The authors received no financial support for the research, authorship, and/or publication of this article.

Declaration of Conflicting Interests: The authors report no conflicts of interest in this work.

Disclosures: The authors report no disclosures related to this article.

Patient Consent for Publication: The requirement for consent for publication was waived due to the retrospective nature of the study.

Ethics Approval: Ethical approval was obtained from the institutional research ethics committee (approval number 2.165.295, date 10/07/2017).

Data Availability Statement: The datasets generated during and/or analyzed during the current study are available from the corresponding author on reasonable request.

Corresponding Author: Rangel Roberto de Assis, Department of Orthopedics and Anesthesiology, Ribeirao Preto Medical School - Sao Paulo University, Av. Bandeirantes, 3900 - Campus da Usp, Ribeirão Preto - SP, 14049-900, Brazil; rangelrassis@gmail.com

Published 31 August 2022

This manuscript is generously published free of charge by ISASS, the International Society for the Advancement of Spine Surgery. Copyright © 2022 ISASS. To see more or order reprints or permissions, see <http://ijssurgery.com>.